

# Systemic contact dermatitis due to corrosion of titanium-coated nickel and cobalt bone plate fixation

## A case report

Oki Suwarsa, MD, PhD, Rachel Marsella Rahardjo, MD, Endang Sutedja, MD, PhD, Hartati Purbo Dharmadji, MD, Reti Hindritiani, MD, PhD, Hendra Gunawan, MD, PhD\*

### Abstract

**Rationale:** Corrosion refers to the degradation of a material that occurs following its interaction with other substances in the environment. Corrosion of metallic substances into tissues may lead to inflammatory responses such as systemic contact dermatitis (SCD), a skin condition where an individual who has previously been sensitized to a particular allergen via the cutaneous route will subsequently react to same allergen via the systemic route. This condition occurs following exposure to allergens such as metals, medications, and certain food substances. In recent years, the use of metal plates for internal fixation has become increasingly common in bone fracture repairs.

**Patient concerns:** A 34-year-old Indonesian male presented with systemic erythema with itching 7 days following a bone plate fixation as a management for mandibular fracture.

**Diagnoses:** Physical examination showed pruritic red macules, papules, and scales on almost his entire body, along with facial swelling. The patch test results revealed a positive reaction to nickel and cobalt. Therefore, the patient was diagnosed with SCD.

**Interventions:** The patient was treated with topical and systemic corticosteroids as well as bone plate removal.

**Outcome:** After treatment, the eruption turned brown, the itching was resolved, and there were no facial swelling as well.

**Lessons:** This case report highlights the need to consider the occurrence of SCD in patients following bone plate fixation.

**Abbreviation:** SCD = systemic contact dermatitis.

**Keywords:** cobalt, metal corrosion, nickel, patch test, systemic contact dermatitis

## 1. Introduction

Corrosion can be defined as the degradation of a material due to reaction with its environment. Corrosion includes the process of destruction and dissolution in saliva. Metal corrosion leads to the release of metallic ions into the surrounding tissues,<sup>[1]</sup> causing inflammatory responses such as systemic contact dermatitis (SCD), a skin disease occurring in previously sensitized individuals following systemic re-exposure of the same or

cross-reacting allergen.<sup>[1–4]</sup> Systemic route of administration includes uptake of an allergen via cutaneous, transmucosal, oral, intravenous, intramuscular, and inhalational routes, as well as implants. These allergens include drugs, food substances, and metals such as nickel and cobalt.<sup>[1–3]</sup> Metal allergy in patients following bone plate fixation generally presents as delayed-type hypersensitivity eczema.<sup>[4]</sup> This condition can manifest in several different ways, including flares at previous patch test sites, symmetrical intertriginous and flexural exanthema, exfoliative erythroderma, and widespread dermatitis.<sup>[2,4]</sup> Bone plate fixation is generally used to accelerate fracture healing.<sup>[5]</sup> This report will discuss a case of SCD occurring due to corrosion of titanium-coated nickel and cobalt bone plate.

## 2. Case presentation

A 34-year-old Indonesian male presented with pruritic red macules, papules, and scales on almost his entire body. The lesions developed 7 days following bone plate fixation as a treatment for mandibular fracture (Fig. 1). History of similar skin reactions, familial history of atopic dermatitis, history of asthma, use of ear piercing or other implants, and occupational and nonoccupational exposure to chemical substances were all denied. Furthermore, the patient denied consumption of excessive amounts of chocolate, canned food, or beans. The patient worked as a security guard in a bank. On physical examination, erythematous macules and papules were observed

Editor: Esaki M. Shankar.

The authors have no conflicts of interest to disclose.

Division of Allergy and Immunology, Department of Dermatology and Venereology, Faculty of Medicine, Universitas Padjadjaran—Dr. Hasan Sadikin Hospital, Bandung, Indonesia.

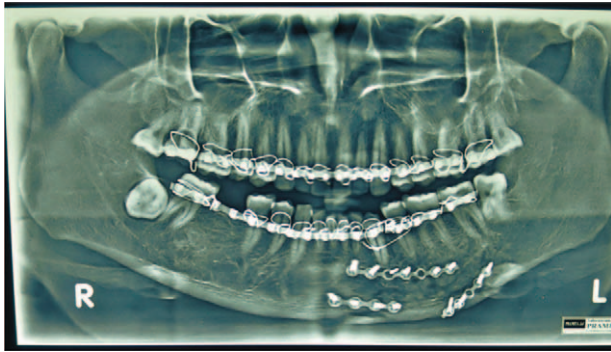
\* Correspondence: Hendra Gunawan, Department of Dermatology and Venereology, Faculty of Medicine, Universitas Padjadjaran—Dr. Hasan Sadikin Hospital, Bandung, Indonesia (e-mail: endaguna@yahoo.com).

Copyright © 2017 the Author(s). Published by Wolters Kluwer Health, Inc. This is an open access article distributed under the terms of the Creative Commons Attribution-Non Commercial-No Derivatives License 4.0 (CCBY-NC-ND), where it is permissible to download and share the work provided it is properly cited. The work cannot be changed in any way or used commercially without permission from the journal.

Medicine (2017) 96:50(e9120)

Received: 7 June 2017 / Received in final form: 14 November 2017 / Accepted: 15 November 2017

<http://dx.doi.org/10.1097/MD.00000000000009120>



**Figure 1.** Bone plate fixation over the left mandible.

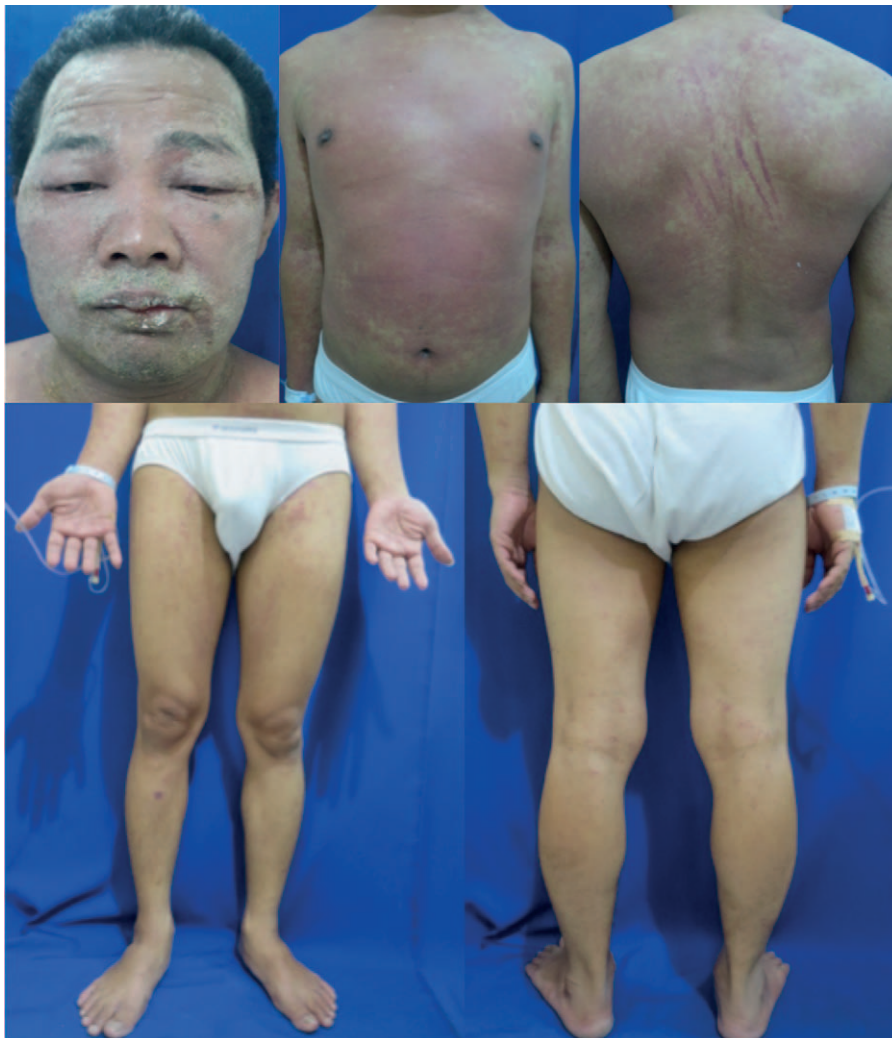on almost his entire body. Facial swelling was also observed, particularly around the mandibular region (Fig. 2). After 8 weeks, the patch test was performed and a positive reaction to nickel and cobalt was found, along with a negative reaction to titanium on readings at days 2, 3, and 4 (Fig. 3). The patient was then treated with twice daily topical 0.25% desoximetasone cream and systemic corticosteroid (dexamethasone 1 mg/kg/day) for a week,

along with removal of the bone plate fixation. Following treatment, the lesions turned brown and resolved completely 1 week later. Ethics approval was not required for this paper as it is a case report. Patient consent was obtained to the writing of this report.

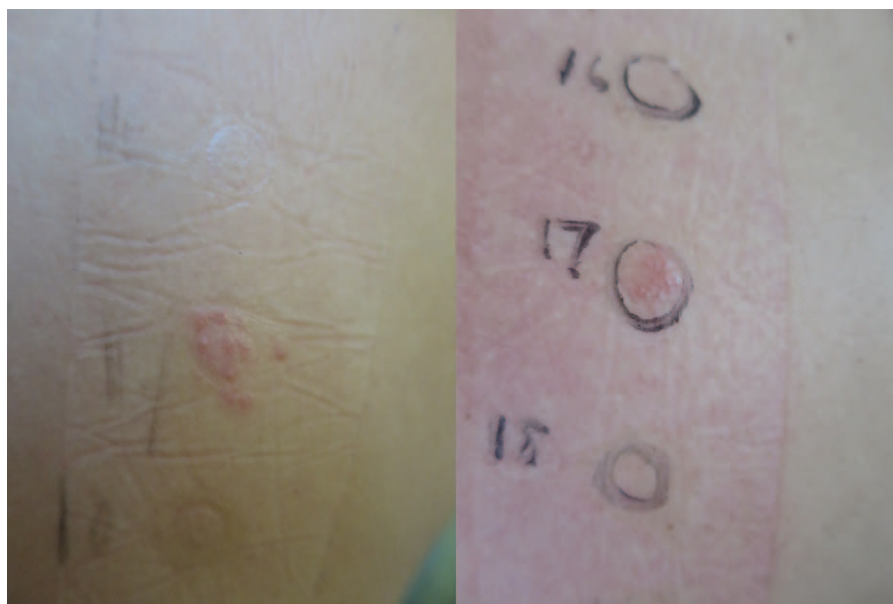### 3. Discussion

Allergic contact dermatitis (ACD) is usually triggered by the external exposure of an allergen to the skin. However, a systemically administered allergen may occasionally affect the skin through the circulatory system, leading to SCD,<sup>[4]</sup> which is defined as the occurrence of dermatitis following a noncutaneous exposure to an allergen in a person who has previously been cutaneously sensitized.<sup>[6]</sup> This condition occurs following exposure to allergens such as metals, medications, and food substances.<sup>[1]</sup> Nickel is the most common contact allergen, and the presence of certain factors such as piercing, occupational exposure, or history of atopic dermatitis can contribute to the development of the disease. Furthermore, a younger age is also associated with the development of nickel contact allergy.<sup>[3]</sup>

The clinical manifestations of SCD can be highly variable, and although the symptoms are believed to appear exclusively on the



**Figure 2.** Multiple erythematous macules and papules, as well as facial swelling.



**Figure 3.** Patch test result after 96 hours, indicating the presence of erythematous papules following exposure to cobalt (left sided) and nickel (right sided).

skin, general symptoms are also occasionally observed. Clinical manifestations of this condition may include dermatitis in areas of previous exposure (flare up of previous dermatitis and positive patch test sites), dermatitis on previously unaffected skin (vesicular hand eczema, flexural dermatitis, baboon syndrome, maculopapular rash, and vasculitis-like lesions), as well as general symptoms (headache, malaise, arthralgia, diarrhea, vomiting, and fever).<sup>[2,4]</sup> Baboon syndrome has been used to refer to SCD manifesting as well-demarcated eruptions on the buttocks, in the genital area, or as a V-shaped lesion on the inner thighs with colors ranging from dark violet to pink. Vesicular hand eczema (pompholyx or dyshidrotic eczema) manifests as pruritic eruptions on the palms, volar regions, sides of the fingers of the hand, and occasionally the plantar aspects of the feet, in the form of deep-seated vesicles with sparse or no erythema. Recurrent vesicular hand eczema, as well as erythema or a flare of dermatitis in the elbow and/or knee flexures are also commonly observed in SCD. Moreover, nonspecific maculopapular rashes may also often be a part of an SCD reaction.<sup>[2,6]</sup>

The pathogenesis of SCD has been well described as an immune-mediated, delayed-type hypersensitivity (type IV) reaction involving sensitization and elicitation phases.<sup>[1,2]</sup> The induction (sensitization) phase refers to events following the first contact with an allergen. Following penetration, allergen is then diffusely distributed into the skin and reacts with antigen-presenting cells that present the bound antigen to T lymphocytes. This results in the production of effector and memory T-cell populations, which are released into the blood flow.<sup>[7,8]</sup> Once these cells are sensitized, they return to the skin, ready to act on target cells when the individual is exposed to the allergen either by oral or systemic routes, leading to cutaneous manifestations.<sup>[2,7,9]</sup> Common routes of exposure include oral, intramuscular, intravenous, inhalation, and subcutaneous. While SCD has been described as a type IV delayed-type hypersensitivity, SCD may also involve a type III immune response, as antigen-antibody complexes have been found in the skin and the blood in such reactions.<sup>[6]</sup>

Novak et al<sup>[10]</sup> showed a strong association between filaggrin mutations and atopic dermatitis (AD) as well as contact

sensitization to nickel.<sup>[10]</sup> Similarly, another study also reported a positive association between nickel sensitization and AD.<sup>[11]</sup> The epidermal barrier impairments in AD is expected to facilitate the penetration of haptens, thereby enhancing contact sensitization.<sup>[6]</sup> It is necessary to be aware of the systemic reactions that occur with SCD, which can be chronic and lead to severe symptoms that are often mistaken for AD.<sup>[4]</sup>

A patch test is the primary tool to determine allergens causing delayed-type hypersensitivity or type IV reactions,<sup>[8]</sup> and is the gold standard diagnostic tool for the detection of metal hypersensitivity.<sup>[4]</sup> The recommended sites are the upper back and outer region of the upper arm. The test is performed by applying test allergen strips onto the skin under occlusion for 2 days, following which an evaluation is conducted at days 3, 4, and 7.<sup>[8,12]</sup> In this case, the patch test was performed with 5% nickel sulfate, 1% cobalt chloride, and the bone plate used for the patient's mandibular fixation (as is). The diagnosis of SCD is also supported if a patient shows improvements following avoidance of exposure to the proven allergen by either oral or other routes.<sup>[6]</sup>

The 5 base metal alloy systems used in dental bone plate fixation are stainless steels, nickel-chrome, cobalt-chromium, titanium, and nickel-titanium alloys.<sup>[13]</sup> Metals that have been previously reported to cause SCD include nickel, mercury, gold, cobalt, copper, chromium, and zinc.<sup>[1,4]</sup> These metals are haptens that require bonding to protein molecules to form antigenic complexes to allow recognition by dendritic cells, which leads to the occurrence of sensitization.<sup>[4]</sup>

Nickel exposure may occur following contact with coins, jewelry, tools, clothing, utensils, nickel-plated objects (mobile phones and laptops), and food substances. This metal is manufactured into steel and a variety of alloys containing cobalt, palladium, iron, titanium, gold, and magnesium.<sup>[4]</sup> Canned foods, cocoa, chocolate, soy, legumes, herring, salmon, shellfish, cashews, and mackerel are several examples of food substances with a high nickel content.<sup>[1,3]</sup> Metal surgical devices and implants are the major causes for iatrogenic SCD to nickel.<sup>[3]</sup> Sensitization to nickel is also likely to occur with ear and body



piercings. In recent years, different types of consumer products have also accounted for nickel allergy, including spectacle frames, necklaces, metal clothing elements, wrist watches, jeans buttons among many others.<sup>[14]</sup> Cobalt is generally used in making jewelries, prosthetics, and various everyday objects.<sup>[2,3]</sup> Concomitant nickel and cobalt allergy has previously been reported and has proven to occur on the basis of cosensitization.<sup>[3]</sup> Research shows that nickel and cobalt are metal alloys most commonly used in bone plate fixation.<sup>[13]</sup> In the current case, the composition of the mandibular device was titanium, various grades of stainless steel (carbon, cuprum, manganese, cobalt, iron, nickel, and chromium), and anodized aluminum.

The process of destruction and dissolution following exposure to saliva, along with erosion caused by food, chewing, and bacterial activity, can lead to corrosion of metallic substances in the oral environment.<sup>[13]</sup> When hypersensitive elements such as nickel are involved in the leaching process, the increased release of metallic ion into surrounding tissues may possibly result in inflammatory tissue responses.<sup>[13,15]</sup> Bhola et al<sup>[16]</sup> stated that the leached ions may induce potentially osteolytic cytokines into tissues, leading to implant loosening and causing severe allergic reactions or hypersensitivity. On the other hand, titanium has a high resistance to corrosion in a physiological environment and has a low prevalence (0.6%) of allergy.<sup>[17,18]</sup> In this particular case, corrosion of the titanium plate coating is suspected, which may have exposed the nickel and cobalt into the surrounding tissues.

Pigatto et al<sup>[9]</sup> reported 1 case of SCD following oral surgical implantation of titanium on the maxillary bone. Similarly, Darlenski et al<sup>[3]</sup> also reported 2 cases of SCD following implantation of a metal stabilizing device for foot bone and metacarpal bone fractures.<sup>[3]</sup> This case report contributes to the body of knowledge by demonstrating the appearance of SCD symptoms following corrosion of plate coating and exposure of its constituent metals to the oral environment.

The mainstay treatment of SCD is avoidance of exposure or contact with the allergen.<sup>[1-3]</sup> Topical steroids with different potencies can be applied, depending on the severity of the skin inflammation. In severe cases, systemic corticosteroids or immunosuppressants may also be necessary.<sup>[3]</sup> An option for symptomatic patients with positive patch test results following implantation or bone plate fixation is removal of the bone plate and replacement with a nonallergenic alloy.<sup>[1]</sup>

#### 4. Conclusion

Although uncommon in general dermatological practice, SCD following bone plate fixation should be suspected and recognized by clinicians. The use of such devices should be avoided and more

suitable alternatives are preferred whenever possible. Therefore, evaluation of patients with metal allergies is crucial before and after certain medical procedures.

#### Acknowledgment

The authors would like to extend their gratitude to the staff of the Department of Dermatology and Venereology, Faculty of Medicine, Universitas Padjadjaran, for critically reading and editing this article.

#### References

- [1] Aquino M, Mucci T. Systemic contact dermatitis and allergy to biomedical devices. *Curr Allergy Asthma Rep* 2013;13:518–27.
- [2] Veien NK, Menne K, Frosch PJ, Menne T, Lepoittevin JP. Systemic contact dermatitis. *Contact Dermatitis* Springer, Berlin, Germany: 2006; 295–307.
- [3] Darlenski RB, Demerdjieva Z, Kazandjieva JS, et al. Systemic contact dermatitis to nickel. *OA Dermatol* 2014;11:7.
- [4] Yoshihisa Y, Shimizu T. Review article: metal allergy and systemic contact dermatitis: an overview. *Dermatol Res Pract* 2012;2012:1–5.
- [5] Uhthoff HK, Poitras P, Backman DS. Internal plate fixation of fractures: short history and recent developments. *J Orthop Sci* 2006;11:118–26.
- [6] Lampel HP, Silvestri DL. Systemic contact dermatitis: current challenges and emerging treatments. *Curr Treat Options Allergy* 2014;1:348–57.
- [7] Abbas AK, Lichtman AF, Phillai S. Hypersensitivity disorders caused by immune responses. *Basic Immunology Functions and Disorders of the Immune System* 4th ed. 2014; Elsevier Saunders, Philadelphia, PA:207–23.
- [8] Wahlberg JE, Lindberg M, Phillai S, Frosch PJ, Menne MT, Lepoittevin JP. Patch testing. *Contact Dermatitis* 4th ed. Springer, Berlin, Germany: 2006;366–86.
- [9] Pigatto PD, Brambilla L, Ferrucci S, et al. Systemic allergic contact dermatitis associated with allergy to intraoral metals. *Dermatol Online J* 2014;20:6.
- [10] Novak N, Baurecht H, Schafer T, et al. Loss of function mutations in the filaggrin gene and allergic contact sensitization to nickel. *J Invest Dermatol* 2008;128:1430–5.
- [11] Diepgen TL, Fartasch M, Hornstein OP. Evaluation and relevance of atopic basic and minor features in patients with atopic dermatitis in the general population. *Acta Derm Venereol (Stockh)* 1989;144:50–4.
- [12] Spiewak R. Patch testing for contact allergy and allergic contact dermatitis. *Open Allergy J* 2008;1:42–51.
- [13] Roach M. Base metal alloys used for dental restorations and implants. *Dent Clin North Am* 2007;51:603–27.
- [14] Darlenski R, Kazandjieva J, Pramatarov K. Review: the many faces of nickel allergy. *Int J Dermatol* 2012;51:523–30.
- [15] Rylander LS, Milbrandt JC, Armington E, et al. Trace metal analysis following locked volar plating for unstable fractures of the distal radius. *Iowa Orthop J* 2010;30:89–93.
- [16] Bhola R, Bhola SM, Mishra B, et al. Corrosion in titanium dental implants/prostheses—a review. *Trends Biomater Artif Organs* 2011;25: 34–6.
- [17] Goutam M, Giriapura C, Mishra SK, et al. Titanium allergy: a literature review. *Indian J Dermatol* 2014;59:630.
- [18] Lahori M, Sharma AJ, Sikri N. Titanium: a metal allergen of growing significance. *Guident* 2015;8:44–9.