

Case Report

Debulking surgery and hyperthermic intraperitoneal chemotherapy in the management of a recurrent aggressive uterine myxoid leiomyosarcoma with peritoneal dissemination



Daisuke Inoue, Makoto Yamamoto, Genki Sugita, Tetsuji Kurokawa, Yoshio Yoshida *

Department of Obstetrics and Gynecology, Faculty of Medical Sciences, University of Fukui, Fukui, Japan

ARTICLE INFO

Article history:

Received 15 May 2015

Received in revised form 26 June 2015

Accepted 30 June 2015

Available online 2 July 2015

Keywords:

Advanced myxoid leiomyosarcoma

Peritoneal sarcomatosis

Hyperthermic intraperitoneal chemotherapy

1. Introduction

Uterine leiomyosarcomas (LMSs) are rare but very aggressive tumors. Patients with advanced disease have a 5-year survival rate less than 20%. In addition, peritoneal sarcomatosis (PS), as a quite rare aggressive presentation of uterine LMS, may present with vague symptoms, leading to poor outcomes. PS refers to a condition in which intra-abdominal sarcoma spread is clinically dominant, and it may occur at the final stage of disease progression (Jimenez et al., 2014).

Limited medical data have been published regarding the management of PS. No prior reasonable treatment option has been proposed, and consensus has not yet been established for treatment of this presentation of uterine LMS.

Yet many studies have shown meaningful outcomes and survival because of high response to chemotherapy by the simultaneous use of hyperthermia and drug therapy in some kinds of cancer patients with peritoneal dissemination, such as that arising from the appendix or mesothelioma (Sugarbaker, 2006; Yan et al., 2009). In addition, some studies have suggested that there is some potential to improve outcomes in peritoneal dissemination from recurrent uterine sarcoma (Berthet et al., 1999; Rossi et al., 2004; Baratti et al., 2010; Jimenez et al., 2014). However, there has been no report of the treatment of patients with PS arising from uterine myxoid leiomyosarcoma (uterine

MLMS) with hyperthermic intraperitoneal chemotherapy (HIPEC). Thus, a recent case of such PS is reported, and the literature on HIPEC for the treatment of abdominal uterine sarcomatosis is reviewed.

2. Case report

A 65-year-old woman, gravida 2 para 2, was referred to our hospital with complaints of abdominal distention and shortness of breath. The patient had a history of treatment for an advanced uterine MLMS with primary debulking surgery (DS) that included total abdominal hysterectomy, bilateral salpingo-oophorectomy, omentectomy, and resection of disseminated peritoneal tumor. The patient's uterus was removed intact. Before her first surgery, thoraco-abdominal CT and abdominal MRI were performed, and these revealed no extra-abdominal disease, including no lung disease. After DS, she was given 8 cycles of intravenous gemcitabine (900 mg/m² over 90 min on days 1 and 8) and docetaxel (75 mg/m² on day 8) with granulocyte growth factor support on day nine of a 21-day cycle scheduled every 3 weeks at another hospital. The patient developed grade 4 leukocytopenia with initial chemotherapy but tolerated it with granulocyte growth factor support. Since the tumor had disseminated aggressively, the primary DS resulted in a sub-optimal outcome. Although the patient underwent this chemotherapy, systemic computed tomography (CT) revealed progressive disease (PD) according to the Response Evaluation Criteria in Solid Tumors (RECIST) because of disseminated aggressive uterine MLMS. A follow-up CT 2 months after the last treatment revealed a rapidly growing abdominal mass, massive mucinous ascites ranging under the diaphragm, multiple lymph node metastases, and a massive malignant pleural effusion in the left thorax. At that time, the patient's life expectancy was estimated to be 1 month. Despite difficulties in complete resection of the tumor, the patient decided to undergo DS in our hospital.

After obtaining the patient's informed consent, secondary DS was performed. There were large amounts of disseminated gelatinous peritoneal lesions and mucus in the abdominal cavity, extending from the pelvic wall. An attempt was made to resect these disseminated peritoneal lesions as much as possible. Approximately 4000 g of the tumor was resected, but a part remained in the pelvis. Furthermore, the left diaphragm was dissected, and 1800 cm³ of malignant pleural effusion was removed with small pleural metastases.

After DS, HIPEC using cisplatin 150 mg/body, mitomycin-C 20 mg/body, and etoposide 200 mg/body was given intraperitoneally

* Corresponding author at: Department of Gynecology, Faculty of Medical Sciences, University of Fukui, 23-3 Matsuoka-Shimoaizuki, Eihei-cho, Fukui 910-1193, Japan.
E-mail address: yyoshida@u-fukui.ac.jp (Y. Yoshida).

and intrathoracically based on our procedure (Yoshida et al., 2005). (Fig. 1) Although there has been no experience using HIPEC for uterine MLMS, we have considerable experience with good outcomes using HIPEC with Sugarbaker's regimen consisting of cisplatin, VP-16, and mitomycin C for mucinous malignant tumors, such as advanced epithelial ovarian cancer or pseudomyxoma peritonei. In addition, this regimen of chemotherapy with HIPEC has been accepted by the Ethics Review Board of our department. Thus, this chemotherapy regimen was selected.

Microscopically, the uterine smooth muscle tumors showed myxoid change in $\geq 60\%$ of the lesion with the presence of focal severe atypia, infiltrative growth, vascular invasion, mitotic index of ≥ 5 mitotic figures/50 high-power fields, and tumor central necrosis. (Fig. 2) This tumor was interpreted as being uterine MLMS with the potential for aggressive behavior (Burch and Tavassoli, 2011).

A follow-up chest-abdominal CT 3 weeks after DS with HIPEC identified marked reduction of the intraperitoneal tumor, and no pleural effusion was observed. There was residual tumor in the pelvis, but the symptoms of abdominal fullness and shortness of breath had improved. Two months after surgery, intravenous adriamycin was administered as adjuvant chemotherapy. However, residual tumor increased rapidly 3 months after surgery. The patient received palliative therapy and died 5 months after surgery.

3. Comment

Systemic chemotherapy is the treatment of choice for inoperative, locally advanced, recurrent, or metastatic uterine LMS (doxorubicin, gemcitabine, or gemcitabine/docetaxel), with a median overall survival of 12.1–17.9 months (O'Cearbhaill and Hensley, 2010). However, there are no clear data available on the benefit for patients with PS arising from uterine LMS, especially MLMS. This is the first case report of treatment for recurrent PS arising from uterine MLMS with DS and HIPEC. Uterine MLMS is a very rare and aggressive variant of uterine sarcoma, of which only 56 cases have been described in the literature published in English (Imai et al., 2015). Previously reported cases of MLMS had a low mitotic index with a favorable prognosis. However, in a patient with a high mitotic index in combination with an infiltrative growth pattern, the prognosis is very poor. The present patient had a high mitotic index and severe cell atypia with an infiltrative growth pattern. This MLMS tumor was interpreted as having the potential for aggressive behavior (Burch and Tavassoli, 2011). In fact, the patient had PS recurrence 2 months after her primary complete surgery while receiving 8

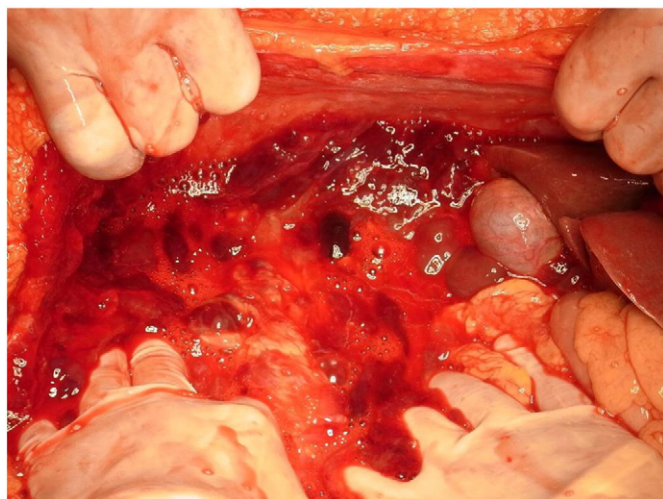


Fig. 1. Exploratory laparotomy shows large amounts of disseminated gelatinous peritoneal lesions and mucus in the abdominal cavity, extending from the pelvic wall.

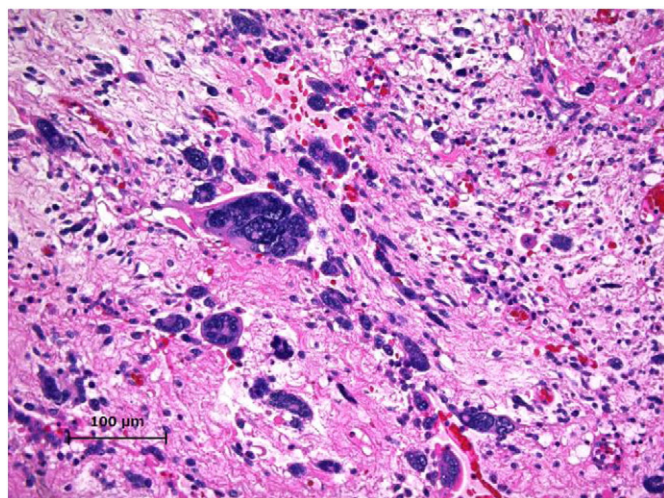


Fig. 2. Microscopically ($\times 20$), uterine smooth muscle tumors with myxoid change in $\geq 60\%$ of the lesion with the presence of focal severe atypia, infiltrative growth, vascular invasion, mitotic index of ≥ 5 mitotic figures/50 high-power fields, and tumor central necrosis.

cycles of gemcitabine and doxorubicin, the combination of which is the most active regimen.

Treatment of peritoneal recurrence following surgical resection of intra-abdominal sarcoma presents a significant challenge to clinicians. A summary of the literature on HIPEC in recurrent uterine PS is shown in Table 1. Eilber et al. reported 44 patients who had recurrent abdominal soft tissue sarcomas, including 14 uterine sarcomas, who underwent surgical excision of all gross disease and postoperative intraperitoneal chemotherapy with mitoxantrone. They concluded that the combination of aggressive surgical resection and intraperitoneal chemotherapy for recurrent abdominal sarcomas is a feasible treatment approach with minimal toxicity. Furthermore, this therapeutic approach significantly decreased the likelihood of developing recurrent intraperitoneal disease, especially uterine LMS (Eilber et al., 1999). Berthet et al. developed a new treatment strategy that involved cytoreductive surgery followed by HIPEC for recurrent abdominopelvic sarcoma. They reported that the median survival of their 43 patients, including 4 uterine sarcomas, was 20 months (Berthet et al., 1999). Rossi et al. reported a phase I study of cytoreductive surgery combined with HIPEC in 29 patients with multifocal primary disease and 31 patients with recurrent abdominal sarcoma, including 12 uterine sarcomas (8 LMS and 4 endometrial stromal sarcomas). They reported that the estimated median overall survival was 36 months, and the median time to local disease recurrence was 24 months. Although these results were encouraging, they stated that the toxicity rate was substantial, and that the therapeutic potential of DS plus HIPEC should be explored (Rossi et al., 2004). Baratti et al. published an interesting report about PS. They assessed the outcome of clinically and pathologically homogeneous subsets of patients with PS uniformly treated by DS and HIPEC. They reported that the operative mortality was 3.7%, morbidity was 21.6%, and median overall survival was 26.2 months. Only patients with uterine LMS had a higher proportion of long survivors and the best locoregional recurrence-free survival (Baratti et al., 2010). Recently, Jimenez et al. stated that DS with HIPEC showed promise as a treatment modality for selected patients with recurrent high-grade uterine sarcoma with PS. They emphasized that careful patient selection is important to achieve better outcomes in PS. Complete cytoreductive surgery is important, and the agent for HIPEC is also important to achieve better outcomes (Jimenez et al., 2014).

Thus, we expected some effect for recurrent or metastatic uterine MLMS patients with prior chemotherapy using the combination of docetaxel and gemcitabine with DS with HIPEC. Unfortunately, the operative procedure resulted in incomplete resection, and it was followed

Table 1
Summary of literature data on HIPEC in recurrent uterine peritoneal sarcomatosis.

Author (year)	Number of patients	Histology of primary tumor (number of patients)	Histological grade (number of patients)	Previous treatments (number of patients)	Completeness of cytoreduction (number of patients)	HIPEC chemo used (number of patients)	Median follow-up (months)	Median overall survival (months)	5-Year survival (%)
Berthet et al. (1999)	43	ULMS (4) GIST (10) RPS (16) Other (13)	Grade 1 (10) Grade 2 (11) Grade 3 (22)	Surgery (43)	Complete (32) (tumor residuals <2.5 mm in greatest diameter) Incomplete (11)	Cisplatin (13) or Cisplatin + doxorubicin (3) Not done (27)	20	20	30
Rossi et al. (2004)	60	ULMS (12) GIST (14) RPS (34)	Low-grade (31) High-grade (29)	Surgery (25) Chemotherapy (15) Radiotherapy (6) Combination (6) Not done (8)	Complete (60) (tumor residuals <3 mm in greatest dimension)	Cisplatin + doxorubicin (60)	26	34	38
Baratti et al. (2010)	11	ULMS (11)	Grade 1 (2) Grade 2 (1) Grade 3 (8)	Surgery (8) Chemotherapy (5) Radiotherapy (3)	Complete (10) (macroscopically) Incomplete (1) (>25 mm residual tumor nodule)	Cisplatin + mitomycin-C/doxorubicin (11)	No data	29.5	No data
	Total 37	GIST (8) RPS (13) Other (5)					104	26	24
Jimenez et al. (2014)	3	ULMS (2) UADS (1)	High-grade (3)	Surgery (2) Chemotherapy (2) Not done (1)	Complete (3) (macroscopically)	Cisplatin + doxorubicin (1) Melphalan (2)		2 with NED (143, 37 respectively) 1 AWD (57)	
Present (2015)	1	UMLMS (1)	High-grade (1)	Surgery (1) Chemotherapy (1)	Incomplete (1) (>25 mm residual tumor nodule)	Cisplatin + mitomycin C + etoposide (1)		Local-free survival 2 months	

HIPEC, hyperthermic intraoperative chemotherapy; CDDP, cisplatin; RPS, retroperitoneal sarcoma; GIST, gastrointestinal stromal tumor; UADS, uterine adenocarcinoma; UMLMS, uterine myxoid leiomyosarcoma; AWD, alive with disease; NED, no evidence of disease.

by HIPEC with Sugarbaker's regimen consisting of cisplatin, VP-16, and mitomycin C as chemotherapeutic agents (Yoshida et al., 2005). The patient had complaint-free and local recurrence-free survival for 2 months, but disease recurred after 2 months, and she died 5 months after undergoing HIPEC. HIPEC is technically feasible and well tolerated. However, the operative procedure in the present case was incomplete, and the chemotherapeutic regimen may not have been adequate.

Incomplete resection of all visible disease from the abdominal cavity, followed by the administration of HIPEC, did not achieve a good outcome. As for the agents, Lim et al. reported that, although the HIPEC technique is feasible for patients with sarcomatosis, the use of cisplatin and mitoxane as chemotherapeutic agents is associated with significant toxicity and limited clinical benefit (Lim et al., 2007). Meanwhile, melphalan has been reported as the agent of choice in the treatment of resistant uterine sarcoma (Jimenez et al., 2014).

In recurrent and metastatic uterine sarcoma with PS, treatment is quite difficult, and patients have a poor prognosis. However, it may be possible to achieve better outcomes in PS if careful case selection based on the pathological stage at the time of surgery, tumor-free resection margin, tumor size, histological type, and type of chemotherapy is performed.

Our experience and the review of the literature suggest that patients with PS arising from uterine sarcoma who undergo an incomplete operative procedure and are then treated by HIPEC with Sugarbaker's regimen consisting of cisplatin, VP-16, and mitomycin C as chemotherapeutic agents benefit less. However, this approach may be promising if complete cytoreductive surgery followed by HIPEC is performed. An important issue is the agent of choice in the treatment of HIPEC, with the use of melphalan as an alternative agent for HIPEC in patients with recurrent PS providing meaningful outcomes and survival.

Another important point is that further larger investigations of HIPEC using melphalan for PS arising from uterine sarcoma in patients who undergo complete operative procedures are needed.

Conflict of interest statement

The authors declare that there are no conflicts of interest.

References

- Baratti, D., Pennacchioli, E., Kusamura, S., Fiore, M., Balestra, M.R., Colombo, C., Mingrone, E., Gronchi, A., Deraco, M., 2010. Peritoneal sarcomatosis: is there a subset of patients who may benefit from cytoreductive surgery and hyperthermic intraperitoneal chemotherapy? *Ann. Surg. Oncol.* 17, 3220–3228.
- Berthet, B., Sugarbaker, T.A., Chang, D., Sugarbaker, P.H., 1999. Quantitative methodologies for selection of patients with recurrent abdominopelvic sarcoma for treatment. *Eur. J. Cancer.* 35, 413–419.
- Burch, D.M., Tavassoli, F.A., 2011. Myxoid leiomyosarcoma of the uterus. *Histopathology* 59, 1144–1155.
- Eilber, F.C., Rosen, G., Forscher, C., Nelson, S.D., Dorey, F.J., Eilber, F.R., 1999. Surgical resection and intraperitoneal chemotherapy for recurrent abdominal sarcomas. *Ann. Surg. Oncol.* 6, 645–650.
- Imai, H., Yagi, H., Okugawa, K., Kenjo, H., Ohgami, T., Kawano, Y., Kaneki, E., Ichinoe, A., Asanoma, K., Yahata, H., Sonoda, K., Kobayashi, H., Kaku, T., Kato, K., 2015. Uterine myxoid leiomyosarcoma with tumor embolism extending into the right atrium. *Case Rep. Obstet. Gynecol.* 316262.
- Jimenez, W.A., Sardi, A., Nieroda, C., Gushchin, V., 2014. Cytoreductive surgery and hyperthermic intraperitoneal chemotherapy in the management of recurrent high-grade uterine sarcoma with peritoneal dissemination. *Am. J. Obstet. Gynecol.* 210, 259.e1–259.e8.
- Lim, S.J., Cormier, J.N., Feig, B.W., Mansfield, P.F., Benjamin, R.S., Griffin, J.R., Chase, J.L., Pisters, P.W., Pollock, R.E., Hunt, K.K., 2007. Toxicity and outcomes associated with surgical cytoreduction and hyperthermic intraperitoneal chemotherapy (HIPEC) for patients with sarcomatosis. *Ann. Surg. Oncol.* 14, 2309–2318.
- O'Ceirbhail, R., Hensley, M.L., 2010. Optimal management of uterine leiomyosarcoma. *Expert. Rev. Anticancer. Ther.* 10, 153–169.
- Rossi, C.R., Deraco, M., De Simone, M., Mocellin, S., Pilati, P., Foletto, M., Cavaliere, F., Kusamura, S., Gronchi, A., Lise, M., 2004. Hyperthermic intraperitoneal intraoperative chemotherapy after cytoreductive surgery for the treatment of abdominal sarcomatosis: clinical outcome and prognostic factors in 60 consecutive patients. *Cancer* 100, 1943–1950.
- Sugarbaker, P.H., 2006. New standard of care for appendiceal epithelial neoplasms and pseudomyxoma peritonei syndrome? *Lancet Oncol.* 7, 69–76.
- Yan, T.D., Deraco, M., Baratti, D., Kusamura, S., Elias, D., Glehen, O., Gilly, F.N., Levine, E.A., Shen, P., Mohamed, F., Moran, B.J., Morris, D.L., Chua, T.C., Piso, P., Sugarbaker, P.H., 2009. Cytoreductive surgery and hyperthermic intraperitoneal chemotherapy for malignant peritoneal mesothelioma: multi-institutional experience. *J. Clin. Oncol.* 27, 6237–6242.
- Yoshida, Y., Sasaki, H., Kurokawa, T., Kawahara, K., Shukunami, K., Katayama, K., Yamaguchi, A., Kotsuji, F., 2005. Efficacy of intraperitoneal continuous hyperthermic chemotherapy as consolidation therapy in patients with advanced epithelial ovarian cancer: a long-term follow-up. *Oncol. Rep.* 13, 121–125.