

# A case report of Schatzker type VI tibial plateau fracture treated with double reverse traction closed reduction combined with minimally invasive percutaneous plate osteosynthesis technique

## A case report

Dian-Qing Li, PhD, De-Ye Song, MD\*, Jiang-Dong Ni, MD, Mu-Liang Ding, MD, Jun Huang, MD

### Abstract

**Rationale:** The knee joint is an important weight-bearing joint, tibial plateau fractures affect knee function and stability. High-energy intra-articular fractures involving the tibial plateau can cause management-related problems such as wound dehiscence; severe comminution leading to malalignment; and delayed complications such as varus collapse, implant failure, and arthritis of the knee joint. The treatment of severe or complex tibial plateau fractures can be quite difficult. Traditional methods of open reduction and plating require extensive exposures, which may further compromise soft tissue and devascularize bone fragments, leading to infection. In this case, a novel device, double reverse traction combined with MIPPO technique, was used and provided the possibility of minimally invasive and personalized orthopedic surgery to treat severe comminuted Schatzker type VI tibial plateau fracture and tibial shaft fracture and got satisfactory results.

**Patient concerns:** A previously healthy 56-year-old man presented to the emergency room after a fall from a height, who lost the movement of the left knee with pain and swelling.

**Diagnoses:** X-rays showed a tibial plateau comminuted fracture, Schatzker type VI, and tibial shaft fracture.

**Interventions:** Applying less extensile exposure and the indirect reduction technique of double reverse traction and closed reduction combined with minimally invasive percutaneous plate osteosynthesis (MIPPO) technique, we got satisfactory recovery of the severe comminuted Schatzker type VI tibial plateau fracture and tibial shaft fracture.

**Outcomes:** This severe comminuted fracture and tibial shaft fracture were successfully reduced and got satisfactory recovery of knee joint function.

**Lessons:** Double reverse traction combined with MIPPO technique can reduce the risk of surgical complications, such as bleeding, oozing, and wound infection. It can be applied in patients with comorbidities such as cardiac disease, hypertension, and heart failure who may otherwise not be candidates for surgery. The cost burden is lower than that of the traditional traction table.

**Abbreviations:** BO = biological osteosynthesis, LISS = less invasive stabilization system, MIPPO = minimally invasive percutaneous plate osteosynthesis.

**Keywords:** double reverse traction, Schatzker type VI, tibial plateau fracture

Editor: Johannes Mayr.

The authors report no funding and conflicts of interest.

Department of Orthopedics, The Second Xiangya Hospital of Central South University, Changsha, Hunan, People's Republic of China.

\* Correspondence: De-ye Song, Department of Orthopedics, The Second Xiangya Hospital of Central South University, Changsha, Hunan 410000, China (e-mail: songdeye@csu.edu.cn).

Copyright © 2017 the Author(s). Published by Wolters Kluwer Health, Inc. This is an open access article distributed under the terms of the Creative Commons Attribution-Non Commercial License 4.0 (CCBY-NC), where it is permissible to download, share, remix, transform, and buildup the work provided it is properly cited. The work cannot be used commercially without permission from the journal.

Medicine (2017) 96:45(e8394)

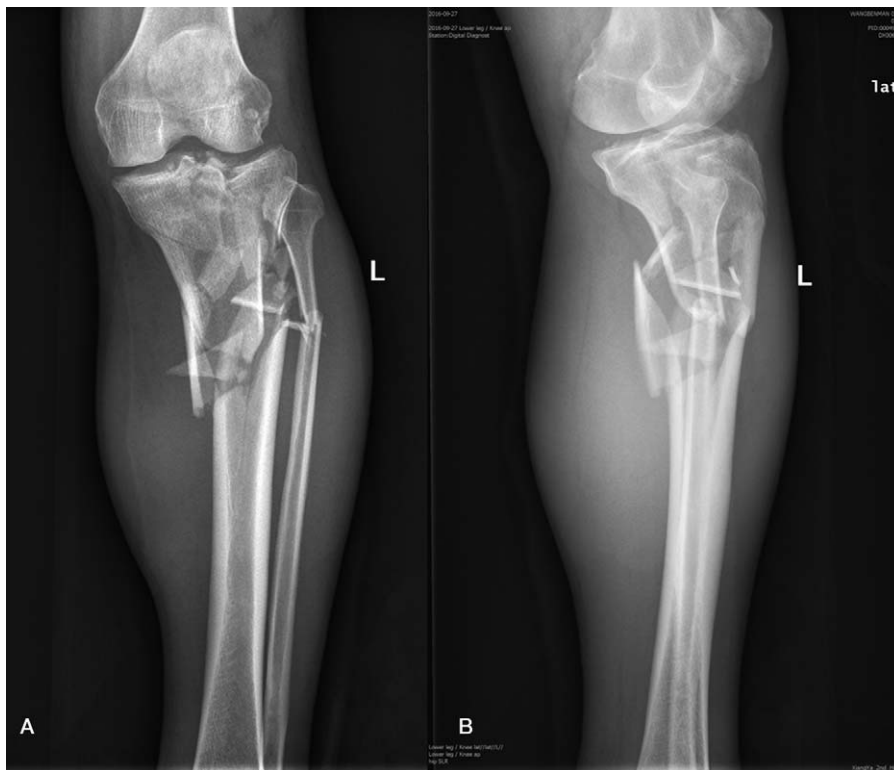Received: 19 December 2016 / Received in final form: 30 September 2017 /

Accepted: 3 October 2017

<http://dx.doi.org/10.1097/MD.00000000000008394>

## 1. Introduction

Tibial plateau fracture is a common intra-articular fracture, with an incidence of 10.3 per 100,000 annually, and occurs most often in individuals between the ages of 40 and 60 years. Tibial plateau fractures constitute approximately 1% of all bone fractures.<sup>[1]</sup> Because the knee joint is an important weight-bearing joint, tibial plateau fractures affect knee function and stability. High-energy intra-articular fractures involving the tibial plateau can cause management-related problems such as wound dehiscence; severe comminution leading to malalignment; and delayed complications such as varus collapse, implant failure, and arthritis of the knee joint.<sup>[2]</sup> The use of minimally invasive and personalized orthopedic surgery to treat severe comminuted Schatzker type VI tibial plateau fracture and tibial shaft fracture is therefore likely to increase.



**Figure 1.** Preoperative x-rays of the tibial plateau. (A) Frontal and (B) lateral views.

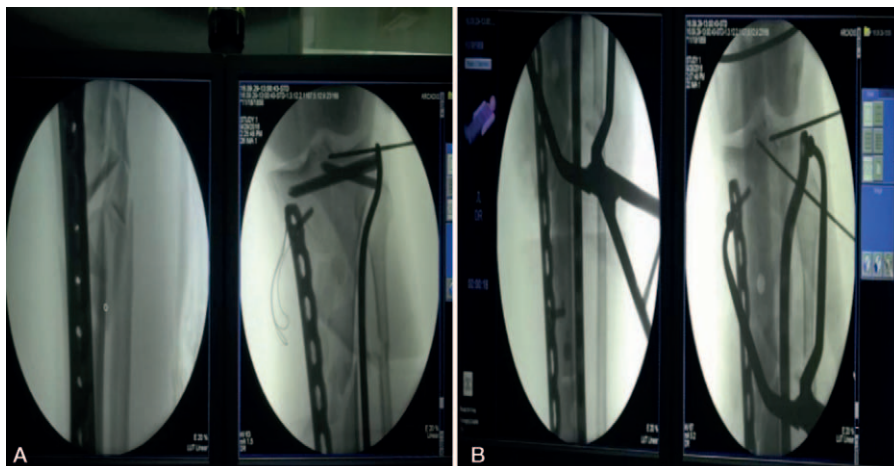## 2. Case report

A previously healthy 56-year-old man presented to the emergency room after a fall from a height. X-rays were obtained and showed a tibial plateau comminuted fracture, Schatzker type VI, and tibial shaft fracture (Fig. 1). The time from injury to operation was 8 days.

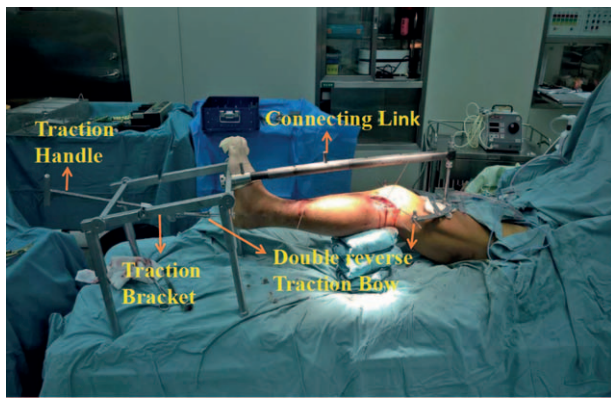
### 2.1. Operative technique

The patient was placed in the supine position and general anesthesia induced. The leg was cleansed with antibacterial solution from hip to groin and draped in the usual sterile fashion.

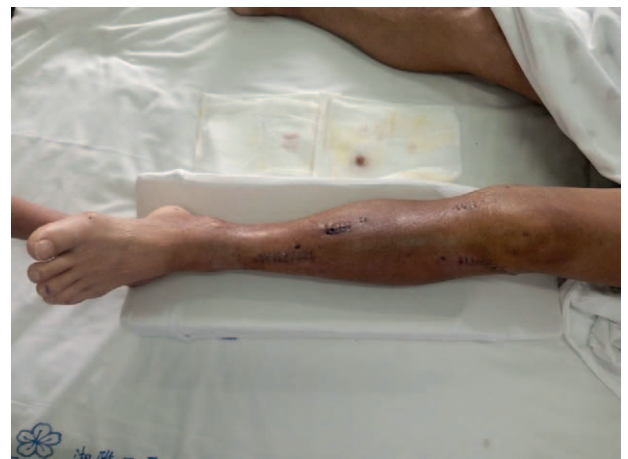First, double reverse traction was applied, with the proximal pin in the distal femur and the distal pin in the calcaneus. A 2- to 3-cm incision was then made over the proximal aspect of the tibia medially and laterally, in accordance with the location of the fracture site and the use of double plates. A submuscular plane was created, and the plate was slid into the anterior submuscular plane and fixed with screws, which were inserted percutaneously through the primary surgical incisions. By employing less extensile exposure and the indirect reduction technique of double reverse traction and closed reduction combined with minimally invasive percutaneous plate osteosynthesis (MIPPO) technique, this severe comminuted fracture and tibial shaft



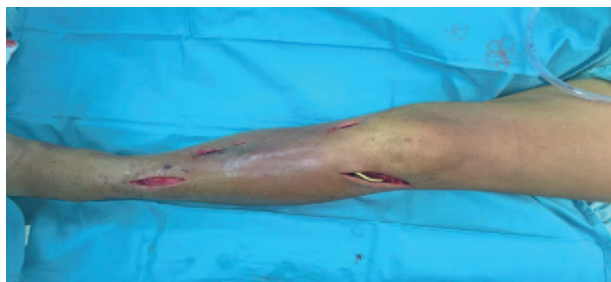
**Figure 2.** Intraoperative reduction (A) and radiologic information (B) of tibial plateau.



**Figure 3.** The complete photograph of double reverse traction.



**Figure 5.** Photograph taken 1 wk postoperatively showing the entire lower limbs.



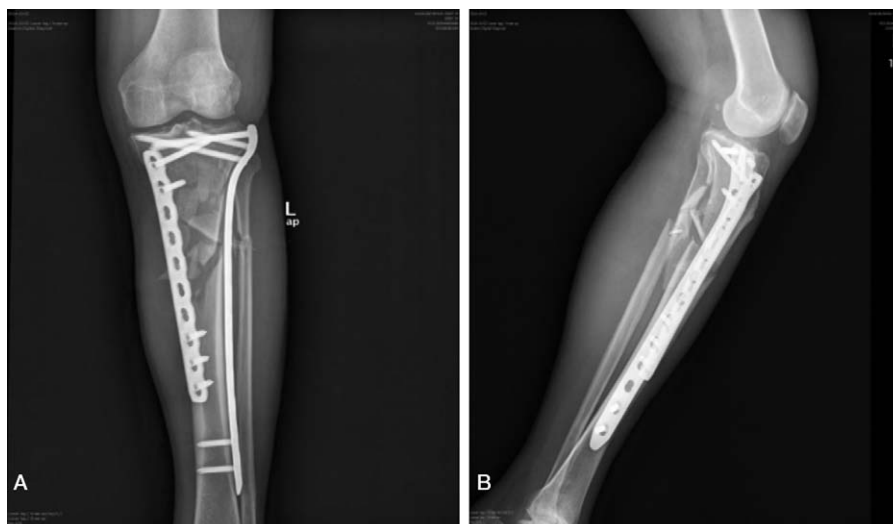**Figure 4.** Photograph showing the 2-cm incision on the medial side of the left knee joint and a 4-cm incision on the lateral side of the left knee joint, and the distal incision for drilling the locking plates.

fracture were successfully reduced (Figs. 2 and 3). The blood supply of the subcutaneous tissue anterior to the tibial plateau, which is beneficial to fracture healing, was spared (Fig. 4), and the operation lasted only 170 minutes.

### 2.2. Postoperative recovery

One week after surgery, there was no bleeding or oozing from the incisions and no sign of wound infection. Circulation, sensation, and movement of the left leg were satisfactory (Fig. 5). On x-ray, the knee joint plane and the alignment of the lower limb were satisfactory (Fig. 6).

An x-ray obtained 2 months postoperatively demonstrated the joint space and articular surface to be in satisfactory condition (Fig. 7). There was obvious absorption of some of the fracture fragments of the tibial plateau and blurring of the fracture lines (Fig. 8). Recovery of knee joint function was satisfactory. Range of motion of the knee joint was  $-5^{\circ}$  to  $120^{\circ}$ , and the Hospital for Special Surgery (HSS) Knee Score was 100 (pain, 30; function, 22; range of motion, 18; muscle strength, 10; flexion deformity, 10; and stability, 10) (Figs. 9 and 10).



**Figure 6.** X-rays of tibial plateau obtained 3 d after operation. (A) Frontal view and (B) lateral view.

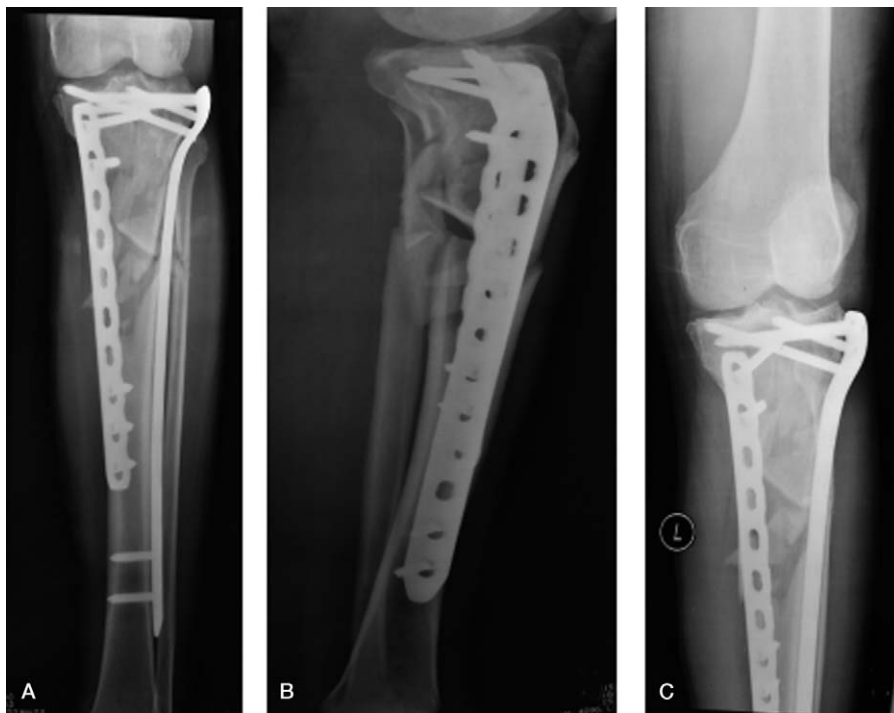

Figure 7. X-rays obtained 2 mo after operation. (A) Knee joint frontal view. Tibial plateau: (B) lateral view and (C) frontal view.

### 3. Discussion

The treatment of severe or complex tibial plateau fractures can be quite difficult. Traditional methods of open reduction and plating require extensive exposures, which may further compromise soft tissue and devascularize bone fragments, leading to infection. The double reverse traction technique employed in the present case can create 2 opposing directional forces, generated by 2 pins

drilled into the condyles of femur and calcaneus, respectively, to distract a displaced fracture. The technique has distinct advantages over traditional methods of distraction. For example, a traditional orthopedic distraction bed which is installed between the perineum and the distal extremity and creates skin traction, provides only unidirectional force to assist with fracture reduction. In most cases, skin traction and unidirectional force are not sufficient or effective for proper re-creation of angular and

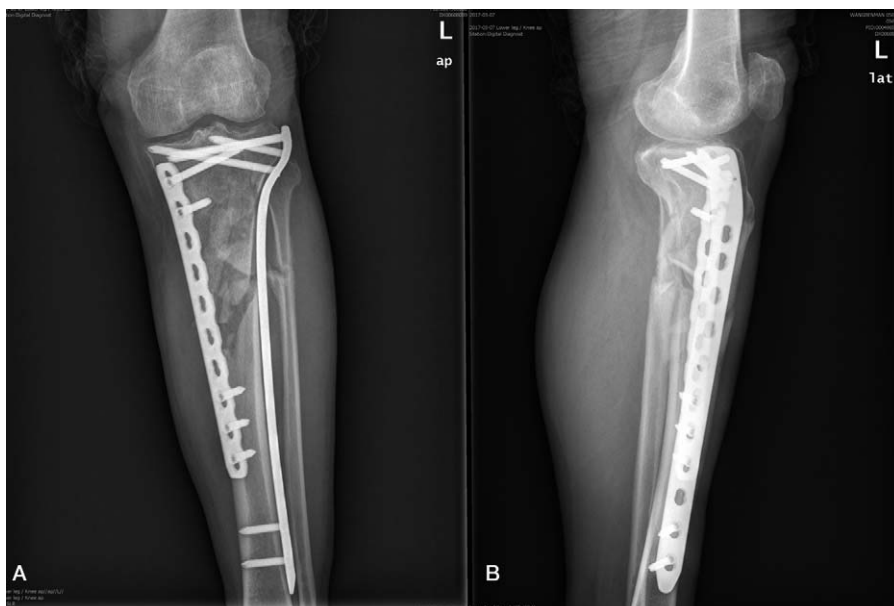
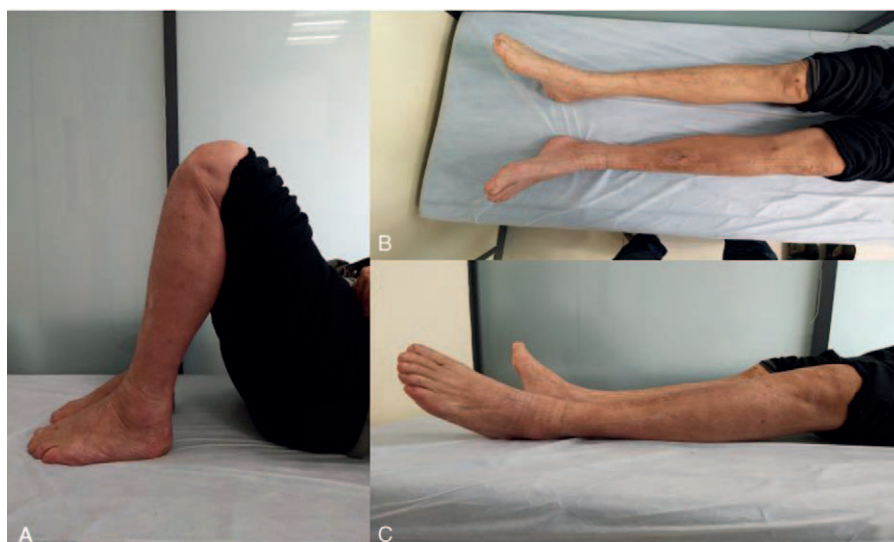
Figure 8. X-rays of tibial plateau obtained 6 mo after operation. (A) Frontal view and (B) lateral view.



**Figure 9.** Photograph of the knee joint in (A) flexed and (B, C) extended positions.

rotational displacements. Furthermore, because the injured limb cannot be moved easily, the surgical incision and approach are often limited.

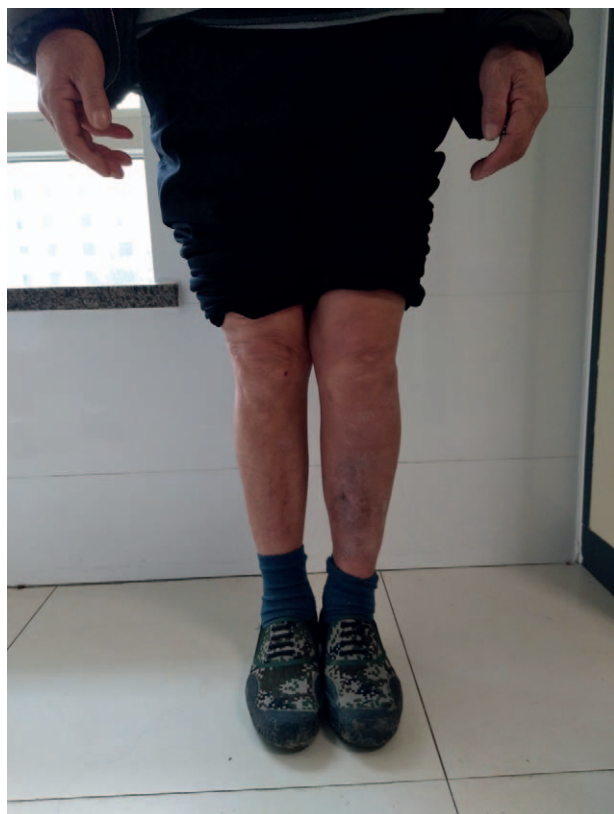With a femoral distractor, which is fixed with 2 pins in the proximal and distal fracture ends, surgeons can move the injured limb according to the requirements of the incision, approach, and reduction, but it is difficult to apply the femoral distractor in cases of rotational and angular displacements. Bones with physiological

curvature will be straightened by such traction, and installing the femoral distractor on 1 side will increase the amount of fracture dislocation. This kind of tractive method is applied mainly when the condition of the soft tissue is poor and/or when there is a severe fracture that cannot accept large incisions and direct reduction, such as metaphyseal, intra-articular, and severely comminuted fractures. By applying traction across a joint, ligaments and soft tissues around the fracture area can assist in achieving reduction (ligamentotaxis and soft-tissue taxis).<sup>[3]</sup>

In contrast, double reverse traction represents a method of true bone traction that is sustained, adjustable, and consistent with the alignment of limbs. In practice, it is difficult for surgeons to achieve a normal shape by indirect reduction, which requires evaluation of damaged tissue, the type of fracture, and the amount of muscular force. Double reverse traction can prevent further soft tissue damage around the fracture through indirect reduction and can facilitate treatment with a less invasive stabilization system (LISS).<sup>[4]</sup> It has important advantages in recreating angular and rotational displacements and makes disassembly for screw and plate fixation unnecessary. Adequate traction allows for the application of MIPPO technique.

Double reverse traction combined with MIPPO technique has a number of advantages. It facilitates restoration of upper- and lower-limb fractures—even those of amputees, who cannot undergo table traction. It can achieve minimally invasive restoration through the use of soft tissue compression around the knee and open reduction/internal fixation and MIPPO technique. This technique can be combined with negative-pressure wound sealing and early *fix-and-flap* efforts to reconstruct soft tissue defects. Reduction and fixation must involve cautious management and careful handling of soft tissue to minimize complications of this severe type of fracture. With these techniques, the incidence of soft tissue complications, infections, and nonunion has decreased.<sup>[5]</sup> MIPPO techniques conforming to biological osteosynthesis (BO) principles result in fewer stress-shielding effects.

Double reverse traction combined with MIPPO technique can reduce the risk of surgical complications, such as bleeding, oozing, and wound infection. It can be applied in patients with comorbidities such as cardiac disease, hypertension, and heart



**Figure 10.** Photograph of patient in standing position.

failure who may otherwise not be candidates for surgery. The cost burden is lower than that of the traditional traction table.

#### 4. Conclusion

Double reverse traction combined with MIPPO technique facilitated successful treatment of a severely comminuted Schatzker type VI tibial plateau fracture and tibial shaft fracture.

#### Acknowledgments

We thank Denise Di Salvo, MS, from Liwen Bianji, Edanz Group China ([www.liwenbianji.cn/ac](http://www.liwenbianji.cn/ac)), for editing the English text of a draft of this manuscript.

#### References

- [1] Elsoe R, Larsen P, Nielsen NP, et al. Population-based epidemiology of tibial plateau fractures. *Orthopedics* 2015;38:e780–6.
- [2] Rohra N, Suri HS, Gangrade K. Functional and radiological outcome of Schatzker type V and VI tibial plateau fracture treatment with dual plates with minimum 3 years follow-up: a prospective study. *J Clin Diagn Res* 2016;10:RC05–10.
- [3] Rüedi TP, Murphy WM. *AO Principles of Fracture Management*. 2nd expanded edn. AO Publishing; Georg Thieme Verlag, Davos; Stuttgart, New York: 2000.
- [4] Lee JA, Papadakis SA, Moon C, et al. Tibial plateau fractures treated with the less invasive stabilisation system. *Int Orthop* 2007;31:415–8.
- [5] Krettek C, Bachmann S. Pilon fractures. Part 2: Repositioning and stabilization technique and complication management. *Chirurg* 2015;86: 187–201.