



Surgical technique

Algorithmic soft tissue femoral release in anterior approach total hip arthroplasty

Morad Chughtai, MD, Linsen T. Samuel, MD, MBA, Alexander J. Acuña, BS, Atul F. Kamath, MD*

Department of Orthopaedic Surgery, Cleveland Clinic, Cleveland, OH, USA

ARTICLE INFO

Article history:

Received 7 July 2019

Received in revised form

13 October 2019

Accepted 20 October 2019

Available online 30 November 2019

Keywords:

Anterior approach

Soft tissue release

Total hip arthroplasty

Clinical outcomes

Femoral release

Component survivorship

ABSTRACT

Although the anterior approach for total hip arthroplasty has gained increasing utilization, some studies have suggested a higher risk of femoral complications, as well as difficulty with femoral exposure. Techniques of soft tissue releases have been described to offer better femoral exposure, and to help mitigate complications. The purpose of the study is to describe an algorithmic soft tissue femoral release in direct anterior approach total hip arthroplasty and to assess the clinical outcomes of patients upon which this algorithm of femoral soft tissue releases was utilized. Clinical outcomes with the Harris Hip Score, reoperation rates, component survivorship, and complications were analyzed.

© 2019 The Authors. Published by Elsevier Inc. on behalf of The American Association of Hip and Knee Surgeons. This is an open access article under the CC BY-NC-ND license (<http://creativecommons.org/licenses/by-nc-nd/4.0/>).

Introduction

The direct anterior approach (DA) to the hip has been increasing in use, despite the historical lower percentage of use worldwide in primary total hip arthroplasty (THA) [1]. The prior lower adoption rates may be due to a host of factors, including particular technical demands, use of specialized instruments, use of a specialized table with certain techniques, and the purported learning curve to perform safely [2]. Furthermore, it is accepted that femoral exposure is the most challenging aspect of the approach, and has been associated with complications in specific series [3]. Nevertheless, this technique has several advantages, including using an intermuscular and internervous plane, leading to earlier functional

recovery with less pain, as well as the potential for a reduced risk of dislocation [4–6].

Multiple techniques have been described utilizing the DA approach for THA [2,7–9]. In comparison to most previous techniques published, we utilized a reported stepwise or hierarchal approach to soft tissue releases in order to achieve adequate femoral exposure during DA THA. Furthermore, although there are numerous reports of outcomes utilizing DA THA in general, there are no reports specifically describing outcomes utilizing a specific algorithmic approach to the femoral soft tissue release aspect of the procedure. Therefore, the purpose of this study is to report on a novel THA technique that utilizes femoral soft tissue releases. Additionally, we aim to report outcomes and complications associated with this approach.

Surgical technique

Positioning and surgical exposure anatomy

All patients were positioned supine on a specialized orthopedic table (Hana; Mizuho OSI, Union City, CA), with both feet placed in boots attached to the associated table spars. The incision was marked out 2 cm lateral and distal to the anterior superior iliac spine and extended in line longitudinally with the fibers of the

One or more of the authors of this paper have disclosed potential or pertinent conflicts of interest, which may include receipt of payment, either direct or indirect, institutional support, or association with an entity in the biomedical field which may be perceived to have potential conflict of interest with this work. For full disclosure statements refer to <https://doi.org/10.1016/j.artd.2019.10.004>.

* Corresponding author. Center for Hip Preservation, Orthopaedic and Rheumatologic Institute, Cleveland Clinic, 9500 Euclid Avenue, Mailcode A41, Cleveland, OH 44195, USA. Tel.: +1 216 444 2606.

E-mail address: kamatha@ccf.org

<https://doi.org/10.1016/j.artd.2019.10.004>

2352-3441/© 2019 The Authors. Published by Elsevier Inc. on behalf of The American Association of Hip and Knee Surgeons. This is an open access article under the CC BY-NC-ND license (<http://creativecommons.org/licenses/by-nc-nd/4.0/>).

tensor fascia lata muscle (TFL). Dissection was performed down to the fascia overlying the TFL. The fascia was then incised and elevated off the TFL with careful attention to avoid injury to the lateral femoral cutaneous nerve. Once the intermuscular plane and femoral neck were identified, retractors were placed to expose the hip capsule. Using electrocautery dissection starting at the edge of the acetabulum, the capsule was incised in line with the femoral neck and then the femoral shaft dividing the capsule at a 135° angle. This inferior medial capsular flap was then tagged with suture, and the capsule was divided superiorly with another tag suture placed for the superior flap. This was considered a primary release, as this was the first sequence of steps performed to expose the femur. Specifically, dissection was taken down to the lesser trochanter inferomedially to begin the release of the pubofemoral ligament. Subsequently, femoral neck cuts were made, and the acetabulum was prepared.

Once the acetabulum is complete, attention was turned to the femur. A complete release of the pubofemoral ligament was then performed. Based on the senior author’s extensive clinical experience, release of the pubofemoral ligament should afford between 80° and 110° of femoral external rotation at the foot (likely this equates to approximately 60°-90° of pure femoral rotation as judged at the cut femoral neck during the eventual broaching phase). Release of the pubofemoral ligament initiates the eventual 270° capsulotomy. The posterior capsule was then subsequently released from the femur allowing for improved elevation of the femur. Incision of the posterior capsule at the level of the neck may generate an additional 5°-10° of femoral external rotation. The leg was then extended and adducted using the Hana table, to allow for femoral preparation (Figs. 1-4).

Primary releases

If at this point the canal exposure was not sufficiently exposed, a superior capsular release was performed for adequate femoral

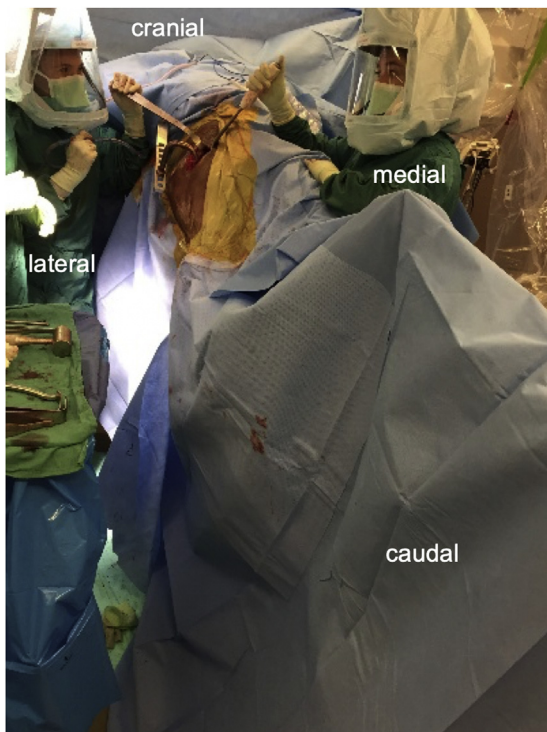


Figure 1. Intraoperative view demonstrating extension, adduction, and external rotation of a right hip for visualization and preparation of the proximal femur.

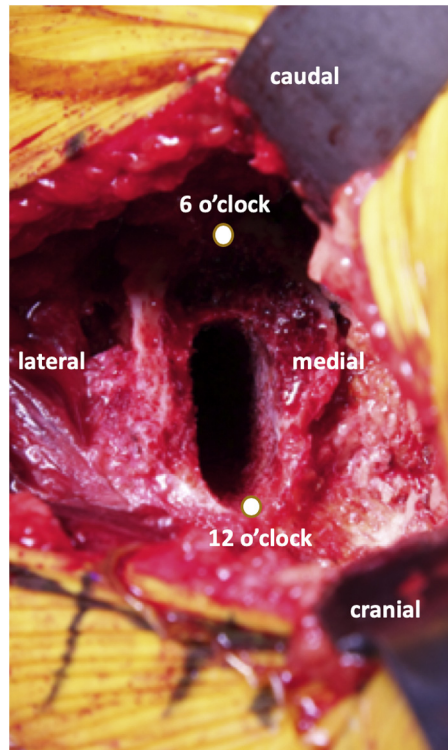


Figure 2. Intraoperative image of a right hip demonstrating exposure of the structures inserting on the greater trochanter of the femur. *12 o'clock position for initiation of superior capsular release.

canal exposure. Full release of the superior capsule should generate 1-2 cm of ventral translation, such that the mouth of the femur is 1-3 cm above the superior rim of the acetabulum (or acetabular prosthesis if a definitive cup has been placed). At this point, if exposure was insufficient, the surgeon carefully reassessed all the above-mentioned releases to ensure that they were as optimally performed as possible before proceeding with secondary releases. The leg was brought back up into the neutral position and retractors were replaced (termed “resetting” the femur) (Fig. 5a). Resetting the femur generally moves any obstructing soft tissues

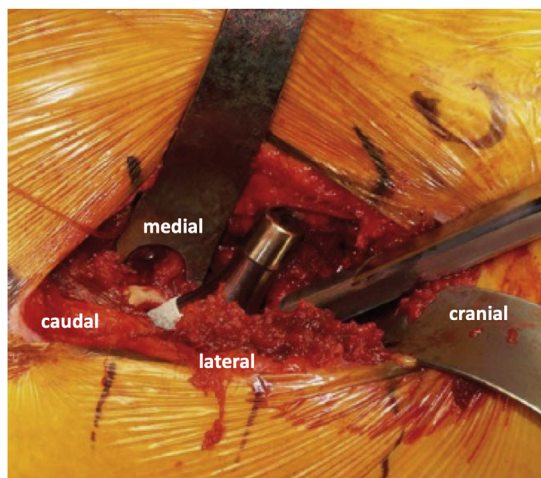


Figure 3. Intraoperative view of a left proximal femur, as viewed by the surgeon standing at the cranial end of the patient looking inferior and distal, demonstrating adequate femoral exposure for safe femoral broaching.

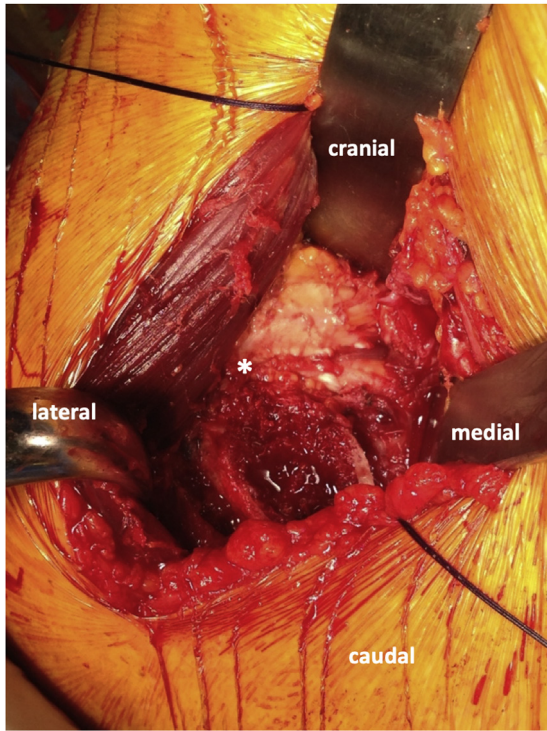


Figure 4. Intraoperative image of a left hip, demonstrating adequate femoral exposure for placement of the definitive femoral implant.

(such as residual capsular flaps or the intact piriformis and obturator externus tendons) posterior to the elevated femur, increasing the excursion (external rotation and ventral translation) of the

femoral mouth. This improved exposure is created without any further soft tissue release.

If this sequence still did not produce adequate exposure, the conjoint tendon was the next to be released, ensuring avoidance of inadvertent damage to the other greater trochanteric tendons and/or abductor musculature, as well as avoiding piriformis and obturator externus tendon releases (Fig. 5b). Release of the conjoint tendon should generate another 10°–15° of femoral external rotation, and 1–2 cm of ventral translation.

Secondary releases

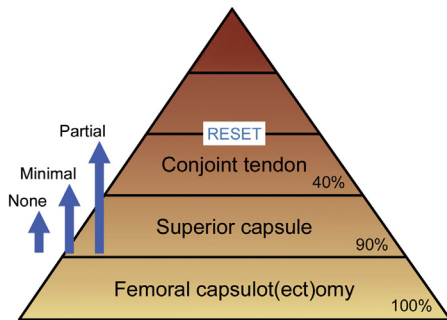
If the aforementioned releases had failed to afford adequate exposure, the piriformis would then be released. If conjoint tendon and piriformis release did not affect adequate exposure, then the obturator externus was released (Fig. 5b). These are considered secondary releases since they are additional steps that must be taken for femoral exposure. It should be noted that a “reset” of the femur should be performed before moving on to any secondary releases. An anatomic sequence of these releases is provided in Figure 6.

In general, adequate exposure (minimum of 90° of femoral external rotation and sufficient ventral translation to afford a straight femoral broaching trajectory) can be accomplished according to this hierarchy of primary and secondary femoral release. Titrated, incremental increases in femoral external rotation and ventral elevation are summarized in Table 1.

Stability testing

For the first 75 cases of the surgeon’s series, the operative leg within the traction boot was disengaged from the spar attachment, and a formal global (anterior and posterior) stability testing was

a Hierarchy of Releases (primary)



b Hierarchy of Releases (secondary)

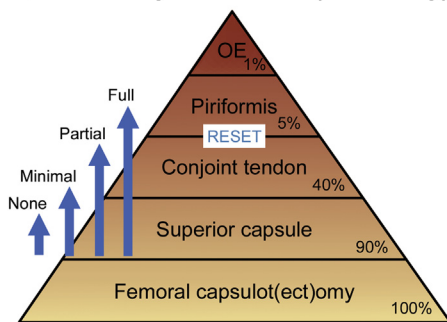


Figure 5. Hierarchy of (a) primary releases and (b) secondary releases. Minimal, partial, and full refer to the amount of release generated about the saddle of the greater trochanter.

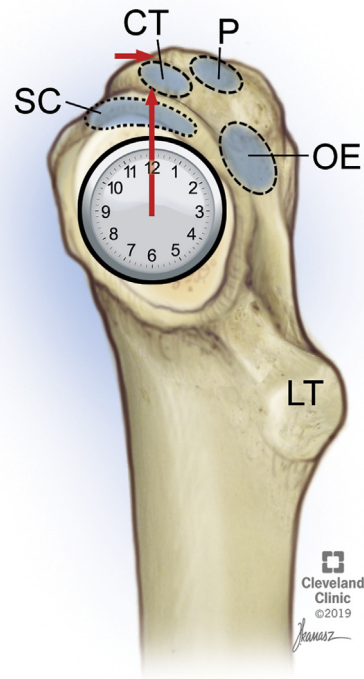


Figure 6. Clockwise release with reference to the right hip. SC, superior capsule; CT, conjoint tendon insertion; P, piriformis tendon insertion; OE, obturator externus tendon insertion; LT, lesser trochanter.

Table 1
Exposure generated by stepwise femoral soft tissue releases.

Structure released	Type of release	Femoral external rotation (°)	Ventral translation (cm)	Percentage of cases release utilized
Pubofemoral ligament	Primary	80-110	<1	100%
Posterior capsule (at the level of cut femoral neck)		5-10	<1	100%
Superior capsule	Secondary	5-10	1-2	90%
Conjoined tendon		10-15	1-2	40%
Piriformis		10-15	1-2	5%

performed. For the remaining cases, stability testing was performed with the boot attached to the leg spar, and the hip placed in 30° of extension and a minimum of 90° of external rotation to simulate anterior dislocation moment. Visual and tactile assessment of anterior instability was performed; moreover, the operating surgeon would place a finger along the posterior trochanter to assess for any pelvi-trochanteric impingement in the position of maximal external rotation and extension. No formal pure shuck testing was performed, although in all cases the surgeon had one hand about the femoral head and neck segment to aid the trial reduction maneuver and to gauge the ease of reduction.

Table positioning

The above technique was also performed using adjunctive of table maneuvers, such as ensuring at least 90° of femoral external rotation, adequate abduction and hip extension, and using Trendelenburg positioning as needed to further help with hip extension.

Revision and extensile maneuvers in total hip arthroplasty

In a revision setting, it is possible that the above-mentioned maneuvers may not provide adequate exposure. It is possible to perform a distal extension of the incision, or the extensile DA approach (Fig. 7). Neurovascular bundles running toward the vastus lateralis cross the surgical field when the DA is extended distally; therefore, it is important to take note of surgical landmarks that are easily identified that will allow for a safe distal extension.

Other extensile maneuvers proximally include release of the leading fibers of the TFL off the iliac crest, leaving a cuff of tendinous portion to repair. An iliac wing osteotomy is generally reserved for the revision setting; the osteotomy screw fixation sites can be predrilled prior to osteotomy, to ensure stable refixation.

Case series

The senior author is a dual-fellowship trained surgeon in adult hip and knee reconstruction and hip preservation. The senior author has utilized the proposed systematic algorithmic femoral soft tissue release technique for all his primary DA THAs. A fluoroscopic view was used for marking the neck cut resection level, for position of the final acetabular reamer, and during the final trialing phase.

This study is institutional review board approved. A database query was performed of a prospectively maintained database (2014–2017) which contained information on patient demographics, indication for surgery, Harris Hip Scores (HHS), radiographic findings, components utilized, and any complications. All patients underwent a standardized radiographic assessment: anteroposterior pelvis view, as well as an anteroposterior and cross-table of the operative hip at 6 weeks, 1 year, 2 years, and 5 years. This yielded 1059 cases of DA THA. Patients were excluded if (1) they had undergone hemi-arthroplasty for femoral neck

fracture ($n = 23$) or (2) they were part of an industry-funded prospective clinical trial of a new stem design ($n = 36$). This resulted in a total of 1000 patients who underwent a primary THA utilizing the DA approach. Specific soft tissue releases performed are depicted in Table 1. There was a minimum follow-up of 2 years (range 2–5).

The cohort had a mean age of 65 years (range 22–89), 48% were males, and had a mean body mass index of 34 (range 22–52). The most common indication for surgery was osteoarthritis (85%) (Table 2). The mean preoperative HHS was 56 (range 34–78).

All variables were assessed utilizing descriptive statistics. For categorical variables, we assessed rates and frequencies. For continuous variables, we calculated means and ranges. Kaplan-Meier analysis was used to assess component survivorship. For descriptive statistics, we utilized Microsoft Excel (Microsoft Corp, Redmond, WA), and for Kaplan-Meier analysis we used SPSS software (IBM Corp, Armonk, NY).

All patients received a Pinnacle acetabular cup (DePuy Synthes Holding AG, West Chester, PA), except 2 patients with a prior history of rigid spinal fusion, who received dual mobility cups (Stryker, Mahwah, NJ). A 28-mm head was used for cups up to 50 mm. A 32-mm head was used for cups ≥ 52 mm. A 36-mm head was used for cups ≥ 58 mm. All heads were ceramic, including the inner ball

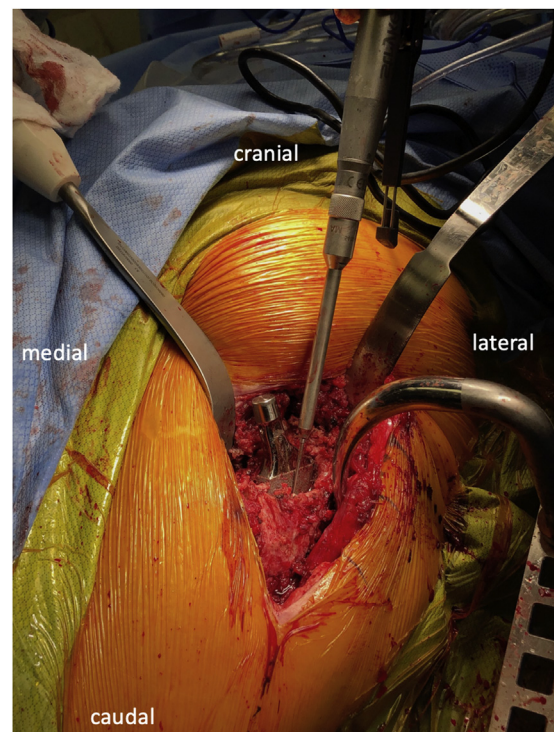


Figure 7. Intraoperative image in the revision hip arthroplasty setting. Adequate femoral release of this left hip is performed for safe extraction of the femoral component.

Table 2
Patient demographic characteristics.

Patient demographics/risk factors	N (%)
Total patient numbers	1000 (100)
Age (y), mean (range)	65 (22-89)
Body mass index, mean (range)	34 (20-52)
Gender	
Male	484 (48)
Female	516 (52)
Preoperative diagnosis/surgical indication	
Osteoarthritis	847 (85)
Post-traumatic arthritis	49 (5)
Rheumatoid arthritis	54 (5)
Osteonecrosis	43 (4)
Systemic lupus erythematosus	7 (1)
Preoperative Harris Hip Score, mean (range)	56 (34-78)

head for the 2 dual mobility bearings. For femoral stems implanted, 93% of patients received a cementless Corail stem (DePuy Synthes Holding AG) with a collar, 3% received a Tri-Lock stem (DePuy Synthes Holding AG), and 2% received an S-ROM stem (DePuy Synthes Holding AG). Two percent of the femurs were cemented with a Summit stem (DePuy Synthes Holding AG).

Mean HHS improved from mean 56 preoperatively (range 34-78) to mean 88 postoperatively (range 65-100) ($P < .01$). There were no component revisions (100% survivorship of cup and stem implants).

Three patients experienced complications postoperatively. They included superficial wound secondary closure ($n = 1$), calcar fracture ($n = 1$), and anterior hip dislocation ($n = 1$). All patients were managed appropriately without further complication. There were no cases of radiographic component loosening, deep infection or prosthetic joint infection, and no deaths (Table 3, Fig. 8).

Postoperatively, 68% of patients were discharged home/home health services, 18% to skilled nursing facility, and 14% to an inpatient rehabilitation facility

Discussion

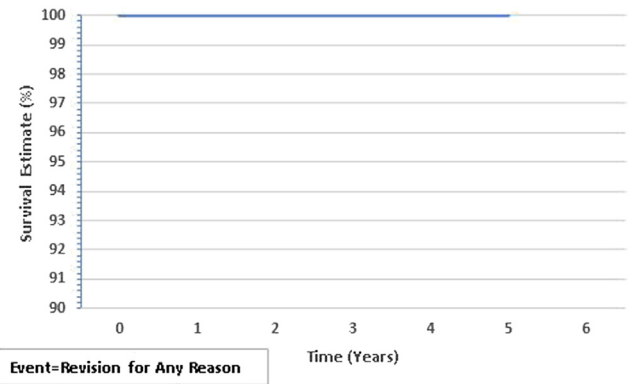
In the present report, we assessed clinical outcomes, reoperation rates, component survivorship, and complications in a consecutive series of patients who underwent AA THA using this stepwise technique. We found that this technique offered good outcomes, minimal complications rates, and excellent component survivorship at a minimum follow-up of 2 years.

In a retrospective study, Meneghini et al. [3] performed an analysis of 342 early failure THAs, and found early femoral failure to be significantly associated with utilizing a DA, as compared to a direct lateral and/or posterior approach. However, the exact

Table 3
Postoperative Complications and Outcome scores.

Complications	N (%)
Total complications	3 (0.3)
Superficial wound dehiscence	1 (0.1)
Dislocation	1 (0.1)
Calcar fracture	1 (0.1)
Aseptic loosening	0 (0)
Prosthetic joint or deep infection	0 (0)
Outcomes	Mean (range)
Postoperative Harris Hip Score	88 (65-100) ^a

^a Significant improvement from preoperative Harris Hip Score ($P < .01$).

**Figure 8.** Kaplan-Meier all-component survivorship curve demonstrating no component loosening.

experience with the DA approach performed by the surgeons is unclear, along with the total number of exposure cases (denominator). Also, it is likely that the index DA cases were not performed with a uniform technique. This was made evident by literature review by Connolly and Kamath [2] which demonstrated significant variations and surgical technique using DA THA. Of note, the authors highlighted that there was significant variation in the use of intraoperative fluoroscopy as well as surgical tables. Given these findings, it is possible that the various adverse outcomes associated with the DA approach could be related to the varying techniques and methods utilized among surgeons. Therefore, a more standardized, stepwise technique may reduce the frequency of these complications. The present study begins to demonstrate this idea given that there were no early failures of the femoral component.

Summary

The present study evaluated the clinical outcomes of patients who underwent DA THA utilizing a specific algorithmic technique for femoral soft tissue release and exposure. Good outcomes and acceptable rate of complications were demonstrated in this specific cohort, possibly due to the specific technique utilized. However, we caution that this study was performed by a single surgeon with extensive experience in the DA technique. Therefore, further studies are warranted to assess whether these results and techniques can be implemented and utilized by other surgeons to achieve similar outcomes. Additionally, the quantification of the effect of each step of the femoral release may be desired to understand the influence of particular femoral releases.

References

- [1] Chechik O, Khashan M, Lador R, Salai M, Amar E. Surgical approach and prosthesis fixation in hip arthroplasty world wide. *Arch Orthop Trauma Surg* 2013;133(11):1595.
- [2] Connolly KP, Kamath AF. Direct anterior total hip arthroplasty: comparative outcomes and contemporary results. *World J Orthop* 2016;7(2):94.
- [3] Meneghini RM, Elston AS, Chen AF, Kheir MM, Fehring TK, Springer BD. Direct anterior approach: risk factor for early femoral failure of cementless total hip arthroplasty: a multicenter study. *J Bone Joint Surg Am* 2017;99(2):99.
- [4] Miller LE, Kamath AF, Boettner F, Bhattacharyya SK. In-hospital outcomes with anterior versus posterior approaches in total hip arthroplasty: meta-analysis of randomized controlled trials. *J Pain Res* 2018;11:1327.
- [5] Miller LE, Gondusky JS, Kamath AF, Boettner F, Wright J, Bhattacharyya S. Influence of surgical approach on complication risk in primary total hip arthroplasty. *Acta Orthop* 2018;89(3):289.

- [6] Miller LE, Gondusky JS, Bhattacharyya S, Kamath AF, Boettner F, Wright J. Does surgical approach affect outcomes in total hip arthroplasty through 90 days of follow-up? A systematic review with meta-analysis. *J Arthroplasty* 2018;33(4):1296.
- [7] Nam D, Sculco PK, Abdel MP, Alexiades MM, Figgie MP, Mayman DJ. Leg-length inequalities following THA based on surgical technique. *Orthopedics* 2013;36(4):e395.
- [8] Wayne N, Stoewe R. Primary total hip arthroplasty: a comparison of the lateral Hardinge approach to an anterior mini-invasive approach. *Orthop Rev (Pavia)* 2009;1(2):e27.
- [9] Rudin D, Manestar M, Ullrich O, Erhardt J, Grob K. The anatomical course of the lateral femoral cutaneous nerve with special attention to the anterior approach to the hip joint. *J Bone Joint Surg Am* 2016;98(7):561.