

# Four-corner arthrodesis of the wrist using Variable Angle Locking Compression Intercarpal Fusion Plate (VA LCP ICF Plate; Synthes®): pre- and postoperative radiological analysis and clinical outcome in long-term evaluation

## Mediokarpale Teilarthrodese des Handgelenkes mit der Variable Angle Locking Compression Intercarpal Fusion Plate (VA LCP ICF Plate, Firma Synthes®): Prä- und postoperative radiologische Analyse und klinische Langzeitergebnisse

### Abstract

Long persisting scaphoid non-unions or scapholunate ligament ruptures can lead to carpal collapse.

The resulting clinical symptoms are restrictions in the range of motion, pain, and loss of grip strength. The symptomatic treatment so far offers different options. In our study, the Variable Angle Locking Compression Intercarpal Fusion Plate (VA LCP ICF Plate) by Synthes® was used in 11 cases of advanced carpal collapse for a four-corner fusion of the wrist. The intra- and postoperative as well as follow-up results have been assessed and compared with those of current literature.

The results of the Manchester-Modified Disability of the Shoulder, Arm and Hand Score (M<sup>2</sup>-Dash) showed an average of 41.5 points (MD=44/SD=16.62/MIN=21/MAX=65).

One of the re-evaluated patients complained about pain at rest. One patient stated pain after mild strain; 4 patients complained pain after heavy burden (e.g. boxing, weight lifting).

Measuring the range of motion, the operated hand showed a maximum in dorsal extension of 78.31% and in flexion of 57.89% compared to the contralateral, non-operated hand. In performance testing the fist clenching sign as well as pinch grip were complete and void of pain in 100%, whereas opposition (dig. man. I to V) was complete in five patients (83.33%), with moderate pain in one patient (16.67%) and a persisting gap of 0.2 cm in n=1 (16.67%). In comparison with the current literature regarding healing rates, complications, and follow-up results, we recommend the Synthes® VA LCP ICF Plate as a good surgical option in patients suffering from advanced carpal collapse.

**Keywords:** wrist fusion, SNAC wrist, SLAC wrist, intercarpal arthrodesis

### Zusammenfassung

Lang bestehende Skaphoidpseudarthrosen oder skapholunäre Bandrupturen können zu einem karpalen Kollaps führen. Symptome dessen sind unter anderem Bewegungseinschränkung, belastungsabhängige Schmerzen und Kraftreduktion. In der aktuellen Literatur sind diverse unterschiedliche Prozeduren und therapeutische Optionen für dieses Krankheitsbild beschrieben. In der vorliegenden Studie werden das intraoperative Handling und die postoperativen klinischen und radiologischen Ergebnisse der Variable Angle Locking Compression Intercarpal Fusion Plate (VA LCP ICF Plate, Firma Synthes®) für die mediokarpale Teilarthrodese (four-corner fusion) mit den Ergebnissen anderer Verfah-

**Christian Eder<sup>1</sup>**

**Ariane Scheller<sup>1</sup>**

**Nina Schwab<sup>2</sup>**

**Björn Dirk Krapohl<sup>3</sup>**

1 Centre for Musculoskeletal Surgery, Charité – Medical University, Campus Virchow Clinic, Berlin, Germany

2 Healthcare Center Meviva, Berlin, Germany

3 Carl-Thiem-Klinikum, Cottbus, Germany

ren und Implantate der aktuellen Literatur verglichen. Das Implantat wurde bei 11 Patienten verwendet; die Nachuntersuchung ergab folgende Ergebnisse: Manchester-Modified Disability of the Shoulder, Arm and Hand-Score (M<sup>2</sup>-DASH) mit einem Durchschnittswert von 41,5 Punkten (MD=44/SD=16,62/MIN=21/MAX=65). Ein Patient klagte über Ruheschmerz, ein weiterer Patient über Schmerz nach leichter Beanspruchung der Hand, wohingegen vier Patienten Schmerzen nach stärkerer Belastung (beispielsweise Boxen, Gewichtheben) beklagten. Die Bewegungsprüfung zeigte folgende Resultate: Dorsalextension mit einem Durchschnittswert von 78,31% und Palmarflexion mit einem Durchschnittswert von 57,89% (jeweils der operierten Hand im Vergleich mit der nicht verletzten Hand). Der Faustschluss war bei allen Patienten unbeeinträchtigt, die Kleinfinger-Daumen-Oppositionsprobe ließ sich bei 83,33% der Patienten unbeeinträchtigt feststellen. Ein Patient beklagte bei Letzterem das Auftreten von Schmerzen, bei einem weiteren zeigte sich eine persistente Distanz von 0,2 cm (je 16,67%). Im Vergleich mit der aktuellen Fachliteratur bezüglich Heilungsraten, Komplikationen und Nachuntersuchungsergebnissen kann die VA LCP ICF Platte als gute Option der mediokarpalen Teilarthrodese empfohlen werden.

**Schlüsselwörter:** karpaler Kollaps, Implantate, Langzeitergebnisse

## Introduction

Persisting scaphoid non-unions and scapholunate ligament ruptures are the main causes for developing an insufficiency in carpal joint structure (carpal collapse, named as scaphoid nonunion advanced collapse = SNAC wrist or scapholunate dissociation advanced collapse = SLAC wrist respectively) [1], [2], [3], [4], [5], [6], [7], [8], [9], [10], [11], [12], [13], [14], [15], [16]. Watson and Ryu classified the severity of degenerative changes into three stages as shown in Table 1 [17].

**Table 1: Stages of advanced carpal collapse according to x-ray related visible arthrosis according to Watson and Ryu [17]**

Stage of carpal collapse	Localisation of arthrosis
I	radial styloid only
II	radioscaphoidal additionally
III	mediocarpal additionally

The specific therapeutic surgical options rely on this classification, displaying the here shown possibilities:

- stage I: scaphoid reconstruction and osteosynthesis (for SNAC) or scapholunate ligament refixation (for SLAC), both combined with resection of the radial styloid (styloidectomy)
- stage II: proximal row carpectomy (PCR) or midcarpal arthrodesis (e.g. three- or four-corner fusion)
- stage III: midcarpal arthrodesis including excision of scaphoid bone (with or without bone graft)

Simplified grouping of operative approaches in stage II and stage III carpal collapse leading to specific study topic (Figure 1).

The four-corner fusion, primarily described by Watson and Ryu, is one of the most popular and common procedures for treating stage II or stage III carpal collapse [17].

However, there is disagreement concerning the best osteosynthesis material for this surgery [3], [16], [18], [19], [20], [21], [22], [23], [24], [25], [26]. While traditionally Kirschner wires, staples or compression screws have been used, in 1999 circular plates were introduced, promising better results [27]. Nowadays, many different plate designs are available on the market, but long-term results are currently scarce.

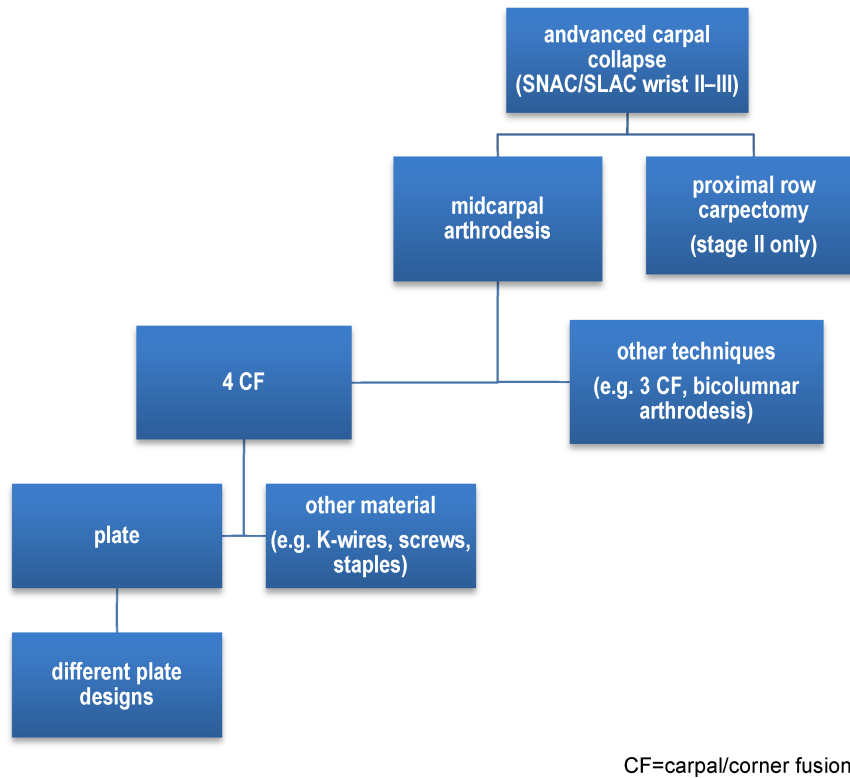
Therefore, the purpose of this study is to evaluate the long-term clinical outcome after four-corner arthrodesis of the wrist using the Variable Angle Locking Compression Intercarpal Fusion Plate by Synthes®.

## Material and methods

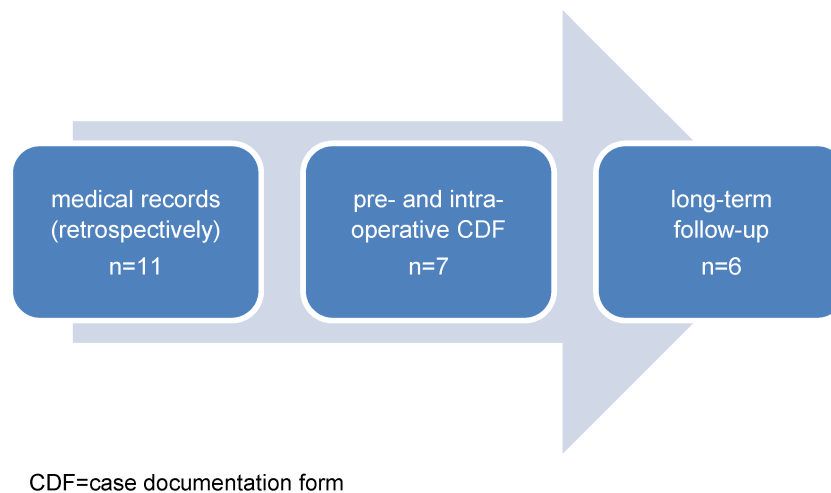
Between 2011 and 2013, 11 patients underwent surgical treatment including implantation of a Variable Angle Locking Compression Intercarpal Fusion Plate (Synthes®) in the Centre for Musculoskeletal Surgery of the Charité, Medical University of Berlin. All patients were explored clinically and radiologically (either X-ray or additionally computertomographic or magnetic resonance imaging if medically advised) for diagnosis and preoperative planning.

To present convincing data, the patients included in the study were interviewed and examined during different steps of the diagnostic and therapeutic process as shown in Figure 2.

Retrospectively, patients' medical records have been reviewed. Therefore, age and gender, previous medical history, trauma history, operation technique (approaches, operation time, complications), pre- and postoperative radiological images, outcome up to three months after the surgery, and fit of the implant were analyzed and summarized under short-term evaluation of the explained modified treatment.



**Figure 1: Short algorithm for treatment options of advanced carpal collapse (stages two and three)** [1], [3], [4], [9], [10], [11], [13], [14], [15], [16], [18], [19], [20], [21], [22], [23], [24], [25], [26], [27], [31], [32], [33], [34], [35], [42], [43], [45], [46], [47], [50]



**Figure 2: Data collection during patients' clinical process**

Additionally, 7 patients agreed in ascertaining data in form of a pre- and intraoperative case documentation (case documentation form 1, CDF 1).

This CDF 1 was presented by Synthes® and was used in the regular treatment of the individual in-patient's stay to get a detailed view on specific interests (such as carpal height pre- and postoperatively). In this study, the data have been assessed and compared retrospectively.

Final and core part of this study is long-term evaluation. Patients under 18 years and those who were unable to give informed consent were excluded according to guidance of the local ethics committee. Due to this constraint

and patient's non-response, in conclusion, a total number of 6 patients were re-evaluated. This long-term evaluation consisted of obtaining a general health questionnaire (therefore a shortened SF-36 was chosen) [28] and the Manchester-Modified Disability of the Arm, Shoulder and Hand-Score [29]. Based on a standardized protocol including range of motion, sensory deficiencies, pain, and strength, all patients underwent a clinical examination by a single surgeon. Grip strength was evaluated by using the hand-held dynamometer (JAMAR®) [30].

Generating radiological images in long-term evaluation was relinquished – due to no or just moderate clinical

conspicuousness; the radiation exposure would not have been ethically and medically justifiable.

All descriptive statistics for our approximately normally distributed data were performed using average/mean (MD), standard deviation (SD), minimum (MIN) and maximum (MAX) and percentage. SPSS v24.0 (SPSS Inc., Chicago, Illinois) has been used to create statistics.

Based on the Medline database a literature research provided the data for comparing the findings of this study with those of other working groups.

The study protocol was approved by the local ethic boards. Written consent was obtained from all patients.

## Results

### Patients' data

Eleven patients underwent implantation of Synthes' Variable Angle Locking-Compression Intercarpal Fusion Plate (VA LCP ICF Plate). 6 of them (54.55%) were male, whereas 5 patients were female gender (45.45%). The average age was 53.27 years (MD=45/SD=16.38) with a maximum of 74 and a minimum of 25 years.

Indications for implantation of VA LCP ICF Plate (total number: n=11) were:

- scapholunate advanced collapse (SLAC) n=4
  - stage II (1 case)
  - stage III (3 cases)
- scaphoid nonunion advanced collapse (SNAC) n=5
  - stage II (3 cases)
  - stage III (2 cases)
- de Quervain fracture with instability, initial treatment in a different hospital (1 case)
- carpal instability non-dissociative (CIND) caused by avascular necrosis of the lunate (Kienböck's disease) stage IIIa (1 case)

All of these 11 patients underwent standard operation procedure for a four-corner arthrodesis, always performed by the leader of the clinic's department for hand surgery. 6 of these patients (54.55%) got a six hole VA LCP ICF Plate; due to a better fit, assessed during the operation, 5 patients were treated with a seven hole variant of the Synthes® plate. Additionally, 10 patients got their scaphoid bone excised. In these cases, cancellous bone of the scaphoid was extracted and reimplanted. Therefore, no further spongiosa plasty from the iliac crest was necessary.

The scaphoid bone remained in situ in one case (carpal instability after avascular necrosis of the lunate) and hence an autologous bone graft transfer from the iliac crest was performed to achieve a satisfactory implant fit and to improve further healing rates.

Following our experiences and recommendation of current literature, immobilization (forearm cast with thumb spica) for 4 to 6 weeks was implemented in postoperative care [20].

For long-term re-evaluation two patients were lost in follow-up and three patients did not want to participate. In conclusion, six patients were clinically re-examined with a mean follow-up of 37.67 months (MD=35.5/SD=7.69/MIN=30/MAX=49). The group of patients, who underwent long-term clinical examination showed the following characteristics:

- 50% male and 50% female patients
- average age of 57.83 years
- comorbidities: 1 patient suffering from nerve lesion of the upper extremity after trauma, 1 patient with total shoulder-replacement and depressive disorder

### Short-term evaluation

Concerning the short-term evaluation, data of 11 patients were analyzed. Post-operative immobilization time of 4 to 6 weeks was conducted. The decision was based on intraoperative stability of the arthrodesis and patient's compliance in participating in postoperative treatment. After about three months after finishing physiotherapy all patients presented with incipient bone healing and good siting of the implant based on the last x-ray images (or CT if plain radiograph findings were suspicious). Except of one case where there was a broken screw, there were no further complications. The screw breakage may be related to the patient's in compliance in postoperative treatment (no immobilization was tolerated since he did weight lifting shortly after surgery).

### CDF 1

Seven patients agreed in taking further pre- and intraoperative data in this standardized form ("Pre- and intraoperative Case Documentation Form" by Synthes®).

The main goal of this form was to generate more detailed information about the specific radiographic characteristics for each patient individually:

- dorsiflexion deformity of the lunate
- carpal height (Youm)
- ulnar wrist translation (Chamay)

Furthermore, it was designed to explore the surgeons experience regarding the implant during the procedure. We evaluated the subitems concerning the special Synthes® reaming guide for the VA LCP ICF Plate "fit", "handling" and "holding strength" with good. Furthermore, the "ease of reaming", "reaming depth", "plate placement" and "assessment of quality of reduction" were considered good on a scale reaching from excellent to poor (excellent – good – satisfactory – poor). The "assessment of final stability" resulted in four excellent intraoperative findings and three good ones. Just the "ease of drilling VA-locking screws through reaming guide" was judged in 3 cases with satisfactory only. Caution is advised to prevent screw breakages intraoperatively.

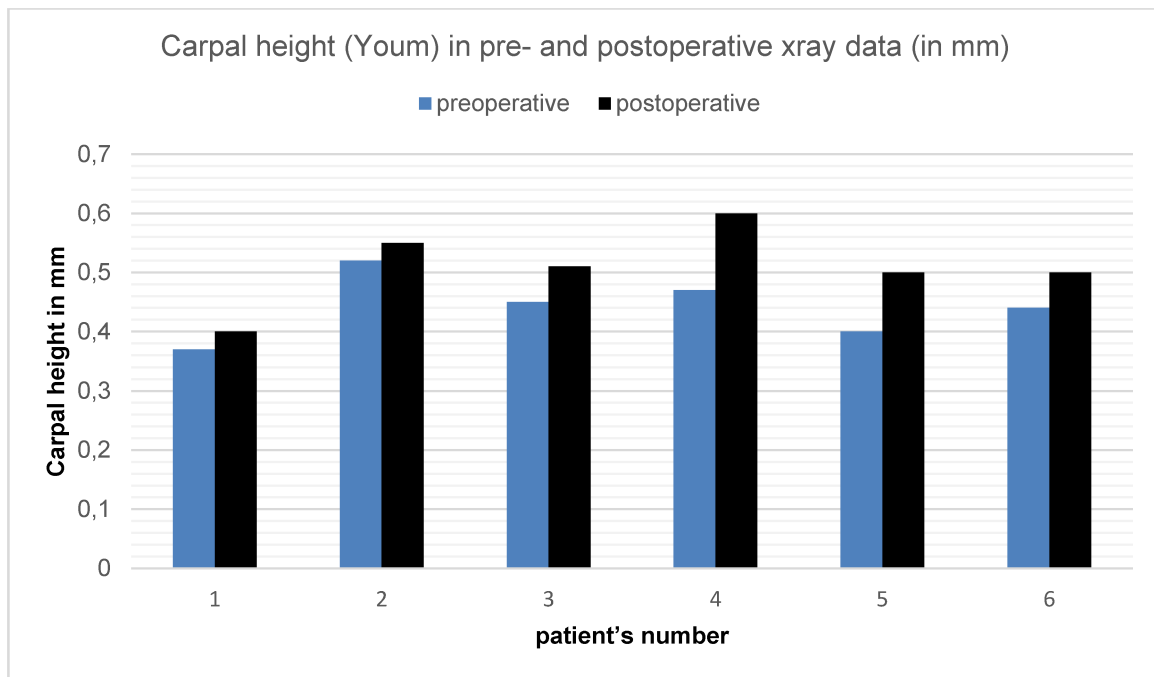


Figure 3: Carpal height (Youm) measured in pre- and postoperative x-ray data of six long-term follow-up patients

### Preoperative x-ray evaluation

One patient brought pre-operative x-ray images from an external hospital; due to technical incompatibility the preoperative radiographic analysis could not have been done properly; therefore, we included just 6 patients.

The dorsiflexion of the wrist in x-ray analysis intraoperatively imposed with an average of  $42.83^\circ$  (MD=46/SD=15.37/MIN=20/MAX=60).

Measuring the Carpal height (Youm) shows an average of 0.44 cm (MD=0.45/SD=0.05/MIN=0.37/MAX = 0.52) (Figure 3).

The average of the ulnar translation of the wrist [position of the lunate] (Chamay) is 0.30 cm (MD=0.31/SD=0.04/MIN=0.23/MAX=0.34).

### Postoperative x-ray evaluation

The comparison of pre- and postoperative carpal height (Youm) is shown in Figure 3.

### Long-term evaluation

Six patients were included. In four patients (66.67%) the carpal collapse affected the dominant hand (right hand always) and in 2 cases (33.33%) the non-dominant hand (left hand always).

The results in the shortened SF-36 general health survey (self-reporting health status for the last four weeks) showed no significant restrictions. Asking for the general health status (independent from age and further comorbidities) in self-estimation two patients answered "good", four said "satisfying". No further significant results could be found in analyzing the SF-36.

The outcome of the Manchester-Modified Disability of the Shoulder, Arm and Hand-Score (M<sup>2</sup>-Dash) is an average of 41.5 points (MD=44/SD=16.62/MIN=21/MAX=65).

One of the re-evaluated patients complained about pain at rest. One patient stated pain after mild strain; 4 patients mentioned pain after heavy burden (e.g. boxing, weight lifting).

Furthermore, three patients noticed dysaesthesia especially in digiti manus IV and V dorsal. In one case, dysaesthesia was already known before surgery.

In exploring the range of motion of the operated hand, the following results can be presented:

- dorsal extension: average  $54.17^\circ$  (MD= $52.5^\circ$ /SD= $19.08^\circ$ /MIN= $30^\circ$ /MAX= $80^\circ$ )
- flexion: average  $45.83^\circ$  (MD= $47.5^\circ$ /SD= $23.54^\circ$ /MIN= $5^\circ$ /MAX= $75^\circ$ )
- ulnar abduction: average  $26.67^\circ$  (MD= $30^\circ$ /SD= $14.02^\circ$ /MIN= $10^\circ$ /MAX= $40^\circ$ )
- radial abduction: average  $24.17^\circ$  (MD= $27.5^\circ$ /SD= $8.01^\circ$ /MIN= $10^\circ$ /MAX= $30^\circ$ )

The differences in mobility of the wrist between the operated and the other hand are shown here (percentage ROM of operated hand compared to non-operated hand):

- dorsal extension: 78.31% of non-operated hand
- flexion: 57.89% of non-operated hand

Additionally, a performance test was conducted:

- fist clenching: complete without pain in 100%
- pinch grip: complete without pain in 100%
- thumb opposition: complete in n=5 (83.33%), moderate pain n=1 (16.67%), persisting gap of 0.2 cm in n=1 (16.67%)

Grip strength evaluation was performed by using the hand-held dynamometer (Jamar<sup>®</sup>). Figure 4 shows the



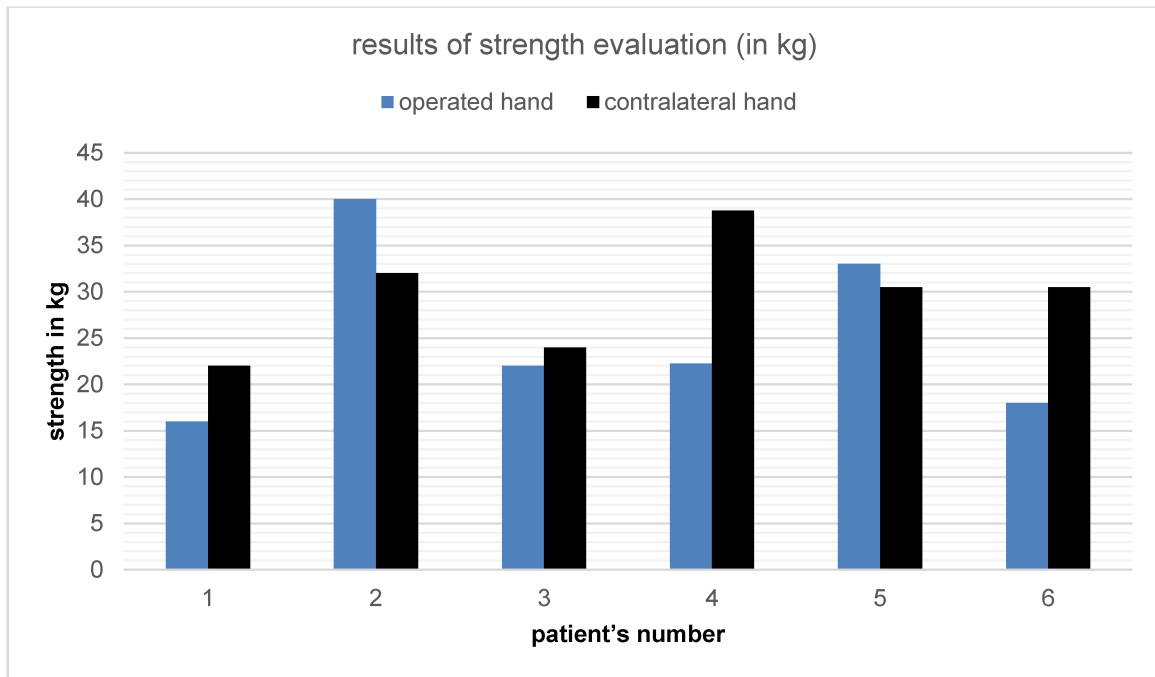


Figure 4: Results of grip strength evaluation of operated and contralateral hand by using the hand-held dynamometer (Jamar®) in six long-term follow-up patients

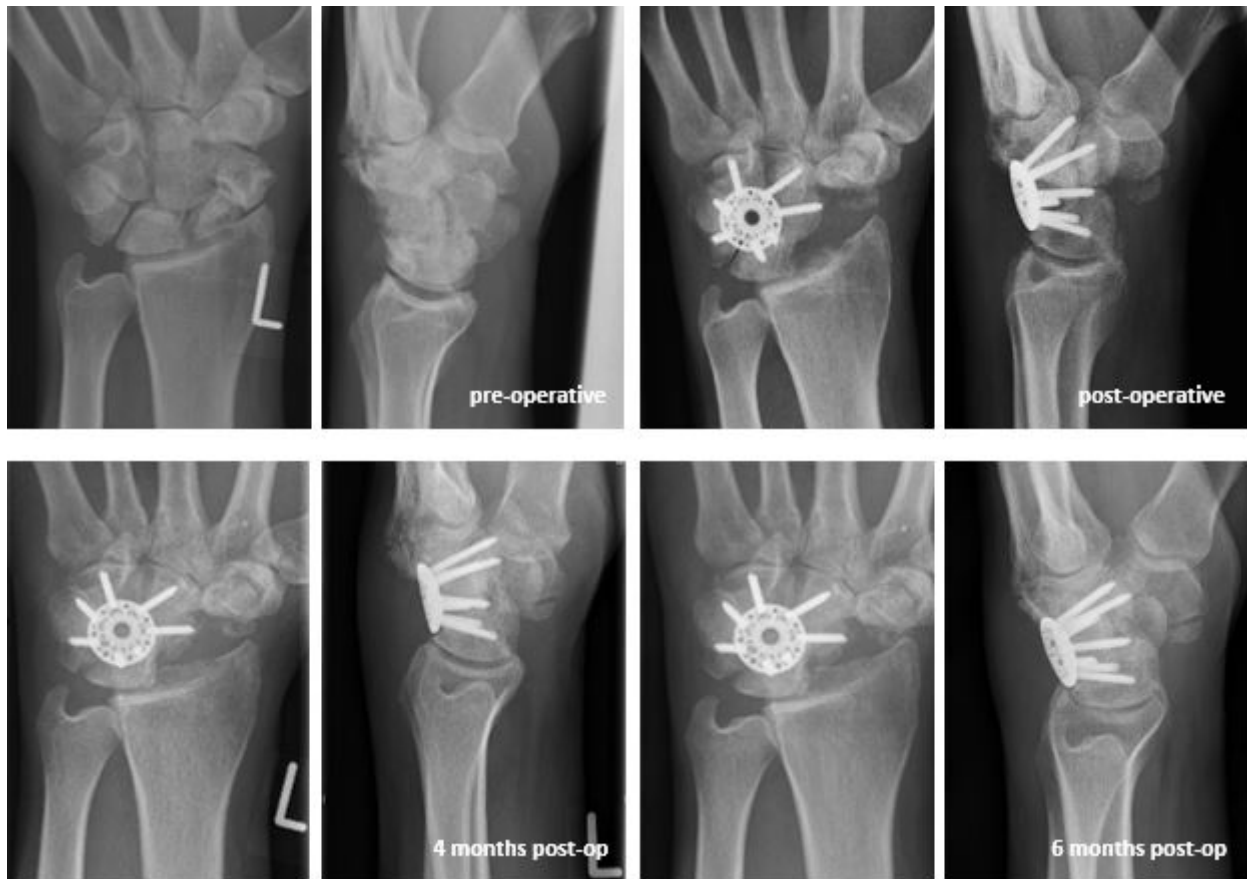

Figure 5: X-ray series of an advanced carpal collapse (SNAC wrist II-III) treated with Synthes® VA LCP ICF Plate up to six months after operation

results comparing reached maximum grip strength of operated hand versus non-operated hand (highest level out of three tries).

Figure 5 shows an X-ray series of an advanced carpal collapse (SNAC wrist II-III) treated with Synthes® VA LCP ICF Plate up to six months after operation.

## Discussion

There is a variety of different operation techniques, treating carpal instabilities like SNAC or SLAC wrist deformities in stage II or III. Most commonly and best described in literature are the 4-corner fusion of the wrist and the proximal row carpectomy [1], [2], [3], [4], [5], [6], [7], [9], [10], [11], [13], [16], [18], [19], [31], [32], [33], [34], [35]. Nonetheless, some authors recommend the 3-corner fusion, bicolunar intercarpal arthrodesis or other modifications as better options for treating wrist instabilities [14], [15].

Based on a systematic literature review we want to discuss and compare the 4-corner fusion, with emphasis on the variable angle locking plate (VA LCP ICF Plate by Synthes®), with other well accepted treatment options. Furthermore, we want to find out whether there were any differences between the Synthes® Variable Angle Locking Compression Intercarpal Fusion Plate and other fixation techniques used for the wrist arthrodesis (either traditional fixation techniques or different plate designs).

Proximal row carpectomy (PCR) and midcarpal arthrodesis (MCA) are motion preserving options for the treatment of stage II carpal collapse [9]. Many studies have been published to discuss the outcome of both operations. Exemplarily, Dacho et al. stated, that the PCR is easier to perform than the MCA operation [9]. However, the biomechanical situation after excision of the proximal carpal row is more dysfunctional due to the creation of incongruent articular surfaces [4], [9]. Furthermore, Brinkhorst et al. explored better functional outcomes (according to the Sollerman hand function test) of PCR patients comparing to those with MCA [36]. Additionally, there were specific complications for PCR and MCA mentioned in literature: On the one hand PCR can cause arthrosis in the radiocapitate region (particularly with necessity for denervation procedures), whereas on the other hand MCA may lead to insufficient cartilage removal, persisting pain, lower functional level postoperative, improper realignment of carpal height with nonunion in consequence (particularly with necessity for complete arthrodesis with loss of motion preserving keynote) [2], [4], [5], [9], [10], [11].

Williams et al. described significantly higher rates of secondary operations after 4 CF compared to PRC procedures due to non-unions, hardware impingement and others. They saw no significant differences in conversion rate to total wrist arthrodesis in the PRC group versus 4 CF group patients [37]. In overall conclusion of a randomized clinical trial comparing proximal row carpectomy and four-corner fusion, Aita et al. resumed no significant statistical differences in clinical and functional results between both salvage procedures [38].

In systematically researching current literature, it becomes obvious that there is a variety of studies seeing advantages and disadvantages for both procedures with consequently recommending either PCR or MCA [34] or seeing no statistical significant differences [38].

Therefore Mulford et al. performed a systematic analysis for comparing both operative treatments for stage II carpal collapse. Although there were no significant differences in pain relief, grip strength, subjective outcomes (such as patient's satisfaction) or reaching the state of complete arthrodesis, the authors stated a higher rate of radiocapitate arthrosis after PCR and 10% higher rate of general complications like non-union, dorsal impingement and material conflicts after MCA [34]. The post-operative flexion-extension arc was 10 degrees lower after MCA in comparison to PCR operation. In conclusion of Mulford et al.'s systematic review there is no clear overall difference between MCA and PCR whereby both procedures are equal options in therapeutic considerations [34].

The other systematical review comparing four-corner fusion (4 CF) and PCR by the working of group of Saltzman et al. stated a significant higher postoperative radial abduction range after MCA, whereas dorsal extension and palmar flexion as well as ulnar abduction displayed no significant differences [39]. Furthermore, the evaluated grip strength after 4 CF showed higher levels than the PCR cohort. Patient's satisfaction and pain severity did not lead to any statistically significant differences [39].

There are many well described variations of midcarpal arthrodesis. Common options are 3-corner arthrodesis and 4-corner arthrodesis as well as bicolunar arthrodesis of the wrist [13], [14], [15]. Klausmeyer et al. documented a more physiological situation after performing 3-corner arthrodesis due to better articulating surfaces [15]. However, Draeger et al. showed a restricted range of motion in wrists after bicolunar arthrodesis [14]. They supposed a higher fusion rate because of leaving greater bone surfaces due to not excising the scaphoid bone [14]. Therefore, no clear recommendation for either one or another varied midcarpal arthrodesis operation is given so far. In our study, all patients were treated with a 4 CF. Following the earlier presented decision tree for treatment of stage II and III carpal collapses, the next step is to consider the right material for the midcarpal arthrodesis operation technique.

After the different variants of traditional techniques (e.g. staples, screws, K-wires), initially the NLDP (e.g. the Spider™ Limited Wrist Fusion Plate, Kinetikos Medical Inc., San Diego, CA, USA) were designed as a new fixation system for 4 CF [4].

In literature research, a lot of case reports or series with either using traditional osteosynthesis material or NLDP are to be found. Comparing studies are rare.

One of these is the study published by Mavrogenis et al. They compared the long-term results of patients with 4 CF with either K-wires, headless compressive screws or a circular plate [40]. They reported patient's satisfaction and improvement of pre-operative pain level, range of motion and grip strength in all groups. Additionally, they displayed a fusion rate of 90.3% and a partial fusion in 9.7%. The partial fused wrists were treated in two cases with K-wire MCA and in one case with a circular plate. The overall complication rate is given with 10% of total:

2 patients with the circular plate (1 case of impingement and 1 case of regional pain syndrome) and one patient after K-wire/ headless compression screws fixation (impingement) [40].

Vance et al. compared the results after 4 CF with non-locking dorsal plates (NLDP) in one group with 4 CF done with traditionally used materials (wires, staples or screws) [23]. The study group discovered non-union rates of 3% in traditional fixation techniques against 26% in the NLDP group [19]. Additionally, they reported impingement rates of 3% in the traditional group versus 22% in the plate group [19]. Grip strength, range of motion and Disability of Arm and Shoulder (DASH) score also showed less satisfactory results in the NLDP group [19]. Furthermore, Chung et al. also reported that even pain relief was poorer after 4 CF with non-locking plate [4]. They have seen no significant pain decrease but an overall increasing patients' satisfaction after the operation. Only two patients described complete pain-freeness. As conclusion, Chung et al. claimed further investigations due to not full satisfying outcomes [4].

Opposingly, the operation technique using a plate for performing the four corner arthrodesis has its advantages: less infections (especially pin infections after K-wire implantation), absence of implant protrusion, no need for further operations (like implant excision when K-wires have been used) [3], [19], [31].

The study group of Hernekamp et al. reported of no statistical differences comparing patients with K-wire 4 CF and locking plate 4 CF [41].

Pauchard et al. stated that the final decision about the most adequate material for performing midcarpal arthrodesis has not been made yet [20]. Therefore, different techniques are currently used. Inconsistent arguments can be found in literature whether screws, K-wires, staples or plates are the best material to reach the most satisfying results in operating on carpal collapses [19], [20].

Evaluations of the non-union rates after using NLDP when performing a 4 CF of the wrist show different results. Kendall et al. stated a high rate of insufficient bony fusion with 62.5% [42] whereas Merrell et al. reached a 100% union rate after using an internal plate fixation technique [22]. Different authors reported non-union rates after 4 CF with traditional fixation materials ranging from 0% [43], [44] up to 17% [45], [46]. Shindle et al. presented a non-union rate of 25% and an overall complication rate of 56% after performing 4 CF via internal plate fixation [47].

In our study we used autogenous bone graft taken from the excised scaphoid bone in 10 cases and reached a 100% union rate. Which may have contributed to the good outcome in healing was the included reaming guide, leading to a better placement of the material. Furthermore, the rigid system with locking screws may contribute to bony fusion, as evaluated by Tielemans et al. using the same implant with reaching bony fusion in 100% as well [48] Dráč et al. reported of no non-union after 4 CF with VA LCP ICF Plate in their study population (abstract only, article in Czech) [35].

Furthermore, Friedel et al. stated the necrosis of the lunate bone to be a strict contraindication for implanting a plate for 4 CF [18]. We had one case with carpal collapse due to Kienböck's disease and can report good outcomes after implanting the VA LCP ICF Plate.

Another important and objective differentiator is the rate of complications occurring after 4 CF with either traditional fixation material or NLDP in different designs.

Chung et al. reported of three cases with screw break postoperatively (complication rate of 27.3%) [4].

The working group of Merrell, using a second-generation circular plate, displayed 2 cases of material failure including 1 case of broken plate and 1 case of screw back-out (total of 28 patients) [22].

Mantovani et al. performed an outcome study after 4 CF with a circular titanium plate with 4 non-locking screws (Carpal Button, SBi Interntional, Peronnas, France). They achieved complete fusion in 18 of 19 patients (94.7%) [24]. Additionally they reported of one case of screw break and two cases of persisting pain. This plate design only allows positioning one screw in each carpal bone. Mantovani et al. described this as a disadvantage because intraoperative screw break-outs are not easy to correct and compensate [24]. The necessity for drilling two screws in each bone was stated by other study groups as well [25]. The VA LCP ICF Plate by Synthes® (six or seven hole design) used in this study allowed the performing surgeon to consider the individual anatomic differences and decide in each case how many screws to be used to achieve a stable result.

Due to these high complication rates and a high risk of non-union, further investigations have been pursued. As consequence, the NLDP were ousted by the new generation of internal fixation method: LDP (locking dorsal plates) in different designs and variations (like the here used Variable Angle Locking Intercarpal Fusion Plate by Synthes®) [13], [21].

Reissner et al. published their comparison of 4 CF patients either treated with a non-locking plate (Spider plate, Integra LifeSciences.Corp., Plainsboro, NJ) or with a dorsal locking fusion system (Flower plate, KLS Martin group, Tuttlingen, Germany) [49]. In overall conclusion, they recommend the locking plates due to their lower rates of dorsal impingement (5% for locking plates versus 30% for non-locking plates) and lower rates of material loosening [49].

Rudnick et al. presented a fusion rate of 80% by using the Xpode® Cup as variant of a LDP (total of 26 operated wrists in 24 patients) [21]. They reported of one case in which a complete wrist arthrodesis had to be performed due to persisting pain and the development of radiolunate arthritis. There were also two cases of screw break-out [21]. Furthermore, five patients imposed with necessity for further surgical treatment because of dorsal adhesion of joint capsule, persisting pain within material conflict and/or impingement symptoms [21].

Luegmair et al., using the same implant, remarked a union rate of 92% [50]. Whereas Rhee et al. reported of 96% of bony healing after using the Xpode® Cup [25].



**Table 2: Comparison of results in grip strength and range of motion after four-corner arthrodesis via plate osteosynthesis in different working groups**

Author (plate used – NLDP or LDP)	Grip strength
	Range of motion (as reported)
Chung et al. [4] (spider plate, NLDP)	17.3 ± 14.5 kg 37.7 ± 15.6° flexion, 36.1 ± 10.4° extension (flexion-extension arc 73.8 ± 24.0°), 15.5 ± 9.5° radial abduction, 21.7 ± 8.7° ulnar abduction
Friedel et al. [18] (spider plate, NLDP)	76% of contralateral 41–53% of contralateral
Vance et al. [19] (spider plate, NLDP)	30 kg (70% of contralateral) 30° flexion, 35° extension, 50% flexion-extension arc of contralateral, 5% radial abduction, 30° ulnar abduction
Pauchard et al. [20] (APTUS four corner fusion® dorsal locking plate, LDP)	29.6 kg (70.7% of contralateral) 67.3° flexion-extension arc, 30.5° radial to ulnar abduction arc
Rudnick et al. [21] (radiolucent circular plate, LDP)	76.7–77.9% of contralateral 23.3° flexion, 46.5° extension (flexion-extension arc 69.8°), 13.1° radial abduction, 15.9° ulnar abduction
Merrell et al. [22] (spider plate, NLDP)	82% of contralateral 26° flexion, 35° extension, 45% ROM of contralateral
Espinoza et al. [23] (dorsal rectangular plate, NLDP)	27 kg (79% of contralateral) 34° flexion, 30° extension, 64° flexion-extension arc (61% of contralateral), 18° radial abduction, 19° ulnar abduction, 37° radial to ulnar abduction arc (76% of contralateral)
Mantovani et al. [24] (carpal button, NLDP)	27.5 kg (37.0 kg contralateral) 74.6° flexion-extension arc 151.0° contralateral), 36.2° radial to ulnar abduction arc (59.7° contralateral)
Xu et al. [26] (memory plate, NLDP)	20 kg 22° flexion, 19° extension, 11° radial abduction, 17° ulnar abduction
Bedford et al. [27] (spider plate, NLDP)	26 kg (78% of contralateral) 84° average total arc of motion (71% of contralateral)
Reissner et al. [49] (Flower plate, KLS Martin group, Tuttlingen, Germany, LDP)	29 kg 28° flexion 32° extension 14° radial abduction 13° ulnar abduction
Chaudhry et al. [51] (APTUS four corner fusion® dorsal locking plate, LDP)	27 kg (4–48 kg); 72% of contralateral 30° flexion (20–45°) 31° extension (10–60°)
Woehl et al. [52] (APTUS four corner fusion® dorsal locking plate, LDP)	18 ± 10 kg; 54% of contralateral 30 ± 9° flexion (48% of contralateral) 30 ± 15° extension (54% of contralateral) 18 ± 7° radial abduction (78% of contralateral) 16 ± 6° ulnar abduction (55% of contralateral) pronation and supination preserved in all
Zatrapa et al. (abstract only) [53] (nfs., NLDP and LDP)	27.5 kg mean (8–54 kg) sagittal plane 63.7° mean frontal plane 32.1° mean

nfs.=no further specification

Chaudhry et al. published their findings after performing 4 CF with the Aptus® LDP by Medartis, showing 2 cases of initial non-union with necessity for revision [51]. The working group of Woehl et al. described bony fusion in all patients (n=11) receiving 4 CF with the Aptus® plate (Medartis, Basel, Switzerland). They reported of two

complications: one screw malpositioning in the pisotriquetral joint and one proximal positioning of implanted plate leading to restricted mobility and pain after stressful movement [52]. As advantage of the Aptus® plate compared to the here used Synthes® implant they described a lower profile, the smaller diameter and more screw

options [52]. But in conclusion they reported of more difficulties in plate positioning due to the missing reaming guide. We can underline this argument due to our good experiences illustrated in the CDF 1 results.

The overall comparison of outcomes in grip strength and range of motion postoperatively is quite difficult, because specific data is commonly missing in the presented studies. If the articles include details about the postoperative clinical evaluation, there is no standardization making direct comparison, even statistically, impossible. Table 2 therefore is just a schedule with included references, using NLDPs or LDPs and giving information about the long-term clinical results.

Tielemans et al. presented their functional outcome score (QuickDASH) after 4 CF using the VA LCP ICF Plate to be improved and the pain level to be decreased post-surgery. They reported of 10% dorsal impingement with necessity to plate removal and 14% of all patients suffering from complex regional pain syndrome [48].

In comparison to studies dealing with different techniques, material and plate designs respectively, the ICF plate by Synthes® seems to be a good option for treating carpal collapse, which we illustrated with our findings as well.

In the long-term evaluation there were no complications like non-union of bony reconstruction, impingement or further material failures in our study population. The examined range of motion and grip strength were comparable to the results of other studies dealing with different implant variations.

As limitation of our study, only few patients could have been long-term re-evaluated. Additionally, there was no comparison group with other implants in our hospital; therefore, we could draw a parallel with other study results only. A larger multicenter study could solve these problems. A randomized clinical trial with different plate designs to afford more comparable results would be desirable. Another disadvantage is the lack of direct and statistical comparison of the results presented in current literature due to the non-standardized dissemination and elicitation of examination data. Thus, it was decided within this study to present all data as descriptive data. Advantageously, all operations were performed by the same surgeon. Additionally, the long-term re-evaluation was always done by the same physician to reach the highest level in commensurability. We used only evaluated and well-proofed questionnaires and diagnostic measures to survey patient's state of health.

## Conclusion

The four-corner fusion is a salvage operation for advanced carpal collapse such as SNAC and SLAC wrist. K-wires were the gold standard for the operation procedure formerly. By using K-wires, good consolidation rates were achieved. Disadvantageously, higher infection rates, K-wire dislocations and tendon ruptures are described in the literature.

Comparing the used locking plate by Synthes® with the K-wire osteosynthesis, the plate showed similar consolidation rates with less complications. Advantageously, no second operation for K-wire removal is needed. Furthermore, the evaluated range of motion, especially in long-term follow-up, is remarkably higher in plate arthrodesis. The non-locking plates, being the ancestor plate implants for four-corner arthrodesis, also showed complications like plate dislocations, missed healing and material failure, which were less frequent in the newer dorsal locking plate designs.

In overall comparison, Synthes® VA LCP ICF Plate is a more expensive option than K-wires or NLDPs for four-corner fusions, but our long-term evaluations showed comparable healing rates and distinctly better postoperative results especially in grip strength and range of motion.

## Notes

### Competing interests

The authors declare that they have no competing interests.

## References

- Dacho A, Grundel J, Holle G, Germann G, Sauerbier M. Long-term results of midcarpal arthrodesis in the treatment of scaphoid nonunion advanced collapse (SNAC-Wrist) and scapholunate advanced collapse (SLAC-Wrist). *Ann Plast Surg.* 2006 Feb;56(2):139-44. DOI: 10.1097/01.sap.0000194245.94684.54
- Ashmead D 4th, Watson HK, Damon C, Herber S, Paly W. Scapholunate advanced collapse wrist salvage. *J Hand Surg Am.* 1994 Sep;19(5):741-50. DOI: 10.1016/0363-5023(94)90177-5
- Winkler FJ, Borisch N, Rath B, Grifka J, Heers G. Mittelfristige Ergebnisse nach Skaphoidresektion und mediokarpaler Teilarthrodesis unter Verwendung von K-Drähten bei fortgeschrittenem karpalen Kollaps [Mid-term results after scaphoid excision and four-corner wrist arthrodesis using K-wires for advanced carpal collapse]. *Z Orthop Unfall.* 2010 May;148(3):332-7. DOI: 10.1055/s-0029-1240757
- Chung KC, Watt AJ, Kotsis SV. A prospective outcomes study of four-corner wrist arthrodesis using a circular limited wrist fusion plate for stage II scapholunate advanced collapse wrist deformity. *Plast Reconstr Surg.* 2006 Aug;118(2):433-42. DOI: 10.1097/01.prs.0000227737.90007.5d
- Sauerbier M, Bickert B, Tränkle M, Kluge S, Pelzer M, Germann G. Operative Behandlungsmöglichkeiten bei fortgeschrittenem karpalen Kollaps (SNAC/SLAC wrist) [Surgical treatment possibilities of advanced carpal collapse (SNAC/SLAC wrist)]. *Unfallchirurg.* 2000 Jul;103(7):564-71. DOI: 10.1007/s001130050584
- Papaloizos M. Wann, welche Behandlung bei scapho-lunären Bandverletzungen? [When and which treatment for scapho-lunate ligament lesions?]. *Ther Umsch.* 2014 Jul;71(7):385-90. DOI: 10.1024/0040-5930/a000527

7. Dacho A, Grundel J, Harth A, Germann G, Sauerbier M. Funktionelle Ergebnisse nach mediokarpaler Teilarthrodesis als Behandlungskonzept bei fortgeschrittenem karpalem Kollaps (SNAC-/SLAC-Wrist) [Functional outcome after midcarpal arthrodesis in the treatment of advanced carpal collapse (SNAC-/SLAC-wrist)]. *Handchir Mikrochir Plast Chir.* 2005 Apr;37(2):119-25. DOI: 10.1055/s-2004-821287
8. Pappou IP, Basel J, Deal DN. Scapholunate ligament injuries: a review of current concepts. *Hand (N Y).* 2013 Jun;8(2):146-56. DOI: 10.1007/s11552-013-9499-4
9. Dacho AK, Baumeister S, Germann G, Sauerbier M. Comparison of proximal row carpectomy and midcarpal arthrodesis for the treatment of scaphoid nonunion advanced collapse (SNAC-wrist) and scapholunate advanced collapse (SLAC-wrist) in stage II. *J Plast Reconstr Aesthet Surg.* 2008 Oct;61(10):1210-8. DOI: 10.1016/j.bjps.2007.08.007
10. Tränkle M, Sauerbier M, Blum K, Bickert B, Germann G. Die Entfernung der proximalen Handwurzelreihe als bewegungserhaltender Eingriff beim karpalen Kollaps [Proximal row carpectomy: a motion-preserving procedure in the treatment of advanced carpal collapse]. *Unfallchirurg.* 2003 Dec;106(12):1010-5. DOI: 10.1007/s00113-003-0670-1
11. Streich NA, Martini AK, Daecke W. Proximal row carpectomy: an adequate procedure in carpal collapse. *Int Orthop.* 2008 Feb;32(1):85-9. DOI: 10.1007/s00264-006-0281-x
12. Engelhardt TO, Krimmer H. Dissoziative Instabilitäten der proximalen Handwurzelreihe. In: Krupp J, Rennekampff HO, editor. *Plastische Chirurgie.* 27. Erg.-Lfg. Landsberg: Ecomed; 2006.
13. González Del Pino J, Campbell D, Fischer T, Vázquez FN, Jupiter JB, Nagy L. Variable angle locking intercarpal fusion system for four-corner arthrodesis: indications and surgical technique. *J Wrist Surg.* 2012 Aug;1(1):73-8. DOI: 10.1055/s-0032-1323640
14. Draeger RW, Bynum DK Jr, Schaffer A, Patterson JM. Bicolunar intercarpal arthrodesis: minimum 2-year follow-up. *J Hand Surg Am.* 2014 May;39(5):888-94. DOI: 10.1016/j.jhssa.2014.01.023
15. Klausmeyer MA, Fernandez DL, Caloia M. Scaphocapitolunate arthrodesis and radial styloidectomy for posttraumatic degenerative wrist disease. *J Wrist Surg.* 2012 Aug;1(1):47-54. DOI: 10.1055/s-0032-1323846
16. Richards AA, Afifi AM, Moneim MS. Four-corner fusion and scaphoid excision using headless compression screws for SLAC and SNAC wrist deformities. *Tech Hand Up Extrem Surg.* 2011 Jun;15(2):99-103. DOI: 10.1097/BTH.0b013e3181f60fec
17. Watson HK, Ryu J. Evolution of arthritis of the wrist. *Clin Orthop Relat Res.* 1986 Jan;(202):57-67. DOI: 10.1097/00003086-198601000-00008
18. Friedel R, Lenz M, Dönicke T, Hofmann G. Mediokarpale Teilarthrodesis des Handgelenks mittels Spiderplatte [Midcarpal fusion with the spider plate]. *Oper Orthop Traumatol.* 2011 Apr;23(2):98-104. DOI: 10.1007/s00064-011-0020-3
19. Vance MC, Hernandez JD, Didonna ML, Stern PJ. Complications and outcome of four-corner arthrodesis: circular plate fixation versus traditional techniques. *J Hand Surg Am.* 2005 Nov;30(6):1122-7. DOI: 10.1016/j.jhssa.2005.08.007
20. Pauchard N, Lecoanet-Strugarek C, Segret J, De Gasperi M, Dap F, Dautel G. Dorsal locking plates versus staples in four-corner fusion: a comparative clinical and radiological study. *Orthop Traumatol Surg Res.* 2014 Oct;100(6):593-7. DOI: 10.1016/j.otsr.2014.05.016
21. Rudnick B, Goljan P, Pruzansky JS, Bachoura A, Jacoby SM, Rekant MS. Four-corner arthrodesis with a radiolucent locking dorsal circular plate: technique and outcomes. *Hand (N Y).* 2014 Sep;9(3):315-21. DOI: 10.1007/s11552-014-9617-y
22. Merrell GA, McDermott EM, Weiss AP. Four-corner arthrodesis using a circular plate and distal radius bone grafting: a consecutive case series. *J Hand Surg Am.* 2008 May-Jun;33(5):635-42. DOI: 10.1016/j.jhssa.2008.02.001
23. Espinoza DP, Schertenleib P. Four-corner bone arthrodesis with dorsal rectangular plate: series and personal technique. *J Hand Surg Eur Vol.* 2009 Oct;34(5):609-13. DOI: 10.1177/1753193409105684
24. Mantovani G, Mathoulin C, Fukushima WY, Cho AB, Aita MA, Argintar E. Four corner arthrodesis limited to the centre using a scaphoid one piece graft and a dorsal circular plate. *J Hand Surg Eur Vol.* 2010 Jan;35(1):38-42. DOI: 10.1177/1753193409349905
25. Rhee PC, Shin AY. The rate of successful four-corner arthrodesis with a locking, dorsal circular polyether-ether-ketone (PEEK-Optima) plate. *J Hand Surg Eur Vol.* 2013 Sep;38(7):767-73. DOI: 10.1177/1753193413475962
26. Xu YQ, Zhu YL, Wang Y. The memory plate for four-corner fusion of scaphoid non-union advanced collapse. *J Plast Surg Hand Surg.* 2013 Dec;47(6):442-5. DOI: 10.3109/2000656X.2013.777844
27. Bedford B, Yang SS. High fusion rates with circular plate fixation for four-corner arthrodesis of the wrist. *Clin Orthop Relat Res.* 2010 Jan;468(1):163-8. DOI: 10.1007/s11999-009-1139-5
28. Brazier JE, Harper R, Jones NM, O' Cathain A, Thomas KJ, Usherwood T, Westlake L. Validating the SF-36 health survey questionnaire: new outcome measure for primary care. *BMJ.* 1992 Jul 18;305(6846):160-4. DOI: 10.1136/bmj.305.6846.160
29. Khan WS, Dillon B, Agarwal M, Fehily M, Ravenscroft M. The validity, reliability, responsiveness, and bias of the Manchester-Modified Disability of the Arm, Shoulder, and Hand score in hand injuries. *Hand (N Y).* 2009 Dec;4(4):362-7. DOI: 10.1007/s11552-009-9191-x
30. Bohannon RW. Reference values for extremity muscle strength obtained by hand-held dynamometry from adults aged 20 to 79 years. *Arch Phys Med Rehabil.* 1997 Jan;78(1):26-32. DOI: 10.1016/S0003-9993(97)90005-8
31. Trail IA, Murali R, Stanley JK, Hayton MJ, Talwalkar S, Sreekumar R, Birch A. The long-term outcome of four-corner fusion. *J Wrist Surg.* 2015 May;4(2):128-33. DOI: 10.1055/s-0035-1549277
32. Sauerbier M, Tränkle M, Linsner G, Bickert B, Germann G. Midcarpal arthrodesis with complete scaphoid excision and interposition bone graft in the treatment of advanced carpal collapse (SNAC/SLAC wrist): operative technique and outcome assessment. *J Hand Surg Br.* 2000 Aug;25(4):341-5. DOI: 10.1054/jhsb.2000.0434
33. Bain GI, Watts AC. The outcome of scaphoid excision and four-corner arthrodesis for advanced carpal collapse at a minimum of ten years. *J Hand Surg Am.* 2010 May;35(5):719-25. DOI: 10.1016/j.jhssa.2010.01.025
34. Mulford JS, Ceulemans LJ, Nam D, Axelrod TS. Proximal row carpectomy vs four corner fusion for scapholunate (Slac) or scaphoid nonunion advanced collapse (Snac) wrists: a systematic review of outcomes. *J Hand Surg Eur Vol.* 2009 Apr;34(2):256-63. DOI: 10.1177/1753193408100954
35. Dráč P, Čížmář I, Homza M, Prášil V, Zapletalová J. Excize clunkové kosti a čtyřhrhý fúze zápěstí pomocí VA-LIF v léčbě degenerativních poúrazových zmen zápěstního kloubu [Scaphoid excision and four-corner fusion using the variable angle locking intercarpal fusion plate for treatment of post-traumatic degenerative changes of the wrist]. *Acta Chir Orthop Traumatol Cech.* 2014;81(2):135-9.

36. Brinkhorst ME, Singh HP, Dias JJ, Feitz R, Hovius SER. Comparison of activities of daily living after proximal row carpectomy or wrist four-corner fusion. *J Hand Surg Eur Vol.* 2017 Jan;42(1):57-62. DOI: 10.1177/1753193416638812
37. Williams JB, Weiner H, Tyser AR. Long-Term Outcome and Secondary Operations after Proximal Row Carpectomy or Four-Corner Arthrodesis. *J Wrist Surg.* 2018 Feb;7(1):51-6. DOI: 10.1055/s-0037-1604395
38. Aita MA, Nakano EK, Schaffhausser HL, Fukushima WY, Fujiki EN. Randomized clinical trial between proximal row carpectomy and the four-corner fusion for patients with stage II SNAC. *Rev Bras Ortop.* 2016 Aug 20;51(5):574-82. DOI: 10.1016/j.rboe.2016.08.008
39. Saltzman BM, Frank JM, Slikker W, Fernandez JJ, Cohen MS, Wysocki RW. Clinical outcomes of proximal row carpectomy versus four-corner arthrodesis for post-traumatic wrist arthropathy: a systematic review. *J Hand Surg Eur Vol.* 2015 Jun;40(5):450-7. DOI: 10.1177/1753193414554359
40. Mavrogenis AF, Flevas DA, Raptis K, Megaloikonomos PD, Igoumenou VG, Antoniadou T, Dimopoulos L, Antonopoulos D, Spyridonos SG. Four-corner fusion of the wrist: clinical and radiographic outcome of 31 patients. *Eur J Orthop Surg Traumatol.* 2016 Dec;26(8):859-66. DOI: 10.1007/s00590-016-1824-5
41. Hernekamp JF, Reinecke A, Neubrech F, Bickert B, Kneser U, Kremer T. Four-corner fusion: comparison of patient satisfaction and functional outcome of conventional K-wire technique vs. a new locking plate. *Arch Orthop Trauma Surg.* 2016 Apr;136(4):571-8. DOI: 10.1007/s00402-016-2416-x
42. Kendall CB, Brown TR, Millon SJ, Rudisill LE Jr, Sanders JL, Tanner SL. Results of four-corner arthrodesis using dorsal circular plate fixation. *J Hand Surg Am.* 2005 Sep;30(5):903-7. DOI: 10.1016/j.jhsa.2005.04.007
43. Tomaino MM, Miller RJ, Cole I, Burton RI. Scapholunate advanced collapse wrist: proximal row carpectomy or limited wrist arthrodesis with scaphoid excision? *J Hand Surg Am.* 1994 Jan;19(1):134-42. DOI: 10.1016/0363-5023(94)90237-2
44. De Smet L, Deprez P, Duerinckx J, Degreef I. Outcome of four-corner arthrodesis for advanced carpal collapse: circular plate versus traditional techniques. *Acta Orthop Belg.* 2009 Jun;75(3):323-7.
45. Rodgers JA, Holt G, Finnerty EP, Miller B. Scaphoid excision and limited wrist fusion: a comparison of K-wire and circular plate fixation. *Hand (N Y).* 2008 Sep;3(3):276-81. DOI: 10.1007/s11552-008-9099-x
46. Wyrick JD, Stern PJ, Kiefhaber TR. Motion-preserving procedures in the treatment of scapholunate advanced collapse wrist: proximal row carpectomy versus four-corner arthrodesis. *J Hand Surg Am.* 1995 Nov;20(6):965-70. DOI: 10.1016/S0363-5023(05)80144-3
47. Shindle MK, Burton KJ, Weiland AJ, Domb BG, Wolfe SW. Complications of circular plate fixation for four-corner arthrodesis. *J Hand Surg Eur Vol.* 2007 Feb;32(1):50-3. DOI: 10.1016/j.jhsb.2006.08.016
48. Tielemans A, Van Innis F, Troussel S, Detrembleur C, Libouton X, Lequint T. Effect of four-corner fusion with locking plate without bone graft on functional recovery of the wrist: New treatment guidelines. *Hand Surg Rehabil.* 2017 Jun;36(3):186-191. DOI: 10.1016/j.hansur.2017.01.005
49. Reissner L, Hensler S, Kluge S, Marks M, Herren DB. Treatment Outcomes of 4-Corner Arthrodesis for Patients With Advanced Carpal Collapse: An Average of 4 Years' Follow-Up Comparing 2 Different Plate Types. *J Hand Surg Am.* 2018 May;43(5):487.e1-487.e6. DOI: 10.1016/j.jhsa.2017.10.036.
50. Luegmair M, Houvet P. Effectiveness of four-corner arthrodesis with use of a locked dorsal circular plate. *Clin Orthop Relat Res.* 2012 Oct;470(10):2764-70. DOI: 10.1007/s11999-012-2312-9
51. Chaudhry T, Spiteri M, Power D, Brewster M. Four corner fusion using a multidirectional angular stable locking plate. *World J Orthop.* 2016 Aug;7(8):501-6. DOI: 10.5312/wjo.v7.i8.501
52. Woehl R, Maier J, Gehmert S, Palm C, Riebschlaeger B, Nerlich M, Huber M. 3D analysis of Osteosyntheses material using semi-automated CT segmentation: a case series of a 4 corner fusion plate. *BMC Musculoskelet Disord.* 2018 02;19(1):52. DOI: 10.1186/s12891-018-1975-0
53. Zatrapa T, Veigl D, Pech J, Landor I, Šimková M. [Four-Corner Arthrodesis of the Wrist with Dorsal Circular Plate – a Retrospective Monocentric Study]. *Acta Chir Orthop Traumatol Cech.* 2017;84(3):189-195.

#### Corresponding author:

Prof. Dr. med. Björn Dirk Krapohl  
Plastic and Reconstructive Surgery, Carl-Thiem-Klinikum  
Cottbus, Thiemstr. 111, 03048 Cottbus, Germany  
bjoern-dirk.krapohl@charite.de

#### Please cite as

Eder C, Scheller A, Schwab N, Krapohl BD. Four-corner arthrodesis of the wrist using Variable Angle Locking Compression Intercarpal Fusion Plate (VA LCP ICF Plate; Synthes®): pre- and postoperative radiological analysis and clinical outcome in long-term evaluation. *GMS Interdiscip Plast Reconstr Surg DGPW.* 2019;8:Doc15. DOI: 10.3205/iprs000141, URN: urn:nbn:de:0183-iprs0001411

#### This article is freely available from

<https://www.egms.de/en/journals/iprs/2019-8/iprs000141.shtml>

Published: 2019-11-15

#### Copyright

©2019 Eder et al. This is an Open Access article distributed under the terms of the Creative Commons Attribution 4.0 License. See license information at <http://creativecommons.org/licenses/by/4.0/>.