

# Tear Fluid Angiogenic Factors: Potential Noninvasive Biomarkers for Retinopathy of Prematurity Screening in Preterm Infants

Anand Vinekar,<sup>1</sup> Archana Padmanabhan Nair,<sup>2,3</sup> Shivani Sinha,<sup>1</sup> Tanuja Vaidya,<sup>2,3</sup> Koushik Chakrabarty,<sup>2</sup> Rohit Shetty,<sup>4</sup> Arkasubhra Ghosh,<sup>2,5</sup> and Swaminathan Sethu<sup>2</sup>

<sup>1</sup>Department of Pediatric Retina, Narayana Nethralaya, Bangalore, India

<sup>2</sup>GROW Research Lab, Narayana Nethralaya Foundation, Bangalore, India

<sup>3</sup>Manipal Academy of Higher Education, Manipal, India

<sup>4</sup>Department of Cornea and Refractive Surgery, Narayana Nethralaya, Bangalore, India

<sup>5</sup>Singapore Eye Research Institute, Singapore

Correspondence: Swaminathan Sethu, GROW Research Laboratory, Narayana Nethralaya Foundation, Narayana Health City, #258/A, Bommasandra, Hosur Road, Bangalore 560 099, India; [swaminathansethu@narayanane-thralaya.com](mailto:swaminathansethu@narayanane-thralaya.com).

**Received:** August 30, 2020

**Accepted:** January 24, 2021

**Published:** March 1, 2021

Citation: Vinekar A, Nair AP, Sinha S, et al. Tear fluid angiogenic factors: Potential noninvasive biomarkers for retinopathy of prematurity screening in preterm infants. *Invest Ophthalmol Vis Sci.* 2021;62(3):2. <https://doi.org/10.1167/iovs.62.3.2>

**PURPOSE.** To determine the status of proangiogenic factors in the tear fluid of preterm infants with and without retinopathy of prematurity (ROP).

**METHODS.** Preterm infants ( $n = 36$ ) undergoing routine ROP screening included in the prospective study were categorized as No-ROP ( $n = 13$ , no ROP at any visits), ROP (if ROP was present at first visit;  $n = 18$ ), or No-ROP to ROP (no disease at first visit, but developed ROP subsequently;  $n = 5$ ). Infants with ROP were also grouped as progressing ( $n = 7$ ) and regressing ( $n = 16$ ) based on ROP evolution between the first and subsequent visits. Schirmer's strips were used to collect tear fluid and proangiogenic factors (VEGF, angiogenin, soluble vascular cell adhesion molecule, and fractalkine) levels (in picograms per milliliter) in tear fluid were measured by multiplex ELISA.

**RESULTS.** Lower levels of VEGF ( $135 \pm 69$ ; mean  $\pm$  standard deviation) and higher levels of angiogenin ( $6568 \pm 4975$ ) were observed in infants with ROP compared with infants without ROP ( $172.5 \pm 54.0$ ;  $4139 \pm 3909$ ) at the first visit. Significantly lower levels of VEGF were observed in the No-ROP to ROP group compared with the No-ROP and ROP groups. The VEGF and angiogenin levels at the first visit were significantly lower in infants with ROP with progressing disease. Angiogenin levels negatively correlated with birth weight and gestational age in ROP. The area under the curve (AUC) and odds ratio (OR) analysis demonstrated that angiogenin/birth weight (AUC = 0.776; OR, 8.6); angiogenin/gestational age (AUC = 0.706; OR, 7.3) and Angiogenin/VEGF (AUC = 0.806; OR, 14.3) ratios were able to differentiate preterm infants with and without ROP.

**CONCLUSIONS.** The association between angiogenin and ROP suggests its possible role in ROP. The ratio of angiogenin level with birth weight, gestational age, and/or VEGF could serve as a potential noninvasive screening biomarker for ROP.

**Keywords:** VEGF, angiogenin, tear fluid, ROP, noninvasive, biomarker

Retinopathy of prematurity (ROP), a vasoproliferative disorder of the developing retina, is one of the major causes of blindness in preterm infants.<sup>1</sup> ROP currently represents the leading preventable cause of childhood blindness worldwide with an incidence of 184,700 (within 14,900,000 preterm births), with close to 30% requiring active treatment for ROP and 17% surviving with some form of visual impairment to blindness owing to ROP.<sup>2,3</sup> It is a significant problem in the developing world such as Asia,<sup>3</sup> where recent advances in neonatal care have led to a substantial increase in the survival of preterm infants, albeit with a higher incidence of ROP.<sup>4,5</sup> The incidence of any stage of ROP among preterm infants in India ranges between 22% and 52% and those that require treatment are from 3.5% to 10%.<sup>5</sup> Birth weight, gestational stage, and oxygen saturation of preterm infants are critical predisposing factors to ROP.<sup>6</sup>

The primary pathology of ROP is driven by the disruption and dysregulation in the postnatal development of the retinal vasculature.<sup>7</sup> The mechanism underlying this pathogenesis is attributed to an imbalance in the endogenous proangiogenic and antiangiogenic factors in the developing retina.<sup>7</sup> Angiogenic factors imbalance in the retina is associated with two major phases in ROP development, namely, the vaso-obliteration and vasoproliferation phases.<sup>7,8</sup> The vaso-obliteration phase in preterm infants happens immediately after birth, owing to the surge in the SpO<sub>2</sub> (peripheral capillary oxygen saturation), caused by the difference between the in utero environment and room air oxygenation.<sup>7</sup> The surge in the SpO<sub>2</sub> results in a hyperoxic environment resulting in a decrease in angiogenic factors inducing reduced growth of retinal vasculature.<sup>7,8</sup> This stasis in vascular growth results in a hypoxic environment at the

developing end that triggers the production of proangiogenic factors including vascular endothelial growth factor (VEGF) to stimulate the retinal vessel development.<sup>7,8</sup> However, in some preterm infants this otherwise physiological response goes awry resulting in an uncontrolled and disorganized pathological angiogenesis that either self-resolves or requires active intervention to prevent irreversible blindness owing to retinal traction and detachment.<sup>7,9</sup>

VEGF has evolved as the most studied and primary disease modifiable factor in ROP. VEGF was found to be elevated in the peripheral, avascular retina of a preterm infant with ROP.<sup>10</sup> Further, an increase in the levels of VEGF<sup>11-17</sup> and other proangiogenic factors including erythropoietin,<sup>15</sup> angiopoietins (angiopoietin-1 and angiopoietin-2)<sup>18</sup> in the vitreous humor of infants with ROP were observed. To further signify the imbalance in angiogenic factors, a decrease in antiangiogenic factors such as pigment epithelium-derived factor<sup>19</sup> and VEGF<sub>165b</sub><sup>13</sup> in the vitreous humor of infants with ROP, have also been reported. In addition to laser photocoagulation to stem the pathological angiogenesis, intravitreal anti-VEGF are also being extensively studied. Intravitreal anti-VEGF therapy is a relatively new modality of treatment for ROP, especially useful in eyes presenting with aggressive posterior ROP.<sup>20,21</sup> Studies have reported variable outcomes after the use of anti-VEGF in the management of ROP, such as eyes that underwent anti-VEGF treatment were associated with a higher likelihood of requiring additional treatment and longer time between treatment to retreatment or recurrence when compared with eyes that underwent laser photocoagulation,<sup>22</sup> and anti-VEGF treatment may not decrease the risk of recurrence in zone II ROP and retinal detachment in type 1 ROP.<sup>22-25</sup> Owing to the mixed response, vascularization after monotherapy with anti-VEGF is often incomplete, prompting additional treatment with other modalities.<sup>26</sup>

Owing to the variability of outcome after the use of anti-VEGF in managing ROP and the possibility of other proangiogenic factors that could mediate ROP, there is a need to study the status of other proangiogenic factors in infants with ROP. Angiogenin, soluble vascular cell adhesion molecule (sVCAM) and fractalkine (FKN/CX3CL1) are other potent proangiogenic factors that have been reported to be associated with pathological angiogenesis in various ocular diseases.<sup>27-37</sup> It is pertinent to determine the status of these angiogenic factors in ocular fluids and tissues. The levels of VEGF in ocular samples, such as vitreous humor<sup>11-17</sup> and aqueous humor,<sup>14,38</sup> were reported to be significantly higher in infants with ROP. There is also a need to measure these factors using a noninvasive strategy for ease, patient compliance, and longitudinal monitoring. Tear fluid is well-documented to be an ideal source to identify and validate molecular markers that have strong correlation with ocular diseases.<sup>39</sup> Recently, matrix metalloproteinase levels in the tear fluid of infants with ROP have been associated with disease progression,<sup>11</sup> suggesting the usefulness of noninvasive ocular sampling strategies in ROP studies.

Despite our understanding of ROP pathobiology, risk stratification, and management, there are gaps that still need to be addressed. First, molecular factors that reflects vaso-obliteration and vasoproliferation status and its degree in infants are yet to be ascertained in ocular samples. Further, these molecular factors could then serve as predictive, risk, or monitoring factors, which will aid in identifying preterm infants who are at a much higher risk of developing ROP

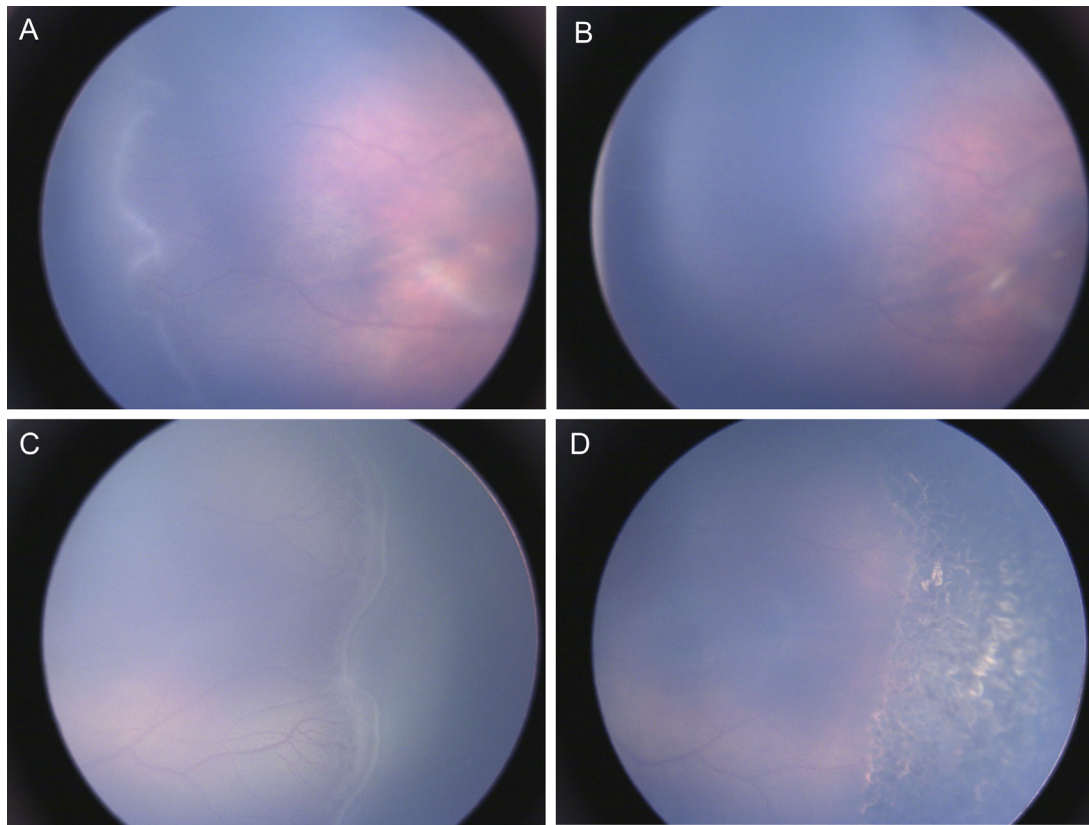
(in addition to clinical risk factors). If this information is available in the first screening visit, it will help the clinician to decide the follow-up course and may potentially help reduce the number of screening sessions. Second, molecular factors may be used to distinguish ROP that can spontaneously regress from that requiring active intervention. This information will help to prognosticate and strategize the clinical course more efficiently. Hence, the current study aims to address these gaps by profiling for key proangiogenic factors, namely, VEGF, angiogenin, sVCAM, and FKN/CX3CL1 in the tear fluid of preterm infants with and without ROP.

## METHODS

### Study Cohort

This prospective, longitudinal pilot study was approved by Narayana Nethralaya Institutional Review Board. The patient recruitment and sample collection procedure was conducted as per institutional ethics committee guidelines and in accordance with the tenets of the Declaration of Helsinki. Written informed consent was obtained from either the parents or legal guardians before patient recruitment and sample collection. The study was conducted between August 2016 and January 2017, wherein 36 consecutive Asian Indian infants who presented to our KIDROP tele-ROP screening service were included.<sup>5,40</sup> Infants were enrolled in the study based on the national screening guideline cut-offs, that is, a birth weight (BW) of 2000 g or less and/or a gestational age of 34 weeks or less.<sup>41</sup> The first screening visit was performed within 30 days of birth according to the national guidelines. The infants were followed-up until the retina was completely vascularized or the laser scars healed completely (Fig. 1). The follow-up period was defined based on the national ROP guidelines.<sup>41</sup> All the patients had at least two follow-up visits, with some infants reporting for three or more visits. The final visit was either second, third, or fourth visit. The disease status at the final visit in all the preterm infants were either mature retina, or resolving/healing between the first and final visits. All infants underwent photo-documentation during each screening visit on the RetCam Shuttle (Natus, San Carlos, CA). The staging of the disease was done according to International Classification of Retinopathy of Prematurity at each visit.<sup>42</sup> Treatment was performed on eyes that had fulfilled the Early Treatment for Retinopathy of Prematurity guidelines.<sup>43</sup> Disease staging, categorization, follow-up, and management were done by the same ROP specialist.

The infants were categorized based on the presence of ROP during the first and subsequent visits. The No-ROP group includes preterm infants who did not have ROP during the first ophthalmic examination visit after birth and did not develop ROP thereafter ( $n = 13$ ). The No-ROP to ROP group includes preterm infants who did not present with ROP during the first ophthalmic examination visit after birth, but developed ROP in any subsequent visit ( $n = 5$ ). The ROP group includes preterm infants who presented with ROP during the first visit of the study ( $n = 18$ ). Because it was more relevant to determine the proangiogenic factor profile variation between preterm infants who did and did not develop ROP, the No-ROP group qualified as an appropriate control group rather than the term infants. This approach would yield molecular information that could be used in stratifying preterm infants with higher risk of developing ROP. Infants were further categorized based on

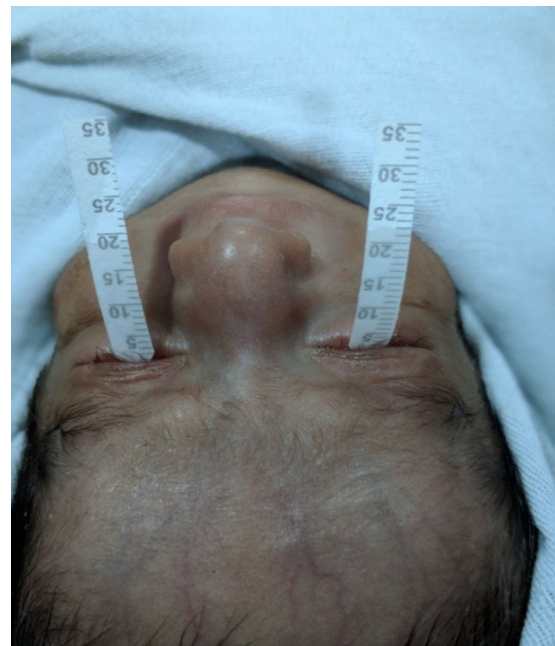

**FIGURE 1.** RetCam images from preterm infants with ROP. Representative RetCam image of a right eye of a preterm infant who presented with ROP stage 2 in the first screening visit (A) and regressed spontaneously in a follow-up visit (B). Left eye RetCam image of an infant who had progressed to type 1 ROP (C) and was followed until the laser scars healed (D).

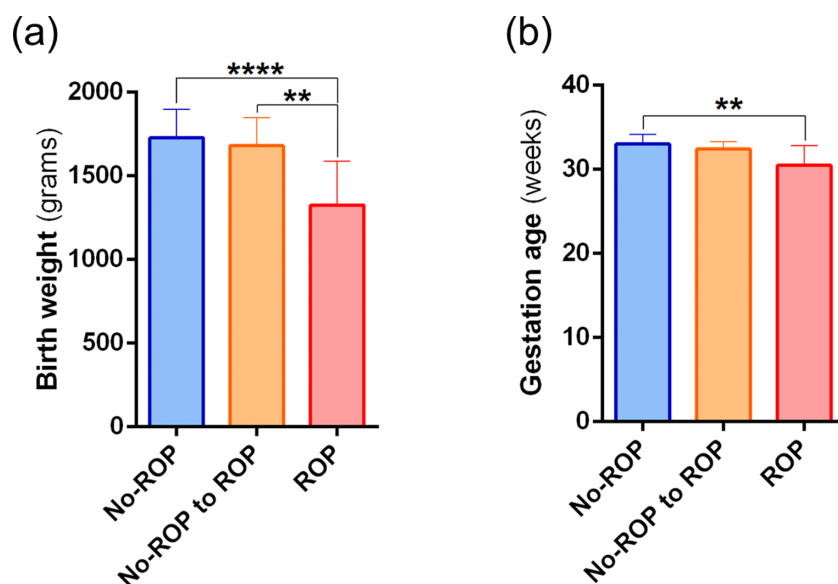
the evolution of the disease between initial and second visit. Preterm infants who had presented with ROP in the first visit and exhibited spontaneous regression to milder stages of ROP as per International Classification of Retinopathy of Prematurity classification or no stage of ROP at a follow-up visit were categorized as regressing ( $n = 16$ ). The progressing group includes preterm infants with and without ROP who showed progression to a higher stage of disease as per International Classification of Retinopathy of Prematurity classification in the second visit compared with first visit ( $n = 7$ ).

### Tear Fluid Collection and Extraction

Tear fluid or conjunctival secretion was collected using sterile Schirmer's strips ( $5 \times 35\text{-mm}^2$ ; Contacare Ophthalmics and Diagnostics, Gujarat, India) during ROP screening visits. The procedure was performed before the use of any topical medication, including topical anesthetics and those required for pupillary dilatation. Briefly, the strips were placed one in each of the conjunctival fornices, simultaneously in both eyes (Fig. 2). The strips were removed after a sufficient amount of tear fluid (wetting of strips until the 20 mm mark or more) was collected, and stored in a sterile microcentrifuge tube at  $-80^\circ\text{C}$ . Tear fluid was extracted as previously described.<sup>44</sup> Briefly, Schirmer's strips were cut them into small pieces, agitated in  $300\ \mu\text{L}$  of 1x sterile PBS for 2 hours at  $4^\circ\text{C}$  at 300 rpm and centrifuged to elute the tear fluid. The eluted tear fluid was used for further processing to measure proangiogenic factors as described elsewhere in this article.



**FIGURE 2.** Tear fluid collection in preterm infants. The representative image demonstrates the collection of tear fluid using sterile Schirmer's strips in preterm infants. The strip is placed in the lower conjunctival fornix and the collection of tear fluid is evident based on the wetting of Schirmer's strips, that is, 22 mm and 19 mm in the right eye and left eye, respectively.



**FIGURE 3.** Birth weight and gestational age of preterm infants in the study cohort. The graphs indicate birth weight in grams (a) and gestational age in weeks (b) of the study cohort at first visit. The cohort was categorized into three groups. The No-ROP group includes preterm infants who did not have ROP during the first ophthalmic examination visit after birth and did not develop ROP thereafter ( $n = 13$ ). The No-ROP to ROP group includes preterm infants who did not present with ROP during the first ophthalmic examination visit after birth, but developed ROP in the subsequent visit ( $n = 5$ ). The ROP group includes preterm infants who presented with ROP during the first visit of the study ( $n = 18$ ). Bar graphs indicate mean  $\pm$  standard deviation. \*\* $P < 0.001$ ; \*\*\*\* $P < 0.0001$ , Mann-Whitney  $U$  test.

### Measurement of Proangiogenic Factors

The levels of proangiogenic factors such as VEGF, angiogenin, sVCAM and FKN/CX3CL1 in the eluted tear fluid were measured by multiplex ELISA – Cytometric Bead Array (BD CBA Human Soluble Protein Flex Set System, BD Biosciences, San Jose, CA) using a flow cytometer (BD FACSCantoII, BD Biosciences) as previously described.<sup>44</sup> BD FACSDiva software (BD Biosciences) was used to acquire the beads and record signal intensities. FCAP array Version 3.0 (BD Biosciences) was used to determine the absolute concentration of the analytes using respective standards. The absolute concentrations were then normalized to the wetting length (tear fluid volume) and dilution (extraction buffer volume) as described elsewhere in this article.<sup>44</sup>

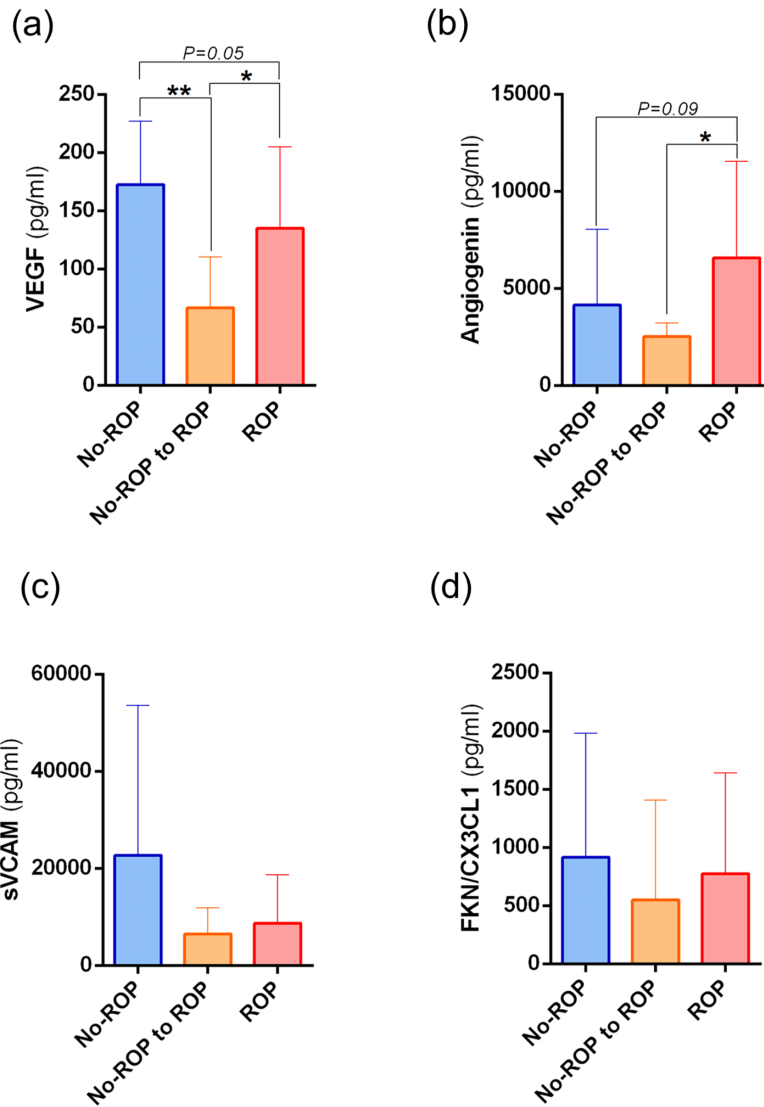
### Statistical Analysis

The distribution of the data was determined by the Shapiro-Wilk normality test. The differences in the level of proangiogenic factors between the groups and between visits were statistically analyzed by either the Mann-Whitney  $U$  test or the Wilcoxon matched-pairs signed rank test, respectively. The Spearman rank correlation coefficient was determined to infer the association between the proangiogenic factors and birth weight or gestational age of preterm infants. Receiver operating characteristic (ROC) curve analysis to determine the area under the ROC curve (AUC), sensitivity, specificity, and odds ratio (OR) was performed to determine the relevance of the various factors studied to differentiate preterm infants with and without ROP. A  $P$  value of less than 0.05 was considered to be statistically significant. Statistical analyses were performed with either GraphPad Prism 6.0 (GraphPad Software, Inc., La Jolla, CA) or MedCalc Version 12.5 (MedCalc Software bvba, Ostend, Belgium).

### RESULTS

In the current cohort, the birth weight (mean  $\pm$  standard deviation, 1325  $\pm$  263 g) and the gestational age (30.4  $\pm$  2.3 weeks) of preterm infants with ROP (ROP group) were observed to be significantly lower compared with preterm infants without ROP (No-ROP group; birth weight, 1730  $\pm$  168 g; gestational age, 33  $\pm$  1.1 weeks) as shown in Figures 3a and 3b. No significant difference was observed in birth weight and gestational age between No-ROP infants and preterm infants who did not have ROP during the first ophthalmic examination visit after birth but developed ROP in the subsequent visit (No-ROP to ROP; birth weight, 1680  $\pm$  168 g; gestational age, 32.4  $\pm$  0.8 weeks) (Fig. 3). Birth weight, but not gestational age, was observed to be significantly lower in infants in the ROP group compared with infants in the No-ROP to ROP group (Fig. 3a).

The levels of proangiogenic factors such as VEGF, angiogenin, sVCAM, and FKN/CX3CL1 in the tear fluid collected during the first visit were measured. Significantly lower levels of VEGF were observed in the No-ROP to ROP group (66.6  $\pm$  43.6 pg/mL) compared with the No-ROP group (172.5  $\pm$  54.7 pg/mL), as shown in Figure 4a. A similar decrease, although not significant, was also observed in the levels of angiogenin (No-ROP group, 4139  $\pm$  3909; No-ROP to ROP group, 2536  $\pm$  694.7 pg/mL), sVCAM (No-ROP group, 22743  $\pm$  30859; No-ROP to ROP group, 6479  $\pm$  5411 pg/mL), and FKN/CX3CL1 (No-ROP group, 917  $\pm$  1065; No-ROP to ROP group, 550  $\pm$  857 pg/mL) (Figs. 4b–d). Further, VEGF and angiogenin was significantly lower in the No-ROP to ROP group (66.6  $\pm$  43.6 and 2536  $\pm$  694.7 pg/mL) compared with the ROP group (135  $\pm$  69.7 and 6568  $\pm$  4975 pg/mL) (Figs. 4a–b). Lower levels of VEGF (135  $\pm$  69.7 pg/mL;  $P = 0.05$ ) as well as sVCAM (8747  $\pm$  9940 pg/mL) and FKN/CX3CL1 (774  $\pm$  866 pg/mL), although not statistically significant, were observed in the ROP group infants



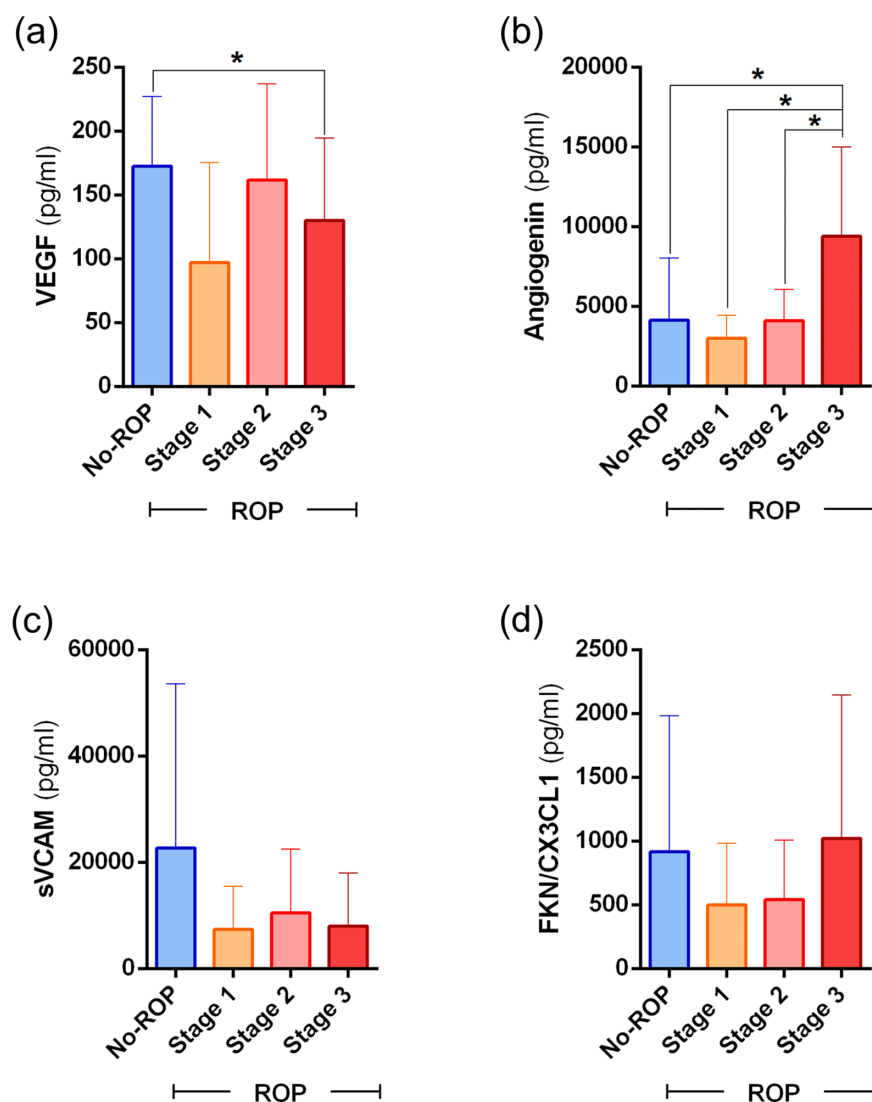
**FIGURE 4.** Proangiogenic factors level in the tear fluid of preterm infants with and without ROP. The graphs indicate the concentration of VEGF (a), angiogenin (b), sVCAM (c), and FKN/CX3CL1 (d) in the tear fluid of preterm infants at first visit. The cohort was categorized into three groups, namely, No-ROP ( $n = 13$ ), No-ROP to ROP ( $n = 5$ ) and ROP ( $n = 18$ ). Bar graphs indicate mean  $\pm$  standard deviation. \* $P < 0.05$ , \*\* $P < 0.01$ , Mann-Whitney  $U$  test.

compared with the No-ROP group infants (Figs. 4a, c, d). In contrast, angiogenin was observed to be higher ( $P = 0.09$ ) in the ROP group infants compared with the No-ROP group infants (Fig. 4b).

Proangiogenic factors during the first visit were observed to be low, albeit statistically insignificant, in stage 1 infants with ROP compared with the No-ROP group infants and other stages of the ROP group infants (Fig. 5). Interestingly, the VEGF level was observed to be significantly lower in the infants with stage 3 ROP ( $130 \pm 64$  pg/mL) compared with the infants without ROP (Fig. 5a). It is important and novel in ROP to observe that the angiogenin level was significantly higher in infants with stage 3 ROP ( $9406 \pm 5587$  pg/mL) compared with infants without ROP (Fig. 5b). A stage-dependent increase in the angiogenin level was also observed in the infants with ROP (Fig. 5b). A correlation analysis was performed to study the association between the proangiogenic factors level and birth weight (BW) or gesta-

tional age (GA) at the first visit. The angiogenin level was observed to be negatively associated with both BW and GA in infants with ROP but not in infants without ROP (Figs. 6 and 7). FKN/CX3CL1 exhibited a negative relationship with BW in infants with ROP (Fig. 6).

To further elucidate the relevance of proangiogenic levels in ROP pathobiology and its risk stratification, the ratio between proangiogenic factors measured and BW or GA for each preterm infant in the study cohort was determined. The angiogenin/birth weight ratio ( $5.4 \pm 4.5$ ;  $P < 0.01$ ) and angiogenin/gestational age ratio ( $224 \pm 181$ ;  $P = 0.06$ ) was observed to be higher in infants with ROP compared with infants without ROP ( $2.3 \pm 2$ ;  $125 \pm 118$ ) (Figs. 8b and f). The angiogenin/VEGF ratio was observed to significantly higher in infants with ROP ( $56 \pm 30$ ) compared with infants without ROP ( $23 \pm 20$ ) (Fig. 9a). Further, the ratio of BW or GA to angiogenin/VEGF ratio was found to significantly lower in the ROP group ( $52.6 \pm 77$ ;  $1.1 \pm 1.6$ )



**FIGURE 5.** Proangiogenic factors level in the tear fluid of preterm infants with different stages of ROP. The graphs indicate the concentration of VEGF (a), angiogenin (b), sVCAM (c), and FKN/CX3CL1 (d) in the tear fluid of preterm infants at first visit. Infants with ROP were subcategorized as stage 1 ( $n = 3$ ), stage 2 ( $n = 6$ ), and stage 3 ( $n = 9$ ) as per International Classification of Retinopathy of Prematurity classification. No-ROP ( $n = 13$ ). Bar graphs indicate mean  $\pm$  standard deviation. \* $P < 0.05$ , Mann-Whitney  $U$  test.

compared with the No-ROP group ( $142 \pm 105$ ;  $2.8 \pm 2.2$ ) (Figs. 9b, c). ROC curve analysis was performed to determine the AUC that would suggest the clinical relevance of these ratios as possible biomarker to differentiate preterm infants with and without ROP. The optimal cut-off criterion that maximizes the sensitivity and specificity that was used for OR calculation was determined using ROC curve analysis. The largest area under the curve (AUC = 0.833;  $P < 0.001$ ) was observed for the birth weight/(angiogenin/VEGF) ratio (Fig. 10d). The cut-off value of 29 or less for the birth weight/(angiogenin/VEGF) ratio determined using the Youden index criterion in the ROC curve analysis showed 72.2% sensitivity, 92.3% specificity, and an OR of 31 (95% confidence interval [CI], 3.2–306.8;  $P = 0.0032$ ), as shown in Figure 10i. The angiogenin/birth weight ratio exhibited an AUC of 0.776 ( $P = 0.002$ ) and a cut-off value of greater than 3 with 72.2% sensitivity, 76.9% specificity, and an OR of 8.6 (95% CI 1.6–45.2;  $P = 0.010$ ), as shown in Figures 10a and f. The AUC for the angio-

genin/gestational age ratio was 0.706 ( $P = 0.042$ ) and a cut-off value of greater than 87 with 76.5% sensitivity, 61.5% specificity, and an OR of 7.3 (95% CI, 1.4–37.1;  $P = 0.016$ ) as seen in Figures 10b and g. The angiogenin/VEGF ratio demonstrated an AUC of 0.806 ( $P < 0.001$ ) and a cut-off value of greater than 41 with 72.2% sensitivity, 84.6% specificity, and an OR of 14.3 (95% CI, 2.3–88.7;  $P = 0.0043$ ) as presented in Figures 10c and h. Finally, the gestational age/(angiogenin/VEGF) ratio recorded an AUC of 0.808 ( $P < 0.001$ ) and a cut-off value of 0.7 or less with 70.6% sensitivity, 84.6% specificity, and an OR of 13.2 (95% CI, 2.1–82.5;  $P = 0.0058$ ), as shown in Figures 10e and j.

Based on the second follow-up visit, preterm infants were categorized as progressing and regressing based on the stage of ROP during first and second visit. The levels of VEGF and angiogenin at first visit were observed to be significantly lower in infant group that showed progression ( $60 \pm 38$ ;  $2919 \pm 1467$  pg/mL) compared with the infant group that exhibited regression ( $146 \pm 65$ ;  $6905$

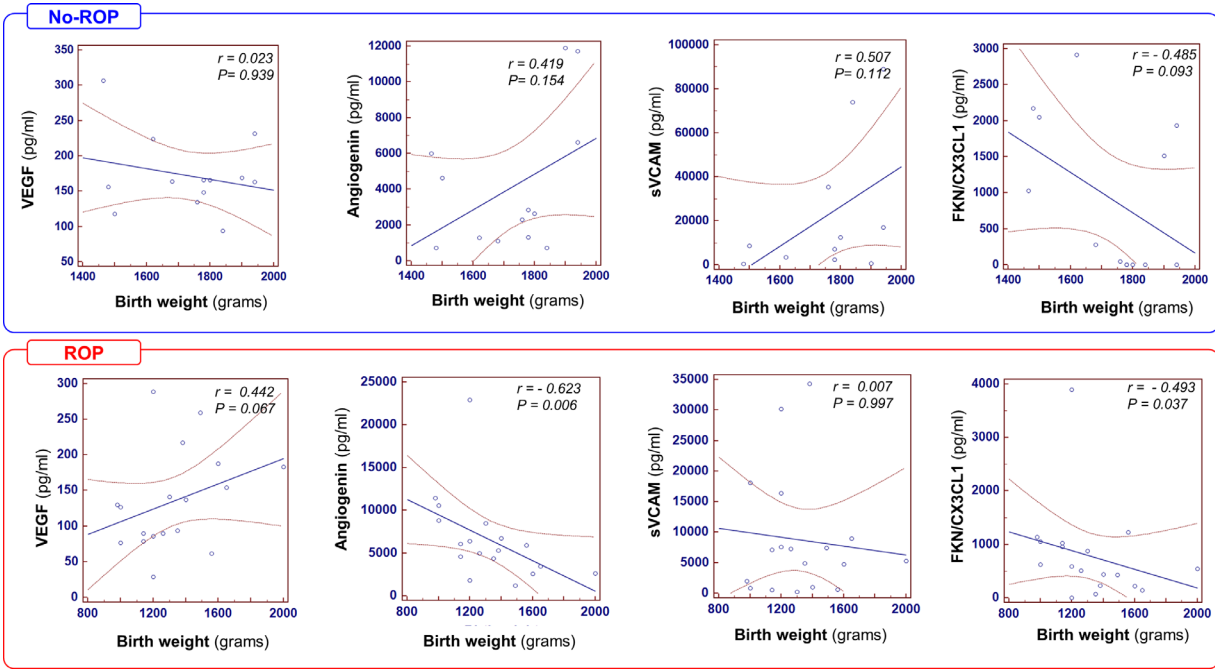


FIGURE 6. Association between tear fluid proangiogenic factors level and birth weight of preterm infants with and without ROP. The scatter diagram with regression line and 95% CI range indicates the correlation between tear fluid VEGF or angiogenin or sVCAM or FKN/CX3CL1 levels and BW in infants without ROP (top) and infants with ROP (bottom). r, Spearman rank correlation coefficient.  $P < 0.05$  is statistically significant. No-ROP ( $n = 13$ ); ROP ( $n = 18$ ).

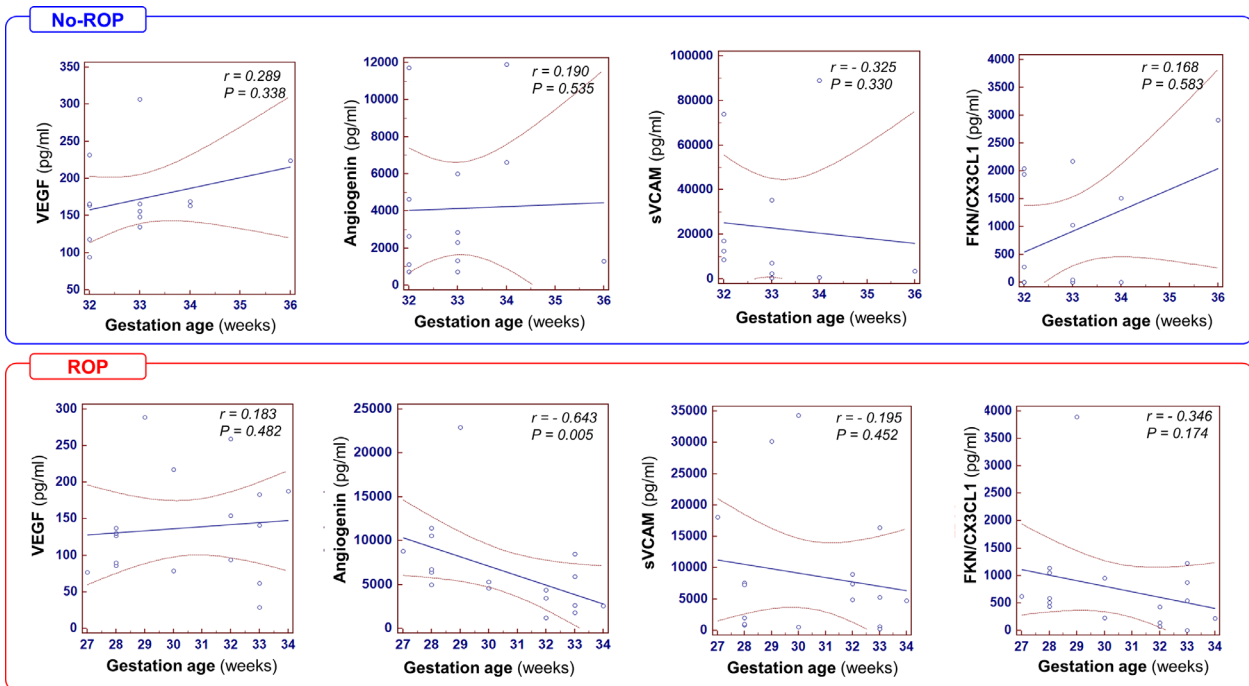
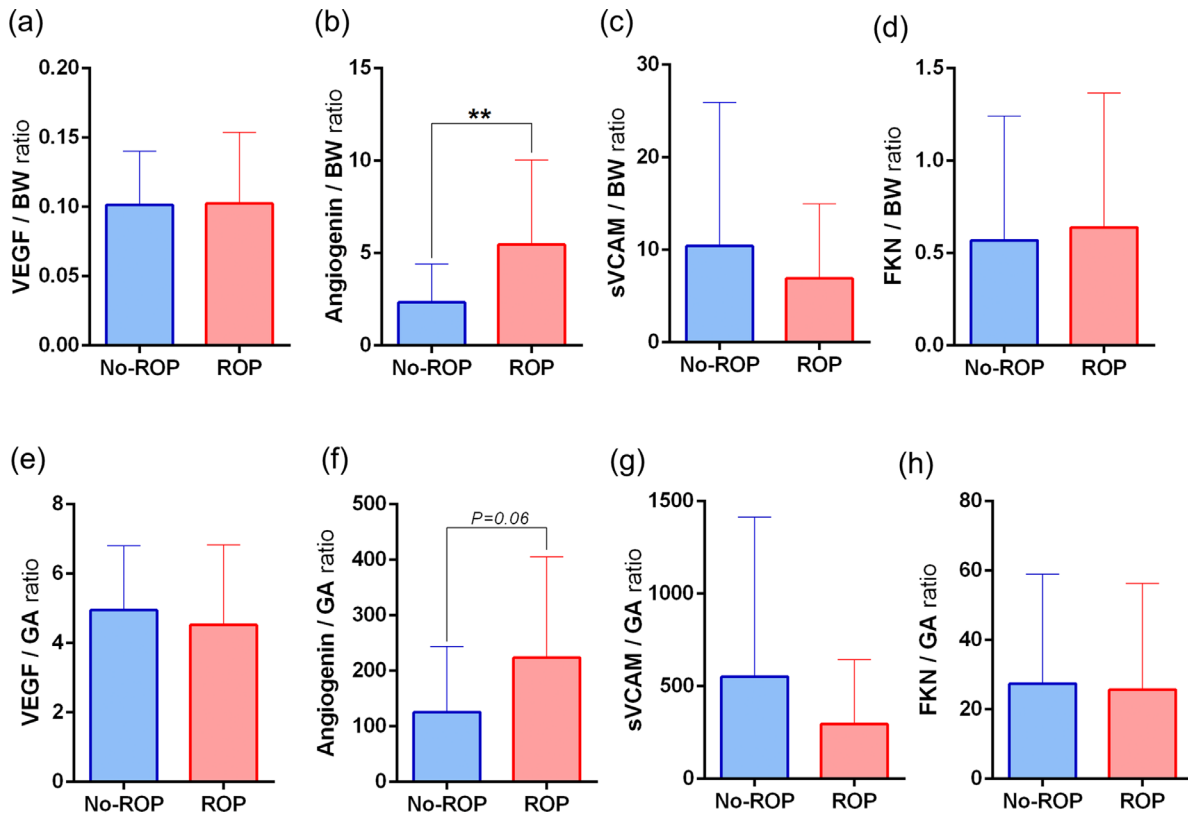


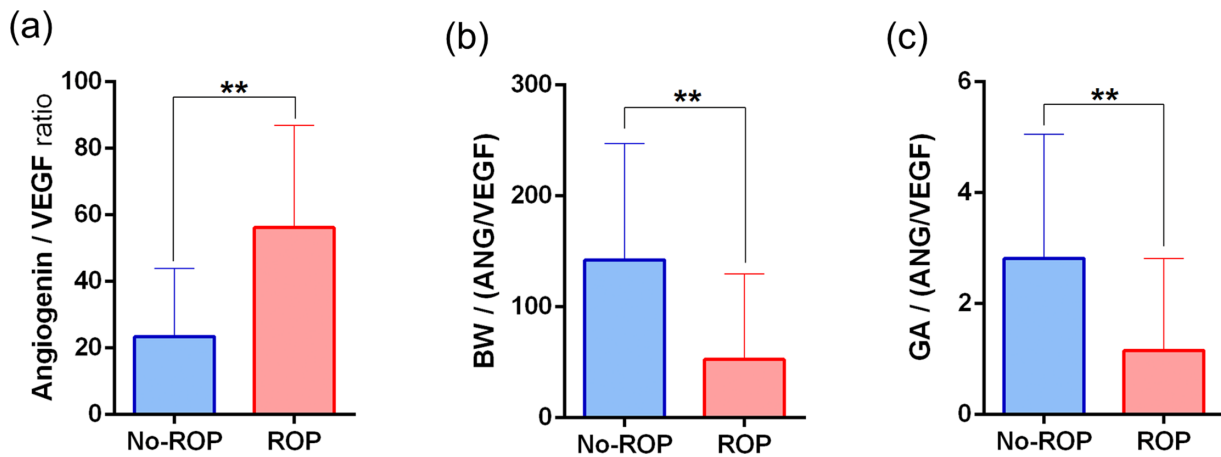
FIGURE 7. Association between tear fluid proangiogenic factors level and gestational age of preterm infants with and without ROP. The scatter diagram with regression line and 95% CI range indicates the correlation between tear fluid VEGF or angiogenin or sVCAM or FKN/CX3CL1 levels and GA in infants without ROP (top) and infants with ROP (bottom). r, Spearman rank correlation coefficient.  $P < 0.05$  is statistically significant. No-ROP ( $n = 13$ ); ROP ( $n = 18$ ).

$\pm 5139$  pg/mL), as shown in Figures 11a and b. Further, follow-up visits confirmed that all the infants with ROP at the

final visit recorded for the study exhibited either resolved, resolving toward a mature retina, or healing since the first



**FIGURE 8.** Relationship between tear fluid proangiogenic factors level and birth weight or gestational age of preterm infants with and without ROP. The graphs indicate the ratio of proangiogenic factor levels and birth weight or gestational age at first visit in preterm infants. Bar graphs indicate mean ratios of VEGF/birth weight (a), Angiogenin/birth weight (b), sVCAM/birth weight (c), FKN/birth weight (d), VEGF/gestational age (e), Angiogenin/gestational age (f), sVCAM/gestational age (g) and FKN/gestational age (h). Bar graphs indicate mean  $\pm$  standard deviation. \*\* $P < 0.01$ , Mann-Whitney test. No-ROP ( $n = 13$ ); ROP ( $n = 18$ ).

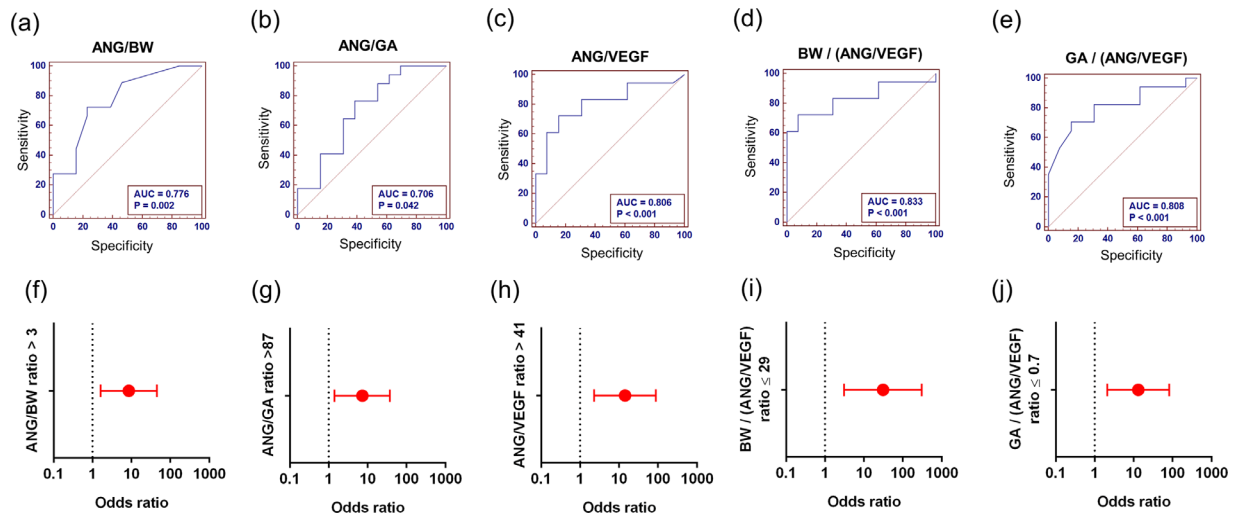


**FIGURE 9.** Relationship between tear fluid Angiogenin/VEGF ratio and BW or GA of preterm infants with and without ROP. The graphs indicate the ratio of angiogenin and VEGF levels (ANG/VEGF), and birth weight or gestational age at first visit in preterm infants. Bar graphs indicate mean ratios of Angiogenin/VEGF (a), birth weight/(ANG/VEGF) (b) and gestational age/(ANG/VEGF). Bar graphs indicate mean  $\pm$  standard deviation. \*\* $P < 0.01$ , Mann-Whitney test. No-ROP ( $n = 13$ ); ROP ( $n = 18$ ). ANG, angiogenin.

visit. It is important to reiterate that the final visit as shown in Figure 12 includes infants exhibiting normal retina to resolving stages of ROP and does not indicate the highest untreated disease stage. The levels of VEGF ( $P = 0.09$ ) and angiogenin ( $P < 0.001$ ) in the final visit ( $156 \pm 109$ ;  $10,346$

$\pm 7465$  pg/mL) were observed to be higher compared with first visit ( $120 \pm 70$ ;  $5692 \pm 4702$  pg/mL) in the ROP group (Figs. 12a and b). Interestingly, higher level of angiogenin was observed in the ROP ( $10,346 \pm 7465$  pg/mL) group compared with the No-ROP group ( $7882 \pm 9049$  pg/mL)





**FIGURE 10.** Diagnostic relevance of angiogenin and VEGF levels along with BW or GA in ROP. Graphs indicate ROC curve and OR analyses of angiogenin and VEGF levels along with BW or GA to differentiate preterm infants with and without ROP. ROC curves along with the AUC for angiogenin/birth weight (a), angiogenin/gestational age (b), angiogenin/VEGF (c), birth weight/(angiogenin/VEGF) (d), and gestational age/(angiogenin/VEGF) (e) are shown. The OR based on the optimal cut-off (indicated in the y-axis) determined by ROC analysis for angiogenin/birth weight (f), angiogenin/gestational age (g), angiogenin/VEGF (h), birth weight/(angiogenin/VEGF) (i), and gestational age/(angiogenin/VEGF) (j) are also shown. All OR graphs exhibited are statistically significant. No-ROP ( $n = 13$ ); ROP ( $n = 18$ ).

in the final visit samples ( $P = 0.07$ ) (Fig. 12b). Increased angiogenin was also observed in the final visit ( $7882 \pm 9049$  pg/mL) compared with the first visit ( $4139 \pm 3909$  pg/mL) in the No-ROP group ( $P = 0.05$ ) as well (Fig. 12b). In contrast, the levels of sVCAM in the final visit ( $12,561 \pm 16,390$ ;  $4157 \pm 6438$  pg/mL) were significantly lower compared with first visit ( $22,743 \pm 30,859$ ;  $8254 \pm 9088$  pg/mL) in both the No-ROP and the ROP groups (Fig. 12c). The findings from this study demonstrate the relevance of angiogenin and VEGF in ROP development, resolution, and maturing retina.

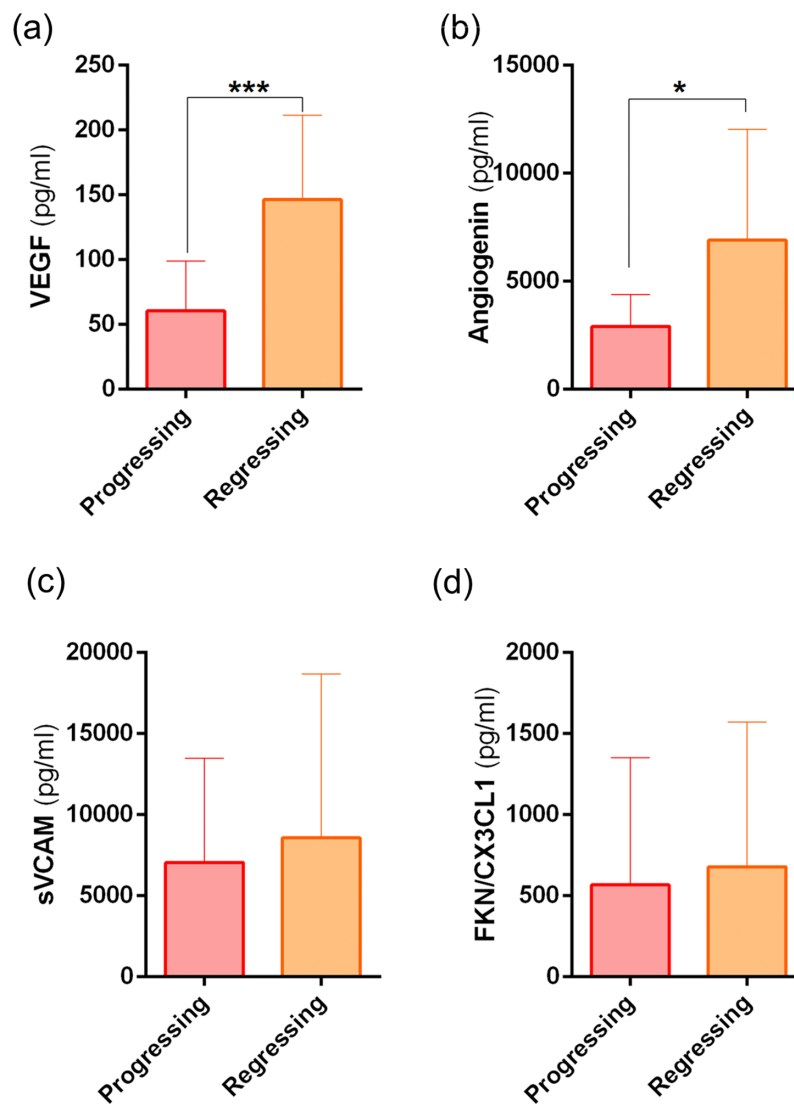
## DISCUSSION

A vast majority of the studies that investigated the status of proangiogenic factors in ocular tissues and fluids of ROP have been on advanced ROP that accurately reflected the proliferative phase of ROP. These findings have been a result of a more invasive collection of intraocular samples, such as the vitreous humor during surgery. However, the relevance of proangiogenic factors in ocular samples of infants with ROP, particularly those during the vaso-obliterative stages and in resolving stages of the disease, have been underexplored. This factor was primarily due to the unavailability of ocular samples. With the evolution of tear fluid as a reliable source in studying vascular conditions of the eye,<sup>39</sup> this lacuna has been addressed in the current study. Observation from the current study provide molecular evidence of post-natal vaso-obliterative process in preterm infants who developed ROP. We observed a decrease in tear fluid VEGF levels in preterm infants with ROP at first visit and in those who did not present with ROP at first screening but developed ROP in the subsequent visit, compared with preterm infants who did not develop ROP. The current observation is in concordance with the findings reported in animals exposed to oxygen-induced retinopathy, to model ROP.<sup>45–47</sup> Previously, studies have reported decreased serum VEGF or urine VEGF levels in infants that developed ROP and required active intervention.<sup>48–50</sup> Similarly, levels of serum BDNF and RANTES were

reported to be lower in infants who developed proliferative ROP compared with infants who did not develop ROP.<sup>51</sup> However, the mechanistic contribution of these factors to pathological angiogenesis in ROP is yet to be explored.

The current study also reports lower levels of VEGF in infants with ROP during progression of the disease and an increase in the levels of VEGF during resolution phase, indicating the need and self-regulation of angiogenic factors during physiological maturation of retinal vasculature in preterm infants. This finding is also in line with another study that reported no difference in the serum VEGF level between preterm infants without ROP and those with self-resolving ROP.<sup>48</sup> Further, the study also showed that the levels of serum VEGF increased over a month in preterm infants with self-resolving ROP, whereas the serum VEGF levels reduced in those preterm infants with ROP that required active intervention,<sup>48</sup> supporting the observation made in the current study with tear fluid VEGF levels.

Angiogenin was the first angiogenic factor to be isolated that was found to induce angiogenesis.<sup>52–55</sup> The angiogenic potency of angiogenin was greater than that for other angiogenic factors, such as VEGF, and they require angiogenin for their angiogenic activity.<sup>52,54,56</sup> The angiogenic activity of angiogenin is due to its ribonuclease activity, nuclear translocation, signal transduction, and ability to degrade basement membrane.<sup>57,58</sup> More recently, the angiogenic role of angiogenin was reported to be mediated by its interaction with cell surface receptors such as plexin-B2 and epidermal growth factor receptor.<sup>59–61</sup> Angiogenin is also reported to regulate number of physiological process including survival, proliferation, migration, invasion, and differentiation of cells.<sup>62–66</sup> Angiogenin is being considered as a biomarker for cancers and cardiovascular diseases.<sup>67</sup> Intraocular angiogenin levels were observed to be increased in AMD, diabetic retinopathy, polypoidal choroidal vasculopathy, and Coat's disease with retinal vascular abnormalities.<sup>27–30</sup> The status of angiogenin in infants with ROP in the current study is being reported for the first time and its



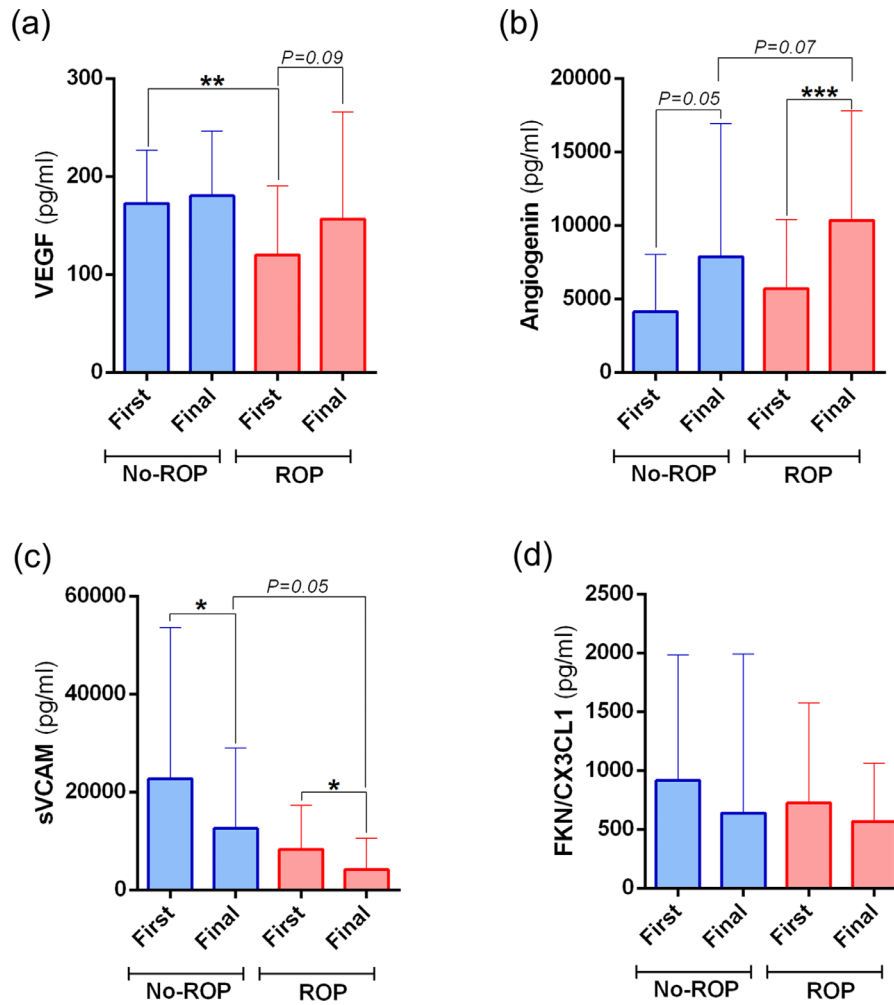
**FIGURE 11.** Proangiogenic factors level in the tear fluid of infants with ROP with different types of disease evolution. The graphs indicate the concentration of VEGF (a), angiogenin (b), sVCAM (c), and FKN/CX3CL1 (d) in the tear fluid of preterm infants at the first visit. Infants with ROP were categorized into two groups. The progressing group includes preterm infants who showed progression to a higher stage of disease as per the International Classification of Retinopathy of Prematurity classification in the second visit compared with the stage at first visit ( $n = 7$ ). The regressing group includes preterm infants who showed resolution to a lower stage of disease as per the International Classification of Retinopathy of Prematurity classification in the second visit compared with the stage at first visit ( $n = 16$ ). Bar graphs indicate mean  $\pm$  standard deviation. \* $P < 0.05$ , \*\*\* $P < 0.001$ , Mann-Whitney  $U$  test.

increase in ROP observed here is supported by its increase in an oxygen-induced retinopathy model.<sup>68</sup> Despite a positive association or positive regulatory relationship of angiogenin with VEGF and HIF1  $\alpha$ ,<sup>69-71</sup> a local imbalance between these two proangiogenic factors, that is, VEGF and angiogenin, has been reported in diabetic retinopathy.<sup>72,73</sup> These studies have shown higher levels of intraocular VEGF, but lower levels of angiogenin in patients with diabetic retinopathy compared with controls.<sup>72,73</sup> In the current study, we have observed a similar phenomenon in infants with ROP, although with an increase in angiogenin and a decrease in VEGF.

sVCAM, is another potent proangiogenic factor and have been implicated in pathological angiogenesis,<sup>74-76</sup> including neovascular AMD and proliferative diabetic retinopathy.<sup>31-35</sup> However, it was interesting to note that levels of sVCAM was

lower in infants with ROP compared with infants without ROP. It was also observed to be significantly lower in infants who had developed full vascularization when compared with when they had ROP.

FKN/CX3CL1 is a chemokine with potent proangiogenic properties and has been associated with pathological angiogenesis both in nonocular<sup>77-79</sup> and ocular diseases, such as the proliferative form of diabetic retinopathy and retinal vein occlusion.<sup>36,37</sup> It has been shown to mediate angiogenesis in oxygen-induced retinopathy model as well.<sup>36</sup> Nonetheless, no significant differences in its levels were observed in our patient cohort. These findings, along with another report,<sup>80</sup> suggest the need to further elucidate the role of VEGF and other proangiogenic factors and compensatory mechanisms underlying pathological angiogenesis in different forms of ROP.



**FIGURE 12.** Proangiogenic factors level in the tear fluid at first and final visits of preterm infants with and without ROP. The graphs indicate the concentration of VEGF (a), angiogenin (b), sVCAM (c), and FKN/CX3CL1 (d) in the tear fluid of preterm infants at first visit and final visit recorded in the study. The final visit was either the second, third, or fourth visit. The disease status at the final visit in all the preterm infants were either mature retina or resolving/healing between the first and final visits. Wilcoxon matched-pairs signed rank test was used to analyze the statistical significance between matched first and final visit sample in both the groups. The Mann-Whitney *U* test was used to analyze the statistical significance between the No-ROP and ROP groups. Bar graphs indicate mean  $\pm$  standard deviation. \**P* < 0.05, \*\**P* < 0.01, \*\*\**P* < 0.001, Mann-Whitney *U* test, Wilcoxon matched-pairs signed rank test. No-ROP first (*n* = 13), No-ROP final (*n* = 13), ROP first (*n* = 23), ROP final (*n* = 23).

It remains essential to predict and categorize preterm infants with the risk of developing ROP and infants with ROP with the risk of undesirable prognosis to provide early intervention and systemic factors modification as proposed<sup>6,7,81</sup> to mitigate disease development and progression. An interesting study reported a dose-specific decrease in the risk of ROP when treated early with recombinant human erythropoietin.<sup>82</sup> Such strategies would decrease the dependence on anti-VEGF in infants which is reported to have varying efficacy in the management of ROP<sup>24,25</sup> and also decreases serum VEGF<sup>83</sup> in a developing infant with unknown long-term consequences. Such screening, stratification, and early interventions in preterm and infants with ROP will yield benefits, especially those in remote areas with no access to tertiary care support. A noninvasive, tear-based, easy to perform molecular biomarkers test is one way to address this unmet need. In addition to the known risk factors such as BW, GA, and SpO<sub>2</sub> status, molecular biomarkers would refine the risk stratification process based

on the individual infant's response status. This information would particularly be useful in identifying preterm infants at risk when they fall outside the ROP screening criteria but develop ROP.<sup>84</sup>

The current study has demonstrated the capability of noninvasive molecular biomarker to differentiate preterm infants with and without ROP as a proof of concept. We demonstrate the usefulness of angiogenin levels adjusted to individual infant's BW or GA as a biomarker for ROP. In addition, the ratio between angiogenin and VEGF showed increased OR compared with angiogenin/BW and angiogenin/GA in the study. Further, factoring BW along with angiogenin/VEGF ratio demonstrated improved specificity and sensitivity in differentiation between preterm infants with ROP and preterm infants without ROP with an OR of 31 and AUC of 0.833. These findings suggest the diagnostic usefulness of the ratios based on tear fluid proangiogenic factors and clinical parameters during ROP screening in preterm infants. The key limitation in the

current pilot study is the limited number of patients, particularly in the No-ROP to ROP category. Despite this limitation, the study establishes the relevance and usefulness of tear fluid-based molecular biomarkers along with physiological parameters in the screening of preterm infants at risk of ROP. It would be necessary for more such studies using noninvasive ocular samples along with additional proangiogenic factors to be conducted across multiple centers, ethnicities, and screening platforms to validate the reliability of molecular biomarkers in ROP prediction and risk stratification. Furthermore, the identification of novel molecular factors that contribute to ROP pathogenesis could aid in the development of strategies to modulate them, which can improve ROP prognosis and prevent blindness in preterm infants.

### Acknowledgments

The authors thank the technical assistance by Priyanka Chevoor and Anupam Sharma, GROW Research lab, Narayana Nethralaya Foundation, Bangalore, India.

Funded by Narayana Nethralaya Foundation, Bangalore, India. The funders had no role in study design, data collection, and analysis.

Disclosure: **A. Vinekar**, None; **A.P. Nair**, None; **S. Sinha**, None; **T. Vaidya**, None; **K. Chakrabarty**, None; **R. Shetty**, None; **A. Ghosh**, None; **S. Sethu**, None

### References

- Hellstrom A, Smith LE, Dammann O. Retinopathy of prematurity. *Lancet*. 2013;382:1445–1457.
- Blencowe H, Lawn JE, Vazquez T, Fielder A, Gilbert C. Preterm-associated visual impairment and estimates of retinopathy of prematurity at regional and global levels for 2010. *Pediatr Res*. 2013;74(suppl 1):35–49.
- Sen P, Wu WC, Chandra P, Vinekar A, Manchegowda PT, Bhende P. Retinopathy of prematurity treatment: Asian perspectives. *Eye (Lond)*. 2020;34:632–642.
- Dutta S, Raghuvver T, Vinekar A, Dogra MR. Can we stop the current epidemic of blindness from retinopathy of prematurity? *Indian Pediatr*. 2016;53(suppl 2):S80–S84.
- Vinekar A, Jayadev C, Mangalesh S, Shetty B, Vidyasagar D. Role of tele-medicine in retinopathy of prematurity screening in rural outreach centers in India - a report of 20,214 imaging sessions in the KIDROP program. *Semin Fetal Neonatal Med*. 2015;20:335–345.
- Kim SJ, Port AD, Swan R, Campbell JP, Chan RVP, Chiang MF. Retinopathy of prematurity: a review of risk factors and their clinical significance. *Surv Ophthalmol*. 2018;63:618–637.
- Chan-Ling T, Gole GA, Quinn GE, Adamson SJ, Darlow BA. Pathophysiology, screening and treatment of ROP: a multidisciplinary perspective. *Prog Retin Eye Res*. 2018;62:77–119.
- Hartnett ME. Pathophysiology and mechanisms of severe retinopathy of prematurity. *Ophthalmology*. 2015;122:200–210.
- Hansen ED, Hartnett ME. A review of treatment for retinopathy of prematurity. *Expert Rev Ophthalmol*. 2019;14:73–87.
- Young TL, Anthony DC, Pierce E, Foley E, Smith LE. Histopathology and vascular endothelial growth factor in untreated and diode laser-treated retinopathy of prematurity. *J AAPOS*. 1997;1:105–110.
- Rathi S, Jalali S, Patnaik S, et al. Abnormal complement activation and inflammation in the pathogenesis of retinopathy of prematurity. *Front Immunol*. 2017;8:1868.
- Nath M, Chandra P, Halder N, et al. Involvement of renin-angiotensin system in retinopathy of prematurity - a possible target for therapeutic intervention. *PLoS One*. 2016;11:e0168809.
- Zhao M, Xie WK, Bai YJ, et al. Expression of total vascular endothelial growth factor and the anti-angiogenic VEGF 165 b isoform in the vitreous of patients with retinopathy of prematurity. *Chin Med J (Engl)*. 2015;128:2505–2509.
- Velez-Montoya R, Clapp C, Rivera JC, et al. Intraocular and systemic levels of vascular endothelial growth factor in advanced cases of retinopathy of prematurity. *Clin Ophthalmol*. 2010;4:947–953.
- Sato T, Kusaka S, Shimojo H, Fujikado T. Vitreous levels of erythropoietin and vascular endothelial growth factor in eyes with retinopathy of prematurity. *Ophthalmology*. 2009;116:1599–1603.
- Sato T, Kusaka S, Shimojo H, Fujikado T. Simultaneous analyses of vitreous levels of 27 cytokines in eyes with retinopathy of prematurity. *Ophthalmology*. 2009;116:2165–2169.
- Sonmez K, Drenser KA, Capone A, Jr., Trese MT. Vitreous levels of stromal cell-derived factor 1 and vascular endothelial growth factor in patients with retinopathy of prematurity. *Ophthalmology*. 2008;115:1065–1070 e1061.
- Sato T, Shima C, Kusaka S. Vitreous levels of angiopoietin-1 and angiopoietin-2 in eyes with retinopathy of prematurity. *Am J Ophthalmol*. 2011;151:353–357 e351.
- Sugioka K, Saito A, Kusaka S, Kuniyoshi K, Shimomura Y. Identification of vitreous proteins in retinopathy of prematurity. *Biochem Biophys Res Commun*. 2017;488:483–488.
- Mintz-Hittner HA, Kennedy KA, Chuang AZ, Group B-RC. Efficacy of intravitreal bevacizumab for stage 3+ retinopathy of prematurity. *N Engl J Med*. 2011;364:603–615.
- Stahl A, Lepore D, Fielder A, et al. Ranibizumab versus laser therapy for the treatment of very low birthweight infants with retinopathy of prematurity (RAINBOW): an open-label randomised controlled trial. *Lancet*. 2019;394:1551–1559.
- Popovic MM, Nichani P, Muni RH, Mireskandari K, Tehrani NN, Kertes PJ. Intravitreal anti-vascular endothelial growth factor injection versus laser photocoagulation for retinopathy of prematurity: a meta-analysis of 3701 eyes [published online ahead of print December 16, 2020]. *Surv Ophthalmol*. 2020, doi:10.1016/j.survophthal.2020.12.002.
- Sankar MJ, Sankar J, Mehta M, Bhat V, Srinivasan R. Anti-vascular endothelial growth factor (VEGF) drugs for treatment of retinopathy of prematurity. *Cochrane Database Syst Rev*. 2016;2:CD009734.
- Kandasamy Y, Hartley L, Rudd D, Smith R. The association between systemic vascular endothelial growth factor and retinopathy of prematurity in premature infants: a systematic review. *Br J Ophthalmol*. 2017;101:21–24.
- Kandasamy Y, Hartley L, Rudd D, Smith R. The lack of association between vascular endothelial growth factor and retinopathy of prematurity in an observational study. *J Matern Fetal Neonatal Med*. 2018;31:2202–2208.
- Martinez-Castellanos MA, Gonzalez HLA, Romo-Aguas JC, Gonzalez-Gonzalez LA. A proposal of an algorithm for the diagnosis and treatment of recurrence or treatment failure of retinopathy of prematurity after anti-VEGF therapy based on a large case series. *Graefes Arch Clin Exp Ophthalmol*. 2020;258:767–772.
- Skeie JM, Zeng S, Faidley EA, Mullins RF. Angiogenin in age-related macular degeneration. *Mol Vis*. 2011;17:576–582.
- Agawa T, Usui Y, Wakabayashi Y, et al. Profile of intraocular immune mediators in patients with age-related macular

- degeneration and the effect of intravitreal bevacizumab injection. *Retina*. 2014;34:1811–1818.
29. Zhang J, Jiang C, Ruan L, Huang X. Associations of cytokine concentrations in aqueous humour with retinal vascular abnormalities and exudation in Coats' disease. *Acta Ophthalmol*. 2019;97:319–324.
  30. Ozaki H, Hayashi H, Oshima K. Angiogenin levels in the vitreous from patients with proliferative diabetic retinopathy. *Ophthalmic Res*. 1996;28:356–360.
  31. Fauser S, Viebahn U, Muether PS. Intraocular and systemic inflammation-related cytokines during one year of ranibizumab treatment for neovascular age-related macular degeneration. *Acta Ophthalmol*. 2015;93:734–738.
  32. Toker E, Kazokoglu H, Sahin S. Cell adhesion molecules in subretinal fluid: soluble forms of VCAM-1 (vascular cell adhesion molecule-1) and L-selectin. *Int Ophthalmol*. 1998;22:71–76.
  33. Limb GA, Hickman-Casey J, Hollifield RD, Chignell AH. Vascular adhesion molecules in vitreous from eyes with proliferative diabetic retinopathy. *Invest Ophthalmol Vis Sci*. 1999;40:2453–2457.
  34. Barile GR, Chang SS, Park LS, Reppucci VS, Schiff WM, Schmidt AM. Soluble cellular adhesion molecules in proliferative vitreoretinopathy and proliferative diabetic retinopathy. *Curr Eye Res*. 1999;19:219–227.
  35. Hernandez C, Burgos R, Canton A, Garcia-Arumi J, Segura RM, Simo R. Vitreous levels of vascular cell adhesion molecule and vascular endothelial growth factor in patients with proliferative diabetic retinopathy: a case-control study. *Diabetes Care*. 2001;24:516–521.
  36. You JJ, Yang CH, Huang JS, Chen MS, Yang CM. Fractalkine, a CX3C chemokine, as a mediator of ocular angiogenesis. *Invest Ophthalmol Vis Sci*. 2007;48:5290–5298.
  37. Zeng Y, Cao D, Yu H, et al. Comprehensive analysis of vitreous chemokines involved in ischemic retinal vein occlusion. *Mol Vis*. 2019;25:756–765.
  38. Lyu J, Zhang Q, Jin H, et al. Aqueous cytokine levels associated with severity of type 1 retinopathy of prematurity and treatment response to ranibizumab. *Graefes Arch Clin Exp Ophthalmol*. 2018;256:1469–1477.
  39. Hagan S, Martin E, Enriquez-de-Salamanca A. Tear fluid biomarkers in ocular and systemic disease: potential use for predictive, preventive and personalised medicine. *EPMA J*. 2016;7:15.
  40. Vinekar A, Gilbert C, Dogra M, et al. The KIDROP model of combining strategies for providing retinopathy of prematurity screening in underserved areas in India using wide-field imaging, tele-medicine, non-physician graders and smart phone reporting. *Indian J Ophthalmol*. 2014;62:41–49.
  41. Project operational guidelines. Prevention of blindness from retinopathy of prematurity in neonatal care units. Available at: <https://phfi.org/wp-content/uploads/2019/05/2018-ROP-operational-guidelines.pdf>. Accessed 2019.
  42. International Committee for the Classification of Retinopathy of Prematurity. The International Classification of Retinopathy of Prematurity revisited. *Arch Ophthalmol*. 2005;123:991–999.
  43. Early Treatment For Retinopathy Of Prematurity Cooperative G. Revised indications for the treatment of retinopathy of prematurity: results of the early treatment for retinopathy of prematurity randomized trial. *Arch Ophthalmol*. 2003;121:1684–1694.
  44. Khamar P, Nair AP, Shetty R, et al. Dysregulated tear fluid nociception-associated factors, corneal dendritic cell density, and vitamin D levels in evaporative dry eye. *Invest Ophthalmol Vis Sci*. 2019;60:2532–2542.
  45. Alon T, Hemo I, Itin A, Pe'er J, Stone J, Keshet E. Vascular endothelial growth factor acts as a survival factor for newly formed retinal vessels and has implications for retinopathy of prematurity. *Nat Med*. 1995;1:1024–1028.
  46. Pierce EA, Foley ED, Smith LE. Regulation of vascular endothelial growth factor by oxygen in a model of retinopathy of prematurity. *Arch Ophthalmol*. 1996;114:1219–1228.
  47. Zhao M, Shi X, Liang J, et al. Expression of pro- and anti-angiogenic isoforms of VEGF in the mouse model of oxygen-induced retinopathy. *Exp Eye Res*. 2011;93:921–926.
  48. Kwinta P, Bik-Multanowski M, Mitkowska Z, Tomasik T, Pietrzyk JJ. The clinical role of vascular endothelial growth factor (VEGF) system in the pathogenesis of retinopathy of prematurity. *Graefes Arch Clin Exp Ophthalmol*. 2008;246:1467–1475.
  49. Yenice O, Cerman E, Ashour A, et al. Serum erythropoietin, insulin-like growth factor 1, and vascular endothelial growth factor in etiopathogenesis of retinopathy of prematurity. *Ophthalmic Surg Lasers Imaging Retina*. 2013;44:549–554.
  50. Levesque BM, Kalish LA, Winston AB, et al. Low urine vascular endothelial growth factor levels are associated with mechanical ventilation, bronchopulmonary dysplasia and retinopathy of prematurity. *Neonatology*. 2013;104:56–64.
  51. Hellgren G, Willett K, Engstrom E, et al. Proliferative retinopathy is associated with impaired increase in BDNF and RANTES expression levels after preterm birth. *Neonatology*. 2010;98:409–418.
  52. Fett JW, Strydom DJ, Lobb RR, et al. Isolation and characterization of angiogenin, an angiogenic protein from human carcinoma cells. *Biochemistry*. 1985;24:5480–5486.
  53. Riordan J. Angiogenin. In: Meyers RA, editor. *Encyclopedia of Molecular Biology*. New York: Wiley-Blackwell; 2001.
  54. Kishimoto K, Liu S, Tsuji T, Olson KA, Hu G-f. Endogenous angiogenin in endothelial cells is a general requirement for cell proliferation and angiogenesis. *Oncogene*. 2005;24:445–456.
  55. Tsuji T, Sun Y, Kishimoto K, et al. Angiogenin is translocated to the nucleus of HeLa cells and is involved in ribosomal RNA transcription and cell proliferation. *Cancer Res*. 2005;65:1352–1360.
  56. King TV, Vallee BL. Neovascularisation of the meniscus with angiogenin. An experimental study in rabbits. *Bone Joint J*. 1991;73:587–590.
  57. Gao X, Xu Z. Mechanisms of action of angiogenin. *Acta Biochim Biophys Sin*. 2008;40:619–624.
  58. Sheng J, Xu Z. Three decades of research on angiogenin: a review and perspective. *Acta Biochim Biophys Sin (Shanghai)*. 2016;48:399–410.
  59. Yu W, Goncalves KA, Li S, et al. Plexin-B2 mediates physiologic and pathologic functions of angiogenin. *Cell*. 2017;171:849–864 e825.
  60. Wang YN, Lee HH, Chou CK, et al. Angiogenin/ribonuclease 5 is an EGFR ligand and a serum biomarker for erlotinib sensitivity in pancreatic cancer. *Cancer Cell*. 2018;33:752–769 e758.
  61. Amin DN, Hida K, Bielenberg DR, Klagsbrun M. Tumor endothelial cells express epidermal growth factor receptor (EGFR) but not ErbB3 and are responsive to EGF and to EGFR kinase inhibitors. *Cancer Res*. 2006;66:2173–2180.
  62. Subramanian V, Crabtree B, Acharya KR. Human angiogenin is a neuroprotective factor and amyotrophic lateral sclerosis associated angiogenin variants affect neurite extension/pathfinding and survival of motor neurons. *Human Mol Genet*. 2008;17:130–149.
  63. Sebastia J, Kieran D, Breen B, et al. Angiogenin protects motoneurons against hypoxic injury. *Cell Death Differ*. 2009;16:1238–1247.

64. Wei S, Gao X, Du J, Su J, Xu Z. Angiogenin enhances cell migration by regulating stress fiber assembly and focal adhesion dynamics. *PLoS One*. 2011;6:e28797.
65. Cho G-W, Kang BY, Kim SH. Human angiogenin presents neuroprotective and migration effects in neuroblastoma cells. *Mol Cell Biochem*. 2010;340:133–141.
66. Jones ML, Ewing CM, Isaacs WB, Getzenberg RH. Prostate cancer-derived angiogenin stimulates the invasion of prostate fibroblasts. *J Cell Mol Med*. 2012;16:193–201.
67. Yu D, Cai Y, Zhou W, Sheng J, Xu Z. The potential of angiogenin as a serum biomarker for diseases: systematic review and meta-analysis. *Dis Markers*. 2018;2018:1984718.
68. Lee YM, Lee YR, Kim CS, et al. Cnidium officinale extract and butylidenephthalide inhibits retinal neovascularization in vitro and in vivo. *BMC Complement Altern Med*. 2016;16:231.
69. Forooghian F, Das B. Anti-angiogenic effects of ribonucleic acid interference targeting vascular endothelial growth factor and hypoxia-inducible factor-1alpha. *Am J Ophthalmol*. 2007;144:761–768.
70. Abdel-Rahman AM, el-Sahrigy SA, Bakr SI. A comparative study of two angiogenic factors: vascular endothelial growth factor and angiogenin in induced sputum from asthmatic children in acute attack. *Chest*. 2006;129:266–271.
71. Kishimoto K, Yoshida S, Ibaragi S, et al. Hypoxia-induced up-regulation of angiogenin, besides VEGF, is related to progression of oral cancer. *Oral Oncol*. 2012;48:1120–1127.
72. Yu Y, Zhang J, Zhu R, et al. The profile of angiogenic factors in vitreous humor of the patients with proliferative diabetic retinopathy. *Curr Mol Med*. 2017;17:280–286.
73. Marek N, Raczynska K, Siebert J, et al. Decreased angiogenin concentration in vitreous and serum in proliferative diabetic retinopathy. *Microvasc Res*. 2011;82:1–5.
74. Byrne GJ, Ghellal A, Iddon J, et al. Serum soluble vascular cell adhesion molecule-1: role as a surrogate marker of angiogenesis. *J Natl Cancer Inst*. 2000;92:1329–1336.
75. Parra ER, Silverio da Costa LR, Ab'Saber A, et al. Nonhomogeneous density of CD34 and VCAM-1 alveolar capillaries in major types of idiopathic interstitial pneumonia. *Lung*. 2005;183:363–373.
76. Fukushi J, Ono M, Morikawa W, Iwamoto Y, Kuwano M. The activity of soluble VCAM-1 in angiogenesis stimulated by IL-4 and IL-13. *J Immunol*. 2000;165:2818–2823.
77. Marchica V, Toscani D, Corcione A, et al. Bone marrow CX3CL1/fractalkine is a new player of the pro-angiogenic microenvironment in multiple myeloma patients. *Cancers (Basel)*. 2019;11(3):321.
78. Skoda M, Stangret A, Szukiewicz D. Fractalkine and placental growth factor: a duet of inflammation and angiogenesis in cardiovascular disorders. *Cytokine Growth Factor Rev*. 2018;39:116–123.
79. Ryu J, Lee CW, Hong KH, et al. Activation of fractalkine/CX3CR1 by vascular endothelial cells induces angiogenesis through VEGF-A/KDR and reverses hindlimb ischaemia. *Cardiovasc Res*. 2008;78:333–340.
80. Xiang N, Zhao MJ, Li XY, Zheng HH, Li GG, Li B. Redundant mechanisms for vascular growth factors in retinopathy of prematurity in vitro. *Ophthalmic Res*. 2011;45:92–101.
81. Gaynon MW. Rethinking STOP-ROP: is it worthwhile trying to modulate excessive VEGF levels in prethreshold ROP eyes by systemic intervention? A review of the role of oxygen, light adaptation state, and anemia in prethreshold ROP. *Retina*. 2006;26:S18–23.
82. Suk KK, Dunbar JA, Liu A, et al. Human recombinant erythropoietin and the incidence of retinopathy of prematurity: a multiple regression model. *JAAPOS*. 2008;12:233–238.
83. Sato T, Wada K, Arahori H, et al. Serum concentrations of bevacizumab (Avastin) and vascular endothelial growth factor in infants with retinopathy of prematurity. *Am J Ophthalmol*. 2012;153:327–333 e321.
84. Romo-Aguas JC, Gonzalez HLA, Meraz-Gutierrez MP, Martinez-Castellanos MA. Retinopathy of prematurity: incidence report of outliers based on international screening guidelines. *Int J Retina Vitreous*. 2019;5:53.