



Open Access

LETTER TO THE EDITOR

Prostate Disease

Multiparametric magnetic resonance imaging/transrectal ultrasound fusion prostate biopsy with semi-robotic navigation in the Chinese population: initial results

Wai Kit Ma¹, Brian SH Ho¹, Andrew SH Lai², Ka Cheong Lam², Yun Sang Chan¹, Lawrance KC Yip², Ada TL Ng¹, James HL Tsu¹, Ming Kwong Yiu¹

Asian Journal of Andrology (2018) 20, 93–94; doi: 10.4103/1008-682X.196855; published online: 21 March 2017

Dear Editor,

The current standard 12-core systematic transrectal ultrasound (TRUS)-guided biopsy in prostate cancer diagnosis has the disadvantages of overdetecting indolent tumors, while failing to identify clinically significant cancers in up to 35%.¹ Advances in imaging techniques, notably the multiparametric magnetic resonance imaging (mpMRI), allow clinically significant prostate cancers to be detected with more precise localization.² Fusion of MRI and real-time TRUS enables targeted biopsy of suspicious lesions, overcoming human error, and inability of biopsy site tracking in cognitive fusion.³ Multiple Western series have suggested a higher detection rate, higher specificity, and better risk stratification with fusion biopsy.^{4–8} Study on the Chinese population, however, is sparse. We report the initial results of the first prospective study on mpMRI/US fusion-guided prostate biopsy in a Chinese population using the Artemis™ (Eigen, Grass Valley, CA, USA) platform, an elastic fusion device dedicated for prostate biopsy. Its distinctive features include elastic registration of MRI and TRUS images, probe stabilization with a semi-robotic navigation arm, and patient movement compensation, allowing accurate 3D modeling and lesion tracking.^{4,5} The ethics approval was obtained and a matched comparison analysis was performed with the systematic 12-core biopsy method.

From July 2015 to April 2016, all men with elevated serum prostate-specific antigen (PSA) level of 4–20 ng ml⁻¹ were counseled for prebiopsy mpMRI of the prostate or conventional systematic TRUS biopsy. MRI prostate was performed with 1.5T MRI scanner (MAGNETOM Aera; Siemens Healthcare, Erlangen, Germany), using a combination of 18-channel phase array body coil and 32-channel spine array coil.

All mpMRI were independently reviewed by a panel of three experienced genitourinary radiologists, with suspicious lesions

defined according to the Prostate Imaging – Reporting and Data System (PI-RADS) version 2 published in 2015.⁹ There were five PI-RADS assessment categories (1–5) correlating with probability of having significant cancer. The software Profuse (Eigen, Grass Valley, CA, USA) was used to outline the contour of the prostate and any PI-RADS 2–5 lesions. The Digital Imaging and Communication in Medicine data sets were then imported into the Artemis workstation for fusion with real-time TRUS images (**Figure 1**). TRUS with power Doppler was performed using an F37 with semi-Compound Pulse Wave Generator (Hitachi Aloka Medical, Tokyo, Japan) equipped with a UST-676P 3.0–7.5 MHz end-fire transrectal probe, under regional periprostatic block with 1% lignocaine (10 ml). Patients with any PI-RADS 2–5 lesions underwent a targeted biopsy (1–3 cores from each lesion depending on lesion size) and template 12-core biopsy (an extended sextant template from the lateral and medial aspects of the base, mid, and apical prostate bilaterally). Clinically significant cancers were defined as pathologic Gleason grade $\geq 3 + 4$, or 3 + 3 with a maximum cancer core length more than 4 mm. All biopsy slides were reviewed by two genitourinary histopathologists of over 10 years' experience.

A total of seventy patients underwent prebiopsy mpMRI in the period. Two non-Chinese ethnic patients were excluded. Among the 68 eligible patients, 57 (83.8%) had positive MRI findings with a total of 98 PI-RADS 2–5 lesions (average 1.7 ± 1.0 lesions per patient) depicted. The mean age was 66.2 ± 6.8 years and mean prebiopsy PSA was 8.5 ± 3.7 ng ml⁻¹. A matched cohort of 250 patients undergoing conventional systematic biopsy was included for comparison. All 11 MRI-negative patients had no prostate cancer detected on systematic biopsy. The cancer detection rates (CDRs) for PI-RADS 2–5 lesions were 0% (0/33), 11.4% (4/35), 29.2% (7/24), and 50.0% (3/6), respectively, with 92.9% (13/14) of the detected cancers being clinically significant cancers. Regarding the lesion location, 65.3% (64/98) and 34.7% (34/98) of the lesions were in the peripheral and transition zones, respectively, with no statistically significant difference in CDR for both zones (14.7% vs 14.1%, $P = 0.5$). In cohort comparison analysis, the overall CDR was significantly higher in the fusion biopsy (targeted + 12-core) group than the conventional biopsy group (33.3% vs 17.6%, $P = 0.01$). While targeted biopsy alone

¹Division of Urology, Department of Surgery, The University of Hong Kong, Queen Mary Hospital, Hong Kong, China; ²Department of Diagnostic Radiology, The University of Hong Kong, Queen Mary Hospital, Hong Kong, China.

Correspondence: Dr. MK Yiu (pmkyiu@gmail.com)

Received: 15 September 2016; Revised: 27 October 2016;

Accepted: 12 December 2016

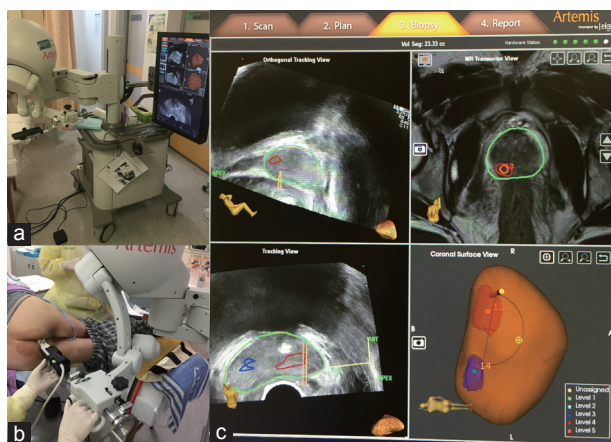


Figure 1: (a) The Artemis elastic fusion platform. (b) An example shows a PIRADS 3 lesion at the left peripheral base and a PIRADS 4 lesion at the right peripheral base of the prostate in a fusion biopsy patient. (c) During the biopsy procedure, the ultrasound probe is docked to the robot-like mechanical arm with encoders (angle-sensing devices) within each joint for tracking of probe position. After fusion of MR images with real-time TRUS images, target lesions will show up as areas of interests in the three-dimensional prostate model. MR: magnetic resonance imaging; TRUS: transrectal ultrasound.

did not increase overall CDR (19.3% vs 17.6%, $P = 0.85$), it detected significantly more Gleason 7 tumors (17.5% vs 8.0%, $P = 0.04$) and apparently more clinically significant cancers than conventional biopsy (19.3% vs 10.4%, $P = 0.06$). The mean cancer core length in targeted biopsy was significantly longer than that in conventional biopsy (5.8 ± 4.2 mm vs 3.6 ± 3.1 mm, $P = 0.03$). The overall complication rates for hematuria, retention of urine, and sepsis were similar for both fusion and conventional biopsy groups (12.3% vs 20.4%, $P = 0.19$). Only one patient (1.8%) in the fusion biopsy cohort developed sepsis requiring hospital care.

Our early results suggest that mpMRI and MRI/TRUS fusion technique is promising in improving diagnostic yield of prostate biopsy in the Chinese population. First, the excellent specificity of mpMRI for negative imaging and PI-RADS 2 lesions in our cohort (negative predictive value of 100%) suggests that mpMRI can be a risk-stratification tool in selecting patients for biopsy, avoiding unnecessary biopsies. From our results, 27 of 68 patients (39.7%) having negative imaging ($n = 11$) or PI-RADS 2 lesions only ($n = 16$) could have saved from biopsy with minimal risk of missing prostate cancer. In a Caucasian study using the same fusion platform, Wysock *et al.*¹⁰ evaluated 125 patients with 172 MRI lesions and found that 18.6% of low-equivocal suspicion lesions yielded prostate cancer, with 5.3% (6) being Gleason ≥ 7 cancers only. In our cohort, PI-RADS 3 lesions had positive predictive value of 11.4%, but with 75.0% (3/4) yielded clinically significant cancers, suggesting that we should not omit biopsy for PI-RADS 3 lesions in the Chinese population.

Another potential of the fusion technique is its ability to achieve equivalent or superior detection of clinically significant cancers

with less over-detection of clinically insignificant cancers. In our series, targeted biopsy alone missed 15.4% (2/13) of clinically significant tumors and could have avoided detection of 100% (6/6) of insignificant tumors. With high concordance of targeted lesions with significant pathological findings, targeted biopsies can play a more specific role in avoiding over-detection of insignificant cancers. This study is ongoing and with larger case number and it is hoped that more concrete conclusion can be made.

AUTHOR CONTRIBUTIONS

WKM and MKY conceived the idea of the study. WKM, BSHH, and LKCY participated in its design. ASHL, KCL, and LKCY reviewed all mpMRI and contoured the target lesions. WKM and BSHH performed all fusion biopsy procedures. WKM and YSC collected the clinical and pathologic data. WKM performed statistical analysis and drafted the manuscript. BSHH, LKCY, ATLN, and JHLT revised the manuscript. MKY supported and supervised the project. All authors read and approved the final manuscript.

COMPETING INTERESTS

All authors declared no competing interests.

REFERENCES

- Ellis WJ, Braver MK. The significance of isoechoic prostatic carcinoma. *J Urol* 1994; 152 (6 Pt 2): 2304–7.
- Turkbey B, Pinto PA, Mani H, Bernardo M, Pang Y, *et al.* Prostate cancer: value of multiparametric MR imaging at 3 T for detection-histopathologic correlation. *Radiology* 2010; 255: 89–99.
- Marks L, Young S, Natarajan S. MRI-ultrasound fusion for guidance of targeted prostate biopsy. *Curr Opin Urol* 2013; 23: 43–50.
- Sonn GA, Margolis DJ, Marks LS. Target detection: magnetic resonance imaging-ultrasound fusion-guided prostate biopsy. *Urol Oncol* 2014; 32: 903–11.
- Natarajan S, Marks LS, Margolis DJ, Huang J, Macairan ML, *et al.* Clinical application of a 3D ultrasound-guided prostate biopsy system. *Urol Oncol* 2011; 29: 334–42.
- Pinto PA, Chung PH, Rastinehad AR, Baccala AA Jr, Kruecker J, *et al.* Magnetic resonance imaging/ultrasound fusion guided prostate biopsy improves cancer detection following transrectal ultrasound biopsy and correlates with multiparametric magnetic resonance imaging. *J Urol* 2011; 186: 1281–5.
- Vourganti S, Rastinehad A, Yerram NK, Nix J, Volkin D, *et al.* Multiparametric magnetic resonance imaging and ultrasound fusion biopsy detect prostate cancer in patients with prior negative transrectal ultrasound biopsies. *J Urol* 2012; 188: 2152–7.
- Fiard G, Hohn N, Descotes JL, Rambeaud JJ, Troccaz J, *et al.* Targeted MRI-guided prostate biopsies for the detection of prostate cancer: initial clinical experience with real-time 3-dimensional transrectal ultrasound guidance and magnetic resonance/transrectal ultrasound image fusion. *Urology* 2013; 81: 1372–8.
- Weinreb JC, Barentsz JO, Choyke PL, Cornud F, Haider MA, *et al.* PI-RADS Prostate Imaging – Reporting and Data System: 2015, version 2. *Eur Urol* 2016; 69: 16–40.
- Wysock JS, Rosenkrantz AB, Huang WC, Stifelman MD, Lepor H, *et al.* A prospective, blinded comparison of magnetic resonance (MR) imaging-ultrasound fusion and visual estimation in the performance of MR-targeted prostate biopsy: the PROFUS trial. *Eur Urol* 2014; 66: 343–51.

This is an open access article distributed under the terms of the Creative Commons Attribution-NonCommercial-ShareAlike 3.0 License, which allows others to remix, tweak, and build upon the work non-commercially, as long as the author is credited and the new creations are licensed under the identical terms.

©The Author(s)(2017)