

## Pulmonary Actinomycosis Associated with Endobronchial Vegetable Foreign Body

Jong Hyun Baek, M.D., Jang Hoon Lee, M.D., Myeong Su Kim, M.D., Jung Cheul Lee, M.D.

A 51-year-old woman visited our hospital with massive hemoptysis. She had suffered from recurrent hemoptysis for five years and had undergone bronchial artery embolization many times. The patient had a history of pulmonary tuberculosis and bronchiectasis. Chest radiography showed consolidation around the nodule in the lateral basal segment of the right lower lobe. We successfully performed a right lower lobectomy. The histological study of the resected specimen showed a vegetable foreign body and clumps of *Actinomyces*, indicating actinomycosis, which was suggested to be the cause of the hemoptysis. This was a very rare case of hemoptysis caused by a vegetable foreign body and actinomycosis.

Key words: 1. Lung infection  
2. Lung surgery  
3. Foreign body  
4. Actinomycosis

### CASE REPORT

In December 2011, a 51-year-old woman was admitted to our hospital due to massive hemoptysis. The patient was a nurse. She had suffered from recurrent hemoptysis for five years and had undergone bronchial artery embolization many times. The patient had a history of pulmonary tuberculosis and bronchiectasis. The patient's vital signs were stable. On chest examination, decreased breathing sound and crackle were audible in the right lower lung field. Laboratory parameters were within normal limits. A chest X-ray showed patchy consolidation in the right lower lung (Fig. 1A). A computed tomography scan of the chest showed a small nodule, ground glass appearance, and consolidation around the nodule in the lateral basal segment of the right lower lobe (Fig. 1B).

We performed an operation for the differential diagnosis between the possibility of a malignancy or life-threatening, massive hemoptysis. Under general anesthesia with a double lumen endotracheal tube, we resected the right lower lobe through a posterolateral thoracotomy at the sixth intercostal space. In the operation field, a dense pleural adhesion was observed on the entire surface of the lung. We could palpate a round, hard mass 2.0×3.0 cm in the lateral basal segment of the right lower lobe. The resected specimen consisted of the right lower lobe, weighed 177.5 g, and was sized 11.5×11.2×3.0 cm. On multiple serial sections, a cavity lesion measuring approximately 2.0×2.5 cm was identified (Fig. 2A). Foreign material was identified in the cavity (Fig. 2B). Histopathological examination confirmed it to be a vegetable foreign body, and clumps of *Actinomyces*, indicating actinomycosis, were pres-

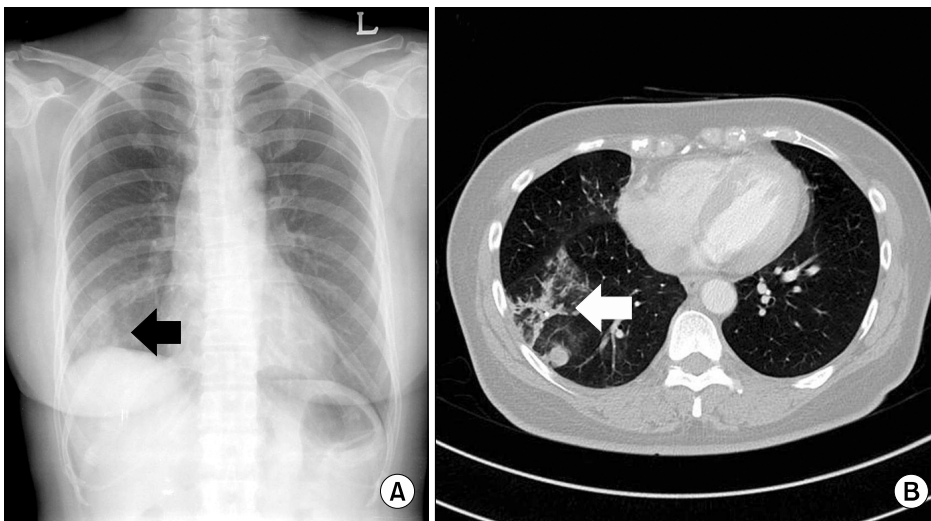
Department of Thoracic and Cardiovascular Surgery, Yeungnam University College of Medicine

Received: June 16, 2014, Revised: August 6, 2014, Accepted: August 7, 2014, Published online: December 5, 2014

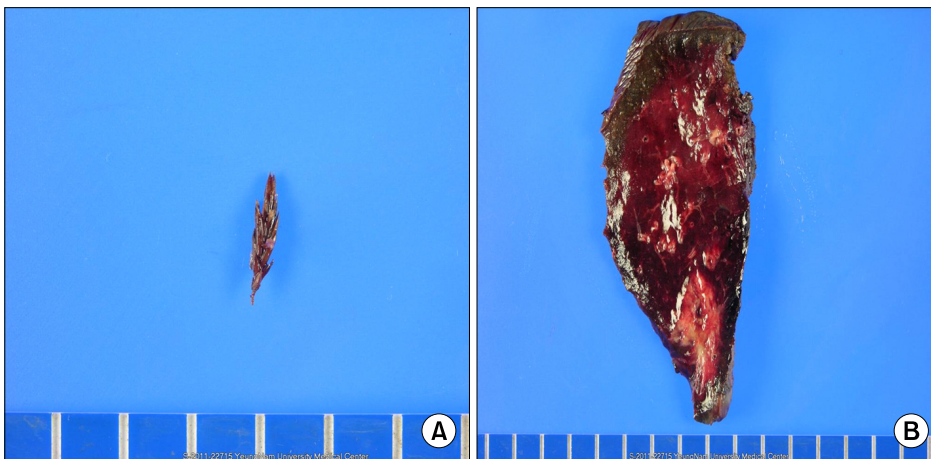
Corresponding author: Jang Hoon Lee, Department of Thoracic and Cardiovascular Surgery, Yeungnam University College of Medicine, 170 Hyeonchung-ro, Nam-gu, Daegu 705-717, Korea  
(Tel) 82-53-620-3885 (Fax) 82-53-626-8660 (E-mail) [heartljh@yumail.ac.kr](mailto:heartljh@yumail.ac.kr)

© The Korean Society for Thoracic and Cardiovascular Surgery. 2014. All rights reserved.

© This is an open access article distributed under the terms of the Creative Commons Attribution Non-Commercial License (<http://creativecommons.org/licenses/by-nc/3.0>) which permits unrestricted non-commercial use, distribution, and reproduction in any medium, provided the original work is properly cited.



**Fig. 1.** Radiologic studies of the patient. (A) A chest X-ray showed patchy consolidation in the right lower lobe. (B) Chest computed tomography showed a right lower lobe nodule with bronchiectasis.



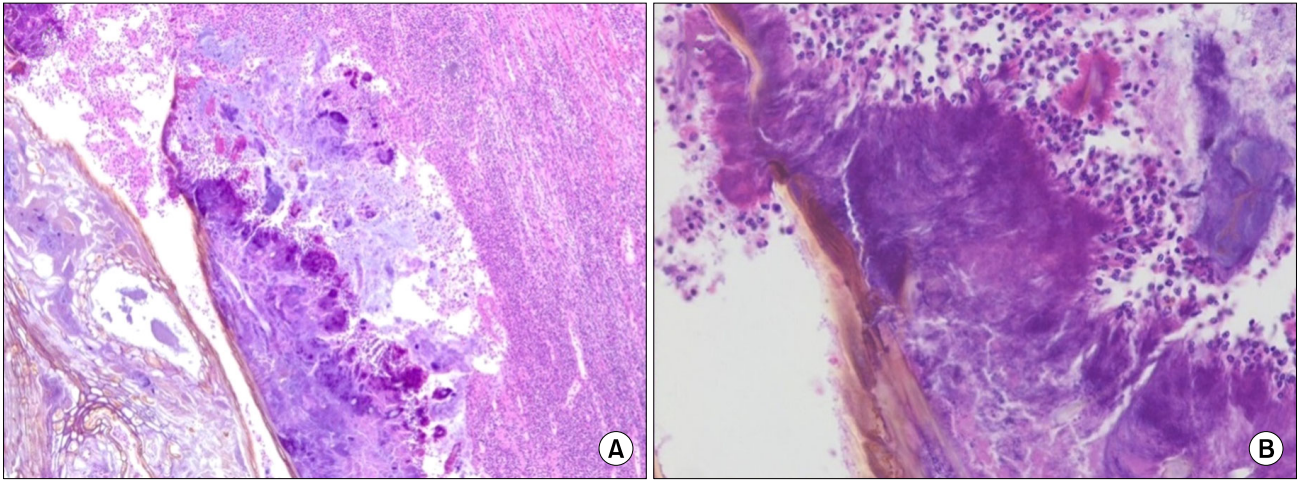
**Fig. 2.** (A) The vegetable foreign body and (B) resected specimen (right lower lobe).

ent within the abscess cavity (Fig. 3). She was discharged on the twelfth postoperative day without any complications. Two years after surgery, she was healthy and free of recurrence.

## DISCUSSION

Actinomycosis is a chronic, suppurative pulmonary infection usually caused by *Actinomyces israelii*, which is present in the oropharynx of humans. Pulmonary infection with species of *Actinomyces* is uncommon, and usually results from aspiration of oropharyngeal secretions in those with chronic dental infections, extension from a cervicofacial infection, or hematogenous spread from a distant source [1]. Bronchial involvement, a rare form of thoracic actinomycosis,

has been reported to be associated with foreign bodies. The first report of endobronchial pulmonary actinomycosis induced by a foreign body was the case of a Spanish patient in 1991, when a chicken bone was aspirated [2]. According to Chouabe et al. [3], eleven cases of pulmonary actinomycosis secondary to endobronchial foreign body aspiration have been described. Most cases have occurred in middle-aged males with known risk factors such as a chronic debilitated state and poor dentition. Most patients did not remember their choking spells. The main symptoms include cough, fever, expectoration of yellow pus, chest pain, and weight loss. Chest computed tomography shows a thickened bronchial wall, dense pulmonary alveolar opacity, atelectasis, pleural effusion, bronchiectasis, lymphadenopathy, or a radiopaque foreign



**Fig. 3.** (A) The granules are surrounded by a purulent exudate (H&E,  $\times 40$ ). (B) The filaments are clearly visible (H&E,  $\times 400$ ).

body. *Actinomyces* tend to colonize and subsequently invade the tissue surrounding the foreign body. Obstructive endoluminal masses have been found on bronchoscopy, but the actual foreign bodies are not easily detected in some cases [3,4]. In the present case, the patient was a middle-aged female and did not have poor dentition. We had no information on an episode of aspiration before the operation. Usually the foreign body is likely to have become a host for subsequent *Actinomyces* contamination once the patient had developed poor dentition. Mucosal breaches secondary to foreign body impaction must occur for *Actinomyces* species to colonize and cause a marked granulomatous inflammatory reaction [5]. Pulmonary actinomycosis associated with a vegetable foreign material is extremely rare. We could find only one case of pulmonary actinomycosis induced by a vegetable foreign body [6]. Our case represents a very rare pathogenesis of pulmonary actinomycosis, which is an important disease in the differential diagnosis of a pulmonary mass.

#### CONFLICT OF INTEREST

No potential conflict of interest relevant to this article was reported.

#### REFERENCES

1. Kinneer WJ, MacFarlane JT. *A survey of thoracic actinomycosis*. Respir Med 1990;84:57-9.
2. Julia G, Rodriguez de Castro F, Caminero J, Rey A, Cabrera P. *Endobronchial actinomycosis associated with a foreign body*. Respiration 1991;58:229-30.
3. Chouabe S, Perdu D, Deslee G, Milosevic D, Marque E, Lebarry F. *Endobronchial actinomycosis associated with foreign body: four cases and a review of the literature*. Chest 2002;121:2069-72.
4. Ariel I, Breuer R, Kamal NS, Ben-Dov I, Mogel P, Rosenmann E. *Endobronchial actinomycosis simulating bronchogenic carcinoma: diagnosis by bronchial biopsy*. Chest 1991;99:493-5.
5. Kim TS, Han J, Koh WJ, et al. *Endobronchial actinomycosis associated with broncholithiasis: CT findings for nine patients*. AJR Am J Roentgenol 2005;185:347-53.
6. Kurai M, Yamada T, Koyama S, Tunoda T, Gono H. *A case of hemoptysis caused by vegetable foreign body (cryptomeria) and actinomycosis*. Nihon Kogyoku Gakkai Zasshi 2002;40:915-8.