

Even Experts Can Be Fooled: Reliability of Clinical Examination for Diagnosing Hip Dislocations in Newborns

Philip Harper, BMBS,† Brijil M. Joseph, BMedSc,*† Nicholas M.P. Clarke, FRCS,*†
Jose Herrera-Soto, MD,‡ Wudbhav N. Sankar, MD,§ Emily K. Schaeffer, PhD,||
Kishore Mulpuri, FRCSC,|| Alexander Aarvold, FRCS,*†
for International Hip Dysplasia Institute (IHDI)*

Background: The aim of this study was to assess the accuracy of clinical screening examination in newborns with dislocated hips compared with ultrasound scan (USS).

Methods: Newborns, up to 3 months of age, with confirmed hip dislocations on USS were prospectively enrolled in a multinational observational study. Data from 2010 to 2016 were

reviewed to determine pretreatment clinical examination findings of the treating orthopaedic surgeon as well as baseline ultrasound indices of developmental dysplasia of the hip (DDH). All infants had been referred to specialist centres with expertise in DDH, due to abnormal birth examination or risk factor.

Results: The median age of the study population was 2.3 weeks and 84% of patients were female. Of the total 515 USS-confirmed

From the *Department of Paediatric Orthopaedic Surgery, Southampton Children's Hospital; †University of Southampton, Southampton, UK; ‡Arnold Palmer Hospital Centre for Orthopaedics, Orlando, FL; §Children's Hospital of Philadelphia, Philadelphia, PA; and ||BC Children's Hospital, Vancouver, BC, Canada.

International Hip Dysplasia Study Group, Orlando, FL: Kishore Mulpuri, MBBS, MS(Ortho), MHSc(Epi), FRCSC. Department of Orthopaedic Surgery, BC Children's Hospital, Vancouver, BC. Emily Schaeffer, PhD, Department of Orthopaedic Surgery, BC Children's Hospital, Vancouver, BC. Anthony Cooper, MBChB, FRCS (Tr&Ortho), Department of Orthopaedic Surgery, BC Children's Hospital, Vancouver, BC. Nicole Williams, MD, Women's and Children's Hospital, North Adelaide, Australia, Centre for Orthopaedic and Trauma Research, University of Adelaide, Australia. Travis Matheny, MD, MBA, Department of Orthopaedic Surgery, Boston Children's Hospital, Boston, MA. Harry Kim, MD, Department of Orthopaedic Surgery, Texas Scottish Rite Hospital, Dallas, Texas. Jose Herrera-Soto, MD, Department of Orthopaedic Surgery, Arnold Palmer Health Center, Orlando, FL. Wudbhav Sankar, MD, Department of Orthopaedic Surgery, Children's Hospital of Philadelphia, Philadelphia, PA. Vidyadhar Upasani, MD, Department of Orthopaedic Surgery, Rady Children's Hospital, San Diego, CA. Simon Kelley, MD, Department of Orthopaedic Surgery, The Hospital for Sick Children, Toronto, ON. Nicholas Clarke, MD, Department of Orthopaedic Surgery, University of Southampton, Southampton, UK. Alexander Aarvold, MD, Department of Orthopaedic Surgery, University of Southampton, Southampton, UK. Charles Price, MD, Department of Orthopaedic Surgery, Arnold Palmer Health Center, Orlando, FL. Leo Donnan, MD, Murdoch Children's Research Institute, Royal Children's Hospital, University of Melbourne, Melbourne, Australia. Emily Dodwell, MD, MPH, FRCSC, Hospital for Special Surgery, Weill Cornell Medical College, New York, NY. Pablo Castaneda, MD, New York University Hospital for Joint Diseases, New York University, New York, NY. Alaric Aroojis, MBBS, MS(Ortho), DNB(Ortho), Department of Pediatric Orthopaedics, Bai Jerbai Wadia Hospital for Children, Mumbai, Maharashtra, India. Hitesh Shah, MBBS, MS(Ortho), DNB(Ortho), Kasturba Medical College, Manipal, Karnataka, India. Venkatadass Krishnamoorthy, MBBS, MS(Ortho), DNB(Ortho), Ganga Medical Centre & Hospitals Pvt Ltd, Coimbatore, India. Sandeep Patwardhan, MBBS, MS(Ortho), DOrth, Sancheti Institute, Pune, India. Chittaranjan Sahu, MBBS, MS(Ortho), Balaji Institute of Surgery, Research and Rehabilitation for the Disabled, Tirupati, India. Jianping Yang, MD, Department of Pediatric Orthopaedics, Tianjin Hospital, Tianjin, China. Edward Bache, MD, Department of Orthopaedics, Birmingham Children's Hospital, Birmingham, UK. Jacob Jaremko, MD, PhD, FRCPC, Department of Radiology and Diagnostic Imaging University of Alberta Hospital/Stollery Children's Hospital, Edmonton, AB. Sukhdeep K. Dulai, MD, BSc, MHSc, FRCSC, Pediatric Orthopaedic Surgery, University of Alberta/Stollery Children's Hospital Edmonton, AB. Ge Yihua, MD, Department of Pediatric Orthopaedics, Shanghai Children's Medical Center, Shanghai Jiao Tong University School of Medicine, Shanghai, China. Thierry Benaroch, BSc, MSc, MDCM, FRCSC, FAAOS, Department of Orthopaedic Surgery, Shriners Hospitals for Children—Canada, Montreal, QC. David Bade, BSc, MBBS, FRACS, Department of Orthopaedic Surgery, Queensland Children's Hospital Brisbane, Queensland. Stephanie Pun, MD, Department of Orthopaedic Surgery, The Stanford Child & Adult Hip Preservation Center, Stanford, CA.

P.H.: Study design, analysis, interpretation, drafting, final approval, agreement of accountability. B.M.J.: Study design, analysis, interpretation, drafting, final approval, agreement of accountability. N.M.P.C.: Study conception, acquisition, drafting, final approval, agreement of accountability. J.H.-S.: Study conception, acquisition, drafting, final approval, agreement of accountability. W.N.S.: Study conception, design, acquisition, analysis, interpretation, drafting, final approval, agreement of accountability. E.K.S.: Study design, final approval, agreement of accountability. K.M.: Study design, final approval, agreement of accountability. International Hip Dysplasia Institute (IHDI): Study conception, design, acquisition, analysis, interpretation, drafting, final approval, agreement of accountability. A.A.: Study conception, design, acquisition, analysis, interpretation, drafting, final approval, agreement of accountability.

Supported by the prospective registry was established with funding from the IHDI.

The authors declare no conflicts of interest.

Reprints: Alexander Aarvold, FRCS, Department of Children's Orthopaedics, Southampton Children's Hospital, University Hospital Southampton NHS Trust, Tremona Road, Southampton, SO16 6YD, UK. E-mail: alexander.aarvold@uhs.nhs.uk.

Copyright © 2020 The Author(s). Published by Wolters Kluwer Health, Inc. This is an open-access article distributed under the terms of the Creative Commons Attribution-Non Commercial-No Derivatives License 4.0 (CCBY-NC-ND), where it is permissible to download and share the work provided it is properly cited. The work cannot be changed in any way or used commercially without permission from the journal.

DOI: 10.1097/BPO.0000000000001602

dislocated hips included in the study, 71 (13.8%) were incorrectly felt to be reduced on clinical examination by the treating orthopaedist ($P < 0.001$). Full hip abduction was documented in 106 hips. Of the hips correctly identified as dislocated, 322 hips were further analyzed based on clinical reducibility. Thirty-three of 322 (10.2%) were incorrectly thought to be reducible when in fact they were irreducible or vice versa.

Conclusions: Expert examiners missed a significant number of frankly dislocated hips on clinical examination and their ability to classify hips based on clinical reducibility was only moderately accurate. This study provides evidence that, even in experienced hands, physical examination findings in DDH are often too subtle to elicit clinically in the first few months of life. This may explain the persistent and measurable rate of late presenting dislocations in countries with screening programmes reliant on clinical examination.

Level of Evidence: Level 1—testing of previously developed diagnostic criteria in series of consecutive patients (with universally applied reference “gold” standard).

Key Words: developmental dysplasia of the hip, ultrasound, clinical examination, screening

(*J Pediatr Orthop* 2020;40:408–412)

Developmental dysplasia of the hip (DDH) encompasses a spectrum of hip instability ranging from acetabular dysplasia in a reduced stable hip to frank dislocation which is reducible or irreducible.¹ It is the most common paediatric hip condition, with 1% to 3% of all newborns diagnosed in infancy.² If diagnosed early, harnesses and splints are highly effective treatments.³ However, those diagnosed late often require surgery to achieve a reduced stable hip, with increased health care costs and worse outcomes than harness treatment in infancy.⁴

For this reason, screening programmes exist in many parts of the world. The United Kingdom and United States share a very similar national screening programme, which includes physical examination of every infant at birth and at 6 weeks of age, by assessing discrepancies in limb length, asymmetric thigh or gluteal folds as well as performing Ortolani and Barlow tests. An ultrasound scan (USS) of the infant hip is performed selectively at 2 weeks of age on those with abnormalities detected on perinatal physical examination, or at 6 weeks of age for those with normal examination but with specified risk factors, for example, first degree family history of DDH, breech presentation after 36 weeks' gestation or presence of other packaging disorders. The staged USS is to allow for spontaneous resolution of physiological perinatal hip instability and therefore prevent over-treatment. The Australian screening programme relies more on clinical examination and the Austrian and German programmes involve a universal USS.⁵ The lack of a universal definition of DDH makes it difficult to ascertain an exact incidence, however, in the United States it is believed to be around 1 in 1000 live births.⁶ In the United Kingdom, the incidence of DDH diagnosed late, that is, above 1 year

old, was calculated at 1.28 per 1000 births despite the selective USS screening programme.⁷ This compares to 0.16 per 1000 births in European countries that employ universal USS screening.⁸

The rationale behind clinical examination screening (with selective USS) is based on the expectation that if a hip is dislocated in a newborn (either at birth or at secondary check in the first few months of life), the clinical signs should be detected by the Ortolani/Barlow tests or reduced hip abduction. This is why late detected cases are often successfully litigated.⁹ At rest, a newborn's hip may be dislocated or dislocatable. A dislocatable hip should theoretically elicit a positive Barlow test and a dislocated hip, if reducible, should elicit a positive Ortolani test. Neither test identifies an irreducible dislocated hip, for which, the only clinical sign may be limited abduction. It remains unclear why the late detection rate remains high despite, as in the United Kingdom and North America, successful implementation of universal clinical examination screening. It is unknown whether this is due to the signs being missed by health care practitioners or whether the clinical signs are not evident in these cases. Although some evidence exists on the poor positive predictive value of clinical signs,¹⁰ there is a dearth of evidence on the accuracy of these tests, upon which national screening policies are based. This study compares, for the first time in the literature, the clinical findings of experienced examiners with the gold standard in DDH diagnosis, namely USS. This study has focused solely on those hips that are dislocated, that is, the hips that are expected to be identified on clinical examination.

METHODS

Data Source

This is a prospective multinational observational study of hips dislocated at rest (REC09/HO502/88), established in 2010 to address the lack of high quality data and evidence available to guide practitioners in managing DDH with regards to optimal screening, diagnosis and management. Data was obtained from multiple centres in the United States, United Kingdom, Australia, and Canada. Patients with known or suspected neuromuscular, collagen or chromosomal abnormalities are not included.

Inclusion/Exclusion Criteria

The prospectively collected database of infantile DDH was queried for patients meeting the following criteria: (a) below 3 months old at baseline visit to a paediatric orthopaedic surgeon between 2010 and 2016; (b) confirmed dislocation on USS. It is widely accepted that a dislocated hip is one with a positive Ortolani sign, that is, dislocated at rest but reducible. A recent large multicentre study found that >90% of Ortolani positive hips within their cohort had femoral head coverage (FHC) of $\leq 33\%$.¹¹ Given the degree of subjectivity when measuring percentage FHC, and the mobility/instability of many of these hips, the baseline level of <30% FHC at rest was used for this study. Patients were excluded if data was incomplete or a teratological cause of

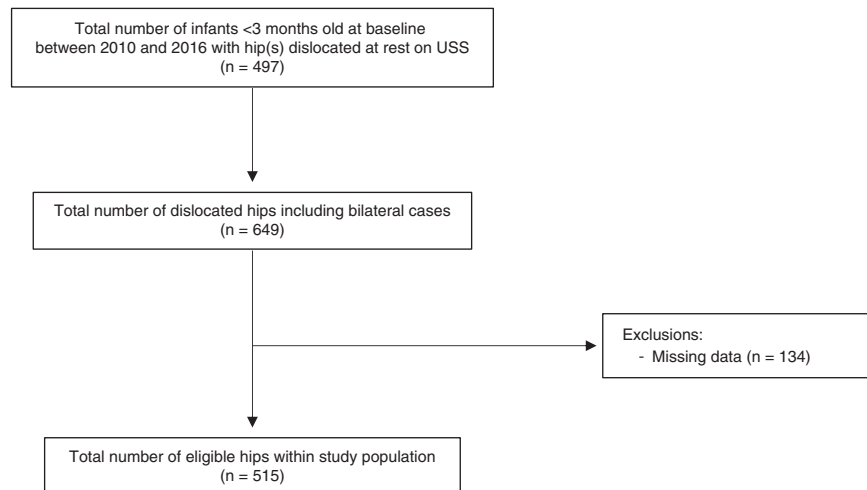


FIGURE 1. Flow chart demonstrating inclusion/exclusion criteria.

the dislocation was present (Fig. 1). All hips were examined by an “expert” examiner following referral for abnormal birth examination or risk factor, according to the respective local and national protocol. The “expert” was a consultant paediatric orthopaedic surgeon with a specialist interest in DDH, to whom the referral had been made, or a team member under their direct supervision. Data was entered into the database by the treating physician. Clinical examination was standardised across each centre and encompassed femoral head location, that is, dislocated or reduced, joint reducibility (based on the Ortolani test), and finally degree of hip abduction (measured with the hips flexed). Specifics of USS parameters were % FHC/location, sonographic stability and reducibility and alpha angles.^{8–10} The pretreatment examination findings were compared with the subsequent USS findings of the same hip with regards to femoral head location and clinical reducibility. Further subanalysis was performed based on the degree of hip abduction.

Statistical Analysis

Clinical examination findings regarding femoral head location were compared with USS using the Binomial test. Cohen kappa statistic was used to measure agreement between reducibility on clinical examination and USS in those where femoral head location was correctly identified as dislocated on clinical examination. The Mann-Whitney *U* test was carried out to compare the distribution of hip abduction between hips classified as clinically reduced and dislocated. Frequency analyses were applied to percentage FHC and alpha angles. Statistical analyses were undertaken using IBM SPSS statistics (version 25; IBM Corp., Armonk, NY) and Microsoft Excel (version 15.16; Microsoft, Redmond, WA).

RESULTS

A total of 649 hips in 497 patients were deemed eligible based on their age and date of baseline visit. One

hundred thirty-four hips (21%) were excluded due to clinical examination findings not being adequately documented, leaving 515 USS-confirmed dislocated newborn hips (in 385 patients) for analysis. Figure 2 demonstrates the patient count per geographical region.

Baseline Demographics

Of the 515 USS-confirmed dislocated hips, 145 (28%) were right-sided, 240 (47%) left-sided, and 130 (25%) were bilateral dislocations. The median age was 2.3 weeks (range: 0 to 13 wk) and 84% of patients were female. Median % FHC was 4.5% (interquartile range=15.5, range: 0% to 30%), with a mean alpha-angle of 42 ± 9.0 degrees.

Femoral Head Location

All 515 hips were examined by experienced paediatric orthopaedic surgeons or under their direct supervision. Of these, 71 (14%) were incorrectly classified as reduced on clinical examination (Table 1), 25 of which were thought to be dislocatable. This included 4 cases of bilateral dislocations. Four hundred forty-four hips (86%) were correctly identified as dislocated. Using the binomial test, the observed proportion of dislocated hips on clinical examination was 0.86 (86%, 444/515) and the expected proportion was 1.00 (100%—as all hips were dislocated on USS) ($P < 0.001$).

Clinical Reducibility

Of the 444 hips where dislocation was correctly identified on clinical examination, data regarding clinical reducibility was available for 322 hips. A total of 33 cases (10.2%) were incorrectly thought to be reducible when in fact they were irreducible or vice versa (Table 2). The clinical agreement of reducibility compared with USS results was substantial (Cohen κ statistic=0.615, $P < 0.001$).

Hip Abduction

The median hip abduction (in flexion) in the group of hips thought to be clinically reduced was 71 degrees (range: 20 to 90 degrees) and in the group thought to be clinically

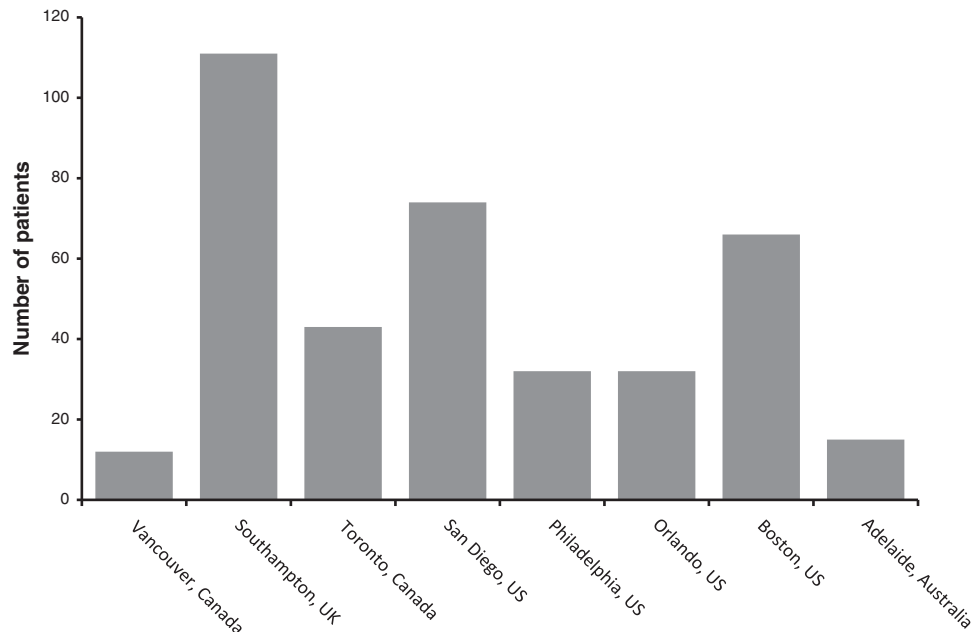


FIGURE 2. Eligible patients sorted by geographical region.

dislocated was 63 degrees (range: 10 to 90 degrees) ($P < 0.001$, Mann-Whitney U test). Notably, the hip abduction was ≥ 80 degrees in 106 hips (20.1%), indicating normal abduction despite the hip being in a frank dislocated position.

DISCUSSION

This study investigated the accuracy of clinical examination of newborn hips that are dislocated at rest. To our knowledge this is the first study that has prospectively explored this aspect of DDH practice, despite many national screening programmes being reliant on this examination. The hip was incorrectly identified as reduced in 14% of dislocated hips, by experienced examiners. Most of these were unilateral cases which, in theory, should be easier to detect on clinical examination than bilateral cases. This confirms a level of inaccuracy, even in expert hands, of this screening test. In clinical environments, the majority of baseline newborn physical examinations are not performed by “experts,” which may increase the proportion of dislocated hips which are missed on newborn clinical examination.¹²

It is interesting to note that hip abduction (in flexion) of 80 to 90 degrees was found in 106 dislocated hips (20%). This study confirms that clinical examination of the infant hip can be entirely normal even in the presence of frank hip dislocation. There is therefore no clinical screening

technique, even in experienced hands, that could detect a proportion of newborn hip dislocations.

In those cases where the hip was correctly diagnosed as dislocated on clinical examination, reducibility had a similar level of inaccuracy (10.2%). This further questions the utility of clinical examination without the aid of ultrasound. The Ortolani maneuver only tests whether a dislocated hip is reducible and so dislocated irreducible hips can be easily missed.

The most notable limitation of this study is the missing documentation of clinical findings in 134 hips, which forced this number to be excluded. Data included in this study is from the inception of the international database, whereby some early data was incomplete, in keeping with the early learning curve of a multinational study group. Despite this being a prospective study, it is observational and not formally blinded nor randomized. As such, clinicians may in some instances have had knowledge of the USS result before performing their clinical examination. Any such potential bias would have falsely elevated the accuracy of clinical examination. Therefore, the misdiagnosis rate of 14% is likely to be an underestimation of the true value.

TABLE 1. Femoral Head Location (ie, Reduced or Dislocated) on Clinical Examination Versus Ultrasound (n = 515)

	Femoral Head Location on Clinical Examination		
	Reduced	Dislocated	Total
Femoral head location on ultrasound			
Dislocated	71	444	515

TABLE 2. Hip Reducibility Findings on Clinical Examination Versus Ultrasound, for Those Hips Correctly Clinically Identified as Dislocated (n = 322)

	Hip Reducibility on Clinical Examination		
	Reducible	Irreducible	Total
Hip reducibility on ultrasound			
Reducible	255	26	281
Irreducible	7	34	41
Total	262	60	322

Hip abduction was not measured using a goniometer and clinical accuracy is somewhat limited. Exact abduction values are useful for research purposes however clinical practice simply requires an appreciation for restricted movement. Some dislocated hips were missed clinically despite having documentation of restricted abduction. This reinforces that reduced hip abduction, even in isolation and in newborns, deserves more attention during clinical examination. This study did not include subluxed hips or those with stable dysplasia, which may have even more subtle clinical findings, yet are still associated with morbidity if untreated. Further work should assess the agreement between USS and clinical examination across the entire spectrum of infant hip dysplasia—not just those with confirmed hip dislocation.

This study has confirmed, for the first time in the literature, that even experienced examiners have difficulty in diagnosing whether a newborn hip is reduced or dislocated. Clinical signs of DDH in newborns can be subtle or absent even in the presence of frank hip dislocation. The optimal screening method for DDH is yet to be sought, but this study questions the utility of relying on clinical examination alone to guide further investigation.

ACKNOWLEDGMENTS

The authors thank the International Hip Dysplasia Study Group for compiling the multinational data and for providing input on the final manuscript. They would also like to acknowledge the funding received from the International Hip Dysplasia Institute (IHDI), I'm a HIPpy Foundation, Pediatric Orthopaedic Society of North America (POSNA) Registry Grant, and Canadian Orthopaedic Foundation.

REFERENCES

1. International Hip Dysplasia Institute (IHDI) Study Group, Schaeffer EK, Mulpuri K. International Hip Dysplasia Institute (IHDI) Study Group. Developmental dysplasia of the hip: addressing the evidence gaps with a multi-centre prospective international study. *Med J Aus.* 2018;208:359–364.
2. Sewell MD, Rosendahl K, Eastwood DM. Developmental dysplasia of the hip. *BMJ.* 2009;339:b4454.
3. Cashman JP, Round J, Taylor G, et al. The natural history of developmental dysplasia of the hip after early supervised treatment in the Pavlik harness. A prospective, longitudinal follow-up. *J Bone Joint Surg Br.* 2002;84:418–425.
4. Terjesen T. Residual hip dysplasia as a risk factor for osteoarthritis in 45 years follow-up of late-detected hip dislocation. *J Child Orthop.* 2011;5:425–431.
5. Ihme N, Altenhofen L, von Kries R, et al. Hip ultrasound screening in Germany. Results and comparison with other screening procedures. *Orthopade.* 2008;37:541–546.
6. Shaw BA, Segal LS. Evaluation and referral for developmental dysplasia of the hip in infants. *Pediatrics.* 2016;138:e20163107.
7. Broadhurst C, Rhodes AML, Harper P, et al. What is the incidence of late detection of developmental dysplasia of the hip in England? *Bone Joint J.* 2019;101-B:281–287.
8. Christoph T, Renata P, Rudolf G, et al. Long-term results of a nationwide general ultrasound screening system for developmental disorders of the hip: the Austrian Hip Screening Program. *J Child Orthop.* 2014;8:3–10.
9. Atrey A, Nicolau N, Katchburian M, et al. A review of reported litigation against English health trusts for the treatment of children in orthopaedics: present trends and suggestions to reduce mistakes. *J Child Orthop.* 2010;4:471–476.
10. Paton RW. Screening in developmental dysplasia of the hip (DDH). *Surgeon.* 2017;15:290–296.
11. Striano B, Schaeffer EK, Matheney TH, et al. Ultrasound characteristics of clinically dislocated but reducible hips with DDH. *J Pediatr Orthop.* 2017;39:453–457.
12. Reidy M, Collins C, MacLean JGB, et al. Examining the effectiveness of examination at 6–8 weeks for developmental dysplasia: testing the safety net. *Arch Dis Child.* 2019;104:953–955.