

# Primary soft tissue chondroma of the posterior mediastinum: a rare case report and literature review

Journal of International Medical Research

49(10) 1–7

© The Author(s) 2021

Article reuse guidelines:

[sagepub.com/journals-permissions](https://sagepub.com/journals-permissions)

DOI: 10.1177/03000605211053557

[journals.sagepub.com/home/imr](https://journals.sagepub.com/home/imr)

Shengru Fang<sup>1</sup>, Lianzi Liu<sup>2</sup>, Min Zhang<sup>3</sup>,  
Nannan Pan<sup>4</sup>, Wanjun Gao<sup>5</sup>, Jinbin Pan<sup>6</sup> and  
Junpeng Liu<sup>5</sup> 

## Abstract

A chondroma is a common benign cartilaginous tumor. However, a primary soft tissue chondroma of the posterior mediastinum is very rare. We herein report a case involving a 51-year-old man with a posterior mediastinal mass. The mass was dissected by thoracoscopy through the eighth intercostal space. Pathological examination led to a definitive diagnosis of a primary mediastinal chondroma with no criteria of malignancy. Preoperative diagnosis of a posterior mediastinal soft tissue chondroma is not easy because of its rarity and lack of typical features other than calcification. When a posterior mediastinal well-circumscribed soft tissue mass contains calcification and shows no obvious enhancement, the possibility of a soft tissue chondroma should be considered.

## Keywords

Chondroma, posterior mediastinum, benign, tumor, diagnosis, case report

Date received: 19 May 2021; accepted: 28 September 2021

<sup>1</sup>Department of Medical Equipment, Baodi Clinical College of Tianjin Medical University, Tianjin, China

<sup>2</sup>Department of General Medicine, Baodi Clinical College of Tianjin Medical University, Tianjin, China

<sup>3</sup>Department of Oncology, Baodi Clinical College of Tianjin Medical University, Tianjin, China

<sup>4</sup>Department of Pathology, Baodi Clinical College of Tianjin Medical University, Tianjin, China

<sup>5</sup>Department of Radiology, Baodi Clinical College of Tianjin Medical University, Tianjin, China

<sup>6</sup>Department of Radiology, Tianjin Medical University General Hospital, Tianjin, China

### Corresponding author:

Junpeng Liu, Department of Radiology, Baodi Clinical College of Tianjin Medical University, No. 8, Guangchuan Road, Baodi District, Tianjin 301800, China.  
Email: 18522587288@163.com



Creative Commons Non Commercial CC BY-NC: This article is distributed under the terms of the Creative

Commons Attribution-NonCommercial 4.0 License (<https://creativecommons.org/licenses/by-nc/4.0/>) which permits non-commercial use, reproduction and distribution of the work without further permission provided the original work is attributed as specified on the SAGE and Open Access pages (<https://us.sagepub.com/en-us/nam/open-access-at-sage>).

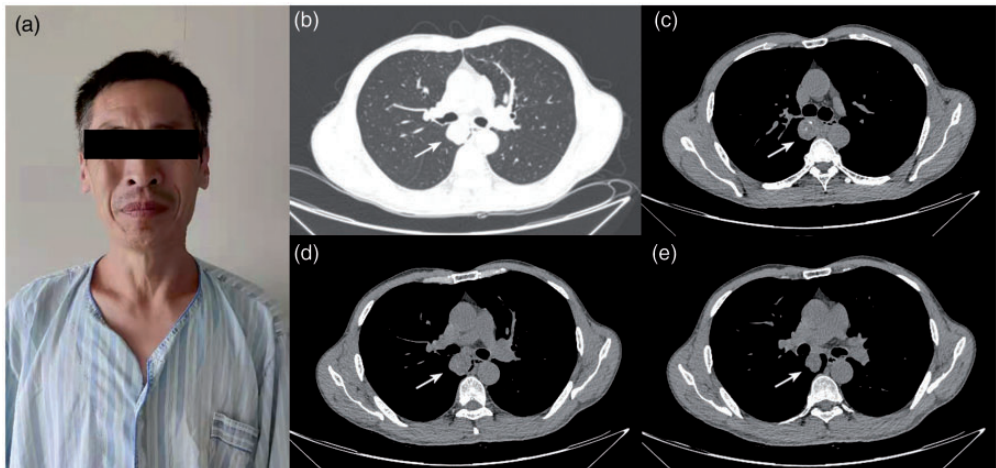
## Introduction

A chondroma is a common benign cartilaginous tumor that usually occurs in the short tubular bones of the hands and feet. The various types of chondromas include enchondromas, periosteal chondromas, and multiple enchondromatosis. A soft tissue chondroma is another rare benign cartilaginous tumor originating from the soft tissues. A primary soft tissue chondroma of the posterior mediastinum is very rare and easily excluded as a differential diagnosis of tumors in the posterior mediastinum.<sup>1</sup> We herein report a case in which both the imaging and pathological results highlighted a posterior mediastinal soft tissue chondroma as a differential diagnosis of a posterior mediastinal mass. We also review the literature regarding soft tissue chondromas of the posterior mediastinum and summarize the relevant differential diagnoses.

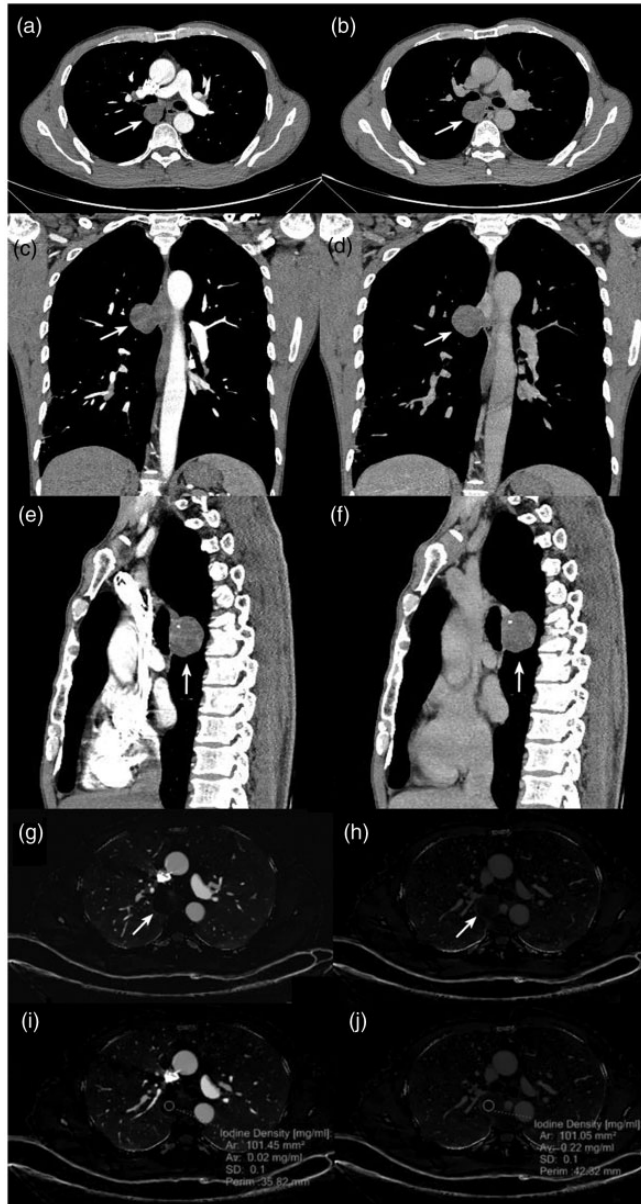
## Case report

The reporting of this study conforms to the CARE guidelines.<sup>2</sup> The study protocol was

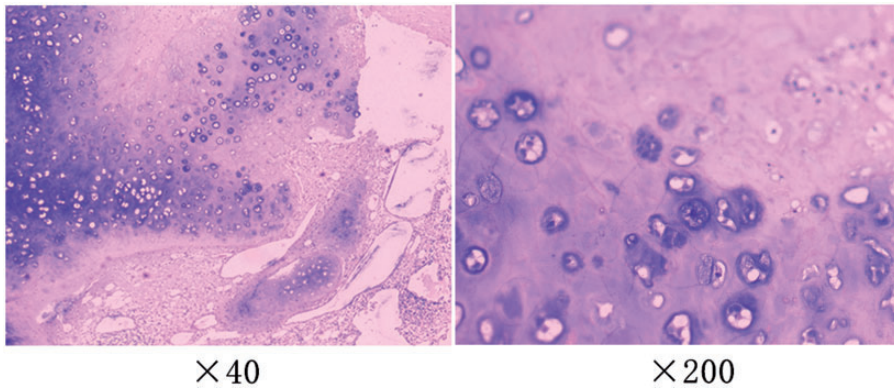
approved by the Ethics Committee of Tianjin Medical University, and the patient provided verbal informed consent. A 51-year-old man was found to have a mass in the posterior mediastinum during a health examination, and he was subsequently admitted to our hospital for further diagnosis and therapy. The patient had no clinical symptoms. Non-contrast and contrast-enhanced computed tomography (CT) of the chest showed a well-circumscribed soft tissue mass at the level of the tracheal bifurcation in the right posterior mediastinum. This mass was approximately  $3.2 \times 2.3 \times 2.5$  cm in size with multiple speckled calcifications on CT. The CT value of the soft tissue mass was about  $36.5 \pm 14.5$  HU. Bone destruction was not observed in adjacent bones (Figure 1). In particular, no enlarged lymph nodes were found in the mediastinum. No obvious enhancement was observed in the mass on contrast-enhanced CT. The CT value of the mass in the arterial and venous phase was about  $37.1 \pm 15.3$  HU and  $41.7 \pm 14.1$  HU,



**Figure 1.** Photograph of patient and non-contrast chest computed tomography images. (a) Photograph of the patient. (b) Lung window. (c–e) Mediastinal window. A well-circumscribed soft tissue mass was observed at the level of the tracheal bifurcation in the right posterior mediastinum (white arrow). The mass was approximately  $3.2 \times 2.3 \times 2.5$  cm in size and showed multiple speckled calcifications. Bone destruction was not observed in adjacent bones.



**Figure 2.** Contrast-enhanced chest computed tomography (CT) images. (a, c, e, g, i) Arterial phase. (b, d, f, h, j) Venous phase. A well-circumscribed soft tissue mass was observed at the level of the tracheal bifurcation in the right posterior mediastinum (white arrow). The CT value of the mass in the arterial phase was about  $37.1 \pm 15.3$  HU. The CT value of the mass in the venous phase was about  $41.7 \pm 14.1$  HU. No obvious enhancement of the mass was observed by contrast-enhanced CT. No enlarged lymph nodes were seen in the mediastinum. An iodine density map in the arterial phase showed iodine accumulation of 0.02 mg/mL, and that in the venous phase showed iodine accumulation of 0.22 mg/mL. The iodine density map further demonstrated that the mass had no obvious enhancement.



**Figure 3.** Pathological diagnosis (hematoxylin and eosin staining). The pathologic examination demonstrated irregularly arranged chondrocytes with surrounding fibrous tissue.

respectively. An iodine density map in the arterial and venous phase showed iodine accumulation of 0.02 mg/mL and 0.22 mg/mL, respectively (Figure 2). Because the patient had a strong desire for surgery and the benignity of the mass was unclear, thoracoscopic surgery was performed through the posterior axillary line and the eighth intercostal space. No adhesion was present between the right lung and the parietal pleura, and the pulmonary fissure was well defined. The mass was located in the right posterosuperior mediastinum on the anterolateral side of the thoracic vertebra. It was about 3.5 × 3.0 × 2.5 cm in size and had a clear boundary and intact capsule. The mass was obviously separated from the bronchus and lung tissue, and it was connected to the posterior mediastinal soft tissue through a pedicle containing feeding vessels. The mass was completely removed, and the histopathological examination confirmed the diagnosis of chondroma (Figure 3). Surgery was uneventfully performed with no postoperative complications. The patient showed no local recurrence or distal disease throughout a 12-month follow-up period.

## Discussion

Common types of chondroma include enchondroma, periosteal chondroma, and multiple enchondromatosis.<sup>1</sup> A soft tissue chondroma, also called an extraskeletal chondroma or chondroma of soft parts, is another very rare type. A soft tissue chondroma is a rare benign cartilage tumor originating from the soft tissues, and it usually occurs in the soft tissues of the hands and feet, accounting for about 96% of cases. Amary et al.<sup>3</sup> found that the development of soft tissue chondromas was related to *FNI* gene rearrangement and to *FNI-FGFR1* and *FNI-FGFR2* gene fusions. These chondromas are particularly more common in the thumb, where they are usually connected to the tendon and tendon sheath. They can also occur in the knee, neck, back, liver, and testis. However, they are very rare in the mediastinum.

Only a few reports have described cases of posterior mediastinal chondromas (Table 1). Zhao et al.<sup>4</sup> reported a case of a chondroma that was derived from the periosteum of the posterior mediastinum with massive calcification. The mass showed inhomogeneous enhancement and was

**Table 1.** Reports of mediastinal chondroma.

Description of tumor	Sex	Age (years)	Symptoms/history	Boundary	Calcification	Bone condition	Enhancement	Reference
Giant periosteal chondroma of rib	F	38	Progressive dyspnea and worsening chest distress	Clear	Yes	Bone destruction	Inhomogeneous enhancement	3
Primary chondroma of posterior mediastinum	F	31	Horner's syndrome	Clear	Yes	Bone destruction	Inhomogeneous enhancement	4
Soft tissue chondroma of posterior mediastinum	F	19	(1) Mild dysuria and frequency (2) Mild dyspnea and chest pain	Clear	Yes	Bone resorption	Not available	5
Chondroma of anterior mediastinum	F	85	(1) Suspected pulmonary embolus (2) History of median sternotomy for coronary artery bypass surgery 10 years previously	Clear	No	Normal	Not available	6
Chondrosarcoma of superior mediastinum	M	73	Progressive inspiratory orthopneic dyspnea and dysphonia	Not perceptible	Yes	Bone destruction	Not available	7
Soft tissue chondroma of posterior mediastinum	M	51	No symptoms	Clear	Yes	Normal	Almost no enhancement	This case

F, female; M, male.

associated with fracture and blurring of the cortex of the adjacent fourth rib. The capsule of the mass was intact. In our case, the mass also contained calcification and an intact capsule, but it showed no obvious enhancement or bone abnormalities. Xu et al.<sup>5</sup> reported a primary chondroma of the posterior mediastinum in a patient with Horner's syndrome. The mass had a clear boundary and showed calcification, and it was associated with enlargement of the adjacent intervertebral foramen and damage to the left second rib. In our case, however, the mass was found during a health examination, and the patient had no clinical symptoms or bone abnormalities. Widdowson and Lewis-Jones<sup>6</sup> reported a large soft tissue chondroma arising from the posterior mediastinum. The mass showed a clear boundary and contained irregular dense calcified areas with bone resorption in the vicinity of the mass. Other reports have described chondromas elsewhere in the mediastinum.<sup>7,8</sup> In these reports, the masses had a clear boundary and might have contained calcification with or without bone abnormalities, showing features similar to the posterior mediastinal chondroma in our case.

In our case, the mass required differentiation from several other types of tumors. First, neurogenic tumors are the most common tumors in the posterior mediastinum. These tumors mostly originate from the intercostal nerve in the paraspinal region. The typical imaging manifestation is described as a round or ovoid mass in the posterior mediastinum that often oppresses the adjacent ribs, vertebral bodies, vertebral pedicles, or transverse processes to form a smooth fan-shaped indentation. Additionally, the intervertebral foramen can be enlarged by the tumor. The tumor often shows obvious enhancement. When cystic degeneration and necrosis occur, the tumor shows inhomogeneous enhancement.<sup>9</sup> In our case,

although the mass did not compress the peripheral bones or show enhancement, it was still difficult to distinguish from an atypical neurogenic tumor. Second, the tumor in our case required differentiation from a lymphoma. Generally, lymphomas mainly involve the anterior and middle mediastinum; they are uncommon in the posterior mediastinum. Lymphomas can involve multiple groups of lymph nodes in the adjacent region along the lymphatic chain. Before treatment, calcification inside the lymphoma is very rare, and the mass shows inhomogeneous enhancement when cystic degeneration and necrosis occur.<sup>10</sup>

The solitary posterior mediastinal mass in our case exhibited multiple speckled calcifications and showed no enhancement, and no enlarged lymph nodes were found elsewhere in the body. Thus, lymphoma was considered less likely in our case. Additionally, although teratomas commonly occur in the anterior mediastinum and gonad, posterior mediastinal teratomas constitute 3% to 8% of all mediastinal teratomas.<sup>11</sup> Posterior mediastinal teratomas usually occur in children or young adults. Typical teratomas often present as round or lobulated well-circumscribed masses and frequently contain calcified dental, adipose, and hair tissues. Calcification and small amounts of fat can be easily detected on CT. Although calcification was detected in our case, a diagnosis of teratoma was not fully supported in terms of the patient's age and the tumor's lack of fat components. In addition, some cystic masses show watery density without enhancement in the posterior mediastinum, such as foregut cysts and lymphangiomas, and the density of the mass may increase when the tumor is complicated by bleeding, protein concentration, or calcium salt deposition.<sup>10</sup> Clinicians should be vigilant for these conditions when encountering a mass such as that seen in the present case.



## Conclusion

Preoperative diagnosis of a posterior mediastinal chondroma is not easy. When a posterior mediastinal well-circumscribed soft tissue mass contains calcification and shows no obvious enhancement, the possibility of a soft tissue chondroma should be considered. Because the mass is likely to be a benign tumor according to its imaging characteristics, careful follow-up appropriate until the tumor shows an increase in size. However, surgical treatment can be performed if the patient has a strong desire for surgery.

## Declaration of conflicting interest

The authors declare that there is no conflict of interest.

## Funding

The authors disclosed receipt of the following financial support for the research, authorship and/or publication of this article: This work was supported by the Science & Technology Development Fund of Tianjin Education Commission for Higher Education (2017KJ192).

## ORCID iD

Liu Junpeng  <https://orcid.org/0000-0001-9222-3663>

## References

1. Uhl M, Herget G and Kurz P. Cartilage tumors: pathology and radiomorphology. *Radiologe* 2016; 56: 476–488.
2. Gagnier JJ, Kienle G, Altman DG, et al. CARE Group. The CARE guidelines: consensus-based clinical case reporting guideline development. *Headache* 2013; 53: 1541–1547.
3. Amary F, Perez-Casanova L, Ye H, et al. Synovial chondromatosis and soft tissue chondroma: extraosseous cartilaginous tumor defined by FN1 gene rearrangement. *Mod Pathol* 2019; 32: 1762–1771.
4. Zhao XG, Chen G and Chen XF. Giant periosteal chondroma of the rib associated with mediastinum deviation. *Ann Thorac Surg* 2012; 94: 1014.
5. Xu XQ, Li X, Ren F, et al. Primary chondroma of posterior mediastinum with Horner's syndrome: a case report. *World J Surg Oncol* 2018; 16: 209.
6. Widdowson DJ and Lewis-Jones HG. Case report: a large soft-tissue chondroma arising from the posterior mediastinum. *Clin Radiol* 1988; 39: 333–335.
7. Shrivastava V, Vundavalli S, Smith D, et al. A chondroma of the anterior mediastinum. *Clin Radiol* 2006; 61: 1065–1066.
8. Philippe G, Henri P, Marie-Christine C, et al. A case of giant chondrosarcoma of the cricoid cartilage presenting as a superior mediastinal tumour. *Eur J Cardiothorac Surg* 1998; 14: 520–522.
9. Rodriguez EF, Jones R, Miller D, et al. Neurogenic tumors of the mediastinum. *Semin Diagn Pathol* 2020; 37: 179–186.
10. Ozawa Y, Hiroshima M, Maki H, et al. Imaging findings of lesions in the middle and posterior mediastinum. *Jpn J Radiol* 2021; 39: 15–31.
11. Feng Q, Xiao Y and Han F. Posterior mediastinal mature cystic teratoma-known but rare entity. *Am J Med Sci* 2020; 359: 308–309.