Case Reports in Ophthalmology

Case Rep Ophthalmol 2023;14:640–646
DOI: 10.1159/000533632
Received: May 27, 2023
Accepted: August 14, 2023
Published online: November 24, 2023

Case Report

Familial Exudative Vitreoretinopathy Initially Diagnosed as Incontinentia Pigmenti in an Asymptomatic Teenager: A Case Report

Reem Karmouta Irena Tsui Monica Khitri

David Geffen School of Medicine, Stein Eye Institute, Doheny Eye Institute, Department of Ophthalmology, University of California Los Angeles, Los Angeles, CA, USA

Keywords
Familial exudative vitreoretinopathy · Incontinentia pigmenti · Transgender health · Case report

Abstract
In this case report, we aim to illustrate a presentation of familial exudative vitreoretinopathy (FEVR) that closely resembles incontinentia pigmenti (IP) and the role of genetic testing that is of no cost to the patient in providing the correct diagnosis. We present a case of an 11-year-old female-to-male transgender patient with a history of hypodontia and skin hypopigmentation who was incidentally found to have a retinal lesion on ultra-widefield fundus imaging during routine screening. Ultra-widefield fluorescein angiography confirmed bilateral peripheral ischemic retinopathy that was successfully treated with laser. The patient was presumed to have IP; however, genetic testing was negative. Due to cost, further genetic testing was declined by the family, and the patient had no further ocular complaints. At age 16, genetic testing became available to the patient, and the patient was found to have FEVR with *LRP5* mutation. The patient began screening for comorbidities associated with *LRP5* mutation. This case highlights how the ophthalmologic findings of FEVR can present identically to those of IP, and genetic testing is an invaluable tool in distinguishing between these two pathologies. Correct diagnosis of FEVR is vital in assessing other comorbidities of the disease, including osteoporosis. Furthermore, increased use of ultra-widefield fundus imaging in routine eye screening may be of great benefit for community screening of retinal disease, and ultra-widefield fluorescein angiography is of significant use in the diagnosis of FEVR.

Correspondence to:
Monica Khitri, mkhitri@mednet.ucla.edu

Karger

Introduction

Asymptomatic peripheral ischemic retinopathies in children are rare and include incontinentia pigmenti (IP), retinopathy of prematurity, sickle cell retinopathy, and familial exudative vitreoretinopathy (FEVR). IP is a rare, X-linked dominant disease that is caused by mutations in the *IKBKG* gene and most commonly presents at birth or early childhood [1]. IP primarily presents with dermatologic manifestations, including a characteristic vesiculobullous rash present within the first months of life. Between infancy and adolescence, this rash evolves into hyperpigmented whorl lesions that may progress to hypopigmentation and alopecia in adulthood. Minor criteria for IP include dental abnormalities, such as hypodontia and anomalies in dental shape, history of multiple male miscarriages in the mother, and ocular abnormalities [2]. It is reported that the prevalence of ophthalmologic findings in IP patients is 36.5%; however, other sources have cited a prevalence as high as 77% [3, 4]. Avascular peripheral retina is considered a classic retinal finding in IP [1]. This finding in IP overlaps with other pediatric retinal diseases, including retinopathy of prematurity and FEVR [2]. Macular pathology is also common in IP, including absence of normal parafoveal vascular pattern [1]. Other retinal findings include retinal hemorrhages, arteriovenous anastomoses, and vascular aneurysms [5]. Fluorescein angiography is critical in the evaluation of suspected IP. While retinal manifestations in IP most often occur by the first year of life, new-onset retinal findings in adolescence and adulthood have been reported [6, 7]. Nonretinal manifestations of IP include nystagmus, strabismus, cataracts, and uveitis [3].

We present an 11-year-old patient having peripheral avascular retina and clinical features most consistent with IP, including hypodontia, progressive dermatologic findings, and a history of maternal miscarriages, who subsequently had genetic testing negative for IP. We also present findings of ultra-widefield fluorescein angiography that aided in diagnosis and treatment planning. The CARE Checklist has been completed by the authors for this case report, attached as supplementary material (for all online suppl. material, see https://doi.org/10.1159/000533632).

Case Report

An 11-year-old female patient was referred to the Doheny Eye Center at the University of California, Los Angeles, after the patient was found to have a retinal lesion on ultra-widefield fundus imaging during a routine eye exam at the optometrist. The patient was not experiencing any visual symptoms. The patient had a history of myopia (−0.75D OD, −2.25D OS spherical equivalent) and a well-controlled, moderate angle intermittent alternating exotropia. On examining, the best corrected visual acuity was 20/20-1 in each eye. The patient was found to have a 3-disc diameter stellate white lesion temporally with 2 feeder vessels in the left eye (Fig. 1). Ultra-widefield fluorescein angiography demonstrated leakage of peripheral retinal neovascularization temporally in the left eye and peripheral nonperfusion in both eyes (Fig. 2). OCT showed macular thinning of the temporal retina in all layers in both eyes (Fig. 3). OCTA showed enlarged foveal avascular zone in both eyes (Fig. 4).

This patient had been born full term but was noted to have a history of skin lesions at birth treated with laser and resultant skin hypopigmentation. The patient also had a history of hypodontia with multiple missing teeth. The patient's mother endorsed three previous miscarriages of male gender. Both parents underwent retinal exams, which were normal. Given the clinical presentation, the patient was presumed to have IP, and genetic testing for the *IKBKG* gene was pursued. No pathologic *IKBKG* variant was detected, and

Case Rep Ophthalmol 2023;14:640–646
DOI: 10.1159/000533632

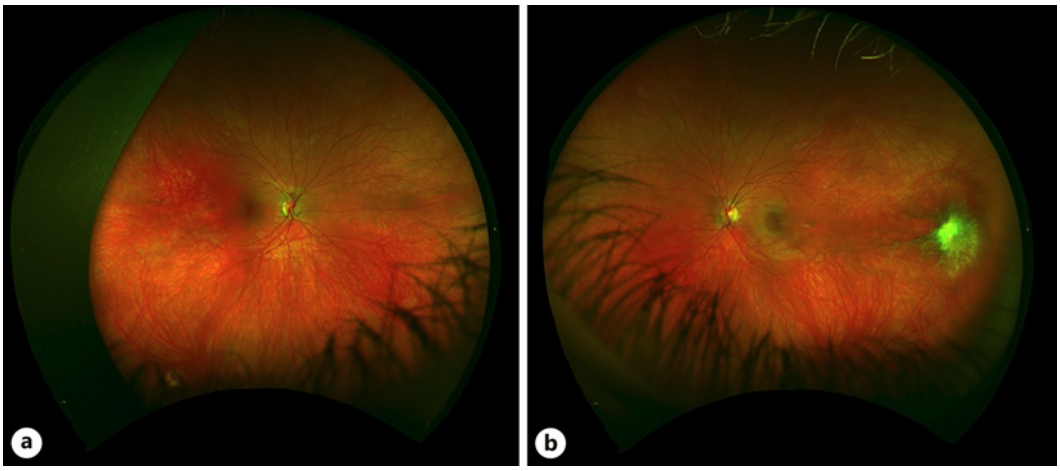

Fig. 1. Fundus photography at presentation. **a** Right eye without significant findings. **b** Left eye fundus imaging demonstrating a 3DD stellate white lesion temporally with 3 feeder vessels.

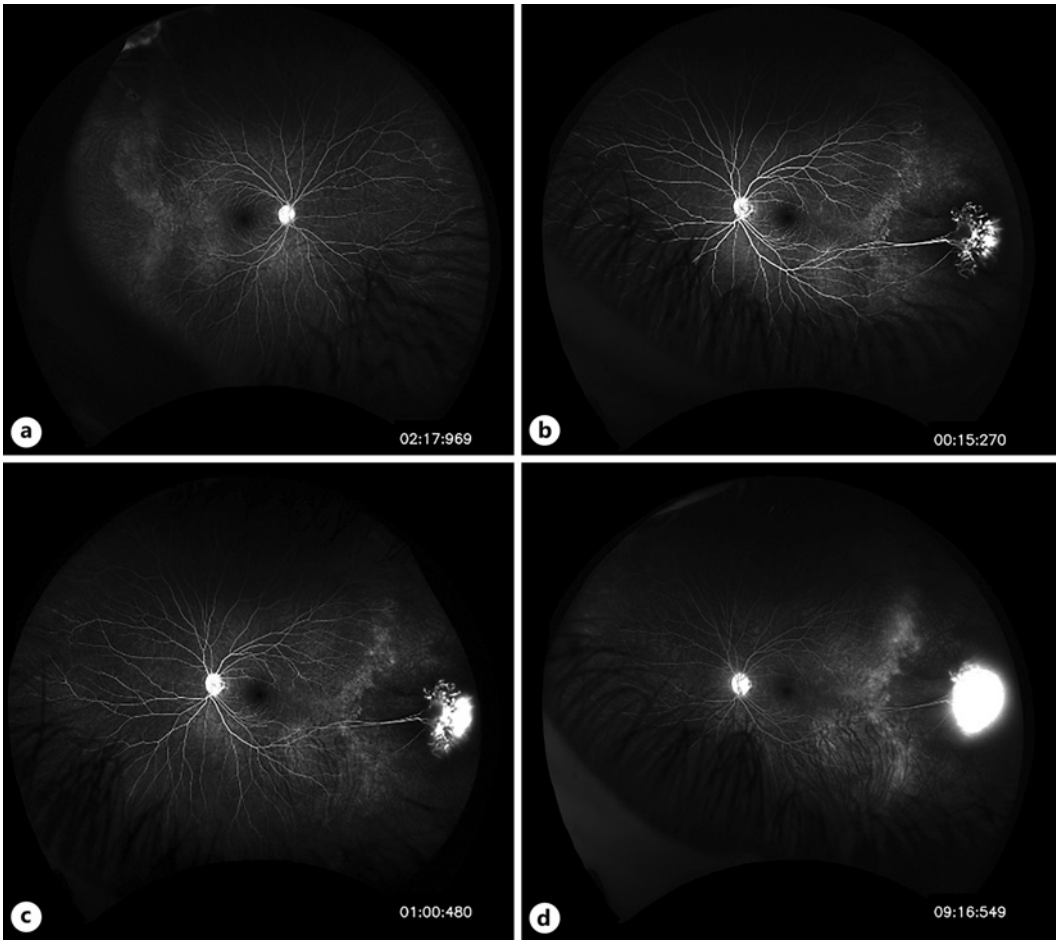

Fig. 2. OPTOS fluorescein angiogram imaging prior to treatment with laser. **a** Right eye, showing temporal nonperfusion. **b** Left eye, early showing temporal retinal neovascularization and nonperfusion. **c** Left eye, medium. **d** Late phase showing temporal retinal neovascularization with late hyperfluorescence.

Case Rep Ophthalmol 2023;14:640–646
DOI: 10.1159/000533632

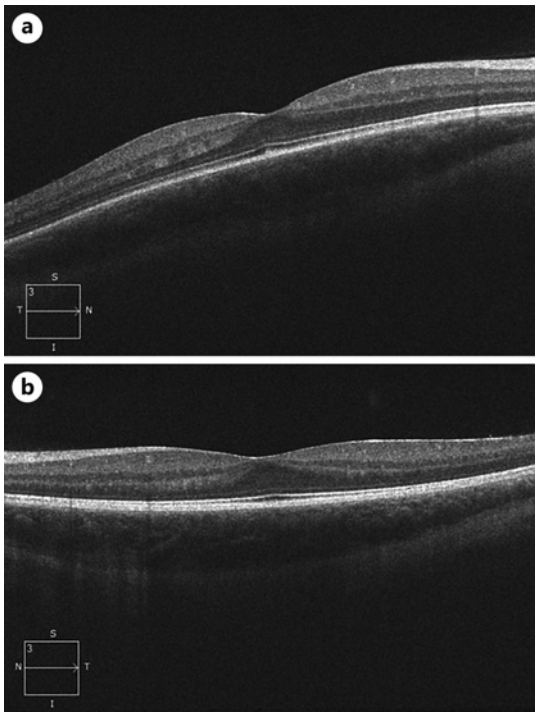

Fig. 3. OCT showing macular thinning in all layers in both eyes. **a** Right eye. **b** Left eye.

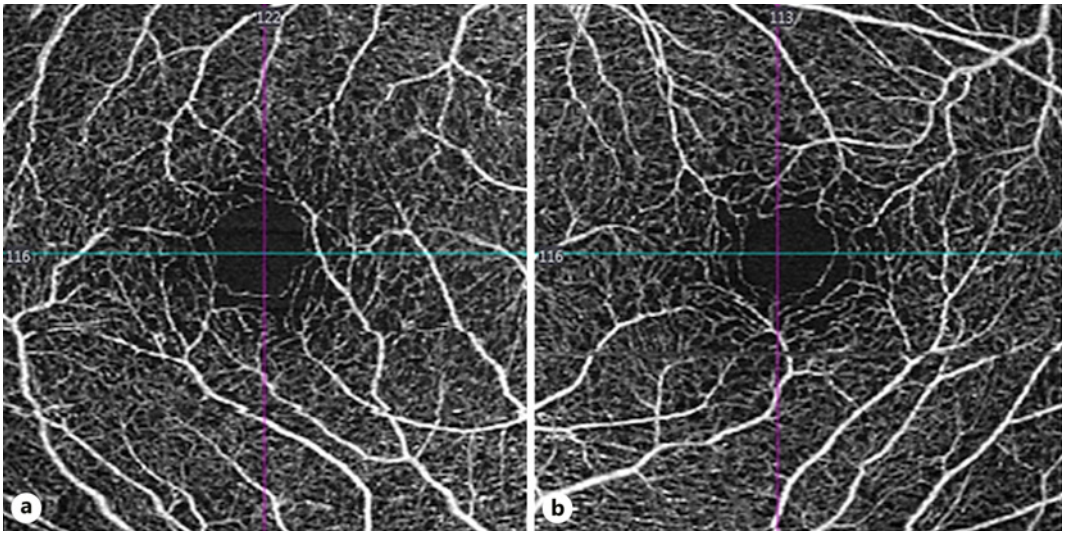

Fig. 4. OCTA showing possible capillary dropout in the perifoveal region in both eyes. **a** Right eye. **b** Left eye.

IP was ruled out. Due to the cost, further genetic testing was declined by the family. The patient was then treated with peripheral laser in both eyes with the resolution of leakage (Fig. 5, Fig. 6).

At the age of 16 yrs, the patient returned, and a notable updated medical history included transitioning from female to male with cross-sex hormone therapy. Genetic testing was offered at no cost to the patient through a privately sponsored genetic testing program. A heterozygous mutation was found in the *LRP5* gene, c.3122C>T (p.Thr1041Met) consistent with autosomal dominant FEVR.

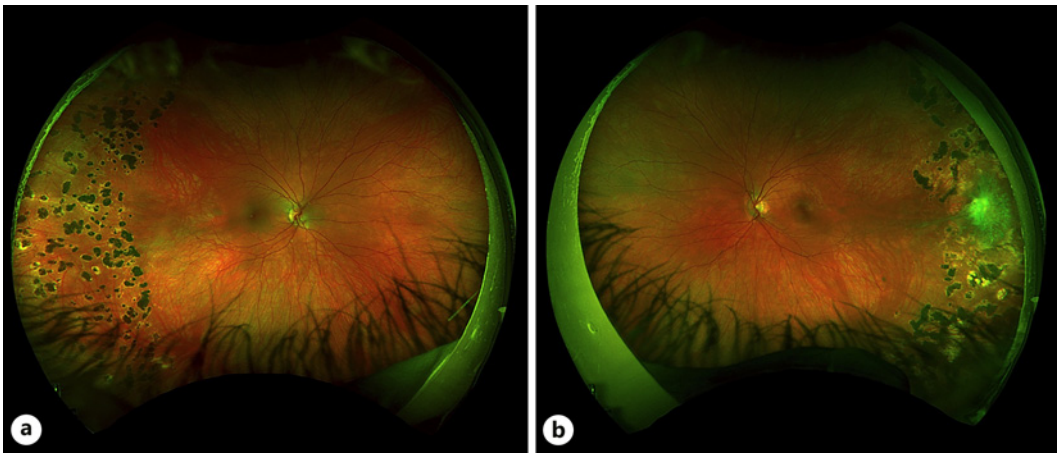

Fig. 5. Fundus imaging following targeted laser treatment to the temporal retinal and regression of neovascularization in the left eye. **a** Right eye. **b** Left eye.

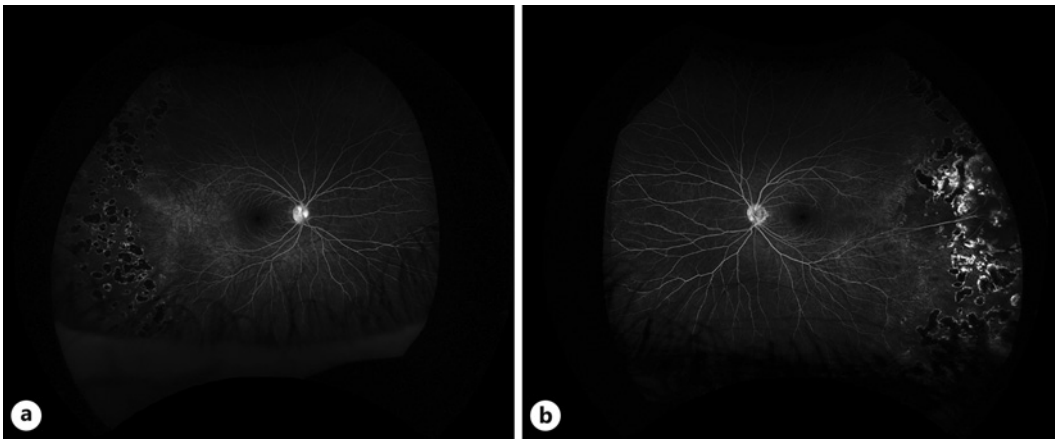

Fig. 6. OPTOS fluorescein angiogram following laser treatment. **a** Right eye. **b** Left eye.

Following the results of the genetic testing, the patient was connected to a clinical geneticist to assess for the presence and risk of comorbidities associated with FEVR with *LRP5* mutation. The patient was found to have osteoporosis, likely secondary to *LRP5* mutation. The patient was not started on osteoporosis treatment at this time as the agent that may be most effective in targeting osteoporosis secondary to *LRP5* mutation, romosozumab, is not currently approved for use in pediatric populations. The patient's family members received genetic testing, and the patient's father was found to carry the pathogenic *LRP5* variant.

Discussion

FEVR is a rare, heritable retinal disease that primarily affects retinal angiogenesis, leading to incomplete vascularization of the peripheral retina. While FEVR is commonly inherited in an autosomal dominant fashion, it can also present in individuals in an autosomal recessive, X-linked, or spontaneous manner [8]. Mutations in five genes, *NDP*,

FZD4, *LRP5*, *TSPAN12*, and *ZNF408*, account for 50% of FEVR cases. Expressivity is variable; however, the hallmark of FEVR is peripheral retinal avascularity. Mild cases may be asymptomatic, while moderate to severe cases can present with macular ectopia, visual dysfunction, retinal folds, and retinal detachment [9]. FEVR with *LRP5* mutation may also present with early-onset osteoporosis. Other extra-ocular manifestations of FEVR are rare [8]. The similarity of ocular findings between FEVR and IP have been described; however, IP can be more easily distinguished from FEVR due to characteristic extra-ocular findings including skin, dental, and neurological abnormalities [8]. Our case highlights a patient who presented with findings most similar to those of IP, including skin hypopigmentation, hypodontia, and a maternal history of miscarriages of male fetus; however, the patient was found to have FEVR upon genetic testing. Our case highlights a unique case of FEVR masquerading as IP and the necessity of genetic testing in distinguishing between IP and FEVR.

The utility of genetic testing for retinal disorders that is of no cost to the patient was instrumental in providing a correct diagnosis in this case. Prior to the availability of a privately sponsored free genetic test, the patient in this case was unable to pursue genetic testing due to financial constraints. As mutations in the *LRP5* gene are not only associated with FEVR but also with other pathologies including bone density disorders, prompt and correct diagnosis with genetic testing is vital to initiate further evaluation by other specialists [10, 11]. This was of particular importance in this case as the patient began transitioning from female to male with the initiation of testosterone therapy and planning for gender-affirming surgeries including salpingo-oophorectomy. Testosterone therapy alone has not been shown to decrease bone mineral density in transgender males and may even decrease the rates of bone loss. Noncompliance with testosterone therapy, suboptimal testosterone dosing following gonadectomy, and initiation of aromatase inhibitors, however, are factors that have been shown to negatively impact bone density in transgender males [12, 13]. The patient in this case is at compounded risk of worsening osteoporosis and increased fracture risk given the patient possesses an *LRP5* mutation manifesting as early-onset osteoporosis and is also undergoing gender transition. This further emphasizes the importance of correct diagnosis of FEVR with *LRP5* mutation with genetic testing at no cost to the patient. With the correct diagnosis, careful attention may be paid to optimizing this patient's bone health as they transition from female to male and pursue further pharmacologic and surgical options in the future.

Furthermore, the use of ultra-widefield fluorescein angiography is important in better characterizing ocular abnormalities in cases of suspected FEVR. Ultra-widefield fluorescein angiography is useful to detect retinal nonperfusion, neovascularization, and vessel leakage that is not clinically apparent and is also of significant benefit in planning of laser treatment. Response to laser treatment in FEVR is variable and can progress with worsening vitreoretinal traction, requiring close follow-up [14]. This case also highlights the utility of ultra-widefield fundus photography as part of routine eye exams in detecting potential retinal disease and promptly connecting patients to the appropriate specialist.

Our case highlights a unique presentation of FEVR that more closely resembled IP on initial examination and history given the characteristic extra-ocular manifestations of IP. Genetic testing was vital in distinguishing between IP and FEVR as ocular abnormalities were consistent with both retinal diseases, and osteoporosis screening and management was important, notably in a patient undergoing gender transition. Additionally, the use of ultra-widefield fundus imaging at routine eye screenings can be of great utility in detecting potential retinal pathology and providing prompt, vision-saving treatment.

Statement of Ethics

Written informed consent was obtained from the parent/legal guardian of the patient for publication of the details of their medical case and any accompanying images. Ethical approval is not required for this study in accordance with local guidelines.

Conflict of Interest Statement

The authors have no conflicts of interest to declare.

Funding Sources

This research did not receive grants for funding from any individual or agency in the commercial, private, or not-for-profit sectors.

Author Contributions

All authors attest that they meet the current ICMJE criteria for authorship. Reem Karmouta: acquisition of data and drafting work. Irena Tsui and Monica Khitri: contribution to conception of work and revising critically important intellectual content.

Data Availability Statement

All data analyzed during this study are included in this article. Further inquiries can be directed to the corresponding author.

References

1 Swinney CC, Han DP, Karth PA. Incontinentia pigmenti: a comprehensive review and update. Ophthalmic Surg Lasers Imaging Retina. 2015;46(6):650–7.
2 Islam YFK, Khurshid SG. Incontinentia pigmenti and the eye. Curr Opin Ophthalmol. 2022;33(6):525–31.
3 Minić S, Obradović M, Kovačević I, Trpinac D. Ocular anomalies in incontinentia pigmenti: literature review and meta-analysis. Srp Arh Celok Lek. 2010;138(7–8):408–13.
4 Holmström G, Thorén K. Ocular manifestations of incontinentia pigmenti. Acta Ophthalmol Scand. 2000;78(3):348–53.
5 Goldberg MF, Custis PH. Retinal and other manifestations of incontinentia pigmenti (Bloch-Sulzberger syndrome). Ophthalmology. 1993;100(11):1645–54.
6 Equi RA, Bains HS, Jampol L, Goldberg MF. Retinal tears occurring at the border of vascular and avascular retina in adult patients with incontinentia pigmenti. Retina. 2003;23(4):574–6.
7 Balaratnasingam C, Lam GC. Retinal sequelae of incontinentia pigmenti. Pediatr Int. 2009;51(1):141–3.
8 Gilmour DF. Familial exudative vitreoretinopathy and related retinopathies. Eye. 2015;29(1):1–14.
9 Ranchod TM, Ho LY, Drenser KA, Capone A Jr, Trese MT. Clinical presentation of familial exudative vitreoretinopathy. Ophthalmology. 2011;118(10):2070–5.
10 Levasseur R, Lacombe D, de Vernejoul MC. LRP5 mutations in osteoporosis-pseudoglioma syndrome and high-bone-mass disorders. Joint Bone Spine. 2005;72(3):207–14.
11 Lee-Law PY, van de Laarschot LFM, Banales JM, Drenth JPH. Genetics of polycystic liver diseases. Curr Opin Gastroenterol. 2019;35(2):65–72.
12 Sedlak CA, Roller CG, van Dulmen M, Alharbi HA, Sanata JD, Leifson MA, et al. Transgender individuals and osteoporosis prevention. Orthop Nurs. 2017;36(4):259–68.
13 Verroken C, Collet S, Lapauw B, T'Sjoen G. Osteoporosis and bone health in transgender individuals. Calcif Tissue Int. 2022;110(5):615–23.
14 Hubbard GB, Li AL. Analysis of predisposing clinical features for worsening traction after treatment of familial exudative vitreoretinopathy in children. Am J Ophthalmol. 2021;223:430–45.