



Correction manoeuvres in the surgical treatment of spinal deformities

Alpaslan Senkoylu¹
Mehmet Cetinkaya²

- Correction manoeuvres are as important as the other issues such as hardware selection, graft options, fusion and osteotomy techniques in the surgical treatment of spinal deformities.
- The property of materials demonstrating both viscous and elastic characteristics when undergoing deformation is called visco-elasticity. Purely elastic materials change in shape with a stress, and go back to their initial form when the stress is removed. However, visco-elastic materials, like the spine, may protect their new formation unless a back stress is applied. Time is a very important parameter during manoeuvre application to the spine because of its visco-elastic behavior.
- The most common correction manoeuvres that can be used for spinal deformities are rod de-rotation, distraction-compression, *in situ* rod bending, segmental de-rotation, *en bloc* de-rotation and cantilever.
- Spontaneous correction of a minor curve is possible after selective fusion of a major curve due to coupling phenomenon.

Keywords: spinal deformity; scoliosis, kyphosis; correction manoeuvres; de-rotation; coupling; cantilever

Cite this article: *EFORT Open Rev* 2017;2.
DOI: 10.1302/2058-5241.2.170002. Originally published online at www.efortopenreviews.org

Introduction

The management of spinal deformity is a challenging issue for spine surgeons. Diagnosis, surgical decision, surgical approach, appropriate surgical technique, decision for fusion levels, or for hardware choice are all confusing puzzles. Even if all these issues are organised very well, how to correct a spinal deformity without any harmful damage to the patient, especially regarding the spinal cord, is another problem to be considered.

The later decades of the 20th century came with a giant leap in spinal deformity surgery thanks to the new

techniques and hardware options which was satisfying both for the surgeons and patients. However, recently, surgeons are now searching for better deformity correction and better post-operative outcomes, and they have investigated these issues in detail.

Beside the techniques of osteotomy, hardware selection, or choice of bone-graft or choice of fusion levels, another researched issue is how to correct a deformity to desirable and satisfactory angles and by which technique. The manoeuvres usually used for scoliosis correction are rod de-rotation, vertebra-to-rod, and three-rod techniques, depending on the pathology of the patient.¹ If we talk about kyphosis, the cantilever manoeuvre is the preferred choice for these disorders which usually have only sagittal-plane deformity. However, scoliosis is a much more complicated deformity which also has deformity in the coronal and transverse planes (rotational deformity) as well as the sagittal plane.

The rotational component of the scoliosis has been a mystery since the early investigations started over this entity. In the late nineteenth century, Little reported his opinions and criticised previous studies over rotational deformity of the scoliosis but revealed no evidence about the causes.²

The correction of scoliosis has been performed for more than 40 years by various systems such as Harrington rods (approximately 40% correction) and the dual-rod multi-hook system, aka Cotrel-Dubousset (approximately 55% correction).^{3,4} Today, scoliosis deformity correction is mostly performed by posteriorly-placed pedicle screws inserted through pedicle holes surrounded by compact bone, especially after Suk et al popularised the use of them in adolescent idiopathic scoliosis and showed that this method can provide high correction rates exceeding 70% in the coronal plane.⁵

Biomechanics of correction

The correction can be in both the soft tissue and bone tissue planes. At the micrometer-to-sub-micrometer scale,

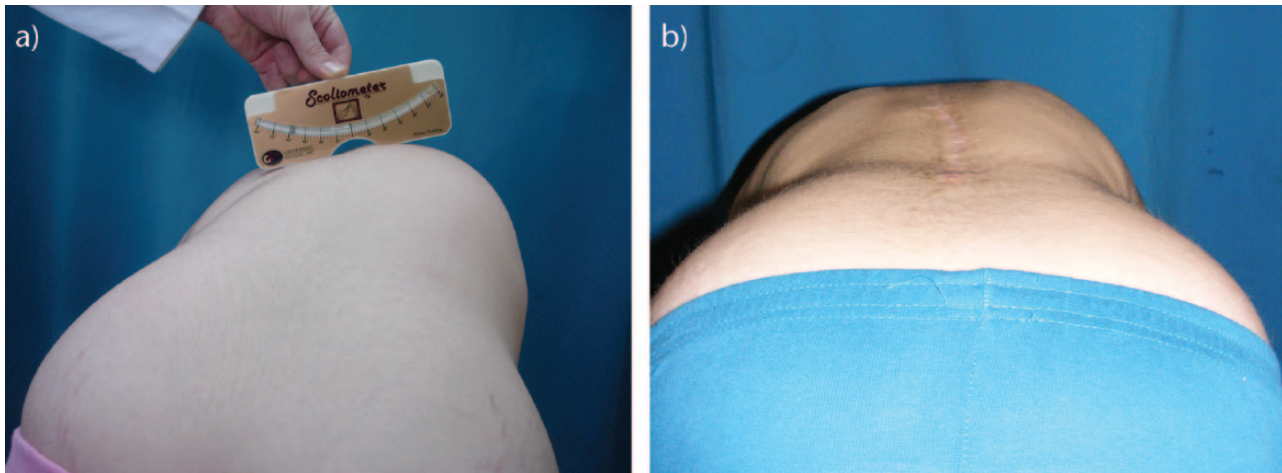


Fig. 1 a) Clinical photograph of a 14-year-old patient with right-sided rib hump on Adam's forward bending test. This is an important sign of the rotational component of scoliosis. b) One year follow-up photograph of the same patient reveals total correction of the rib hump by the de-rotation manoeuvre.

general material properties, including the elastic modulus and contact hardness, of specific bony structures (e.g., lamellae), bone types (osteonal vs interstitial), and soft tissues are variable.⁶ When examined the stress-strain curve, the interval between the yield point and the fracture point of the compact cortical bone is too short to acquire enough deformation without fracture to correct the scoliosis deformity. The necessary change for deformity correction in bony tissue can be only gained by osteotomies. Therefore, the change in bony tissue can be ignored because of being non-observable during the corrective manoeuvres of the spine. However, the visco-elasticity of soft tissues can provide enough deformity correction without losing their integrity.

The property of materials demonstrating both viscous and elastic characteristics when undergoing deformation is called visco-elasticity. Whereas elasticity is usually the result of bond stretching along crystallographic planes in an ordered solid, viscosity is the result of the diffusion of atoms or molecules inside an amorphous material. When encountering a stress, viscous materials, like honey, resist flow strain linearly while elastic materials strain and quickly return to their original state once the stress is removed.⁷ Specifically, visco-elasticity is a molecular re-arrangement. When a stress is applied to a visco-elastic material such as a polymer, parts of the long polymer chain change position. This movement or re-arrangement is called *creep*. Polymers remain a solid material even when these parts of their chains are re-arranging in order to accompany the stress. Elastic materials may also sustain plastic deformity if the deforming force increases or is sustained.⁷ Purely elastic materials change in shape with a stress, and go back to their initial form when the stress is removed. However, visco-elastic materials, like tendons

and ligaments, may protect their new formation unless a back stress is applied. Time is a very important parameter during manoeuvre application to the spine because of its visco-elastic behavior.

Despite the advantages of modern instrumentation and surgery techniques available for the surgeons' use, the management of severe (Cobb angle more than 70°)⁸ rigid (flexibility index less than 40%)⁹ scoliosis can be troublesome and challenging. Therefore, the correction steps may start before surgery with some pre-adjuvant methods. For the management of severe rigid deformities greater than 100°, halo-femoral, halo-tibial, or halo-pelvic traction methods can be used.⁹ These pre-adjuvant methods can be explained by the visco-elastic properties of the spine and surrounding tissues. If you give enough time and apply constant traction for a long time, deformity will be corrected at the end more effectively. However, these methods are associated with several long-term complications and confine patients to bed.¹⁰ Halo-gravity tractions in a wheelchair can be an efficient alternative to apply for a period of time (2 to 8 weeks) before the surgery as a rather safe alternative with the benefit of mobilising patients out of bed.¹¹

Correction manoeuvres

Probably the most important issue in scoliosis deformity correction is the rib hump deformity (Fig. 1a) produced from the axial rotation of a scoliotic curve. It is one of the cosmetically dissatisfying attributes that patients note and has been correlated with post-operative patient cosmetic satisfaction. A thoracoplasty can be an option by removing some ribs to provide more flexible thoracic vertebrates for correction and improved rib hump deformity. In addition to helping in deformity correction, removed ribs may

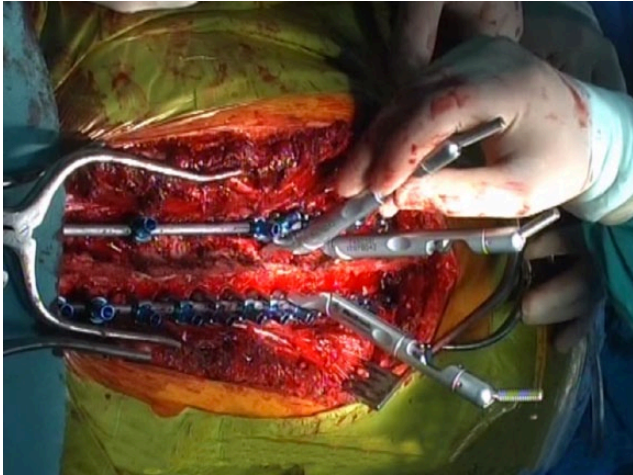


Fig. 2 Operative photograph showing attachment of the de-rotation devices to the pedicle screws before the segmental de-rotation manoeuvre.

also be used by the surgeon as bone graft for fusion. Simple rod de-rotation (SRD) and direct vertebral body de-rotation (DVBD) can also be an option made possible by the efficacy of 3-column control of the vertebrae which have two types of basic manoeuvre available, (Fig. 1b): segmental and *en bloc*.^{13,14} The latter was found to be associated with excellent radiographic axial spinal column de-rotation but with no better rib hump correction by Mattila et al.¹⁵ Suk et al reported 38% improvement in rib hump deformity angle with SRD in the absence of thoracoplasty or DVBD.¹⁶ They found 58% improvement with additional thoracoplasties and 72% improvement with both thoracoplasties and DVBD. DVBD alone was reported to produce 54% correction of rib hump deformity by another study. Thoracoplasty is still suggested by some authors as a powerful tool and claimed to be the right choice for the optimal correction of rib prominence.¹⁶ However, Samdani et al reported similar outcomes with thoracoplasty and DVBD alone, especially in mild deformities.¹⁷ On the other hand, it was reported that there was a trend towards loss of coronal correction and recurrence in apical vertebral rotation and rib hump deformity at two years in patients with only DVBD, and thoracoplasty is needed for lower recurrence rates.¹⁸ Besides these studies, another thought is that the changes in parameters including Cobb's angle, functional vital capacity, and low back pain after the treatment do not differ significantly between the surgical options.¹⁹

1. Segmental de-rotation:

After the posterior exposure of the desired levels of vertebral column and placement of pedicle screws at planned levels, the concave side rod is placed initially as usual. Then, rod de-rotation and translation is applied to reduce

the rod into the screw tulips. If the apical vertebra rotation and rib prominence is too much for an appropriate deformity correction and alignment, the surgeon now can consider DVBD with or without thoracoplasty. This can be also performed across the convex rod. Before these steps, the surgeon should identify the rostral and caudal neutral vertebrae and secure them with derotation devices to act as a counterforce to the rotatory manoeuvres. De-rotation devices, or tubes, can now be attached to each adjacent screw and corrective axial force applied (Fig. 2). The convex de-rotation device should be forced downward and medially while the concave one should be forced upward by a pulling vector. Simultaneously, the neutral vertebrae should be forced towards opposite side, and additional downward force can be applied across the rib hump.¹⁴

2. *En Bloc* derotation:

The *en bloc* de-rotation is performed with the same exposure. In this method, the de-rotation devices are attached to all intervening levels. The entire segment can now be linked through a locking device, and these locking devices can also be linked to each other with a cross-link, to provide simultaneous rotation of the entire bloc (Fig. 2).¹⁴ According to the study by Mattel et al, the *en bloc* de-rotation technique was found to be associated with better outcomes including significant effect on radiographic spinal column de-rotation and less flattening of thoracic kyphosis, but this thoracic rib hump correction was not maintained at the two-year follow-up.¹⁵ Hwang et al found no significant difference in curve correction and rib prominence reduction. Furthermore, they had increased operative time, estimated blood loss, and volume of blood transfused.¹⁴

Implant type and density may also affect the outcomes with the "manoeuvre" method. Mono-axial pedicle screws, compared with multi-axial screws, are known to allow better correction of scoliosis and significantly improved rib cage symmetry when using the DVBD technique.^{20,21} This better correction of rotational deformity in the transverse plane can be attributed to no degree of freedom between the head and the body of the pedicle screw.²¹ A third type of pedicle screw was introduced, the head of which pivots in only one plane (sagittal), and theoretically, it provides more effortless rod loading whilst maintaining the ability of mono-axial screws to de-rotate the spine.²² In 2011, Wang et al reported the MDOF system in which screws are connected to rods with post-connectors providing 6°-of-freedom (translation in two planes and rotation in four planes) relative motion while mono-axial screws provide 2°-of-freedom (only translation and rotation). This is done by a pivoting post connected to a pedicle screw and a joint connecting the post to rod. This system provided more flexibility in achieving the final configuration of the spine and more ways of attaining the desired configuration.²³

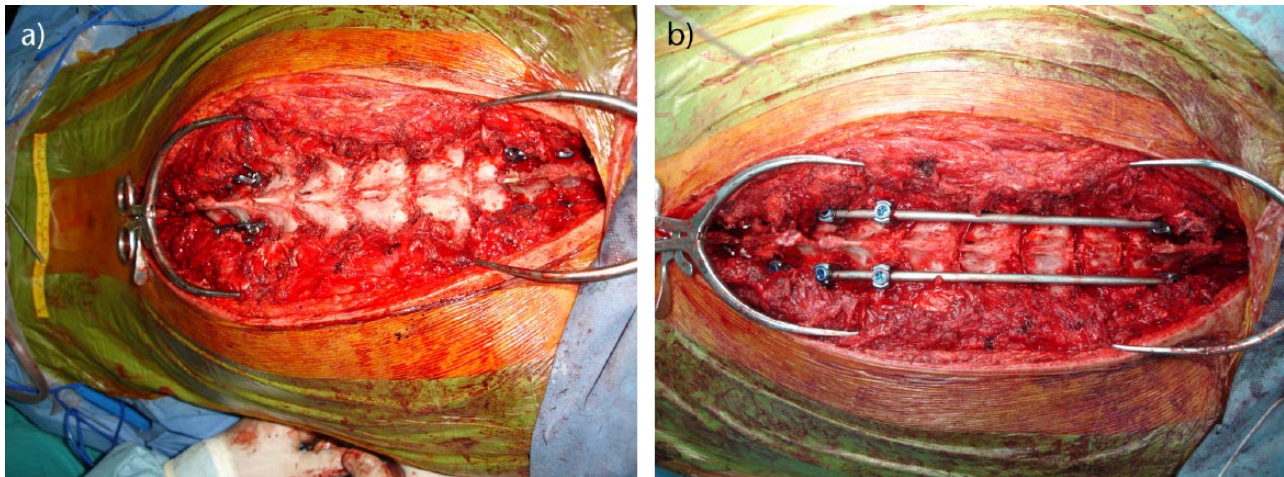


Fig. 3 Operative photographs showing the use of the cantilever manoeuvre typically for the correction of kyphosis. a) The photograph shows the upper and lower pedicle screw foundations. b) After multiple Smith-Petersen osteotomies were done at the apex, kyphosis was corrected by using the cantilever manoeuvre.

For the challenging severe rigid curves, some osteotomies, such as the Smith-Petersen osteotomy, pedicle subtraction osteotomy, asymmetric pedicle subtraction osteotomy or vertebral column resection, can also be performed. Instead of those major approaches to the spinal column, some minor intervention methods can be used to avoid complications such as spinal cord and major vessel injuries. Minor approaches can also provide efficient deformity corrections, according to some studies. Wiemann et al investigated the contribution of each facetectomy, rib resection, and both in cadavers and found 18%, 36%, and 47%, respectively, decrease in torque needed to de-rotate the deformed vertebral column producing 25° correction at individual segments, and pronounced these choices as very efficient applications.²⁴

The other types of correction manoeuvres include cantilever forces, compression-distraction forces, and *in situ* rod bending.

3. Cantilever force:

This type of manoeuvre is probably the most common technique used in rod reduction by spinal surgeons. It can also be used in combination with the other techniques. After bending to the desired contour for optimal sagittal alignment, rods are connected sequentially to each pedicle screw or hook one by one. As the screws are connected to the rods, the spine begins to take the shape of the rods and comes into the desired sagittal and coronal alignment. In severe curves, connecting the screws to the rods may be difficult without an extra manoeuvre. One option can be the use of reduction screws and persuaders for these cases. These screws have an extra-long tulip to facilitate the connection of rods to screws, which are then broken following the tightening of set screws. To provide screw pull-out during this manoeuvre, the surgeon should apply the reduction

forces to as many screws as possible simultaneously as the spine is brought to the contoured rod. Another important tip is bending the operating table in order to extend the trunk of the patient. This prevents the pull-out of the screws during correction of kyphosis (Fig. 3). The Cantilever manoeuvre was previously shown to be effective, even without anterior release.¹ It can also be performed in anterior approaches for thoracic scoliosis correction.¹

4. Compression-distraction forces:

These forces can be applied at all segments of the spinal construct to improve both coronal and sagittal alignment. Typically, the intervertebral discs are opened more on the convex side, and the compression force is applied along the convexity of the curve. The opposite holds true for the distraction force. These forces are usually performed for the fine-tuning of the spine after the cantilever and derotation manoeuvres are finished. But, one should keep in mind that the compression results in hyperlordosis and hypokyphosis while distraction results in hypolordosis and hyperkyphosis, and care must be taken to preserve sagittal alignment. With the reduction in intervertebral motion, the spine is thought to improve stability with fusion after instrumentation, and previous researchers have postulated that stiffer constructs allow less intervertebral motion.^{25,26} The compression and distraction forces were shown to be factors enhancing the stability of vertebral column which is of benefit, providing a better environment for spinal fusion offered by a spinal instrumentation system, especially the compression forces and especially in the lumbar region.²⁷

5. *In situ* rod bending

After the connection of the rods, application of the correction manoeuvres, and tightening of the set screws, a

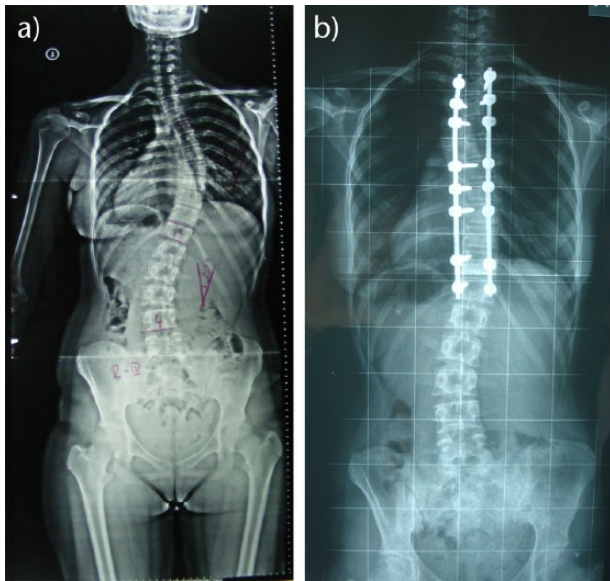


Fig. 4 a) Anteroposterior radiograph of a 15-year-old patient with a Lenke Type-1 curve treated with posterior correction and posterior instrumented fusion. b) Post-operative radiograph shows spontaneous correction of the lumbar curve after selective thoracic fusion.

second fine-tuning manoeuvre can be applied. The rods are held by a vice-grip type plier and bent by *in situ* benders to bring the sagittal and coronal alignment to the desired angles a little bit more. This type of manoeuvre should not be used as a major curve correction method because of the significant stresses applied at the bone-implant interface during the bending force which may result in implant insufficiency. The spring-back phenomena is also a complicating factor for *in situ* bending which prevents preserving the acquired deformity correction after the removal of the bending force. Furthermore, the amount of deformity created by bending the rod while connected to the vertebral column stays under that needed to arrive at the yield point of the material. These drawbacks can be minimised by the use of malleable stainless rods.²⁸

Spontaneous correction

Spontaneous correction can be possible in two situations. One is spontaneous correction in the same plane. Spontaneous correction of a minor curve is possible after selective fusion of a major curve in adolescent idiopathic scoliosis²⁹ (Fig. 4). Another type is spontaneous correction in another plane. For instance, during the coronal curve correction a limited correction can spontaneously arise in the axial plane. This can be explained by the coupling phenomenon which refers a harmonious association of one motion around an axis on a particular plane with another motion around a second axis in another plane.

Thus, any manoeuvre that corrects the deformity in one plane should affect deformities in other planes.³⁰

It is crucial to understand the applied biomechanics of the spine for proper implementation of correction manoeuvres. The visco-elastic nature of the spine and surrounding tissues is a very important concept. The surgeon should carefully check and, if necessary refine the correction at the end of the operation based on this biomechanical concept.

AUTHOR INFORMATION

¹Gazi University Faculty of Medicine, Ankara, Turkey

²Erzincan University, Mengucek Gazi Education and Research Hospital, Erzincan, Turkey

Correspondence should be sent to: Dr A. Senkoylu, Gazi University Faculty of Medicine, Besevler, 06510, Ankara, Turkey.

Email: drsenkoylu@gmail.com

ICMJE CONFLICT OF INTEREST STATEMENT

None

FUNDING STATEMENT

No benefits in any form have been received or will be received from a commercial party related directly or indirectly to the subject of this article.

LICENCE

© 2017 The author(s)

This article is distributed under the terms of the Creative Commons Attribution-Non Commercial 4.0 International (CC BY-NC 4.0) licence (<https://creativecommons.org/licenses/by-nc/4.0/>) which permits non-commercial use, reproduction and distribution of the work without further permission provided the original work is attributed.

REFERENCES

1. Chang KW. Cantilever bending technique for treatment of large and rigid scoliosis. *Spine* 2003;28:2452-2458.
2. Little EM, Bryant T. *On the causes of rotation of the vertebrae in scoliosis*. London, UK: John Bale & Sons, 1891.
3. Vora V, Crawford A, Babekhir N, et al. A pedicle screw construct gives an enhanced posterior correction of adolescent idiopathic scoliosis when compared with other constructs: myth or reality. *Spine* 2007;32:1869-1874.
4. Lehman RA Jr, Lenke LG, Keeler KA, et al. Operative treatment of adolescent idiopathic scoliosis with posterior pedicle screw-only constructs: minimum three-year follow-up of one hundred fourteen cases. *Spine* 2008;33:1598-1604.
5. Suk SI, Lee CK, Kim WJ, Chung YJ, Park YB. Segmental pedicle screw fixation in the treatment of thoracic idiopathic scoliosis. *Spine* 1995;20:1399-1405.
6. Rho JY, Tsui TY, Pharr GM. Elastic properties of human cortical and trabecular lamellar bone measured by nanoindentation. *Biomaterials* 1997;18:1325-1330.
7. Meyers MA, Chawla KK. Chapter 2: *Elasticity and viscoelasticity*. *Mechanical behavior of materials*. 2nd Ed. New York. Cambridge University Press; 2009:71-160.
8. O'Brien MF, Lenke LG, Bridwell KH, Blanke K, Baldus C. Preoperative spinal canal investigation in adolescent idiopathic scoliosis curves > or = 70 degrees. *Spine* 1994;19:1606-1610.

9. **Koptan W, EIMiligui Y.** Three-staged correction of severe rigid idiopathic scoliosis using limited halo-gravity traction. *Eur Spine J* 2012;21:1091-1098.
10. **Edgar MA, Chapman RH, Glasgow MM.** Pre-operative correction in adolescent idiopathic scoliosis. *J Bone Joint Surg [Br]* 1982;64-B:530-535.
11. **Greiner KA.** Adolescent idiopathic scoliosis: radiologic decision-making. *Am Fam Physician* 2002;65:1817-1822.
12. **Pizones J, Sánchez-Mariscal F, Zúñiga L, Izquierdo E.** The effect of sublaminar wires on the rib hump deformity during scoliosis correction maneuvers. *Eur J Orthop Surg Traumatol* 2016;26:771-777.
13. **Hwang SW, Dubaz OM, Ames R, et al.** The impact of direct vertebral body derotation on the lumbar prominence in Lenke Type 5C curves. *J Neurosurg Spine* 2012;17:308-313.
14. **Hwang SW, Samdani AF, Cahill PJ.** The impact of segmental and en bloc derotation maneuvers on scoliosis correction and rib prominence in adolescent idiopathic scoliosis. *J Neurosurg Spine* 2012;16:345-350.
15. **Mattila M, Jalanko T, Helenius I.** En bloc vertebral column derotation provides spinal derotation but no additional effect on thoracic rib hump correction as compared with no derotation in adolescents undergoing surgery for idiopathic scoliosis with total pedicle screw instrumentation. *Spine* 2013;38:1576-1583.
16. **Suk SI, Kim JH, Kim SS, Lee JJ, Han YT.** Thoracoplasty in thoracic adolescent idiopathic scoliosis. *Spine* 2008;33:1061-1067.
17. **Samdani AF, Hwang SW, Miyajji F, et al.** Direct vertebral body derotation, thoracoplasty, or both: which is better with respect to inclinometer and scoliosis research society-22 scores? *Spine* 2012;37:E849-E853.
18. **Samdani AF, Asghar J, Miyajji F, et al.** Recurrence of rib prominence following surgery for adolescent idiopathic scoliosis with pedicle screws and direct vertebral body derotation. *Eur Spine J* 2015;24:1547-1554.
19. **Winter RB, Lonstein JE, Denis F.** How much correction is enough? *Spine* 2007;32:2641-2643.
20. **Kuklo TR, Potter BK, Polly DW Jr, Lenke LG.** Monoaxial versus multiaxial thoracic pedicle screws in the correction of adolescent idiopathic scoliosis. *Spine* 2005;30:2113-2120.
21. **Martino J, Aubin CE, Labelle H, Wang X, Parent S.** Biomechanical analysis of vertebral derotation techniques for the surgical correction of thoracic scoliosis. A numerical study through case simulations and a sensitivity analysis. *Spine* 2013;38:E73-E83.
22. **Dalal A, Upasani VV, Bastrom TP, et al.** Apical vertebral rotation in adolescent idiopathic scoliosis: comparison of uniplanar and polyaxial pedicle screws. *J Spinal Disord Tech* 2011;24:251-257.
23. **Wang X, Aubin CE, Crandall D, Labelle H.** Biomechanical comparison of force levels in spinal instrumentation using monoaxial versus multi degree of freedom postloading pedicle screws. *Spine* 2011;36:E95-E104.
24. **Wiemann J, Durrani S, Bosch P.** The effect of posterior spinal releases on axial correction torque: a cadaver study. *J Child Orthop* 2011;5:109-113.
25. **Farcy JP, Weidenbaum M, Michelsen CB, Hoeltzel DA, Athanasiou KA.** A comparative biomechanical study of spinal fixation using Cotrel-Dubousset instrumentation. *Spine* 1987;12:877-881.
26. **Ashman RB, Birch JG, Bone LB, et al.** Mechanical testing of spinal instrumentation. *Clin Orthop Relat Res* 1988;227:113-125.
27. **Goodwin RR, James KS, Daniels AU, Dunn HK.** Distraction and compression loads enhance spine torsional stiffness. *J Biomech* 1994;27:1049-1057.
28. **Noshchenko A, Xianfeng Y, Armour GA, et al.** Evaluation of spinal instrumentation rod bending characteristics for in-situ contouring. *J Biomed Mater Res B Appl Biomater* 2011;98:192-200.
29. **Senkoylu A, Luk KD, Wong YW, Cheung KM.** Prognosis of spontaneous thoracic curve correction after the selective anterior fusion of thoracolumbar/lumbar (Lenke 5C) curves in idiopathic scoliosis. *Spine J* 2014;14:1117-1124.
30. **Luk KD, Cheung WY, Wong Y, et al.** The predictive value of the fulcrum bending radiograph in spontaneous apical vertebral derotation in adolescent idiopathic scoliosis. *Spine* 2012;37:E922-E926.