

# Gallbladder Adenomyomatosis in an Infant

Charles B. Chen, MD<sup>1</sup>, and Mohammad Nasser Kabbany, MD<sup>1</sup>

<sup>1</sup>Cleveland Clinic Foundation, Cleveland, OH

## ABSTRACT

Gallbladder adenomyomatosis is a rare condition that is predominantly seen in adults, and only a few cases have been described in the pediatric population. Although it is generally benign, it may present a diagnostic challenge for physicians. Advances in imaging have led to an increase in its detection. Nevertheless, the characteristics and management of this condition in pediatric patients have not been well described. We present a case of a 6-week-old infant boy who was found to have gallbladder adenomyomatosis.

## INTRODUCTION

Gallbladder adenomyomatosis is characterized by hypertrophy of the gallbladder mucosal epithelium and invagination of the mucosa into the thickened muscular layer, causing the formation of sinus tracts called Rokitansky-Aschoff sinuses (RAS).<sup>1</sup> It is most frequently seen in adults, and the incidence increases with age as most of the detected individuals are past their fifth decade of life.<sup>2</sup> In fact, this condition has been found in up to almost 10% of cholecystectomy specimens.<sup>3,4</sup> However, gallbladder adenomyomatosis is extremely rare in the pediatric population, and at the time of this literature review, only 9 other cases have been reported.

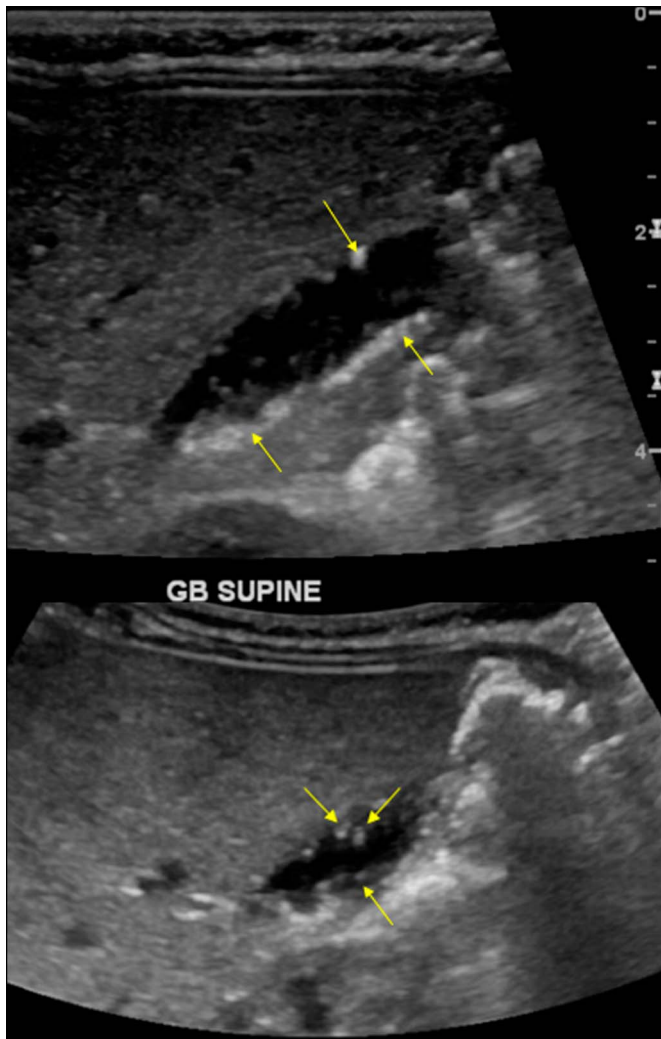
## CASE REPORT

A 6-week-old infant boy born at 37 weeks gestational age was evaluated for jaundice and abnormal findings on imaging. His history was significant for indirect hyperbilirubinemia at 1 week of life requiring phototherapy. He continued to have hyperbilirubinemia at his subsequent visits to his pediatrician and laboratory tests at 6 weeks of age showed a total bilirubin of 13.3 mg/dL, conjugated bilirubin of 0.3 mg/dL, aspartate aminotransferase of 60 U/L, alanine aminotransferase of 38 U/L, and international normalized ratio of 1.0. His complete blood count was unremarkable and reticulocyte count was normal. Both the patient and his mother had O-positive blood type. The newborn screen showed hemoglobin FAS suggestive of sickle cell trait. His mother had a history of alpha-thalassemia trait and sickle cell trait. The patient was exclusively breastfed and had been growing appropriately since birth. Physical examination was unremarkable except for jaundice. An abdominal ultrasound showed a normal liver and echogenic foci within the wall of the gallbladder with a comet-tail artifact (Figure 1). These findings prompted referral to gastroenterology clinic.

The imaging findings were consistent with adenomyomatosis and were unrelated to his jaundice which was attributed to breast milk jaundice. A repeat right upper quadrant ultrasound at 3 months of age showed no significant change from the previous study (Figure 2). A repeat right upper quadrant ultrasound at 6 months of age showed fewer and smaller echogenic foci. His most recent ultrasound at 15 months of age showed normal appearance of the gallbladder wall (Figure 3). The patient continued to do well clinically.

## DISCUSSION

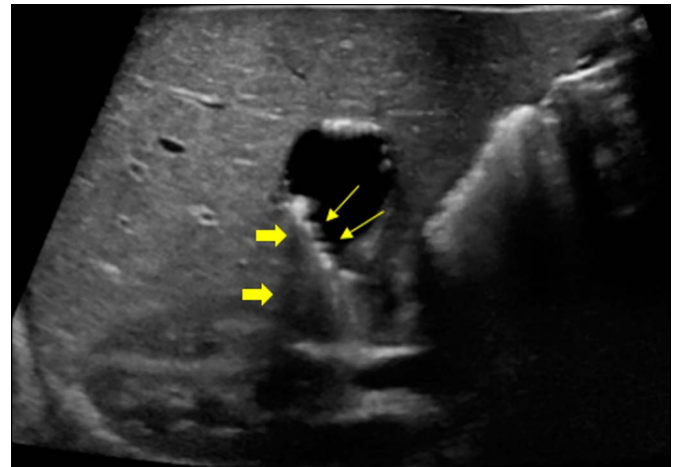
The exact pathophysiology of gallbladder adenomyomatosis remains unknown, although a number of hypotheses have been postulated. One theory is that changes in intracystic pressure (possibly because of abnormal muscle contraction) because of disruption of gallbladder function may lead to proliferation of the cells in the gallbladder mucosa and hyperplasia of the muscle layer. The epithelial layer can then invaginate into the muscular layer, leading to the formation of RAS. This is also seen on histopathology, which generally shows hyperplasia of the epithelium and mucosal outpouching through the muscular layer.<sup>5</sup>



**Figure 1.** Initial ultrasound at 6 weeks of age showing gallbladder adenomyomatosis (arrows).

The differential for gallbladder adenomyomatosis includes cholelithiasis, gallbladder polyps, and cholecystitis.<sup>4</sup> Most importantly, gallbladder malignancy including adenocarcinoma and cholangiocarcinoma must be ruled out. Gallbladder adenomyomatosis is known to be associated with gallstones and cholecystitis. Many patients may not be diagnosed and treated until they develop symptoms from cholelithiasis or other gallbladder conditions. Although there has been data suggesting an association between adenomyomatosis and gallbladder carcinoma in the adult population, adenomyomatosis is still considered a benign condition.<sup>3,6,7</sup> There have not been any studies on the risk of development of gallbladder cancer in pediatric patients with adenomyomatosis.

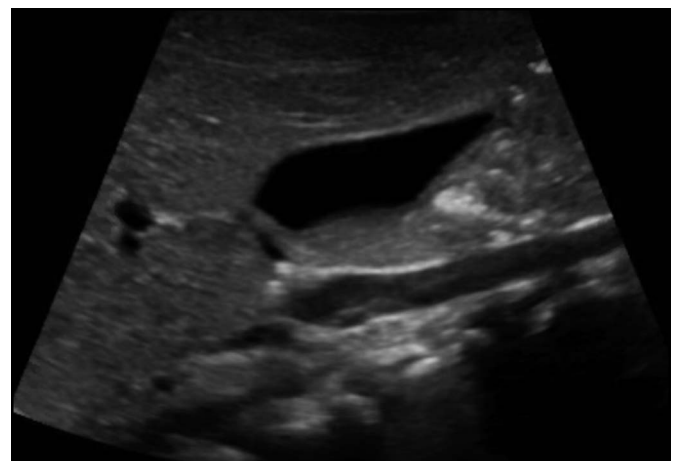
The main patterns of gallbladder adenomyomatosis are generalized, localized, segmental, and annular. The generalized (diffuse) pattern is characterized by diffuse thickening of the gallbladder. The localized pattern usually involves the fundus, and the segmental type typically involves the larger portions of the gallbladder and is likely the type that was observed in our



**Figure 2.** Follow-up ultrasound at 3 months of age shows persistence of gallbladder adenomyomatosis (arrows) and comet-tail artifact (thick arrows).

patient. The segmental type is the most common and has been shown to have the highest rate of causing cholelithiasis given increased risk of biliary stasis. The annular type appears as a ring-shaped thickening that involves the middle portion of the gallbladder.<sup>6,8</sup>

Many patients with gallbladder adenomyomatosis are asymptomatic. However, some individuals may develop symptoms such as right upper quadrant pain and vomiting that is associated with gallbladder disease. A review of the current literature shows only 9 other reported cases of pediatric gallbladder adenomyomatosis, with ages ranging from 1 day to 14 years.<sup>1-3,5,9-13</sup> The most common symptom was abdominal pain, which was seen in 7 of the patients. Cholecystectomy was performed in 7 of the 9 pediatric cases.<sup>9</sup> One patient was a 1-day old newborn with suspected heterotaxy syndrome and complete atrioventricular canal. Patients generally did not have other significant comorbid



**Figure 3.** Follow-up ultrasound at 15 months of age showing resolution of gallbladder adenomyomatosis.

conditions. In both infants, as in our case, gallbladder adenomyomatosis was an incidental finding.<sup>13</sup>

Formal diagnosis is often made with radiographic imaging, and ultrasound is the preferred imaging modality. On ultrasound, gallbladder wall thickening is frequently seen. Other features include the presence of RAS, which is critical to the diagnosis of gallbladder adenomyomatosis.<sup>1</sup> In addition, a “comet-tail” finding may be present because of the reverberation of signals of cholesterol crystals that are present in RAS. Computed tomography and magnetic resonance imaging have also been used in the diagnosis of this condition. On computed tomography, nonspecific wall thickening is often noted. In some cases, a “rosary sign” is found, which is due to the enhancement of the mucosa epithelium in the RAS surrounded by the unenhanced muscle layer.<sup>14</sup> Similarly, magnetic resonance imaging shows gallbladder wall thickening along with the presence of RAS. The “pearl necklace” sign has also been described as high intensity cavities in the gallbladder wall, which are representative of RAS.<sup>15</sup>

Although there is literature on the treatment of adults with gallbladder adenomyomatosis, there is a lack of data on management in pediatric patients. In asymptomatic individuals, monitoring with serial ultrasounds is often recommended. However, there is little data on the length of time it takes for gallbladder adenomyomatosis to resolve. In the reported pediatric cases, all of the patients who were symptomatic underwent cholecystectomy with subsequent resolution of symptoms. In our patient, although the ultrasound findings improved after 6 months, it did not resolve completely until 15 months of age. The benefits and risks of surgery must be weighed against the severity of the patient’s symptoms and the effect on their quality of life. This condition is rare in children, its benign nature and frequent absence of symptoms make it harder to detect. Although uncommon, it is important to consider gallbladder adenomyomatosis when patients present with gastrointestinal symptoms. It is possible that many pediatric patients have adenomyomatosis that may not be detected until much later in life.

## DISCLOSURES

**Author contributions:** Both authors contributed equally to this manuscript. MN Kabbany is the article guarantor.

**Financial disclosure:** None to report.

**Informed consent** was obtained for this case report.

**Previous presentation:** This case was presented at the North American Society for Pediatric Gastroenterology, Hepatology and Nutrition, October 17-19, 2019; Chicago, Illinois.

Received February 9, 2020; Accepted May 21, 2020

## REFERENCES

- Zarate YA, Bosanko K, Jarasvaraparn C. Description of the first case of adenomyomatosis of the gallbladder in an infant. *Case Rep Pediatr.* 2014; 2014(2014):248369.
- Eroglu N, Erduran E, Imamoglu M, et al. Diffuse adenomyomatosis of the gallbladder in a child. *J Pediatr Hematol Oncol.* 2016;38(8):e307–9.
- Parolini F, Indolfi G, Magne MG, et al. Adenomyomatosis of the gallbladder in childhood: A systematic review of the literature and an additional case report. *World J Clin Pediatr.* 2016;5(2):223–7.
- Bonatti M, Vezzali N, Lombardo F, et al. Gallbladder adenomyomatosis: Imaging findings, tricks and pitfalls. *Insights Imaging.* 2017;8(2):243–53.
- Akcam M, Buyukyavuz I, Ciris M, et al. Adenomyomatosis of the gallbladder resembling honeycomb in a child. *Eur J Pediatr.* 2008;167(9):1079–81.
- Pang L, Zhang Y, Wang Y, et al. Pathogenesis of gallbladder adenomyomatosis and its relationship with early-stage gallbladder carcinoma: An overview. *Braz J Med Biol Res.* 2018;51(6):e7411.
- Ootani T, Shirai Y, Tsukada K, et al. Relationship between gallbladder carcinoma and the segmental type of adenomyomatosis of the gallbladder. *Cancer.* 1992;69(11):2647–52.
- Nishimura A, Shirai Y, Hatakeyama K. Segmental adenomyomatosis of the gallbladder predisposes to cholecystolithiasis. *J Hepatobiliary Pancreat Surg.* 2004;11(5):342–7.
- Alapati S, Braswell LE. Neonatal adenomyomatosis of the gallbladder: An incidental finding at 12 hours of life. *Radiol Case Rep.* 2014;9(3):859.
- Alberti D, Callea F, Camoni G, et al. Adenomyomatosis of the gallbladder in childhood. *J Pediatr Surg.* 1998;33(9):1411–2.
- Zani A, Pacilli M, Conforti A, et al. Adenomyomatosis of the gallbladder in childhood: Report of a case and review of the literature. *Pediatr Dev Pathol.* 2005;8(5):577–80.
- Cetinkursun S, Surer I, Deveci S, et al. Adenomyomatosis of the gallbladder in a child. *Dig Dis Sci.* 2003;48(4):733–6.
- Agrusti A, Gregori M, Salviato T, et al. Adenomyomatosis of the gallbladder as a cause of recurrent abdominal pain. *J Pediatr.* 2018;202:328.
- Boscak A, Al-Hawary M, Ramsburgh S. Adenomyomatosis of the gallbladder. *RadioGraphics.* 2006;26(3):941–6.
- Catalano OA, Sahani DV, Kalva SP, et al. MR imaging of the gallbladder: A pictorial essay. *Radiographics.* 2008;28(1):135–55.

**Copyright:** © 2020 The Author(s). Published by Wolters Kluwer Health, Inc. on behalf of The American College of Gastroenterology. This is an open-access article distributed under the terms of the Creative Commons Attribution-Non Commercial-No Derivatives License 4.0 (CCBY-NC-ND), where it is permissible to download and share the work, provided it is properly cited. The work cannot be changed in any way or used commercially without permission from the journal.