



Human Milk-Derived Fortifier to Reduce Hospital-Acquired Malnutrition in Uncomplicated Gastroschisis: A Case Report

Anna Strle, RDN, LD¹ Sarah M. Reyes, PhD² Megan Schmidt, MD¹ Mary Frances Lynch, MD¹

¹ Neonatal Intensive Care Unit, Texas Health Harris Methodist Hospital Fort Worth, Fort Worth, Texas

² Rev Bioscience, LLC, Boise, Idaho

Address for correspondence Anna Strle, RDN, LD, CNSC, Neonatal Intensive Care Unit, Texas Health Harris Methodist Hospital, Fort Worth, 1301 Pennsylvania Ave, Fort Worth, TX 76104 (e-mail: AnnaStrle@texashealth.org).

AJP Rep 2024;14:e275–e280.

Abstract

Gastroschisis is one of the most common congenital gastrointestinal disorders, occurring in about one in 1,953 infants born each year in the United States. Infants with gastroschisis rely on total parenteral nutrition (TPN) preoperatively, and due to intestinal function and dysmotility issues, continue to face feeding challenges post-closure, including feeding intolerance and increased risk of necrotizing enterocolitis (NEC). Postclosure, human milk-feeding is preferred over infant formula because of its associated reduced risk of feeding intolerance and NEC. However, unfortified human milk often falls short of meeting the increased metabolic demands of these postsurgical infants in the first few weeks of life, leading to hospital-acquired malnutrition (undernutrition) as TPN is weaned. We hypothesized that fortifying maternal milk with human milk-based fortifiers would mitigate the risk of hospital-acquired malnutrition while providing the tolerance benefits of an exclusive human milk diet, specifically by meeting the increased energy and protein demands of the immediate postsurgical infant as parenteral nutrition is weaned. The case report describes our unit's use of a human milk-based fortifier in an infant with uncomplicated gastroschisis and its positive effect on the patient's growth. Further research is warranted to assess the use of human milk-derived fortifiers to prevent hospital-acquired malnutrition after gastrointestinal surgery.

Keywords

- ▶ malnutrition
- ▶ case report
- ▶ human milk
- ▶ human milk fortifier
- ▶ gastroschisis

Gastroschisis is a congenital defect characterized by herniation of the intestines and other abdominal contents through an anterior abdominal wall defect, typically located on the right side of the umbilicus. Herniated intestines are not covered in a membrane, thus are exposed to the amniotic fluid in utero. Gastroschisis is a relatively common congenital gastrointestinal defect occurring in about one in every 1,953 infants born each year in the United States.¹ While its

etiology is unknown, gastroschisis is more common in infants born to young mothers.^{2,3} Risk factors also include maternal smoking before or during pregnancy, illicit drug use, and genitourinary infection within 3 months before or 3 months after becoming pregnant.^{4–7}

All gastroschisis cases require surgical repair after birth, either as a primary closure shortly after birth or a staged closure utilizing a silo with reduction of the bowel into the

received
July 10, 2024
accepted after revision
November 22, 2024

DOI <https://doi.org/10.1055/a-2490-3521>.
ISSN 2157-6998.

© 2024. The Author(s).

This is an open access article published by Thieme under the terms of the Creative Commons Attribution-NonDerivative-NonCommercial-License, permitting copying and reproduction so long as the original work is given appropriate credit. Contents may not be used for commercial purposes, or adapted, remixed, transformed or built upon. (<https://creativecommons.org/licenses/by-nc-nd/4.0/>)

Thieme Medical Publishers, Inc., 333 Seventh Avenue, 18th Floor, New York, NY 10001, USA

abdominal cavity over several days. Infants with gastroschisis have high rates of intestinal dysmotility even after closure and the incidence of necrotizing enterocolitis (NEC) is reported to be between 10 and 20% in this population.^{8,9} Human milk is the preferred choice for nutrition after gastroschisis closure as it is usually well tolerated in infants at risk of intestinal failure.¹⁰ This is presumably because human milk contains a variety of bioactive factors that aid in the development of gut barrier function, succession of the microbiome, and the maturation of the infant immune system.^{11–14} Compared with formula feeding, human milk feeding has been associated with reduced incidence of NEC and earlier time to discharge in high-risk infants with gastroschisis after repair.^{15–18} Importantly, however, unfortified human milk alone may not meet the in-hospital nutritional requirements for these infants as they, compared with healthy term infants, have increased protein and caloric demands during the early postoperative course to support optimal healing.^{10,19}

Hospital-Acquired Malnutrition (Undernutrition)

Deteriorating nutritional status during hospitalization, also known as hospital-acquired malnutrition (undernutrition),²⁰ is common among infants with gastroschisis.^{21–23} The Academy of Nutrition and Dietetics (the Academy) and the American Society for Parenteral and Enteral Nutrition (A.S.P.E.N.) authored a joint consensus statement on the indicators recommended for the identification and documentation of pediatric and neonatal malnutrition.²⁴ Goldberg et al expanded upon these guidelines to diagnose and document malnutrition related to undernutrition in preterm and neonatal populations.²⁵ Some neonatal indicators independently signify malnutrition, such as a decline in weight-for-age Z-score (WAZ) and weight gain velocity. Specifically, a decline in WAZ of 0.8 to 1.2, >1.2 to 2.0, and >2.0 standard deviation (SD) or a weight gain velocity below 75, 50, and 25% of goal indicate mild, moderate, and severe malnutrition, respectively.²⁵

The prevalence of hospital-acquired malnutrition among infants with gastroschisis remains high. Fullerton et al reported 57% of infants with gastroschisis were <10th percentile weight at discharge.²⁶ Similarly, Strobel et al reported 55% of infants with gastroschisis have weight or length growth failure at discharge (z-score change from birth of -0.8 SD or more).²¹ In our facility, approximately 25% of infants with gastroschisis have a diagnosis of malnutrition at the time of discharge. Additionally, growth challenges commonly occur as an infant is weaned off of parenteral nutrition. Hall et al reported a mean decrease in weight standardized scores from birth to discharge of -0.84 ± 0.58 among infants with gastroschisis ($n = 61$).²⁷ Notably, this study observed negative weight velocity around the time of transition from parenteral to enteral feeds, despite tolerating full enteral feeds. Taken together these data suggest that unfortified breast milk alone does not meet the in-hospital nutritional demands of this population.

Fortification with Human Milk-Derived Fortifiers

Fortification with human milk-derived fortifiers for surgical populations has received recent attention. In a randomized trial comparing human milk-derived fortifiers to standard of care among neonates with single ventricle physiology after stage 1 surgical palliation, Blanco et al reported that infants who received human milk-derived fortifiers achieved higher median weight gain velocity and a significantly decreased incidence of NEC.²⁸ The interest in using human milk-derived fortifiers is 2-fold: (1) they can help achieve macronutrient goals, particularly protein requirements for term (2–3 g protein/kg/d) and preterm infants (3.5–4.5 g protein/kg/d)^{25,29,30} and (2) they provide additional bioactive components such as immunoglobulins, growth factors, and a variety of bioactive proteins that help reduce inflammation and promote intestinal growth and development.^{31–33} We hypothesized that fortifying maternal milk with human milk-based fortifiers would mitigate the risk of hospital-acquired malnutrition while providing the tolerance benefits of an exclusive human milk diet, specifically by meeting the increased energy and protein demands of the immediate postsurgical infant as TPN is weaned.

The following case describes our experience using human milk-derived fortifier in addition to human milk (both mother's own milk [MOM] and donor milk) to reduce hospital-acquired malnutrition for an uncomplicated case of simple gastroschisis. This manuscript was prepared following the CARE guidelines (<https://www.care-statement.org>). Informed consent was obtained from the parents and the University of Texas Southwest Medical Center's Institution Review Board determined this case to be exempt from formal review.

Case Description

The patient was a female prenatally diagnosed with gastroschisis and born vaginally after induction of labor at 37^{2/7} weeks. Birthweight was 2,810 g (16.8th percentile and WAZ -0.96 SD), length was 46.5 cm (7.76th percentile and length-for-age Z-score [LAZ] -1.42 SD), and frontal occipital circumference (FOC) was 33.5 cm (37.5th percentile and head circumference-for-age Z-score [HCAZ] -0.32 SD). The pediatric surgeon was able to easily reduce the bowel followed by sutureless closure shortly after birth without complications. Parenteral nutrition, consisting of TPN and SMOFlipid (SMOF) was the sole source of nutrition until infant's bowel function allowed enteral feeding. On day of life (DOL) 7, the patient was diagnosed with cholestasis (direct bilirubin 2.0 mg/dL). Consequently, SMOF lipids were reduced to 2 g/kg/d for liver preservation and minimal enteral feedings of unfortified human milk were successfully started. Enteral feeds with unfortified human milk were advanced based on the infant's tolerance. Human milk feeds were primarily (>85%) MOM. When MOM was insufficient for a particular feed, donor milk was used to supplement.

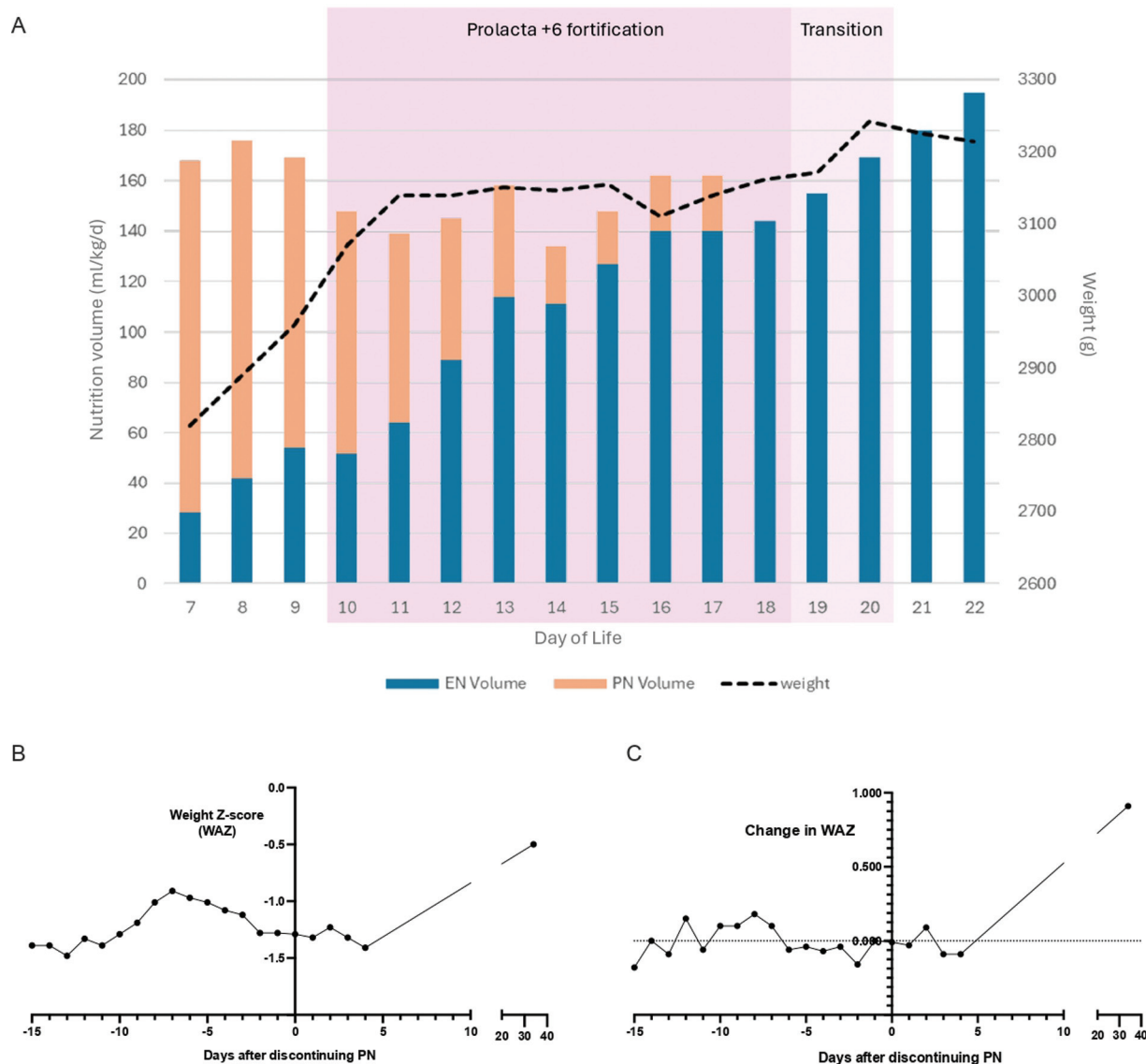


Fig. 1 Schema representing (A) weight gain trajectory and nutrition support from start of enteral feeding through discharge. (B) Daily weight z score (WAZ) and (C) Change in daily WAZ during hospitalization through postdischarge outpatient visit. EN, enteral nutrition; PN, parenteral nutrition; WAZ, weight-for-age z score.

Fortification with a human milk-based human milk fortifier started when feeds reached 50 mL/kg/d mimicking our neonatal intensive care unit's fortification guideline for premature infants (► **Fig. 1A**). Total calories and protein received from enteral and parenteral nutrition during the study period are available in ► **Table 1**. Overall, our patient received 113 to 149 kcal/kg/d and 2.8 to 4.2 g protein/kg/d during the fortification period. The infant reached full enteral feedings of 140 mL/kg/d by DOL 14. TPN and SMOF were discontinued on DOL 15 and the infant began an oral challenge, in which the infant was allowed oral feeds ad libitum without gavage. TPN and SMOF were briefly resumed when oral intake was inadequate but were again stopped on DOL 18 when oral intake improved. During the fortification period (DOL 10–20), which coincided with the transition from parenteral to enteral nutrition, our patient gained 172 g, reflecting a change in weight z-score (WAZ) of only -0.22 SD (► **Fig. 1B, C**).

Once the patient achieved appropriate oral intake and weight gain, we began preparing for discharge, which, for all patients includes weaning from human milk-derived fortifiers. On DOL 19, the patient was weaned from Protract +6 (Prolecta Bioscience, Duarte, CA) to unfortified MOM or feeding at the breast. Despite consuming appropriate volumes of MOM (estimated 170–200 mL/kg/d), this infant experienced a slight decrease in weight leading the team to conclude the patient would benefit from additional supplementation. Because Protract +6 is not available for outpatient use, she was prescribed supplementation with 22 kcal/ounce of elemental formula (EleCare) 2 times daily to help weight gain starting on DOL 20 and increased to 3 feeds per day on DOL 22.

During the fortification period the patient's weight increased without signs of feeding intolerance, as evidenced by no feeds held, normal stooling, and only a single bout of emesis, which was recorded as small and partially digested.

Table 1 Feeding and tolerance from start of enteral nutrition through discharge (day of life 7–22)

DOL	Feedings (was all oral for feeds, never needed NGT)	Enteral nutrition		Parenteral nutrition		Total calories (kcal/kg/d)	Total protein (g/kg/d)	Feeding tolerance ^a	
		EN kcal (kcal/kg/d)	EN protein (g/kg/d)	PN kcal (kcal/kg/d)	PN protein (g/kg/d)			Emesis (yes/no)	Stools
7	First feeds—MOM	20	0.3	96	3.8	116	4.1	No	X1 (large, soft)
8	MOM	28	0.4	89	3.7	117	4.1	no	none
9	MOM	36	0.5	80	3.6	116	4.1	no	X1 (large, soft)
10	MOM/DHM +P6	45	1.3	68	2.5	113	3.8	No	X1 (large, loose/seedy)
11	MOM/DHM +P6	55	1.6	58	2.5	113	4.1	No	X3 (small-large, loose/seedy)
12	MOM/DHM +P6	77	2.2	51	2.0	128	4.2	No	X2 (small-mod, soft/seedy)
13	MOM/DHM +P6	99	2.9	40	2.0	139	4.9	No	X8 (small-mod, soft/seedy)
14	MOM/DHM +P6	96	2.8	8	0	104	2.8	No	X4 (small-large, soft/seedy)
15	MOM/DHM +P6	110	3.2	25	0.3	135	3.5	X1 (small, partially digested)	X3 (small-mod, soft/seedy)
16	MOM/DHM +P6	123	3.5	26	0.4	149	3.9	No	X5 (small-large, soft/seedy/loose)
17	MOM/DHM +P6	121	3.5	25	0.3	146	3.8	No	X5 (small-large, soft/seedy)
18	MOM/DHM +P6	125	3.6	-	-	125	3.6	No	X6 (small-large, soft/seedy)
19	MOM/DHM +P6 (starting transition off Pro lacta)	135	3.9	-	-	135	3.9	2 wet burps (small-moderate)	X3 (small-mod, soft/seedy)
20	Finished Pro lacta feeds then started MOM × 6 feeds + 2 feeds per day EleCare 22 cal/oz	146	4.2	-	-	146	4.2	No	X3 (small-large, soft/seedy)
21	MOM x6 and EleCare 22 cal/oz × 2 feeds	126	2.4	-	-	126	2.4	X2 (large, partially digested)	X4 (small-large, soft/seedy)
22	For discharge: increased to 3 feeds per day EleCare 22 cal/oz and 5 feeds MOM (and if no MOM, to give EleCare) just to further help weight gain	134	2.6	-	-	134	2.6	No	X4 (small-large, soft/seedy)

Table 2 Growth velocity from start of enteral nutrition through discharge (day of life: 7–22)

Measurement	Patient growth rate (average)	WHO target growth rate ^a
Weight gain velocity (g/d) ^b	26.3	23–34
Length gain (cm/wk)	1.1	0.8–0.93
FOC gain (cm/wk)	0.8	0.38–0.48

Abbreviation: DOL, day of life; FOC, frontal occipital circumference; WHO, World Health Organization.

^aWHO target guidelines for term infants aged 0–4 months.³⁴

^bAfter regaining birthweight

She was discharged home on DOL 22 (gestational age: 40^{1/7} weeks). At discharge, the patient weighed 3,214 g (7.98th percentile and WAZ -1.41 SD) with an FOC of 36 cm (62.3rd percentile and HCAZ $+0.31$ SD) and length 50 cm (13.4th percentile and LAZ -1.11 SD). Overall, this patient experienced a better growth trajectory than reference data^{21,26,27} (►Table 2). She regained birthweight by DOL 6. From the start of enteral feeding (DOL 7) to discharge (DOL 22), she had an average weight, length, and FOC gain meeting or exceeding goals set by the World Health Organization for term infants 0 to 4 months³⁴ (►Fig. 1 and ►Table 2). Additionally, her change in WAZ and LAZ from birth to discharge were -0.45 and $+0.31$ SD, respectively; thus, no indication of malnutrition at discharge²⁵ (►Fig. 1 and ►Table 2). Furthermore, 30 days after discharge (34 days after discontinuation of PN), she had a net increase in WAZ $+0.46$ SD.

Discussion

This case demonstrates that a human milk-derived fortifier along with human milk supports adequate growth without signs of feeding intolerance in infants after gastroschisis repair, and it may also help clinicians ensure an exclusive human milk diet during the postoperative period. Maintaining an exclusive human milk diet is thought to be important to aid in healing as many bioactive components in human milk improve gut barrier function, and human milk-fed infants often have improved health outcomes than those fed formula, such as a reduced risk of NEC.^{11,19,35}

Infants with gastroschisis have a high risk of growth failure, and the highest rate of growth failure occurs during the transition period from parenteral to enteral nutrition, similar to what is observed in preterm infants.^{21,27,36} In our case, we intentionally implemented a fortification strategy during the transition period from parenteral to enteral nutrition to minimize the negative weight velocity typically observed during this period. This approach was successful, as evidenced by our patient's outcomes, namely a change in weight and length z-scores (WAZ and LAZ) from birth to discharge of -0.45 SD and $+0.31$ SD, respectively, significantly better than reference data,^{21,26,27} and no indication of malnutrition at discharge.²⁵

A growing body of literature suggests that an exclusive human milk diet, including human milk-derived fortifiers are advantageous during the postoperative period for critically ill infants, including those who have undergone gastrointestinal or cardiac surgeries.^{28,37} This case supports these

findings and suggests that feeding protocols using human milk-derived fortifiers could follow existing protocols for premature infants. In our unit, we begin fortifying preterm infants to 26 kcal/ounce with human milk-derived fortifiers starting at 50 mL/kg/d. This gastroschisis patient followed the same protocol and this early fortification was well tolerated. Notably, however, we fortified this gastroschisis patient for fewer days overall than we would have for a preterm infant. For these reasons, we recommend future research focused on timing and feeding advancement protocols using human milk-derived fortifiers for infants recovering from gastrointestinal surgery.

Conclusion

Meeting the nutritional needs of surgical infants after gastroschisis repair is critical to avoiding hospital-acquired malnutrition. As shown in this case, the use of a human milk-derived fortifier in addition to maternal and donor milk in this term infant with uncomplicated gastroschisis was well tolerated by the infant and supported appropriate growth without hospital-acquired malnutrition as she weaned off parenteral nutrition. This novel strategy allows provision of an exclusive human milk diet while meeting the increased nutritional demands of the surgical infant during feeding advancement. While our case report is encouraging, studies of this feeding strategy for infants with gastroschisis are needed to determine the impact of this strategy on hospital-acquired malnutrition, feeding tolerance, and length of stay in this vulnerable, high-risk population.

Conflict of Interest

Sarah M. Reyes serves as an independent consultant for ProLacta Bioscience and received financial support to write the manuscript. The other coauthors report no conflict of interest.

References

- 1 Mai CT, Isenburg JL, Canfield MA, et al; National Birth Defects Prevention Network. National population-based estimates for major birth defects, 2010–2014. *Birth Defects Res* 2019;111(18):1420–1435
- 2 Kirby RS, Marshall J, Tanner JP, et al; National Birth Defects Prevention Network. Prevalence and correlates of gastroschisis in 15 states, 1995 to 2005. *Obstet Gynecol* 2013;122(2 Pt 1):275–281
- 3 Jones AM, Isenburg J, Salemi JL, et al. Increasing prevalence of gastroschisis—14 States, 1995–2012. *MMWR Morb Mortal Wkly Rep* 2016;65(02):23–26

- 4 Feldkamp ML, Arnold KE, Krikov S, et al. Risk of gastroschisis with maternal genitourinary infections: the US National birth defects prevention study 1997–2011. *BMJ Open* 2019;9(03):e026297
- 5 Mac Bird T, Robbins JM, Druschel C, Cleves MA, Yang S, Hobbs C. National Birth Defects Prevention Study. Demographic and environmental risk factors for gastroschisis and omphalocele in the National Birth Defects Prevention Study. *J Pediatr Surg* 2009;44(08):1546–1551
- 6 Baldacci S, Santoro M, Coi A, Mezzasalma L, Bianchi F, Pierini A. Lifestyle and sociodemographic risk factors for gastroschisis: a systematic review and meta-analysis. *Arch Dis Child* 2020;105(08):756–764
- 7 Fisher SC, Howley MM, Romitti PA, Desrosiers TA, Jabs EW, Browne ML. National Birth Defects Prevention Study. Maternal periconceptional alcohol consumption and gastroschisis in the National Birth Defects Prevention Study, 1997–2011. *Paediatr Perinat Epidemiol* 2022;36(06):782–791
- 8 Oldham KT. Postoperative necrotizing enterocolitis (NEC) in 10 of 54 (18.5%) infants with gastroschisis. *J Pediatr Surg* 1989;24(11):1214
- 9 Phillips JD, Raval MV, Redden C, Weiner TM. Gastroschisis, atresia, dysmotility: surgical treatment strategies for a distinct clinical entity. *J Pediatr Surg* 2008;43(12):2208–2212
- 10 Hair A, Premkumar M. Intestinal failure and intestinal rehabilitation. In: Pammi M, Katakam L eds, *Gastroenterology: Guidelines for Acute Care of the Neonate*. 30th edition (2022–2023) ed. : Baylor College of Medicine; 2022
- 11 Rodríguez-Camejo C, Puyol A, Arbildi P, et al. Effects of human donor milk on gut barrier function and inflammation: in vitro study of the beneficial properties to the newborn. *Front Immunol* 2023;14:1282144
- 12 Brockway MM, Daniel AI, Reyes SM, et al. Human milk bioactive components and child growth and body composition in the first 2 years: a systematic review. *Adv Nutr* 2024;15(01):100127
- 13 Ford SL, Lohmann P, Preidis GA, et al. Improved feeding tolerance and growth are linked to increased gut microbial community diversity in very-low-birth-weight infants fed mother's own milk compared with donor breast milk. *Am J Clin Nutr* 2019;109(04):1088–1097
- 14 Fehr K, Moossavi S, Sbihi H, et al. Breastmilk feeding practices are associated with the co-occurrence of bacteria in mothers' milk and the infant gut: the CHILD Cohort Study. *Cell Host Microbe* 2020;28(02):285–297.e4
- 15 Gulack BC, Laughon MM, Clark RH, et al. Enteral feeding with human milk decreases time to discharge in infants following gastroschisis repair. *J Pediatr* 2016;170:85–89
- 16 Jayanthi S, Seymour P, Puntis JW, Stringer MD. Necrotizing enterocolitis after gastroschisis repair: a preventable complication? *J Pediatr Surg* 1998;33(05):705–707
- 17 Shinnick JK, Wang E, Hulbert C, et al. Effects of a breast milk diet on enteral feeding outcomes of neonates with gastrointestinal disorders. *Breastfeed Med* 2016;11(06):286–292
- 18 Hoban R, Khatri S, Patel A, Unger SL. Supplementation of mother's own milk with donor milk in infants with gastroschisis or intestinal atresia: a retrospective study. *Nutrients* 2020;12(02):589
- 19 Hair AB, Good M. Dilemmas in feeding infants with intestinal failure: a neonatologist's perspective. *J Perinatol* 2023;43(01):114–119
- 20 Mehta NM, Corkins MR, Lyman B, et al; American Society for Parenteral and Enteral Nutrition Board of Directors. Defining pediatric malnutrition: a paradigm shift toward etiology-related definitions. *JPEN J Parenter Enteral Nutr* 2013;37(04):460–481
- 21 Strobel KM, Romero T, Kramer K, et al; University of California Fetal Consortium. Growth failure prevalence in neonates with gastroschisis: a statewide cohort study. *J Pediatr* 2021;233:112–118.e3
- 22 Hong CR, Zurakowski D, Fullerton BS, Ariagno K, Jaksic T, Mehta NM. Nutrition delivery and growth outcomes in infants with gastroschisis. *JPEN J Parenter Enteral Nutr* 2018;42(05):913–919
- 23 Wallon C, Binet A, Bernardo K, et al. Weight-for-height Z-score improves in half of undernourished children hospitalized in surgical wards. *Arch Pediatr* 2020;27(08):403–407
- 24 Becker P, Carney LN, Corkins MR, et al; Academy of Nutrition and Dietetics American Society for Parenteral and Enteral Nutrition. Consensus statement of the Academy of Nutrition and Dietetics/American Society for Parenteral and Enteral Nutrition: indicators recommended for the identification and documentation of pediatric malnutrition (undernutrition). *Nutr Clin Pract* 2015;30(01):147–161
- 25 Goldberg DL, Becker PJ, Brigham K, et al. Identifying malnutrition in preterm and neonatal populations: recommended indicators. *J Acad Nutr Diet* 2018;118(09):1571–1582
- 26 Fullerton BS, Velazco CS, Sparks EA, et al. Contemporary outcomes of infants with gastroschisis in North America: a multicenter cohort study. *J Pediatr* 2017;188:192–197.e6
- 27 Hall NJ, Drewett M, Burge DM, Eaton S. Growth pattern of infants with gastroschisis in the neonatal period. *Clin Nutr ESPEN* 2019;32:82–87
- 28 Blanco CL, Hair A, Justice LB, et al; Cardiac Neonate Nutrition Study Group. A randomized trial of an exclusive human milk diet in neonates with single ventricle physiology. *J Pediatr* 2023;256:105–112.e4
- 29 Koletzko B, Poindexter B, Uauy R. Recommended nutrient intake levels for stable, fully enterally fed very low birth weight infants. *World Rev Nutr Diet* 2014;110:297–299
- 30 Moreira DH, Gregory SB, Younge NE. Human milk fortification and use of infant formulas to support growth in the neonatal intensive care unit. *Nutr Clin Pract* 2023;38(Suppl 2):S56–S65
- 31 Liang N, Koh J, Kim BJ, Ozturk G, Barile D, Dallas DC. Structural and functional changes of bioactive proteins in donor human milk treated by vat-pasteurization, retort sterilization, ultra-high-temperature sterilization, freeze-thawing and homogenization. *Front Nutr* 2022;9:926814
- 32 Meredith-Dennis L, Xu G, Goonatilake E, Lebrilla CB, Underwood MA, Smilowitz JT. Composition and variation of macronutrients, immune proteins, and human milk oligosaccharides in human milk from nonprofit and commercial milk banks. *J Hum Lact* 2018;34(01):120–129
- 33 Lima HK, Wagner-Gillespie M, Perrin MT, Fogleman AD. Bacteria and bioactivity in Holder pasteurized and shelf-stable human milk products. *Curr Dev Nutr* 2017;1(08):e001438
- 34 WHO Multicentre Growth Reference Study Group. WHO child growth standards: Growth velocity based on weight, length and head circumference: Methods and development. World Health Organization, Geneva, Switzerland; 2009
- 35 Meek JY, Noble L. Technical report: breastfeeding and the use of human milk. *Pediatrics* 2022;150(01):e2022057989
- 36 Miller M, Vaidya R, Rastogi D, Bhutada A, Rastogi S. From parenteral to enteral nutrition: a nutrition-based approach for evaluating postnatal growth failure in preterm infants. *JPEN J Parenter Enteral Nutr* 2014;38(04):489–497
- 37 Riddle S, Karpen H. Special populations-surgical infants. *Clin Perinatol* 2023;50(03):715–728