

# Quantitative Electroencephalography Indicators in Children with Acute Purulent Meningitis

V. B. Voytenkov,<sup>1,2</sup> A. A. Vilnitz,<sup>1,3</sup> N. V. Skripchenko,<sup>1,3</sup> E. V. Ekusheva,<sup>2,5</sup>  
N. A. Savelyeva,<sup>4</sup> A. V. Klimkin,<sup>1</sup> N. V. Marchenko,<sup>1</sup> and M. A. Bedova<sup>1</sup>

*Translated from Rossiiskii Fiziologicheskii Zhurnal imeni I. M. Sechenova, Vol. 107, No. 8, pp. 1049–1056, August, 2021. Original article submitted December 1, 2020. Accepted January 12, 2021.*

The aim of the present work was to assess the state of brain bioelectrical activity in children during the acute period of bacterial purulent meningitis, with quantitative mathematical analysis of the changes found. The studies included 31 children on days 1 and 6 from onset of illness: 16 children ( $8.9 \pm 2.4$  years) admitted to the Pediatric Scientific Clinical Center for Infectious Diseases with laboratory confirmation of diagnoses of purulent meningitis (due to *Neisseria meningitidis* ( $n = 11$ ) or *Streptomyces pneumoniae* ( $n = 2$ ) or unidentified pathogen ( $n = 3$ )), along with 15 healthy children. Electroencephalogram (EEG) traces were recorded from all these children in the state of calm waking using a Neuron-Spectrum 4/VP 16-channel electroencephalograph. Clinical assessment of the EEG included analysis of background rhythms, zonal differences, and detection of pathological types of activity. Quantitative analysis consisted of the mean power ( $\mu V^2$ ) and amplitude ( $\mu V$ ) of the  $\alpha$ ,  $\theta$ , and  $\delta$  rhythms, along with mean power ratios –  $\alpha/\theta$  and  $\alpha/\delta$ . Visual analysis of the EEG in 100% of children in the acute period of purulent meningitis showed diffuse slowing with detection of  $\delta$  and  $\theta$  waves. Focal changes in the form of sharp waves were seen in 18.8% of cases (three patients). No cases displayed periodic activity. Meningitis patients showed significant reductions in the  $\alpha/\delta$  ( $p = 0.001$ ) and  $\alpha/\theta$  ( $p = 0.048$ ) spectral ratios. ROC analysis showed that the  $\alpha/\theta$  value was  $<0.18$  and the  $\alpha/\delta$  value was  $<0.02$  (sensitivity 100% and specificity 80%, AUROC 0.9), which may be evidence of the likely development of cerebral edema. Thus, pediatric patients with acute purulent meningitis showed significant impairments to the normal  $\alpha/\theta$  and  $\alpha/\delta$  rhythm power ratios on the EEG, which is presumptively explained by suppression of the functional activity of the thalamus and thalamocortical pathways, as well as the reticular formation of the brain.

**Keywords:** children, electroencephalography, meningitis.

Electroencephalography (EEG) is one of the main methods for evaluating the functional state of the brain and is used when clinical evaluation is impossible, particularly in patients with encephalopathies and coma of various origins [1]. Indications for EEG include diagnoses of paroxysmal states, prognostication of outcomes of pathological states, assessment of bioelectrical activity when there is suspicion of brain

death, etc. [2]. Up to 90% of the native EEG in conditions of calm waking in healthy people is within frequencies of up to 10 Hz, height 40–80  $\mu V$ , i.e., the  $\alpha$  rhythm, or  $\alpha$  activity [3]. Currently the most widely held theory is that the  $\alpha$  rhythm originates in the thalamus, with the thalamic relay nuclei as its main generators [4]. It has been suggested that the  $\alpha$  and  $\theta$  rhythms form the so-called  $\alpha$ - $\theta$  continuum, as the discharge frequency of thalamic neurons changes in the range 2–13 Hz; the hippocampus is regarded as the generation center of the  $\theta$  rhythm [4]. Various diseases produce increases in the representation of the  $\theta$  rhythm in the EEG, which can be explained, particularly in focal brain lesions, by impairments to intercenter interactions and normal neurotransmitter and signal molecule activity ratios [3].

<sup>1</sup> Pediatric Research and Clinical Center for Infectious Diseases, St. Petersburg, Russia; e-mail: vlad203@inbox.ru.

<sup>2</sup> Postgraduate Education Academy, Moscow, Russia.

<sup>3</sup> St. Petersburg State Pediatric Medical University, St. Petersburg, Russia.

<sup>4</sup> Wagner Perm State Medical University, Perm, Russia.

<sup>5</sup> Belgorod State National Research University, Belgorod, Russia.

A variety of nonspecific EEG changes have been recorded and described in inflammatory diseases affecting the meninges (meningitis). The EEG can be normal in aseptic meningitis [5]. Acute purulent meningitis due to streptococcal infection can produce diffuse slowing of bioelectrical activity (BEA) [6]. Pathological changes to BEA in acute purulent meningitis (increased representation of  $\delta$  and  $\theta$  waves, appearance of spike/slow-wave complexes) have a statistically significant predictive capacity for the development of neurological and cognitive complications of neuroinfection [7]. Deviations of different magnitudes in BEA from normal are described in 89% of cases of meningoencephalitis [8]. Bursts of epileptiform activity involving one hemisphere with subsequent generalization were found in a five-month-old patient with acute purulent meningitis of pneumococcal origin [9]. Periodic lateralized bursts of epileptiform activity have also been seen in streptococcal meningitis [10].

Despite the wide spectrum of changes described in different stages of development of acute purulent meningitis, quantitative objective analysis of EEG patterns in this disease remains poorly studied, especially in pediatric practice. Use of quantitative EEG analysis in children with purulent meningitis may be of value as a tool supplementing visual analysis [11]. In this regard, we have studied EEG changes in children in the acute period of purulent meningitis with quantitative mathematical analysis of the data obtained.

The aim of this work was to assess the state of brain BEA in children in the acute period of bacterial purulent meningitis with quantitative mathematical analysis of the changes identified.

**Methods.** A total of 31 children were studied: 16 patients with purulent meningitis ( $8.9 \pm 2.4$  years, nine boys and seven girls), admitted for hospital treatment at the Pediatric Scientific Clinical Center for Infectious Diseases (St. Petersburg) with laboratory confirmed diagnoses of purulent meningitis. Disease etiology was *Neisseria meningitidis* ( $n = 11$ ) or *Streptomyces pneumoniae* ( $n = 2$ ) or unidentified pathogen ( $n = 3$ ). The reference group consisted of 15 healthy children. The groups were comparable in terms of age and sex. Investigations were performed in the acute period of illness on days 1–6 from onset.

Brain BEA traces were recorded in the state of calm waking with the eyes open and closed using a programmable Neuron-Spectrum system with 32 electrodes. Recordings were made using a monopolar lead with electrodes distributed according to the international 10–20 scheme. The reference electrodes were ipsilateral ear electrodes. Bandpass was 0.5–35 Hz. Electrode impedance averaged  $<10$  k $\Omega$ . EEG recordings were made for 15 min. Spectral power analyses were run using artifact-free trace segments using a Neurosoft automatic analyzer.

Clinical evaluation of the EEG included analysis of baseline rhythms, zonal differences, and detection of pathological types of activity. The corresponding laboratory and

instrumental diagnostics were also run, in particular including neuroimaging studies (brain MRI scans) to detect signs of inflammation of both the meninges and the parenchyma. If this was seen, the case was evaluated as meningoencephalitis and was not included in the study.

Visual analysis of the EEG was followed by assessment of mean power ( $\mu V^2$ ) and amplitude ( $\mu V$ ) in the  $\alpha$ ,  $\theta$ , and  $\delta$  rhythms and the ratios of mean spectral power levels, i.e.,  $\alpha/\theta$  and  $\alpha/\delta$ , were computed.

All participants or their legal representatives signed informed consent to take part in the study and its aims were fully explained to them. Studies were run in compliance with the ethical norms of the Helsinki Declaration of the World Medical Association, “Ethical principles for scientific medical studies on humans” with the 2013 amendments and the “Regulations for clinical practice in the Russian Federation,” approved by the Russian Federation Ministry of Health No. 266 of June 19, 2003. The study was approved by the local ethics committee.

Data were processed statistically in Excel, Statistica 10, and MedCalc 15.2.2. Significant differences between pairs of independent sets were identified using the nonparametric Mann–Whitney test (significance level  $p = 0.05$ ). Analysis of the prognostic significance of values (mean  $\alpha$ ,  $\theta$ , and  $\delta$  rhythm power,  $\alpha/\theta$  and  $\alpha/\delta$  ratios of mean spectral powers) for the probability of developing complications of purulent meningitis, i.e., cerebral edema, was by ROC analysis (Receiver Operating Characteristic). A low probability of developing cerebral edema was scored 0 and a high probability was scored 1. Areas under ROC curves (AUROC), which characterize the prognostic strength of the model taking account of values for sensitivity (the proportion of purely positive results) and specificity (the proportion of purely negative results), were computed. Models with good (AUROC 0.7–0.8) and very good (AUROC  $>0.8$ ) predictive ability were selected at optimal levels of sensitivity and specificity.

**Results.** Clinical severity in seven children (44%) was associated with the development of cerebral edema, apparent as suppression of consciousness (to 11–16 points on the Glasgow Coma Score) and stem symptomatology. In four patients, single convulsions were seen at the onset of illness. Anticonvulsant therapy was not started because convulsions were not repeated. Five children (31%) showed a dominance of signs of septic shock (all with purulent meningitis due to *N. meningitidis*) with the development of multiorgan failure. Investigations, particularly neuroimaging, showed changes typical of the acute period of purulent meningitis (Fig. 1).

Visual analysis of the EEG showed diffuse slowing with recording of  $\delta$  and  $\theta$  waves in 100% of cases in the acute period of purulent meningitis. Focal changes in the form of sharp waves were seen in 18.8% of cases (three patients). None of the patients showed periodic activity.

Results obtained from statistical processing showed that patients with meningitis had decreases in the  $\alpha/\delta$  ( $p = 0.001$  (Fig. 2, A) and  $\alpha/\theta$  ( $p = 0.048$ ) (Fig. 2, B) spectral

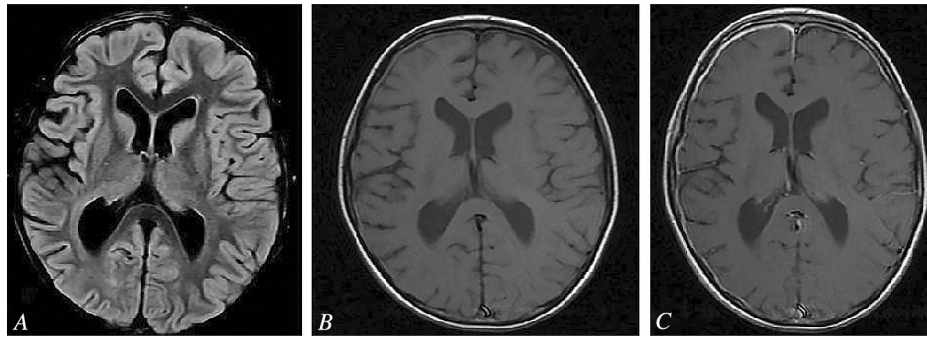


Fig. 1. Changes on MRI brain scans in a patient with clinically confirmed acute purulent meningitis. FLAIR (A) and T1 (B) modes visualize minor thickening of the meninges in the right frontal area. Images in T1 mode with internal contrasting (C) show marked increases in signal from the meninges on the right in the frontal and parietal areas.

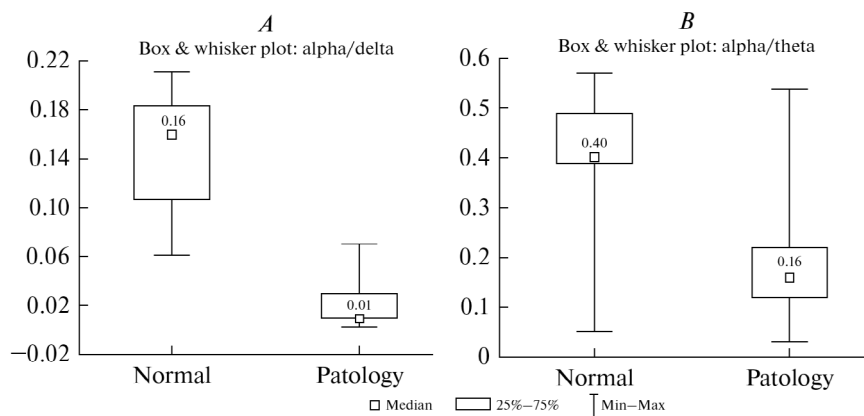


Fig. 2. Significant reductions in the  $\alpha/\delta$  (A) and  $\alpha/\theta$  (B) ratios in patients in the acute period of purulent meningitis as compared with the control group.

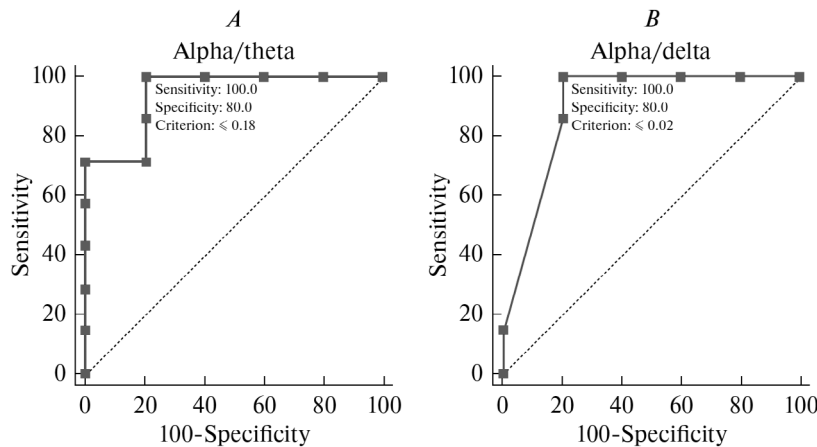


Fig. 3. Results of ROC analysis of the  $\alpha/\theta$  (A) and  $\alpha/\delta$  (B) ratios for prediction of the development of cerebral edema.

ratios, while no significant differences were seen in spectral power in the  $\alpha$ ,  $\delta$ , and  $\theta$  ranges.

ROC analysis showed that a  $\alpha/\theta$  ratio of less than 0.18 and an  $\alpha/\delta$  ratio of less than 0.02 with sensitivity 100% and specificity 80% (AUROC 0.9) could be evidence of the likely development of cerebral edema (Fig. 3). Other parameters had no convincing prognostic value.

**Discussion.** Our data on EEG changes obtained by visual analysis of the EEG were consistent with findings from

other investigators. Thus, visual analysis of the EEG in acute COVID-19-associated meningitis shows diffuse slowing without focal activity [12]. Triphasic waves reflecting encephalopathic changes and described, in particular, in carcinomatous meningitis [13], were not seen in the present study.

Our quantitative analysis of BEA in children with acute purulent meningitis revealed significant decreases in the  $\alpha/\theta$  and  $\alpha/\delta$  EEG rhythm ratios. Power in this case reflects the extent of arousal and the ability of brain structures

to generate particular rhythms. Considering that the source of the  $\alpha$  and  $\theta$  rhythms is the thalamus [3], it can be suggested that temporary suppression or rearrangement of its activity occurs in the acute period of neuroinfection and this also applies to the activity of the reticular formation of the brain; we have previously observed similar transient degradation of neurophysiological measures in acute bacterial purulent meningitis using acoustic brainstem event-related potentials, in acute viral encephalitis using visual event-related potentials, and in serous meningitis using diagnostic transcranial magnetic stimulation [14, 15]. Thus, it is possible that the changes observed here can be regarded as a type reaction. The question of whether this type reaction is pathological requires further assessment. The question of suppression of the activity of exclusively brainstem structures is also clearly controversial – diffuse reductions in the functional activity of the cortex can also be suggested.

The present work obtained less marked deviations from normal values for quantitative EEG parameters: impairments to both power and spectral ratios are seen in encephalitis [16], while the study group of children with acute purulent meningitis showed no significant decrease in power. This may be due to the fact that no focal lesions were demonstrated in the brain matter itself in the study children with acute purulent meningitis. Thus, the scale of central nervous system damage in this case was somewhat lower but, nonetheless, brain bioelectrical activity was significantly altered.

**Conclusions.** Patients of pediatric age with acute purulent meningitis showed significant impairments to the normal EEG  $\alpha/\theta$  and  $\alpha/\delta$  spectral power ratios. It can be suggested that the cause of these decreases is suppression and/or rearrangement of the functional activity of the thalamus and the thalamocortical pathways, and also the reticular formation of the brain.

The authors report that they have no conflicts of interests.

*Authors' contributions:* V.B.V. – design of article, literature review, data acquisition, data analysis, writing manuscript, checking intellectual content of article; A.A.V. – literature review, data acquisition, data analysis, writing manuscript, checking intellectual content of article; N.V.S. – checking intellectual content of article, approving manuscript for publication; E.E.V. – data acquisition, data analysis, writing manuscript; N.A.S. – data acquisition, data analysis, writing manuscript; A.V.K. – data acquisition, data analysis, writing manuscript; N.V.M. – data acquisition, data analysis, writing manuscript; M.A.B. – data acquisition, data analysis, writing manuscript.

This work was funded by the state budget.

## REFERENCES

1. V. V. Gnezdzitskii and M. A. Piradov, *the Neurophysiological of Coma and Impaired Consciousness (analysis and interpretation of clinical observations)*, PresSto, Ivanovo (2015).
2. S. T. Herman, N. S. Abend, T. P. Bleck, et al., “Consensus statement on continuous EEG in critically ill adults and children, part I: indications,” *J. Clin. Neurophysiol.*, **32**, No. 2, 87–95 (2015), <https://doi.org/10.1097/WNP.000000000000166>.
3. M. V. Aleksandrov, A. A. Chukhlovina, M. E. Pavlovskaya, et al., “Alpha-theta continuum: neurophysiological mechanisms of generation,” *Med. Alfavit.*, **1**, No. 14, 46–50 (2017).
4. G. Buzsáki, *Rhythms of the Brain*, Oxford University Press (2006), <https://doi.org/10.1093/acprof:oso/9780195301069.001.0001>.
5. L. Chen, Y. Xu, C. Liu, et al., “Clinical features of aseptic meningitis with varicella zoster virus infection diagnosed by next-generation sequencing: case reports,” *BMC Infect. Dis.*, **20**, No. 1, 435 (2020), <https://doi.org/10.1186/s12879-020-05155-8>.
6. A. Chiaretti, G. Eftimiadi, D. Buonsenso, et al., “Intranasal nerve growth factor administration improves neurological outcome after GBS meningitis,” *Childs Nerv. Syst.*, **36**, No. 9, 2083–2088 (2020), <https://doi.org/10.1007/s00381-020-04590-x>.
7. B. Gazibera, E. Suljic-Mehmedika, N. Serdarevic, et al., “Predictive role of electroencephalography in regard to neurological and cognitive sequelae after acute central nervous system infection,” *Acta Inform. Med.*, **27**, No. 4, 234–239 (2019), <https://doi.org/10.5455/aim.2019.27.234-239>.
8. T. Bharucha, L. Nashef, N. Moran, et al., “A 9-month retrospective evaluation of the aetiology and management of patients presenting with encephalitis/meningoencephalitis at a South London hospital,” *Epidemiol. Infect.*, **148**, e23 (2020), <https://doi.org/10.1017/S0950268820000047>.
9. H. Yamamoto, Y. Miyamoto, and H. Yamamoto, “A case of bacterial meningitis with burst waves of local onset on ictal Electroencephalography,” *Pediatr. Int.*, **61**, No. 12, 1263–1264 (2019), <https://doi.org/10.1111/ped.14019>.
10. N. Germano, M. G. Sibbel, D. Summerfield, and A. Pitzemberger, “Group B streptococcus meningitis complicated by periodic lateralising epileptiform discharges in an elderly patient with type 2 diabetes mellitus,” *BMJ Case Rep.*, **12**, No. 8, e228040 (2019), <https://doi.org/10.1136/bcr-2018-228040>.
11. B. F. Westmoreland, “The EEG in cerebral inflammatory processes,” in: *Niedermeyer’s Electroencephalography: Basic Principles, Clinical Applications, and Related Fields*, D. L. Schomer and F. H. L. da Silva (eds.), Oxford University Press (2018), 7th ed.
12. R. S. El-Zein, S. Cardinali, C. Murphy, and T. Keeling, “COVID-19-associated meningoencephalitis treated with intravenous immunoglobulin,” *BMJ Case Rep.*, **13**, No. 9: e237364 (2020), <https://doi.org/10.1136/bcr-2020-237364>.
13. C. Liu, S. Cheng, Y. Ma, et al., “Triphasic waves in electroencephalogram as a possible early marker of carcinomatous meningitis: a case report,” *Medicine (Baltimore)*, **99**, No. 33, e21735 (2020), <https://doi.org/10.1097/MD.00000000000021735>.
14. N. V. Skripchenko, Yu. V. Lobzin, V. B. Voytenkov, et al., “Innovations in the management of neuroinfections in children,” *Detskii Infektsii*, **16**, No. 3, 5–9 (2017).
15. V. B. Voytenkov, N. V. Skripchenko, and V. N. Komantsev, “Varicella encephalitis-related EEG modifications in children,” *Neurophysiology*, **45**, 219 (2013), <https://doi.org/10.1007/s11062-013-9359-4>.
16. V. B. Voytenkov, M. V. Sinkin, N. V. Skripchenko, et al., “Brain bioelectrical activity in children with acute viral encephalitis,” *Ros. Fiziol. Zh.*, **106**, No. 7, 890–897 (2020).