

# Piezocision as an adjunct to orthodontic treatment of unilateral posterior crossbite

Manal A. Bakathir, MSc, MOrth-RCSEd, Ali H. Hassan, BDS, PhD, Maha A. Bahammam, DSc, DABP.

## ABSTRACT

إن تقنية التقشير العظمي (القطع العظمي بتقنية البيزو) هي عملية قليلة الاجتياحية تتكون من قطع أصغرية، قطع بتقنية البيزو وتفتيح انتقائي لطعوم النسخ الرخوة والصلبة. لدى تقنية التقشير العظمي عدة استطببات في تقويم الأسنان، ولكن استخدام هذه التقنية في حالات العضات المعكوسة مازالت محدودة. توضح هذه الحالة السريرية نتائج معالجة مريضة تبلغ من العمر ١٩ عاما لديها عضة خلقية معكوسة احادية الجانب تم معالجتها باستخدام تقنية التقشير العظمي قليل الاجتياح مع طعم عظمي في الجهة المصابة. بالإضافة الى العضة المعكوسة، كانت المريضة تعاني من انحراف وظيفي و ازدحام شديد و انزياح الخط المتوسط السني. تم معالجة الانحراف الوظيفي بتوسيع الفك العلوي باستخدام جهاز رباعي الحلقات، تم إكمال المعالجة باستخدام الجهاز الثابت و قلع ضواحك أولى في كلا الفكين. تم معاينة المريضة بعد مرور ١٨ شهرا من العلاج، كان الاطباق مستقرا والبروفيل الوجهي مقبول كذلك. يمكن استخدام تقنية التقشير العظمي كعلاج مساعد في المعالجة التقويمية لتسريع علاج بعض الحالات التقويمية المعقدة.

Piezocision (corticotomy) is a minimally invasive approach that involves micro-incisions, piezoelectric incisions, and selective tunnelling for soft or hard tissue grafting. Piezocision has many uses in orthodontics, but its uses in cross-bite cases are limited. This case report illustrates the outcomes of a 19-year-old female patient with unilateral cross-bite that was treated with a minimally invasive piezocision with bone grafting in the affected side. In addition, she also had a functional shift, severe crowding, and mid-line shift. Therefore, the shift was eliminated using a quad helix expansion, she was treated with a fixed appliance, and a bimaxillary extraction of the first premolars was performed. The patient followed-up at 18 months, and the occlusion was stable with a pleasant profile. Piezocision can be used as an adjunct to the orthodontic treatment of adults to facilitate the treatment of complicated cases.

*Saudi Med J 2017; Vol. 38 (4): 425-430  
doi:10.15537/smj.2017.4.16390*

From the Department of Orthodontics (Bakathir), Ministry of Health, Dammam, King Abdulaziz University (Hassan), Department of Periodontology (Bahammam), Faculty of Dentistry, Jeddah, Kingdom of Saudi Arabia.

Received 8th September 2016. Accepted 16th November 2016.

Address correspondence and reprint request to: Prof. Ali H. Hassan, Department of Orthodontics, Faculty of Dentistry, King Abdulaziz University, Jeddah, Kingdom of Saudi Arabia. E-mail: aakbr@kau.edu.sa  
ORCID: <http://orcid.org/0000-0002-6132-862X>

Treating a unilateral posterior cross bite in adults is challenging. Proffit has classified the condition into either a functional or true unilateral crossbite. Since occlusal interference causes the mandible to shift to the other side, the functional unilateral crossbite can be treated with the symmetrical expansion of the upper arch.<sup>1</sup> However, a true unilateral crossbite requires an asymmetric expansion that is difficult to achieve without overcorrection of the affected side; therefore, complications and a lengthy treatment are expected.<sup>1</sup> Hassan et al<sup>2</sup> has published 2 unilateral crossbite cases, which were successfully treated by corticotomy-assisted expansion. Accelerated osteogenic orthodontics or periodontally accelerated osteogenic orthodontics was introduced by Wilco et al.<sup>3</sup> This technique requires patients with fixed appliances to undergo surgeries, including full thickness muco-periosteal buccal, or lingual flaps with bone bur decortication and bone grafting. Despite of the aggressiveness of the procedure and the possibility of damaging the roots with bone burs, the technique is reported to reduce the treatment time by 30-50%, when compared with conventional orthodontics.<sup>3</sup> Park<sup>4</sup> eliminated the need for flap elevation and significantly reduced the invasiveness

**Disclosure.** Authors have no conflict of interest, and the work was not supported or funded by any drug company.

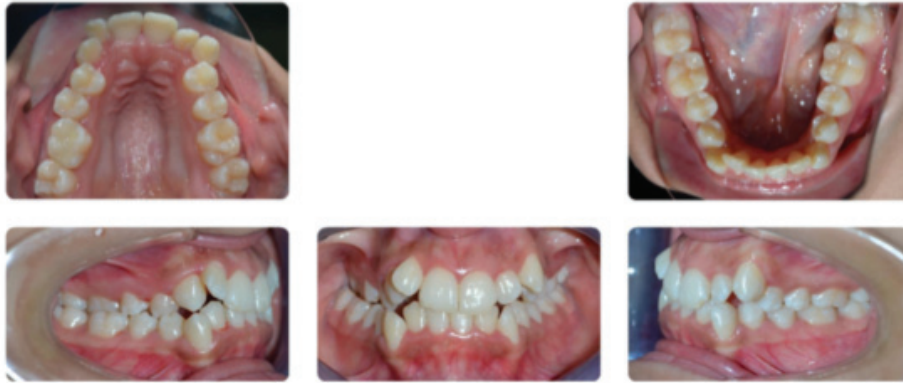of the surgery by performing their incisions directly through the gingiva using a blade and a surgical hammer. However, due to the aggressive use of a hammer and chisel when performing the procedure in the maxilla, placing a bone graft was impossible and there was a risk of developing benign paroxysmal positional vertigo.<sup>5</sup> In another approach of decortication that avoided the use of the hammer and chisel, as well as the accompanied discomfort, was introduced by Vercellotti.<sup>6</sup> He used a piezo-surgical micro-saw and reported a reduction of orthodontic treatment time by 60-70%. In his technique, he replaced the lingual flaps by only vestibular incisions, but the elevation of a flap prior to the piezocision was maintained; therefore, postoperative discomfort was only relatively reduced.<sup>6</sup> Dibart et al<sup>7</sup> overcame the disadvantages of the other techniques with his flapless procedure that combined piezo-surgical cortical micro-incisions with selective tunnelling for bone or soft-tissue grafting. Since the technique was recently introduced, there is a lack of case reports showing its effectiveness, especially in patients with crossbites. In this case report, the piezocision technique was used to treat a 19-year-old female patient with a true unilateral cross bite and crowding in the maxillary arch. The objective of this treatment were as follows: a) correct the unilateral cross bite through unilateral piezocision-assisted expansion; b) relieve crowding, eliminate rotations, and correct upper and lower midline deviations through the extraction of the 4 first premolars; c) correct the deep bite; d) achieve a functional occlusion with maximum intercuspation, minimal overbite, and minimal overjet; and e) retain the achieved results.

**Case Report.** A 19-year-old female patient presented to the orthodontic clinic with a chief complaint of crooked teeth and unpleasant smile. Her medical and dental histories were insignificant. She showed mucogingival problems in association with the lower right and both upper canines due to their position, but she otherwise had good gingival health. she was well motivated and demonstrated a good standard of oral hygiene. Extra-oral examination revealed a Class I pattern with a slightly convex profile and average nasolabial angle. Her facial symmetry was acceptable and balanced, with an increased lower vertical proportion. Examination of the soft tissue demonstrated competent lips with a slightly protrusive lower lip relative to Ricketts' E-plane. She had no gingival display on smiling. The upper midline was deviated by 1 mm to the right of the facial midline, and the lower midline was deviated by 2 mm to the right of the upper

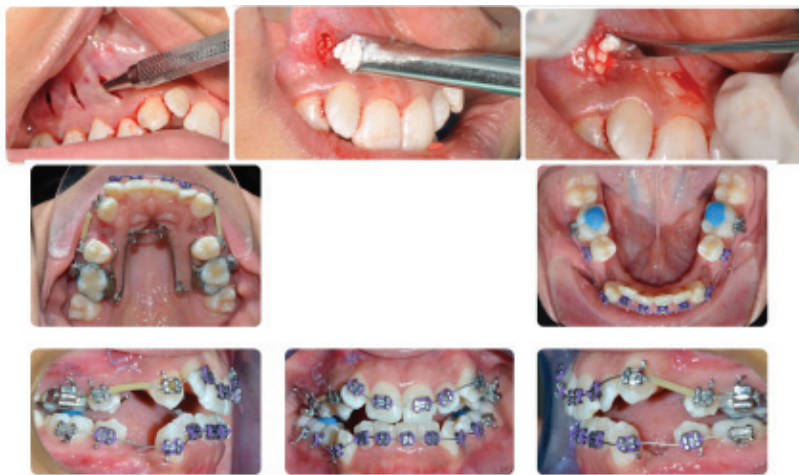midline. Dentally, she had Class I buccal segments, a 50% deep bite (incomplete due to the flared upper lateral incisors), an average overjet, a deep curve of Spee, and an exaggerated compensating curve. There was 6 mm of crowding in the lower anterior segment, 14 mm of total upper arch crowding, and decreased inter-molar widths of both the upper and lower arches. She also had unilateral crossbite on the right side (Figure 1). Radiographically, she had a Class I skeletal relationship with an increased mandibular plane angle. The lower incisors were significantly retroclined relative to the mandibular plane. The lower lip was slightly protrusive relative to Ricketts' E-plane. All the third molars were still erupting (Table 1). Our treatment

Piezocision with bone grafting in the buccal side of the right upper arch 'from the distal of the second molar (UR 7) to the mesial of the canine (UR 3)' was performed following the protocol presented by Dibart et al,<sup>7,8</sup> with the extraction of all first premolars. One week later, cementation of an expanded quad helix and bonding the upper and lower teeth (7-7) with pre-adjusted edgewise-fixed appliances (Victory Series™ Roth prescription, 3M Unitek, St. Paul, Minnesota, USA; 0.018" × 0.025" slot) was carried out. Upper and lower 0.014 NiTi aligning arch wires were placed. All second molars were bonded one visit later (Figure 2). Crossbite correction was achieved within 3 months and maintained using a trans-palatal arch. After levelling and aligning, space-closure was achieved by retraction of the canines using a power chain, followed by T-loop retraction of the incisors. However, bodily retraction of the lower canines was difficult and distal tipping occurred. Therefore, piezocision was attempted once again to the buccal and distal of the lower canines, which helped with uprighting of the canines smoothly (Figure 3). Arches were coordinated, finished, and detailed by wire bending and inter-maxillary elastics. For retention, upper and lower fixed retainers from canine to canine were bonded, and an upper wrap-around with an anterior bite plane and lower Hawley retainer were delivered.

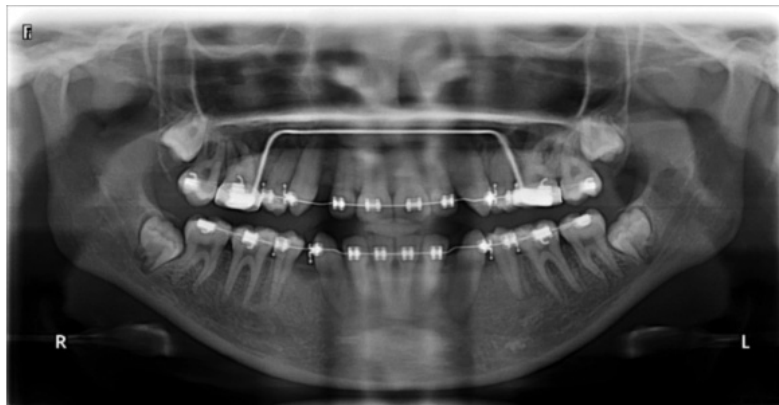Although she had a low level of cooperation and missed more than 10 appointments, treatment with an orthodontic fixed appliance for 27 months was still successful. The original treatment goals were accomplished, and the patient's presenting complaint was addressed. A good occlusal and aesthetic result was achieved, and she was notably pleased with the treatment outcome. No obvious skeletal changes could be observed in the antero-posterior skeletal pattern during treatment. Vertical relations did not deteriorate notably.



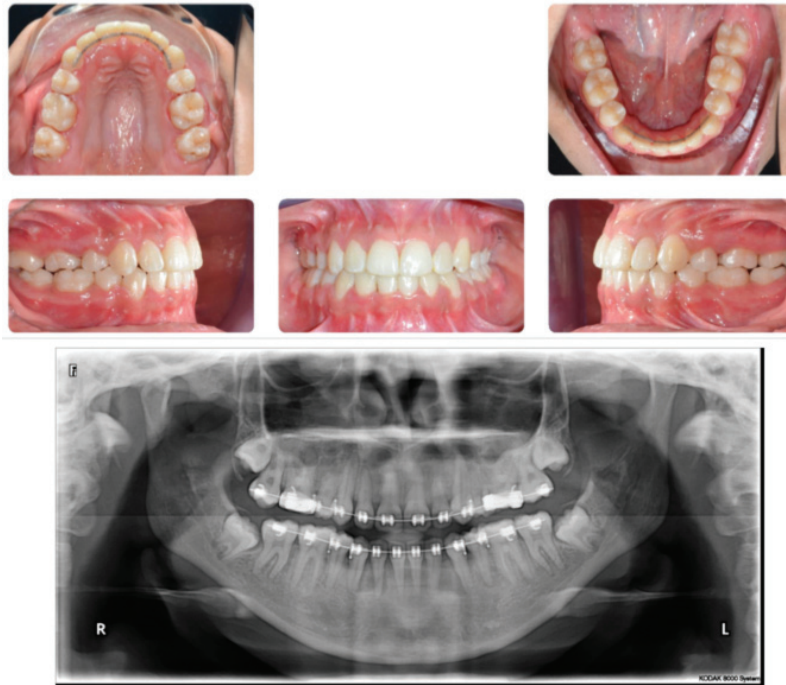
**Figure 1** - Initial intra-oral photographs of the patient (note the unilateral asymmetry of the upper arch)



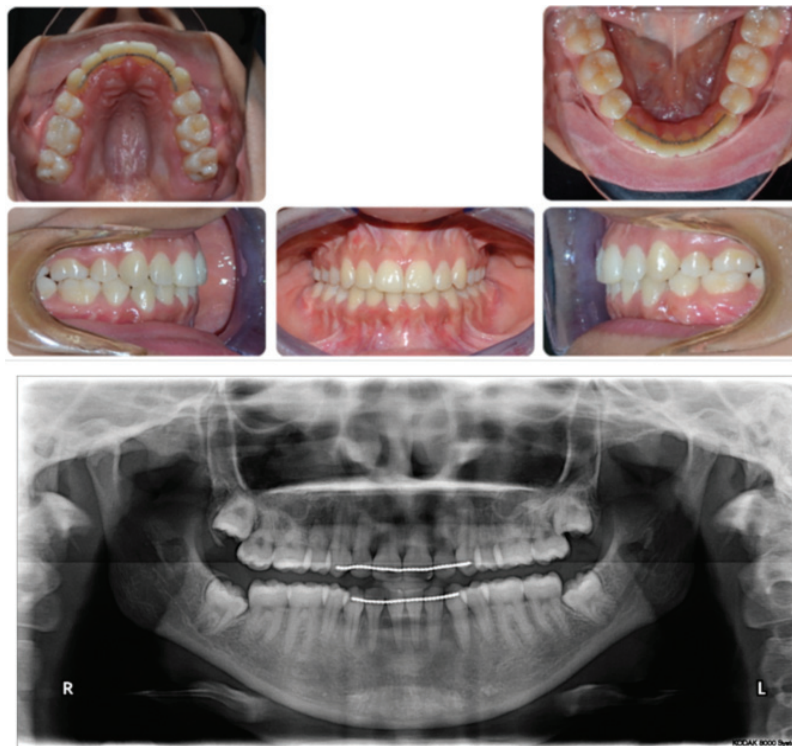**Figure 2** - Minimally invasive corticotomy (piezo-surgery) with bone graft on the buccal side of the right upper arch (from the distal of UR 7 to the mesial of UR3). One week later, cementation of the expanded quad helix and bonding the upper and lower teeth (6-6) with pre-adjusted edgewise-fixed appliances (0.018" × 0.025" slot Roth prescription) was performed. Upper and lower 0.014 NiTi aligning arch wires were placed.



**Figure 3** - Tipping of the lower canines was noticed and an orthopantomogram was obtained. The lower canines' apices were displaced mesially while the crowns tipped distally. A consultation was made with the periodontist to perform piezocision around the apices of the lower canines.



**Figure 4** - Final photographs and orthopantomogram.



**Figure 5** - Photographs and orthopantomogram from the 18-month follow-up.

**Table 1** - Initial and final cephalometric readings.

Variable	Norms	Pre-treatment	Near end of treatment	Change
SNA	82° ± 3	76.3°	76.4°	+0.1°
SNB	79° ± 3	76.1°	76.2°	+0.1°
ANB	3° ± 1	0.2°	0.2°	+0.0°
SN to maxillary plane	8° ± 3	7.7°	8.2°	+0.5°
MP - SN	33° ± 6	44.9°	45.6°	0.7°
Wits appraisal	-1 mm	-0.9 mm	-4.1 mm	-3.2 mm
Upper incisor to maxillary plane angle	108° ± 5	112.5°	109.7°	-2.8°
Lower incisor to mandibular plane angle	92° ± 5	78.1°	77.6°	-0.5°
Interincisal angle	133° ± 10	132.1°	135.4°	+3.3°
Maxillary mandibular planes angle	27° ± 5	37.3°	37.4°	+0.1°
Upper anterior face height		49.1mm	49.1mm	0.0 mm
Lower anterior face height		60.1mm	60.1mm	0.0 mm
Face height ratio	55%	55.1%	55.1%	0 %
Lower incisor to A-Pog line	0-2 mm	3.7mm	2.7 mm	-1.0 mm
Lower lip to Ricketts E Plane	-2 mm	-1.0 mm	-1.5 mm	-0.5 mm
Nasiolabial angle	102° ± 8°	116.6°	110.8°	-5.8°

SNA - Sella-nasion to A point angle, SNB - Sella-nasion to B point angle, ANB - A point to B point angle, MP - SN, SN to mandibular plane angle

Minimal overjet and overbite, were achieved. Posteriorly, the buccal segments were Class I, and the posterior cross-bite was eliminated. Upper and lower midlines coincided with each other and with the face. The lower lip protrusion was treated successfully. The gingival condition, roots, and alveolar bone were all normal and healthy (Figure 4, Table 1). The patient was followed-up for 18 months post-treatment, and the occlusion was stable without any relapse (Figure 5)

**Discussion.** A high IOTN score of both the dental health and the aesthetic component registered for the patient suggested a “great” need for treatment. The patient originally demonstrated a high level of perceived need, notably with complaints that the upper front teeth were crooked, which affected her smile and social life. Oral hygiene was excellent, and the patient appeared highly motivated for treatment at the beginning. The patient was 19 years old with a true unilateral crossbite and crowding that was treated successfully by piezocision on the side with the eccentric load. Conventional expansion in a case such as this is expected to produce a bilateral effect<sup>2-4</sup> resulting in overexpansion of the unaffected side. In addition, piezocision was used successfully to retract a distally tipped lower right canine.

Piezocision is a new minimally invasive corticotomy technique.<sup>5,7,8</sup> When compared with conventional corticotomy, it is believed to produce less patient discomfort and trauma with the same clinical outcome.<sup>5,7</sup> Moreover, it has less periodontal complications than those associated with conventional corticotomy, such as

mild bone loss and the partial loss of interdental papilla. However, this technique has some complications, such as root and mental foramen damage, gingival clefts, and gingival scars in patients with ethnic gingival pigmentations. These complications can be avoided by acquiring full mouth periapical radiographs or 3-dimensional imaging in order to stay 5-6 mm away from the gingival margin, as well as proper discussion with the patient.<sup>5,7,8</sup>

Since the acceleration of orthodontic tooth movement was not the aim of the surgery, it was only performed on the right upper side with a bone graft buccally to avoid root fenestration or dehiscence, and quad helix was used for expansion. Bilateral expansion was observed; however, there was more expansion on the right side in a shorter period of time. Once the desired expansion was achieved in 12 weeks, trans-oral arch (TPA) was used in the upper arch for 2 reasons: a) maximizing the anchorage since more space was required in the upper arch than in the lower arch and b) to maintain the expansion. The inter-molar and inter-canine widths were increased by 3 mm. Patient selection is very critical. Since the orthodontist has to activate the appliance every 2 weeks due to the transient effect of the regional acceleratory phenomenon, excellent cooperation and oral hygiene are needed.<sup>9</sup>

In our case, extraction of the first premolars in the maxillary and mandibular arches was deemed necessary due to severe crowding of the labial segments. The profile of the patient was pleasant and minimal changes were desired. The extraction was needed in order to align the teeth in their arches, and no retraction was planned

for the labial segments. Increasing the anchorage in the lower arch with an under tie ligation of the buccal segments to the second molars was needed only until the teeth were aligned, at that time, the anchorage was burned. Stability was successfully maintained for 18 months, which could also be partially attributed to the piezocision procedure. Although our patient was successfully treated, the amount of evidence proving the effectiveness of piezocision-assisted orthodontics for the correction of posterior crossbite, especially the unilateral ones, remains inadequate.<sup>10</sup> The report on the outcome of our case supports using piezocision for the treatment of unilateral cross-bites and bilateral cross-bites of unequal severity.

In conclusion, piezocision can be used as an adjunct for the orthodontic treatment of adults who require challenging tooth movement that would be difficult to achieve by conventional orthodontics, and to overcome the side effects of conventional orthodontics.

## References

1. Proffit WR, Fields Jr HW, Sarver DM. Contemporary orthodontics. 5th ed. St. Louis (US): Elsevier Health Sciences; 2014.
2. Hassan AH, AlGhamdi AT, Al-Fraidi AA, Al-Hubail A, Hajrassy MK. Unilateral cross bite treated by corticotomy-assisted expansion: two case reports. *Head Face Med* 2010; 6: 6.
3. Wilcko WM, Ferguson DJ, Bouquot JE, Wilcko MT. Rapid orthodontic decrowding with alveolar augmentation: case report. *World J Orthod* 2003 1; 4: 3.
4. Park YG, Kang SG, Kim SJ. Accelerated tooth movement by corticision as an osseous orthodontic paradigm. *Kinki Tokai Kyosei Shika Gakkai Gakujuyutsu Taikai, Sokai*. 2006; 48: 34.
5. Sebaoun JD, Surmenian J, Dibart S. Traitements orthodontiques accélérés par piézocision: une alternative mini-invasive aux corticotomies alvéolaires. *L'Orthodontie Française* 2011; 82: 311-319. French
6. Vercellotti T, Podesta A. Orthodontic microsurgery: a new surgically guided technique for dental movement. *Int J Periodontics Restorative Dent* 2007; 27: 325-331.
7. Dibart S, Sebaoun JD, Surmenian J. Piezocision: a minimally invasive, periodontally accelerated orthodontic tooth movement procedure. *Compend Contin Educ Dent* 2009; 30: 342-344, 346, 348-3450.
8. Dibart S, Keser EI. Piezocision™. Minimally invasive periodontally accelerated orthodontic tooth movement procedure. In: Federico Brugnami, Alfonso Caiazzo, editors. *Orthodontically Driven Corticotomy: Tissue Engineering to Enhance Orthodontic and Multidisciplinary Treatment*. NJ (USA): Wiley-Blackwell; 2014 P.119.
9. Frost HM. From Wolff's law to the Utah paradigm: insights about bone physiology and its clinical applications. *Anat Rec (Hoboken)* 2001; 262: 398-419.
10. Hassan AH, Al-Saeed SH, Al-Maghlouth BA, Bahammam MA, Linjawi AI, El-Bialy TH. Corticotomy-assisted orthodontic treatment: A systematic review of the biological basis and clinical effectiveness. *Saudi Med J* 2015; 36: 794.

## Illustrations, Figures, Photographs

All figures or photographs should be submitted in a high resolution (minimum 300 DPI) electronic version saved in jpeg or tiff format. Original hard copies of all figures may be requested when necessary. Photographs will be accepted at the discretion of the Editorial Board. All lettering, arrows, or other artwork must be done by an artist or draftsman. If arrows are used please ensure they appear in a different color to the background color, preferably black with a white border, or white with a black border. If arrows distinguish different items on the figure then different arrow styles should be used ie. long, short, wide, narrow. Written informed consent for publication must accompany any photograph in which the subject can be identified. Written copyright permission, from the publishers, must accompany any illustration that has been previously published.