

Performance of semi-quantitative lung ultrasound in the assessment of disease severity in interstitial lung disease

Ishan Kumar, Zeeshan Siddiqui, Ashish Verma, Aarushi Chokhani¹, Govind Narayan Srivastava¹, Ram C. Shukla

Departments of
Radiodiagnosis and ¹TB
and Respiratory Medicine,
Institute of Medical
Sciences, Banaras Hindu
University, Varanasi,
Uttar Pradesh, India

**Address for
correspondence:**

Dr. Ashish Verma,
Department of
Radiodiagnosis, Institute
of Medical Sciences,
Banaras Hindu University,
Varanasi - 221 005,
Uttar Pradesh, India.
E-mail: drdnv5@gmail.
com

Submission: 13-04-2020
Accepted: 27-08-2020
Published: 14-01-2021

Abstract:

BACKGROUND: Accurate staging of disease severity and its serial monitoring thus is central to the effective management protocols of interstitial lung disease (ILD).

PURPOSE: The aim is to evaluate the effectiveness of semi-quantitative parameters of lung ultrasound (LUS) in patients of ILD as a means of staging disease severity.

MATERIALS AND METHODS: LUS of 47 patients of ILD and 20 age-matched controls was performed, and findings such as B-line distance, pleural thickening, subpleural changes, decreased lung sliding, and fragmented pleural lining were charted, and an LUS score was done using these parameters. Findings were compared with the Modified Medical Research Council (MMRC) dyspnea grade and spirometry parameters.

RESULTS: The presence of B-lines and fragmented pleural lining were the most common findings observed in patients of ILD. Predicted forced vital capacity (FVC) and predicted forced expiratory volume in 1 s (FEV1) showed a good correlation with all the LUS parameters. B-line distance was the most significant LUS parameter to predict the variability in predicted FEV1, FVC, and MMRC dyspnea score. LUS severity score also showed good negative correlation with predicted FEV1 ($r = -0.674$, $P < 0.001$) and predicted FVC ($r = -0.65$, $P < 0.001$). LUS severity score of 4 or more predicted MMRC dyspnea score of > 3 with 82% sensitivity and 70% specificity.

CONCLUSION: Semi-quantitative LUS score and B-line distance can provide a simple but effective estimate of disease severity in ILD.

Keywords:

Interstitial lung disease, thorax, ultrasound

Interstitial lung disease (ILD) is an umbrella term comprising of a heterogeneous group of more than 200 diffuse lung parenchymal disorders primarily affecting the interstitium of the lung with variable involvement of alveoli, airways, lung vessels, and pleura.^[1] The lung in these patients is characterized by variable degrees of fibrosis and inflammation with fibrosis-predominance carrying a poorer prognosis.^[2] Early recognition of

ILD is essential for the timely initiation of therapy. Unfortunately, presenting clinical symptoms is insidious and non-specific, which often delays the diagnosis. Surgical biopsy was previously considered as a "gold standard" technique for the diagnosis of ILD; however, currently, most of the guidelines recommend a multidisciplinary approach consisting of clinical examination, lung spirometry, high-resolution computerized tomography (HRCT), transbronchial biopsy and bronchoalveolar lavage.^[3] Lung transplantation is the only therapeutic

This is an open access journal, and articles are distributed under the terms of the Creative Commons Attribution-NonCommercial-ShareAlike 4.0 License, which allows others to remix, tweak, and build upon the work non-commercially, as long as appropriate credit is given and the new creations are licensed under the identical terms.

For reprints contact: WKHLRPMedknow_reprints@wolterskluwer.com

How to cite this article: Kumar I, Siddiqui Z, Verma A, Chokhani A, Srivastava GN, Shukla RC. Performance of semi-quantitative lung ultrasound in the assessment of disease severity in interstitial lung disease. *Ann Thorac Med* 2021;16:110-7.

Access this article online
Quick Response Code:

Website: www.thoracicmedicine.org
DOI: 10.4103/atm.ATM_145_20

option shown to prolong survival in advanced ILD; however, 5-year survival is 40%, and the facility of lung transplant is available in only limited centers.^[4] Current therapeutic regimens in most of the centers rely on combined usage of corticosteroid, immunosuppressive drugs, and N-acetyl cysteine.^[5] Accurate staging of disease severity and its serial monitoring thus is central to the effective management protocols of ILD.

HRCT is the imaging modality of choice to diagnose and classify various types of ILD. However, heavy radiation burden prevent its usage in follow-up, surveillance of disease severity, and post-therapeutic changes. Transbronchial and surgical biopsy cannot be used for monitoring because of its invasiveness and frequent sampling errors. Pulmonary function tests and 6-min walk distance are currently being used as a means to longitudinally follow-up these patients; however, they are difficult to perform in severe disease and are subject to intra-individual variability.^[6] In this context, the transthoracic ultrasonographic (US) examination might provide a radiological marker of disease severity owing to its inexpensive, radiation-free, and objective assessment capability and widespread availability.

The present study is aimed to evaluate the effectiveness of semi-quantitative parameters of lung ultrasound (LUS) in patients of ILD as a means of staging disease severity.

Materials and Methods

Subjects

This was a prospective observational study carried out in a University-based tertiary care hospital from October 2017 to June 2019. The Institutional ethical committee approved the study and written informed consent was obtained from all the patients in this study. The patient group was selected and recruited from among those who were referred from the Department of TB and respiratory diseases. Patients with typical findings of ILD on HRCT were included in this study. Computed tomography (CT) scan was performed on 64-slice scanner (Lightspeed, GE Medical systems, Milwaukee, Wisconsin) in a craniocaudal direction with breath-hold from the lung apices to lateral costophrenic sulci, with 1 mm slice thickness, 120 kVp, and 80–100 mAs. Patients were excluded if they were diagnosed with infection, malignancy, or alternate diagnosis on HRCT. Patients with ILD having features suggestive of heart failure or those unable to perform spirometry were excluded from this study. 20 age- and gender-matched controls, with no past or present history of tuberculosis or any other acute, chronic respiratory diseases, were included and evaluated using transthoracic ultrasonography. CT scan of the controls was not performed.

Ultrasound scan

All ultrasonography scans were performed using high-end sonographic equipment (IU22, Philips Medical System, The Netherlands) [Figure 1]. The scans were performed using a linear electronic array transducer of frequency range 5–17 Hz as well as a convex probe with a frequency range of 2–5 Hz. Scans were done in supine and sitting positions. In the supine position, a total of 8 regions were examined: two anterior (upper and lower) and two lateral (upper and basal) per hemithorax). The anterior chest wall is defined as the region from the sternum to the anterior axillary line, whereas the lateral zone is defined as the region from the anterior to the posterior axillary line. In the sitting position, the patient was examined with his/her back facing the examiner. The examination was performed to explore the posterior axillary line and posterior thorax along the paravertebral line and below the angle of the scapula. All the US scans were performed within 2 days of performing the HRCT scan.

Ultrasound interpretation

B-lines were defined as vertical, laser-like, hyperechoic artifacts arising from the pleural line and extending to the bottom of the screen, which moves synchronously with lung sliding. B-line artifacts look different at different levels, depending on the frequency and transducer shape used. Thus, in our study, the depth of penetration was standardized to 4–10 cm starting from the pleural line (depending on the frequency used), and the focus of the image was set at the level of the pleural line, thus focusing most of the energy for reflection and reverberation. The distance between two consecutive B-lines [Figures 1 and 2] was measured and documented. It is seen that the distance between two consecutive B-lines increases with increasing depth, as one moves away from the pleural surface. Hence, for the sake of uniformity, the distance between B-lines was taken at the lung-pleura interface, and measurements were done on images obtained by scan using a convex probe. The presence or absence of a fragmented pleural line was noted [Figure 3]. Pleural thickening was defined as focal or diffuse echogenic lesions arising from the visceral or parietal pleura that are >3 mm in width with or without an irregular pleural surface. The presence or absence of subpleural hypoechoic [Figure 3] areas in the immediate subpleural region was recorded. Normal versus decreased lung sliding was also documented. The presence or absence of any pleural effusion was also noted.

Based on our observations, an attempt was made to develop an LUS Severity Score to score the degree of severity. B-line distance showed a highly significant negative correlation with PFT. Hence, a B-line distance between 2.5 and 5 mm was given one point and 5.1–7.5 mm

was assigned two points. One point each was given for the presence of rest of the LUS parameters, i.e., pleural irregularity, pleural thickening, subpleural changes, and decreased lung sliding. Thus, the maximum score which can be obtained would be 2 + 1 + 1 + 1 + 1 = 6 [Figure 4].

Clinical data

Pulmonary function test was performed according to the American Thoracic Society guidelines^[7] to evaluate forced expiratory volume in 1 s (FEV1), and the percentage predicted FEV1 (hereafter referred to as FEV1%). The dyspnea of each patient was categorized with the help of the modified medical research council (MMRC) dyspnea scale, which is a five-point scale ranging from grade 0 (dyspnea on strenuous exercise) to grade 4 (too dyspneic to leave the house). ABG PO₂, PCO₂, and SpO₂ were also charted for each patient.

Statistical analysis

Data analysis was performed using SPSS software (IBM Corp 2013. Version 22.0. Armonk, NY, USA). Scatter plots were drawn between PFT parameters and LUS parameters. Correlations between spirometric parameters and LUS parameters were determined and quantified using Pearson's correlation coefficients. $P < 0.05$ was considered a statistically significant correlation. Receiveroperated characteristic (ROC) curves were plotted for each quantitative LUS parameters in the prediction of MMRC of 3 or more. Linear regression analysis was performed to examine the relationship

between the clinical outcomes such as FEV1, forced vital capacity (FVC), MMRC dyspnea score as response variables, and the quantitative LUS parameters such as B-line distance, pleural thickness as explanatory variables.

Results

A total of 51 patients, which were referred from the department of TB and respiratory diseases, were recruited for the study. However, four patients had to be excluded: two due to their inability to perform spirometry, one due to concomitant tuberculosis and another one due to the presence of features suggestive of congestive heart failure. Hence, a total of 47 (M: F: 25:22) patients were finally included in the study with a mean age of 52.2 + 14.4 years (20–81 years). Mean age 20 controls (M: F = 12:8) was 50.5 + 15.5 years (24–78 years). Among ILD patients, 32% were smokers and 38% of patients had significant occupational exposure at work. ILD was diagnosed based on clinical features, typical HRCT features, and laboratory parameters. Lung biopsy had to be performed for

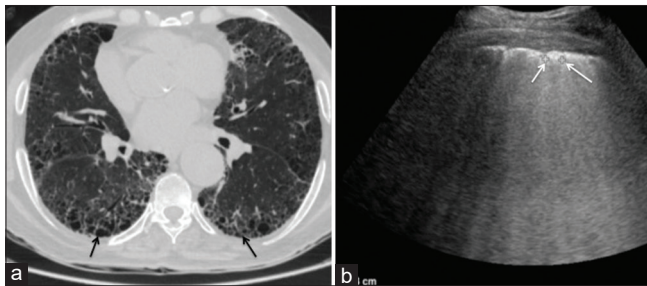


Figure 1: (a) Axial computed tomography image of a patient with idiopathic pulmonary fibrosis showing areas of honeycombing (black arrows) and reticulations (b) Corresponding ultrasonographic image performed using convex probe shows multiple B-lines. The distance between B-lines is wider, i.e., 7.1 mm (white arrows)

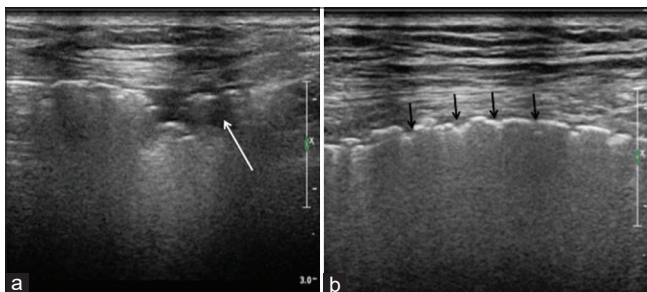


Figure 3: (a) Lung ultrasound performed using linear transducer shows hypoechoic subpleural changes (white arrow) and (b) fragmented pleural line (black arrows)

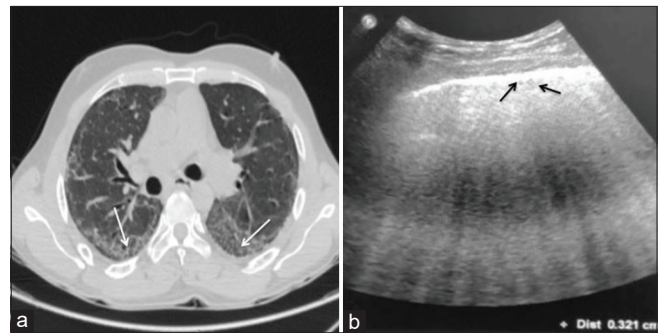


Figure 2: (a) Axial computerized tomography image of a patient with nonspecific interstitial pneumonia shows areas of bilateral ground-glass opacities (white arrows) (b) Corresponding ultrasonographic image performed using convex probe shows multiple closely spaced B-lines. The distance between B-lines is lesser ~3.2 mm (black arrows)

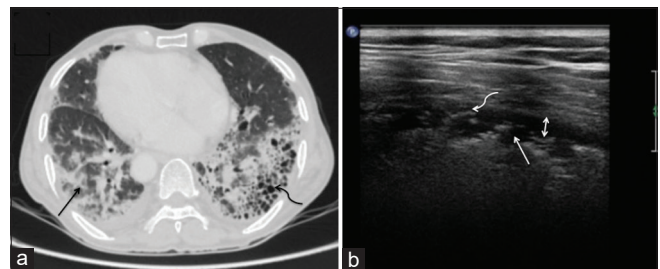


Figure 4: (a) Axial computerized tomography image of a patient with IPF showing extensive reticulations (black straight arrow), fibrosis and honeycombing (black curved arrow). Pleural thickening is also present. Associated dextrocardia is noted. (b) Grey scale sonography image of the same patient showing pleural thickening (double headed arrow) with subpleural changes (white straight arrow) and fragmented pleural line (curved white arrow). The patient also had bilateral diffuse B-lines with 6.3 mm B-line distance (not shown). Real-time sonography scan of this patient showed reduced lung sliding. The patient was given a lung ultrasound severity score of 6/6

six cases of PAP ($n = 1$), fibrotic sarcoidosis ($n = 2$), lymphoid interstitial pneumonia (LIP) ($n = 1$), and hypersensitivity pneumonitis ($n = 2$). Both the cases of sarcoidosis were of stage 4 disease with extensive fibrosis, interstitial thickening, and honeycombing. Our study group included cases of IPF/UIP ($n = 14$), connective tissue-related ILD ($n = 12$), chronic hypersensitivity pneumonitis ($n = 8$), occupational ILD ($n = 4$), iNSIP ($n = 3$), fibrotic sarcoidosis ($n = 2$), and one cases each of RB-ILD, LIP, PAP and chronic eosinophilic pneumonia. The most common clinical feature in patients with ILD was breathlessness (93%) followed by dry cough (49%), wheeze (40%), productive cough (36%), crept (44%), and clubbing (29%).

On LUS, the most common findings observed in patients of ILD were B-lines (43/47), pleural irregularity (34/47), subpleural changes (19/47), pleural thickening (17/47), decreased lung sliding (12/47), and pleural effusion (4/47). In the control group, 2 patients, both aged >70 years, showed pleural irregularity and all of the controls showed A-lines. Mean pleural thickening in cases of ILD was 2.20 ± 1.18 (range 0.8–4.4 mm) and that in control group 1.00 ± 0.32 (range 0.6–1.4 mm). The mean B-line distance in patients with ILD was 4.3 ± 2.02 (minimum 2.6 mm in LIP and maximum 6.03 mm in IPF). Table 1 summarizes the frequency of LUS parameters among various ILD groups.

Table 2 shows the correlation of LUS parameters with various PFT parameters and MMRC dyspnea grade. Predicted FVC and predicted FEV1 showed a good correlation with all the LUS parameters. SpO2 and ABG PO2 correlated significantly with the distance between B-lines. ABG PCO2 correlated significantly with pleural thickness. Figure 5 shows scatter plots to depict the correlation between B-line distance and pulmonary function tests. ROC curve drawn for B-line distance

and pleural thickness to predict MMRC of 3 or more yielded AUC of 0.791 and 0.697, respectively [Figure 6]. A B-line distance of 4.7 mm had a sensitivity of 82.4%, and specificity of 77% to predict MMRC of 3 or more were as the pleural thickness of 1.75 mm predicted the same with a sensitivity of 76.5% and specificity of 60%.

Linear regression analysis to assess the relationship between LUS parameter and predicted FEV1, FVC, and MMRC showed that changes in B-line distance values can account for 23% change in MMRC dyspnea score ($P = 0.002$), 33.5% variability in predicted FEV1 value ($P < 0.001$) and 36% variability in predicted FVC values ($P < 0.001$). The addition of pleural thickness to the multiple regression model did not account for a greater proportion of variation in predicted FVC, FEV1, and MMRC scores.

LUS severity score of 4 or more predicted MMRC dyspnea score of > 3 with 82% sensitivity and 70% specificity. Moreover LUS severity score showed good negative correlation predicted FEV1 ($r = -0.674$, $P < 0.001$) and predicted FVC ($r = -0.65$, $P < 0.001$) and a good positive correlation with MMRC score ($r = 0.484$, $P < 0.001$) [Figure 7]. Cronbach's alpha, for the LUS severity score, was 0.702.

Chi-square test was performed to evaluate the relationship between HRCT parameters and LUS parameters. Honeycombing on HRCT was significantly associated with subpleural changes ($P < 0.001$), pleural irregularity ($P < 0.001$), decreased lung sliding ($P = 0.001$), whereas its no significant association was present with the presence of B-lines ($P = 0.085$), pleural thickening ($P = 0.052$). Reticular interstitial thickening was significantly associated with subpleural changes ($P = 0.034$), pleural irregularity ($P < 0.001$), whereas its association with presence of B-lines ($P = 0.085$), pleural thickening ($P = 0.052$), and decreased lung

Table 1: Frequency of lung ultrasound parameters among various interstitial lung disease groups

ILD diagnosis (n)	B lines	Pleural irregularity	Pleural thickening	Subpleural changes	Decreased lung sliding	Pleural effusion	B line distance in mm
IPF UIP (14)	14 (100)	14 (100)	7 (50)	10 (71.4)	7 (50)	0 (0)	6.03±0.22
CTD ILD (12)	12 (100)	10 (83.3)	4 (33.3)	4 (33.3)	2 (1.7)	3 (25)	4.3±1.4
Hypersensitivity pneumonitis (8)	6 (75)	4 (50)	2 (25)	3 (37.5)	3 (37.5)	1 (12.5)	3.78±2.6
Occupational ILDs (4)	3 (75)	2 (50)	3 (75)	2 (50)	0 (0)	0 (0)	3.35±2.9
Sarcoidosis (2)	2 (100)	2 (100)	1 (50)	0 (0)	0 (0)	0 (0)	3.7±0.84
Eosinophilic pneumonia (1)	1 (100)	0 (0)	0 (0)	0 (0)	0 (0)	0 (0)	3.1
Pulmonary 1 (1)	1 (100)	0 (0)	0 (0)	0 (0)	0 (0)	0 (0)	2.7
LIP (1)	1 (100)	0 (0)	0 (0)	0 (0)	0 (0)	0 (0)	2.6
RBILD DIP (1)	0 (0)	0 (0)	0 (0)	0 (0)	0 (0)	0 (0)	0
i NSIP (3)	3 (100)	2 (66)	0 (0)	0 (0)	0 (0)	0 (0)	3.03±0.15

Values mentioned are number of patients and %. NSIP=Nonspecific interstitial pneumonia, ILD=Interstitial lung disease, RBILD=Respiratory bronchiolitis associated with interstitial lung disease, DIP=Desquamative interstitial pneumonia, LIP=Lymphoid interstitial pneumonia, IPF=Idiopathic pulmonary fibrosis, UIP=Usual interstitial pneumonia, CTD=Connective tissue diseases

Table 2: Correlation of lung ultrasound parameters with pulmonary function test parameters, clinical severity Modified Medical Research Council score

Parameters	Distance between B lines mm	Pleural irregularity	Pleural thickness	Subpleural changes	Lung sliding
FEV1 predicted.					
<i>r</i>	-0	-0.45	-0.315	-0.574	0.513
<i>P</i>	<0.001	0.001	0.031	0.001	0.001
FVC predicted.					
<i>r</i>	-0.37	-0.502	-0.2	-0.531	0.522
<i>P</i>	0.000	0.001	0.07	0.001	0.001
FEV1/FVC					
<i>r</i>	0.014	0.172	-0.15	-0.085	-0.243
<i>P</i>	0.27	0.247	0.287	0.570	0.0
ABG PO ₂					
<i>r</i>	-0.385	-0.121	-0.03	-0.187	0.277
<i>P</i>	0.008	0.418	0.74	0.208	0.05
ABG PCO ₂					
<i>r</i>	0.231	0.14	0.31	0.21	-0.155
<i>P</i>	0.111	0.32	0.007	0.13	0.2
SpO ₂					
<i>r</i>	-0.423	-0.284	-0.27	-0.278	0.235
<i>P</i>	0.003	0.053	0.01	0.05	0.112
MMRC					
<i>r</i>	0.470	0.323	0.355	0.2	-0.320
<i>P</i>	0.001	0.027	0.014	0.043	0.028

FEV1=Forced expiratory volume in 1 s, FVC=Forced vital capacity, MMRC=Modified Medical Research Council, ABG=Arterial blood gas

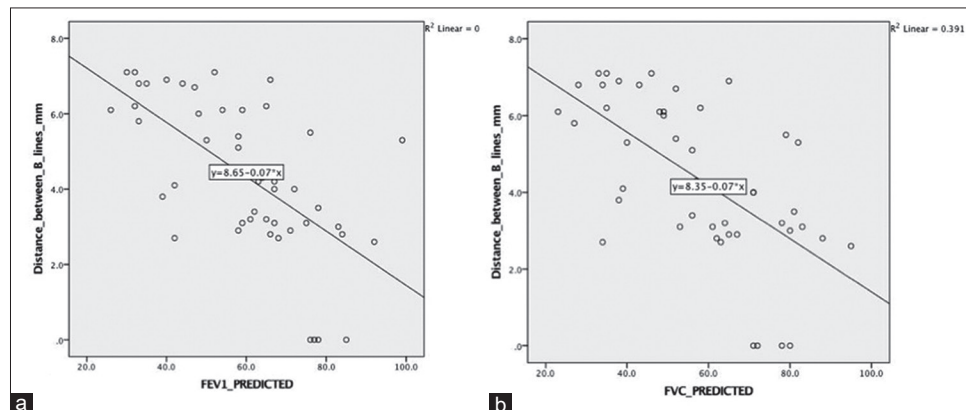


Figure 5: Scatter plot showing negative correlation between B-line distance and Predicted Forced expiratory volume in 1 s (a) and predicted forced vital capacity (b)

sliding ($P = 0.159$) were not statistically significant. Ground-glass opacities on HRCT were significantly associated with subpleural changes ($P < 0.001$) and pleural thickening ($P = 0.018$), whereas mosaic attenuation of lung parenchyma was not significantly associated with any of the observed LUS parameters.

Discussion

HRCT is the imaging modality of choice in the evaluation of ILD. Its excellent spatial resolution enables early detection of the lung pathology, assessment of the extent of lung involvement and can identify the pattern of involvement leading to a specific diagnosis.^[8] Treatment in ILD revolves around corticosteroid and other immunosuppressive drugs, although demonstrated to

have only a modest response on morbidity and overall survival. The assessment of disease severity and serial monitoring is integral to the effective management of patients with ILD.

Moreover, based on the predominant changes identified on HRCT, cases can be categorized into inflammatory-predominant findings (ground-glass opacities) and fibrosis predominant changes (septal thickening and honeycombing). This distinction is therapeutically important as ILD with a predominance of inflammation have a better prognosis and often respond to treatment^[2,7,9-12] Ultrasound is an inexpensive, readily available and radiation-free investigation, and data from the present study showed that LUS can provide a radiological estimate of disease severity in ILD patients.

Various clinical, spirometric, and radiological parameters have been shown to correlate with disease severity in ILD patients.^[6,13-17] However, none of the parameters or techniques has been unequivocally validated. The current consensus relies on combined assessment of different domains of disease severity consisting of clinical assessment (cough and dyspnea), functional markers (6-min walk distance), physiological markers (spirometry and DLCO) and Radiological marker (quantitative CT). In this study, we used MRC breathlessness scale, Predicted FVC and predicted FEV1, and Arterial blood gas parameters as the dependent variables to stratify the severity in our cohort and compare the LUS data.

Studies suggest a better negative predictive value of LUS compared to chest radiography in ruling out ILD. Various LUS features have been identified in the previous studies that indicate ILD. These findings include irregular and fragmented pleural line, subpleural hypoechoic areas,

B-line pattern, pleural thickening, and decreased or absent lung sliding.^[18] In our study, the most consistent finding observed in cases of ILD was B-lines, followed by irregular pleural lines and thickened pleura. B-line artifacts, first demonstrated by Ziskin *et al.*, are linear echogenic lines arising from the pleural line extending to the bottom of the screen and moving with lung sliding on ultrasonography.^[18-21] These lines can be seen using both a low-medium frequency convex probe and a high-frequency linear probe.^[22] In this study, although we could demonstrate these lines using both the probes, we used a convex probe for the measurement of B-line distance because of better subjective visibility. Dietrich *et al.* observed that B-line artifact counts were higher while using a convex probe.^[21,23] In this study, we could demonstrate that higher B-line distance was associated with more severe disease. This was concordant with the results of previous studies that showed that B line distance in fibrotic thickening of the interlobular septum is higher (7 mm) than that in alveolar inflammatory involvement and ground glass opacities (3 mm).^[24-26] This may be because histologically, the interlobular septa are 7 mm apart when they reach the subpleural space.^[26,27] In the present study, mean B-line distance in NSIP patients was 3.03 mm, whereas that in IPF patients was 6.03 mm. B-line distance correlated well with FEV1, FVC, and MMRC dyspnea grade. Further, B-line distance higher than 4.7 mm predicted had high sensitivity and specificity to predict MMRC dyspnea grade of 3 or more.

Irregular, interrupted pleural lining was found in 34/47 patients, whereas thickened pleura was seen in 17 patients, similar to previous studies.^[22,28] The pleural thickness of 1.75 or higher predicted severe dyspnea (MMRC >2) with moderate sensitivity and specificity. On linear regression analysis, the associations were not significant with FEV1, FVC or MMRC grade. Subpleural hypoechoic areas that may represent consolidation, cavitation, fibrosis, cysts, or honeycombing were seen in slightly over one-third of patients, similar to a previous study.^[29] Decreased lung

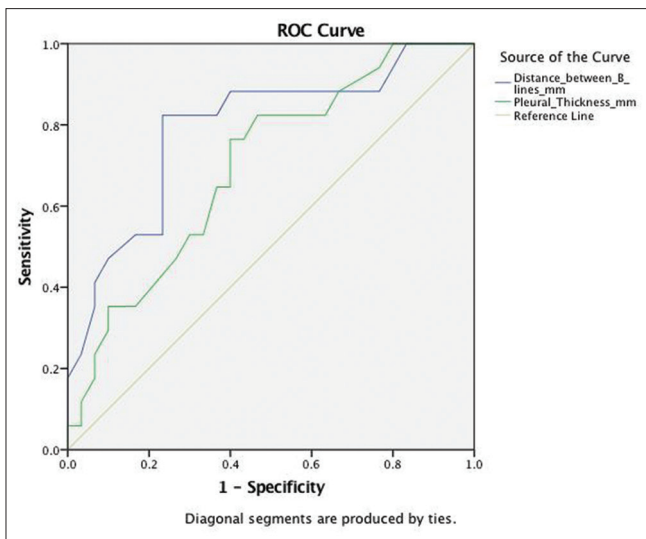


Figure 6: Receiver operated characteristic curve drawn for values of pleural thickness (green line) and B-line distance (Purple line) to predict MMRC Dyspnea score of 3 or more

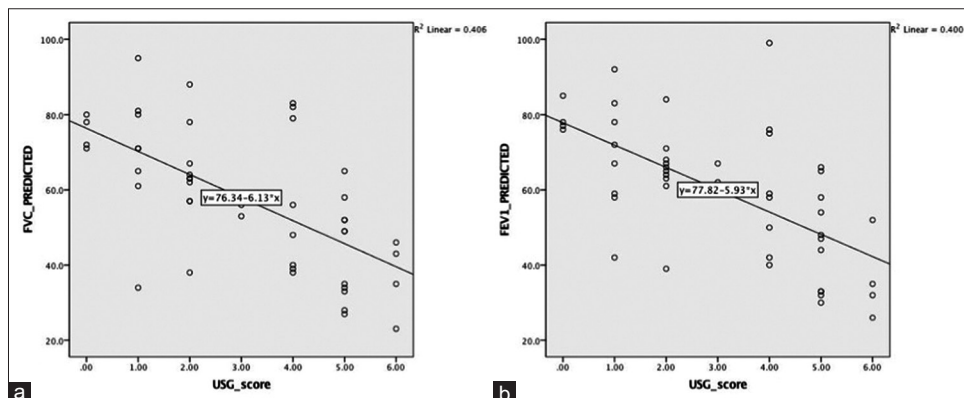


Figure 7: Scatter Plot showing negative correlation between lung ultrasound Score and predicted forced vital capacity (a) and predicted Forced expiratory volume in 1 s (b)

sliding, thought to represent a measure of extensive fibrosis, was seen approximately 25% of patients, similar to previous studies.^[22,28]

There have been few attempts in previous studies to quantify the severity of pulmonary fibrosis based on LUS findings. Studies have shown that the total number of B-lines shows an excellent correlation with lung fibrosis using a previously described 30-point Warrick score on HRCT.^[12,30,31] One of the studies has utilized B-line distance while grading the severity.^[32] The counting of the total number of B-lines is a tedious and cumbersome process. Moreover, none of these studies have taken into account the other LUS findings. We have devised a simpler scoring system, which takes into account all the LUS features. B-line distance showed a highly significant negative correlation with PFT. Hence, a B-line distance between 2.5 and 5 mm was given one point (representing inflammatory predominant activity) and 5.1–7.5 mm was assigned two points (representing fibrosis predominant pathology). One point each was given for the presence of the rest of the LUS parameters, i.e., pleural irregularity, pleural thickening, subpleural changes, and decreased lung sliding. The value of Cronbach's alpha, for our LUS severity score, was 0.702, which places our severity score in the category of Acceptable. LUS severity score of 4 or more predicted MMRC dyspnea score of >3 with high sensitivity and specificity. Moreover, the LUS severity score showed a good negative correlation predicted FEV1, predicted FVC, and a good positive correlation with MMRC dyspnea grade. The study shows that our simple scoring system can provide a reasonably good measure of disease severity.

Honeycombing observed on HRCT was significantly associated with subpleural changes, pleural irregularity, and decreased lung sliding on LUS in the present study. Ground-glass opacities on HRCT were significantly associated with subpleural changes and pleural thickening. These observations in our study imply that LUS can provide some insight into prognostic CT findings of the patients as extensive reticulations and honeycombing is an independent predictor of mortality in patients of ILD.

We realize that there are a few limitations of our study. First, the number of patients included was relatively small. Second, subjects selected in this study were already diagnosed with ILD based on HRCT, and the radiologist in our study performing the sonography was not blinded to HRCT findings, which may introduce a bias. Third, although we envision a potential role of LUS in the monitoring of the effect of therapy, an actual follow-up scan with LUS scoring was not performed after initiation of therapy, which may be done in subsequent studies.

Conclusion

To conclude, our study demonstrates that LUS findings can provide a semi-quantitative assessment of disease severity in patients with ILD. LUS parameters significantly correlate with FVC, FEV1, MMRC dyspnea scale, and ABG parameters. Of the various LUS parameters, B-line distance appears to be more closely related to disease severity in ILD patients, both in terms of spirometric measures and severity of clinical dyspnea. The results of our study suggest that there is a potential role of LUS in the follow-up of the patients with ILD because of its low cost, absence of radiation burden, and ability to be used as point-of-care ultrasound (POCUS). We recommend larger, multicentric studies to gather evidence to support the use of POCUS in follow-up of the ILD patients as well as in directing the workup of patients with undiagnosed disease. Moreover, future studies should also explore the utility of LUS in early recognition of ILD, especially comparing them to chest radiographs and HRCT.

Financial support and sponsorship

Nil.

Conflicts of interest

There are no conflicts of interest.

References

1. Cottin V, Hirani NA, Hotchkin DL, Nambiar AM, Ogura T, Otaola M, *et al.* Presentation, diagnosis and clinical course of the spectrum of progressive-fibrosing interstitial lung diseases. *Eur Respir Rev* 2018; 27:180076.
2. Kalchier-Dekel O, Galvin JR, Burke AP, Atamas SP, Todd NW. Interstitial Lung Disease and Pulmonary Fibrosis: A Practical Approach for General Medicine Physicians with Focus on the Medical History. *J Clin Med* 2018;7:476.
3. Bradley B, Branley HM, Egan JJ, Greaves MS, Hansell DM, Harrison NK, *et al.* Interstitial lung disease guideline: The British Thoracic Society in collaboration with the Thoracic Society of Australia and New Zealand and the Irish Thoracic Society. *Thorax* 2008;63 Suppl 5:v1-58.
4. Trulock EP, Christie JD, Edwards LB, Boucek MM, Aurora P, Taylor DO, *et al.* Registry of the International Society for Heart and Lung Transplantation: Twenty-fourth official adult lung and heart-lung transplantation report-2007. *J Heart Lung Transplant* 2007;26:782-95.
5. Demedts M, Behr J, Buhl R, Costabel U, Dekhuijzen R, Jansen HM, *et al.* High-dose acetylcysteine in idiopathic pulmonary fibrosis. *N Engl J Med* 2005;353:2229-42.
6. Robbie H, Daccord C, Chua F, Devaraj A. Evaluating disease severity in idiopathic pulmonary fibrosis. *Eur Respir Rev* 2017;26:170051.
7. Remy-Jardin M, Remy J, Wallaert B, Bataille D, Hatron PY. Pulmonary involvement in progressive systemic sclerosis: Sequential evaluation with CT, pulmonary function tests, and bronchoalveolar lavage. *Radiology* 1993;188:499-506.
8. Bhat IM, Bhat JA, Shamshad M, Malik A, Mir S. Role of high-resolution computed tomography chest in interstitial lung diseases. *Int J Sci Stud* 2016;4:20-26.

9. Park JH, Kim DS, Park IN, Jang SJ, Kitaichi M, Nicholson AG, *et al.* Prognosis of fibrotic interstitial pneumonia: Idiopathic versus collagen vascular disease-related subtypes. *Am J Respir Crit Care Med* 2007;175:705-11.
10. Strollo DC, Franks TJ, Galvin JR. The idiopathic interstitial pneumonias: Histology and imaging. *Semin Roentgenol* 2015;50:8-15.
11. Remy-Jardin M, Giraud F, Remy J, Copin MC, Gosselin B, Duhamel A. Importance of ground-glass attenuation in chronic diffuse infiltrative lung disease: Pathologic-CT correlation. *Radiology* 1993;189:693-8.
12. Gargani L. Imaging of interstitial lung disease in systemic sclerosis: Computed tomography versus ultrasound. *Int J Clin Rheumatol* 2011;6:87-94.
13. du Bois RM, Weycker D, Albera C, Bradford WZ, Costabel U, Kartashov A, *et al.* Forced vital capacity in patients with idiopathic pulmonary fibrosis: Test properties and minimal clinically important difference. *Am J Respir Crit Care Med* 2011;184:1382-9.
14. du Bois RM, Albera C, Bradford WZ, Costabel U, Leff JA, Noble PW, *et al.* 6-Minute walk distance is an independent predictor of mortality in patients with idiopathic pulmonary fibrosis. *Eur Respir J* 2014;43:1421-9.
15. Papiris SA, Daniil ZD, Malagari K, Kapotsis GE, Sotiropoulou C, Milic-Emili J, *et al.* The medical research council dyspnea scale in the estimation of disease severity in idiopathic pulmonary fibrosis. *Respir Med* 2005;99:755-61.
16. Maldonado F, Moua T, Rajagopalan S, Karwoski RA, Raghunath S, Decker PA, *et al.* Automated quantification of radiological patterns predicts survival in idiopathic pulmonary fibrosis. *Eur Respir J* 2014;43:204-12.
17. Jacob J, Bartholmai BJ, Rajagopalan S, Kokosi M, Nair A, Karwoski R, *et al.* Automated quantitative computed tomography versus visual computed tomography scoring in idiopathic pulmonary fibrosis: Validation against pulmonary function. *J Thorac Imaging* 2016;31:304-11.
18. Volpicelli G, Elbarbary M, Blaivas M, Lichtenstein DA, Mathis G, Kirkpatrick AW, *et al.* International evidence-based recommendations for point-of-care lung ultrasound. *Intensive Care Med* 2012;38:577-91.
19. Thickman DI, Ziskin MC, Goldenberg NJ, Linder BE. Clinical manifestations of the comet tail artifact. *J Ultrasound Med* 1983;2:225-30.
20. Ziskin MC, Thickman DI, Goldenberg NJ, Lapayowker MS, Becker JM. The comet tail artifact. *J Ultrasound Med* 1982;1:1-7.
21. Dietrich CF, Mathis G, Blaivas M, Volpicelli G, Seibel A, Wastl D, *et al.* Lung B-line artefacts and their use. *J Thorac Dis* 2016;8:1356-65.
22. Sperandeo M, Varriale A, Sperandeo G, Filabozzi P, Piattelli ML, Carnevale V, *et al.* Transthoracic ultrasound in the evaluation of pulmonary fibrosis: Our experience. *Ultrasound Med Biol* 2009;35:723-9.
23. Sperandeo M, Varriale A, Sperandeo G, Polverino E, Feragalli B, Piattelli ML, *et al.* Assessment of ultrasound acoustic artifacts in patients with acute dyspnea: A multicenter study. *Acta Radiol* 2012;53:885-92.
24. Hasan AA, Makhlof HA. B-lines: Transthoracic chest ultrasound signs useful in assessment of interstitial lung diseases. *Ann Thorac Med* 2014;9:99-103.
25. Bouhemad B, Zhang M, Lu Q, Rouby JJ. Clinical review: Bedside lung ultrasound in critical care practice. *Crit Care* 2007;11:205.
26. Lichtenstein D, Mézière G, Biderman P, Gepner A, Barré O. The comet-tail artifact. An ultrasound sign of alveolar-interstitial syndrome. *Am J Respir Crit Care Med* 1997;156:1640-6.
27. Gutierrez M, Salaffi F, Carotti M, Tardella M, Pineda C, Bertolazzi C, *et al.* Utility of a simplified ultrasound assessment to assess interstitial pulmonary fibrosis in connective tissue disorders--preliminary results. *Arthritis Res Ther* 2011;13:R134.
28. Sayed SS, Agmy GM, Said AF, Kasem AH. Assessment of transthoracic sonography in patients with interstitial lung diseases. *Egypt J Bronchol* 2016;10:105-12.
29. Reissig A, Kroegel C. Transthoracic sonography of diffuse parenchymal lung disease: The role of comet tail artifacts. *J Ultrasound Med* 2003;22:173-80.
30. Warrick JH, Bhalla M, Schabel SI, Silver RM. High resolution computed tomography in early scleroderma lung disease. *J Rheumatol* 1991;18:1520-8.
31. Tardella M, Di Carlo M, Carotti M, Filippucci E, Grassi W, Salaffi F. Ultrasound B-lines in the evaluation of interstitial lung disease in patients with systemic sclerosis: Cut-off point definition for the presence of significant pulmonary fibrosis. *Medicine (Baltimore)* 2018;97:e0566.
32. Assayag D, Kaduri S, Hudson M, Hirsch A, Baron M. High Resolution Computed Tomography Scoring Systems for Evaluating Interstitial Lung Disease in Systemic Sclerosis Patients. *Rheumatology* 2012; S1:003.