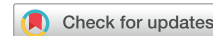

# Antenatal Membranous Nephropathy and Type 2 (Axonal) Charcot-Marie-Tooth With Mutations in the Metallo-Membrane Endopeptidase Gene: A Call for Family Screening and Pharmacovigilance



Joëlle L. Nortier<sup>1</sup>, Gauthier Remiche<sup>2</sup>, Paul Delrée<sup>3</sup>, Jeroen Nauta<sup>4</sup>, Nicolette C. Notermans<sup>5</sup>, Marina Vivarelli<sup>6</sup>, Daria Diodato<sup>7</sup>, Guilhem Solé<sup>8</sup>, Hanna Debiec<sup>9</sup> and Pierre Ronco<sup>9,10</sup>

<sup>1</sup>Nephrology Department, CHU Brugmann, Université libre de Bruxelles, Brussels, Belgium; <sup>2</sup>Neurology Department, Centre de Référence Neuromusculaire Erasme-HUDERF, Hôpital Erasme, Université libre de Bruxelles, Brussels, Belgium; <sup>3</sup>Pathology Department, Institute of Pathology and Genetics, Gosselies, Belgium; <sup>4</sup>Department of Pediatric Nephrology, Erasmus MC, Sophia Childrens Hospital, Rotterdam, The Netherlands; <sup>5</sup>Department of Neurology, University Medical Center, Utrecht, The Netherlands; <sup>6</sup>U.O. Nefrologia e Dialisi, Children's Hospital Bambino Gesù, IRCCS, Roma, Italy; <sup>7</sup>Neuromuscular and Neurodegenerative Diseases Unit, Children Research, Children's Hospital Bambino Gesù, IRCCS, Roma, Italy; <sup>8</sup>Centre de référence des maladies neuromusculaires AOC, Pellegrin Hospital, Bordeaux, France; <sup>9</sup>Sorbonne Université, Inserm UMR\_S1155, Tenon Hospital, Paris, France; and <sup>10</sup>Nephrology Department, Centre Hospitalier du Mans, Le Mans, France

**Correspondence:** Joëlle Nortier, Nephrology Department, CHU Brugmann, Université libre de Bruxelles, 4 place Van Gehuchten, 1020 Brussels, Belgium. E-mail: [joelle.nortier@chu-brugmann.be](mailto:joelle.nortier@chu-brugmann.be) or E-mail: [joelle.nortier@ulb.be](mailto:joelle.nortier@ulb.be)

Received 12 April 2021; accepted 19 April 2021; published online 12 May 2021

*Kidney Int Rep* (2021) 6, 1981–1986; <https://doi.org/10.1016/j.ekir.2021.04.034>

KEYWORDS: congenital nephropathy; maternofetal allo-immunization; membranous nephropathy; MME gene; neprilysin; neutral endopeptidase; peripheral neuropathy

© 2021 International Society of Nephrology. Published by Elsevier Inc. This is an open access article under the CC BY-NC-ND license (<http://creativecommons.org/licenses/by-nc-nd/4.0/>).

In 2002, two of us (HD, PR) identified the first human podocyte antigen, neutral endopeptidase (NEP), in membranous nephropathy (MN) in a French child of Portuguese origin who was born with the nephrotic syndrome.<sup>1</sup> MN could be experimentally reproduced in rabbit infused with the mother's serum that contained anti-NEP antibodies. The mother was deficient in NEP and thus became immunized at a previous miscarriage against the NEP antigen presented by placenta cells. The consequence of this allo-immunization process was the transplacental passage of anti-NEP antibodies during the last trimester of pregnancy that caused the development of MN in the offspring. Two other families from the Netherlands and Morocco (living in Belgium) were then investigated, which led to identification of the cause of NEP deficiency as a truncating mutation in *MME*, the gene coding for NEP.<sup>2</sup> Two additional families from Italy and Germany were subsequently reported with the same homozygous truncating mutation c.466delC (p.Pro156Leufs\*14).<sup>3</sup>

Here, we report the outcome of the 6 mothers from 4 families (Table 1, Figure 1), the German mother being lost to follow-up. Despite the absence of NEP protein due to homozygous or compound heterozygote mutation, the mothers aged 18 to 24

years at the time of the first pregnancy were healthy without renal or neurological manifestation. By contrast with *MME* null mice,<sup>4</sup> they had normal blood pressure, renal functional tests, lymphocyte phenotypes, and functions.<sup>2</sup> The same absence of abnormal phenotype also found in a male individual (Table 1), was mostly due to compensation by an enzyme that remains to be identified. However, more than a decade later, all the NEP-deficient individuals developed progressive sensorimotor length-dependent peripheral neuropathy (PNP) symptoms, suggestive of type 2 (axonal) Charcot-Marie-Tooth disease. In this report, we analyze the clinical and histopathological features of all 7 patients and we discuss the clinical impact of those findings for monitoring NEP-deficient families and preventing cases of neonatal allo-immune MN.

## RESULTS

Figure 1 (a–c) describes the 4 families, including the neurological manifestations in the mothers who did not develop signs of renal disease and the renal manifestations in the offspring.

Neurological symptoms developed between the age of 30 and 43 years, 10 to 18 years after the first

**Table 1.** Clinical and electrophysiological data from 7 NEP-deficient patients with type 2 (axonal) Charcot-Marie-Tooth disease

Patients with homozygous c466delC (p.Pro156Leufs*14) MME gene mutation <sup>a</sup>	Moroccan family						
	II:2	II:3	II:4	II:6	II:4	II:2	III:3
	Moroccan family			Dutch family		Italian family	Portuguese family
Gender	F	F	F	M	F	F	F
Plasma creatinine (mg/dl) / eGFR (ml/min per 1.73 m <sup>2</sup> )	0.50 / 119	0.56 / 119	0.69 / 110	0.78 / 133	0.36 / 102	0.8 / 124	0.71 / 105
Current age = age at the assessment (yr)	48	41	40	34	59	50	43
Age at diagnosis of MME deficiency (yr)	30	23	22	16	41	37	26
Age at onset (first symptoms of polyneuropathy) (yr)	43	no symptoms	30	30	39	40	42
Age at diagnosis of polyneuropathy (electrodiagnostic test) (yr)	44	40	36	33	50	47	42
Polyneuropathy disease duration	5	no symptoms	10	4	19	10	1
Pregnancies (number; M/F; age; MN+/-; PLEX+/-)	1; M; 18; -; -	1; M; 23; MN+; PLEX-	1; F; 20; MN-; PLEX-	-	1; M; 21; MN+; PLEX-	1 = miscarriage	1 = miscarriage
	2; F; 20; <sup>b</sup> ; -	2; M; 26; MN+; PLEX+ †	2; F; 23; MN+; PLEX+	-	-	2; F; 27; MN+; PLEX-	2; M; 24; MN+; PLEX-
	3; M; 24; -; -	3; F; 31; MN+; PLEX-	3; M; 29; MN+; PLEX+	-	3; F; 42; MN+; PLEX-	3 = miscarriage	3 = miscarriage
	4; F; 26; -; -	-	-	-	-	-	-
	5; M; 32; <sup>b</sup> ; -	-	-	-	-	-	-
	6; M; 35; -; -	-	-	-	-	-	-
First neurologic symptoms	Steppage, walking impairment and lower limbs pain	None	Climbing stairs and walking impairment and lower limbs pain	Lower limb cramps and exercise intolerance	Walking impairment, lower limb cramps	Balance impairment, lower limb cramps	Ataxia
Current functional status	Balance impairment, walking limitations, use of plantar orthosis, frequent fall ( $\approx$ 1/mo)	No functional limitation	Balance impairment, walking limitations, use of plantar orthosis and a cane, frequent fall (< 1/ mo)	Mild functional limitation (limitations to climbing stairs)	Balance impairment, walking limitations, use of plantar orthosis, weakness of hands	Steppage gait, wasting of distal muscles of legs	Very mild ataxia, no functional limitation (no walking limitation, no fall, no weakness)
Neurologic examination							
Distal amyotrophy	+	-	+	+	+	+	-
<i>Pes cavus</i>	+	-	+	-	-	-	-
Distal motor impairment	+	-	+	+	+	-	-
Distal sensory impairment	+	+	+	-	+	n.a.	+
Gait unsteadiness	+	-	+	+	+	+	+
Diminished/abolished reflexes	+	+ <sup>c</sup>	+	-	+	+	-
Electrodiagnostic tests							
Lower limbs							
Impaired motor conduction velocity	+	+ <sup>d</sup>	+	+	+	+	+

(Continued on following page)

**Table 1.** (Continued) Clinical and electrophysiological data from 7 NEP-deficient patients with type 2 (axonal) Charcot-Marie-Tooth disease

Patients with homozygous c466delC (p.Pro156Leufs*14) <i>MME</i> gene mutation <sup>a</sup>	II:2		II:3		II:4		II:6		II:4		II:2		II:3	
	Moroccan family		Moroccan family		Dutch family		Dutch family		Italian family		Portuguese family			
Impaired sensory conduction velocity	+	+	+	+	+	+	+	+	+	+	+	+	+	+
Upper limbs														
Impaired motor conduction velocity	+	+	+	+	+	+	+	+	+	+	+	+	+	+
Impaired sensory conduction velocity	+	+	+	+	+	+	+	n.d.	+	+	+	+	+	+

eGFR, estimated glomerular filtration rate according to Chronic Kidney Disease Epidemiology Collaboration equation; F, female; M, male; MN+, presence of antenatal membranous nephropathy; MN-, absence of antenatal membranous nephropathy; n.a., not assessed; PLEX+, plasma exchanges during pregnancy; PLEX-, no plasma exchanges during pregnancy.

<sup>a</sup>Except Patient III:3 found heterozygous compound for the c.466delC (p.Pro156Leufs\*14) and the c.1342C>T (p.Arg448Ter) *MME* gene mutations.

<sup>b</sup>Neonatal hematuria.

<sup>c</sup>Only ankle reflex on the left side.

<sup>d</sup>Only absence of F wave on the left peroneal nerve.

<sup>e</sup>No response on the external saphenous nerves.

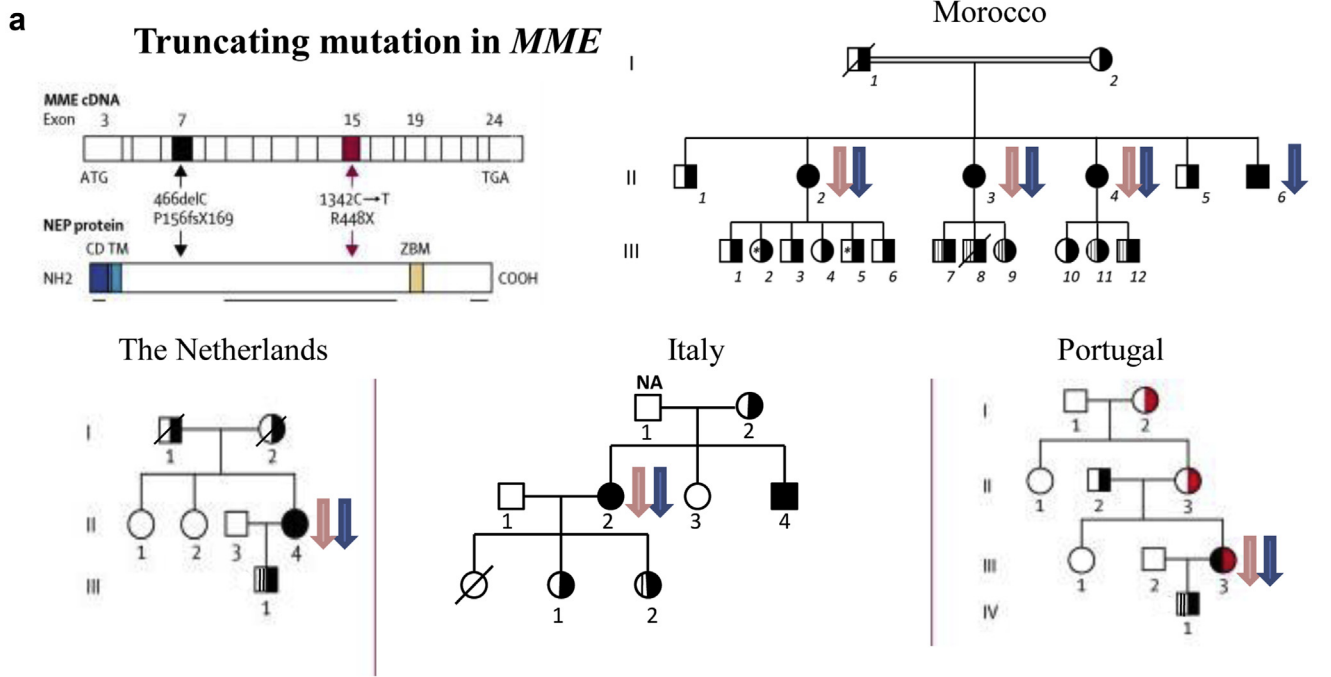
pathologic pregnancy. The patients suffered from vasomotor painful episodes and progressive gait disturbances and muscular weakness of the lower limbs with foot drop and frequent falls (Figure 1c). Substantial variability in the severity of clinical disabilities even between members of the same family was observed (Table 1).

### Moroccan Family

**Patient II:2**, a 48-year-old woman, bore 6 children without noticeable renal manifestation except for transient hematuria in 2 of her newborns (second and fifth). Remarkably, she only produced anti-NEP IgG4 antibodies, whereas the other sisters who bore children with antenatal MN produced IgG1 in addition to IgG4.<sup>2</sup> She progressively experienced steppage, walking impairment, and lower limb pain at the age of 43. Clinical examination showed distal amyotrophy, *pes cavus*, distal motor weakness (distal lower limbs Medical Research Council [MRC] score for feet extensor at 3+/5 bilaterally), distal sensory impairment, gait unsteadiness, and abolished ankle reflexes. Electrodiagnostic tests confirmed the presence of a 4-limb moderate sensorimotor axonal PNP. Due to an accidental fall at the age of 44 years, the patient experienced a fracture of the distal part of the fibula needing osteosynthesis. Fragments of the sural nerve were histologically analyzed at that time (Figure 1c).

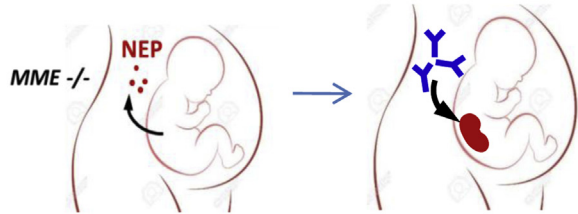
Her sister, **Patient II:3**, 41 years old, bore 3 children with antenatal MN; her second child died at day 6 of life from a vasomotor shock with cerebral hemorrhage. Up to now, she has no significant neurologic symptom. Clinical examination showed only a mild sensory impairment (25% of errors in pinprick-touch discrimination on feet and left ankle reflex abolishment). Electrodiagnostic test confirmed the diagnosis of an early stage of slight sensory PNP involving the lower limbs.

**Patient II:4** is a 40-year-old woman who bore 2 children with antenatal MN(2:F, 3:M) despite i.v.Ig and plasma exchanges during the last trimester of the second pregnancy and intensive plasma exchanges during the third pregnancy.<sup>5</sup> Ten years later, she presented with vasomotor painful episodes and progressive muscle weakness of the lower limbs characterized by limitations to climb stairs, walking impairment, foot drops, and frequent falls. This was improved by foot orthosis. Clinical examination showed distal amyotrophy, *pes cavus*, distal motor weakness (MRC score between 0/5 and 2/5), distal sensory impairment, gait unsteadiness, and abolished ankle reflexes. Electrodiagnostic tests confirmed the presence of a 4-limb moderate sensorimotor axonal PNP.

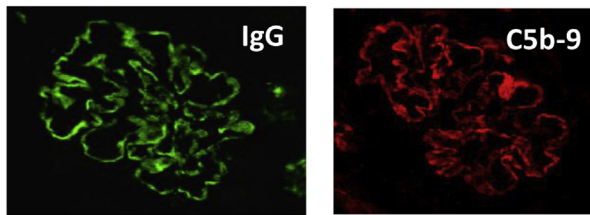


**b** **Antenatal membranous nephropathy**

↓ Females *MME*<sup>-/-</sup> develop alloimmunization



Anti-*NEP* antibodies are transferred to their *MME*<sup>+/-</sup> children

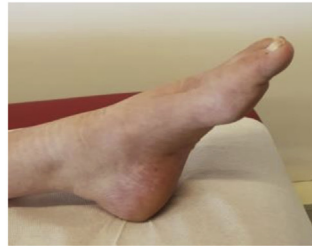

Children are born with MN and nephrotic syndrome

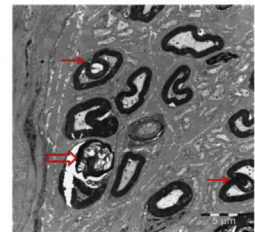
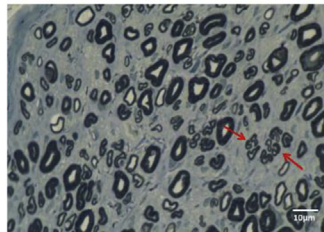
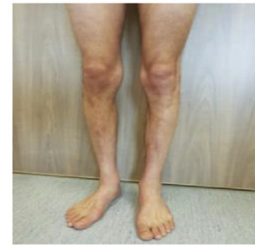**c** **Charcot-Marie-Tooth type 2 CMT2**

↓ Females and males *MME*<sup>-/-</sup> lately develop peripheral axonal neuropathy

*Pes cavus*



Distal amyotrophy



Alterations of myelinated axons and myelin sheaths

**Figure 1.** Overview of the 4 families and depiction of the neurological manifestations in the individuals with biallelic mutations in the neprilysin (*NEP*)/metallo-membrane endopeptidase (*MME*) gene and the renal disease in their offspring. (a) The truncating mutations in *MME* gene found in 4 families (6 women and 2 men) and the corresponding pedigrees showing males (squares) and females (circles) still alive or deceased (slash). Subjects are numbered by birth order, the lowest number being attributed to the oldest. Filled shapes represent homozygous c.466delC (p.Pro156Leufs\*14) *MME* gene mutation, and half-filled squares and circles depict heterozygous status. The Portuguese index case was heterozygous compound for the c.466delC and the c.1342C>T (p.Arg448Ter) mutations. Dashed squares and circles refer to antenatal membranous nephropathy; asterisks refer to transient neonatal hematuria. (b) The pathophysiological mechanism of antenatal membranous nephropathy (MN) developed in *MME*<sup>+/-</sup> fetuses (red arrows) after transplacental transfer of anti-*NEP* antibodies (IgG1 or IgG4). (Continued)



**Patient II:6** is a 34-year-old man who suffered from lower limb cramps and exercise intolerance since the age of 30 related to sensorimotor axonal PNP.

### Dutch Family

**Patient II:4** is a 59-year-old woman who, at the age of 21 years, delivered a male infant born with anuria. The diagnosis of MN was made on a kidney biopsy performed at 3 days of age.<sup>6</sup> She progressively developed lower limb weakness and wasting, and since the age of 39 years, she also complained about muscle cramps and wasting of her hands. She had no sensory features except occasional paresthesia in her hands without any pain. At the age of 50 years, examination noted symmetrical atrophy of the interosseous muscles, lower arms, quadriceps, lower limbs, and feet. There was no proximal weakness of the shoulder, the biceps and triceps muscles were MRC 4, wrist flexors and extensors MRC 3, the intrinsic hand muscles were also affected (MRC 2). There was proximal weakness of the legs MRC 4 (especially of the quadriceps MRC 3) and distal weakness of the legs MRC 0. All tendon reflexes were absent. Touch and pain sensation was normal in arms and legs.

### Italian Family

**Patient II:2** is a woman aged 50, who after a miscarriage had a first infant at the age of 27 years with mild to moderate transient proteinuria at birth, which resolved completely without treatment in the first year of life. At the age of 42 years, she bore a second child, who presented with acute renal failure and anasarca at birth. A renal biopsy showed MN.<sup>3</sup> At the age of 41 years, she developed wasting of distal muscles of her legs. Seven years later, electrodiagnostic tests confirmed an axonal sensory-motor PNP of upper and lower limbs. The latest neurological examination at 49 years of age showed a steppage gait, possible only with monolateral support; there was symmetrical atrophy of the interosseous muscles of the arms, moderate atrophy of quadriceps bilaterally, and marked atrophy of the lower legs and feet.

### Portuguese Family

**Patient III:3** is a 44-year-old woman who, at the age of 24, had a miscarriage at 14 weeks of gestation 2 months before she became pregnant with a male infant born

with oligoanuria. A diagnosis of MN was made by a kidney biopsy at 1 month of age.<sup>1</sup> She then experienced a great number of miscarriages despite i.v.Ig and plasma exchanges. Eighteen years later, she presented with slight ataxia, distal sensory impairment, and gait unsteadiness. Nerve conduction tests revealed a reduction of distal sensory amplitudes in the lower limbs associated with a slight slowing of motor conduction velocities and prolonged F-response latencies in the lower limbs.

## DISCUSSION

We report here the late development in the third and fourth decades of PNP in NEP-deficient individuals with a family history of allo-immune MN. This expands to *all* available families reported so far, the findings observed in the Moroccan family living in Belgium that were reported in a neurology journal.<sup>7</sup>

Nepriylisin/*MME* is a highly glycosylated protein able to hydrolyze numerous physiologically active peptides like enkephalins, P-substance,  $\beta$ -amyloid, gastrin, somatostatin, atrial natriuretic peptide, angiotensin II, and endothelin-1. Its wide distribution, including in the central and peripheral nervous system, accounts for the association of neurological abnormalities with antenatal MN linked to *MME* gene mutation. The same c.466delC (p.Pro156Leufs\*14) mutation has been reported by other groups in patients with late-onset Charcot-Marie-Tooth disease but no information was given on pregnancy complications in the affected women.<sup>8,9</sup> However, contrary to the glomerular disease, which is immune mediated, the pathophysiology of the neuropathy is unknown. These observations underline the need for a prolonged surveillance of families affected with rare diseases.

These findings have important clinical implications. Identification of *MME*-related Charcot-Marie-Tooth disease in families should lead to early screening of women predisposed to fetomaternal allo-immunization and renal complications in their offspring. Conversely, one should monitor development of axonal PNP in mothers with affected offspring and in other family members with bi-allelic *MME* mutation. Finally, we suggest that prolonged administration in patients with heart failure of an angiotensin receptor antagonist combined with a NEP inhibitor should include careful

**Figure 1.** (Continued) Kidney biopsy findings of one of the neonates born with MN and nephrotic syndrome (anti-IgG and C5b-9 immunostaining). (c) The phenotype of biallelic *MME*-mutated patients displaying symptoms of peripheral axonal sensorimotor polyneuropathy (PNP) (blue arrows). Typical *pes cavus* and distal lower limb amyotrophy exhibited by Patient II:4 and her brother Patient II:6, respectively, from the same Moroccan family. Bottom left: semithin section (toluidine blue staining) of a sural nerve fascicle (Patient II:2) showing 2 axonal clusters (arrows) with respectively 3 and 5 regenerating axons in 2 adjacent Schwann cells. Myelin fiber density is focally diminished. Bar scale: 10  $\mu$ m. Bottom right: ultrathin section showing (small arrows) skinny axons with myelin sheath loop induced by myelin redundancy. Large arrow points to a skinny axon enwrapped by a partially degenerating myelin sheath. Bar scale: 5  $\mu$ m.

long-term neurological surveillance, although no adverse effect has been reported as yet, possibly for lack of sufficient hindsight.

## DISCLOSURE

All the authors declared no competing interests.

## ACKNOWLEDGMENTS

This work was presented as a Poster during the ASN Kidney Week 2019 in Washington, DC, USA.

## SUPPLEMENTARY MATERIAL

[Supplementary File \(PDF\)](#)

[Supplementary Methods.](#)

[Supplementary References](#)

## REFERENCES

1. Debiec H, Guignonis V, Mougnot M, et al. Antenatal membranous glomerulonephritis due to anti-neutral endopeptidase antibodies. *N Engl J Med.* 2002;346:2053–2060.
2. Debiec H, Nauta J, Coulet F, et al. Role of truncating in MME gene in fetomaternalalloimmunization and antenatalglomerulopathies. *Lancet.* 2004;364:1252–1259.
3. Vivarelli M, Emma F, Pellé T, et al. Genetic homogeneity but IgG subclass-dependent clinical variability of alloimmune membranous nephropathy with anti-neutral endopeptidase antibodies. *Kidney Int.* 2015;87:602–609.
4. Lu B, Figini M, Emanuelli C, et al. The control of microvascular permeability and blood pressure by neutral endopeptidase. *Nat Med.* 1997;3:904–907.
5. Nortier JL, Debiec H, Tournay Y, et al. Neonatal disease in neutral endopeptidase alloimmunization: lessons for immunological monitoring. *Pediatr Nephrol.* 2006;21:1399–1405.
6. Nauta J, de Heer E, Baldwin WM, et al. Transplacental induction of membranous nephropathy in a neonate. *Pediatr Nephrol.* 1990;4:111–116.
7. Dupuis M, Raymackers JM, Ackermans N, et al. Hereditary axonal neuropathy related to MME gene mutation in a family with fetomaternal alloimmune glomerulonephritis. *Acta Neurol Belg.* 2020;120:149–154.
8. Auer-Grumbach M, Toegel S, Schabutt M, et al. Rare variants in MME, encoding metalloprotease neprilysin, are linked to late-onset autosomal-dominant axonal polyneuropathies. *Am J Human Genet.* 2016;99:607–623.
9. Lupo V, Frasquet M, Sanchez-Monteagudo A, et al. Characterizing the phenotype and mode of inheritance of patients with inherited peripheral neuropathies carrying MME mutations. *J Med Genet.* 2018;55:814–823.