



## Original Article

# Preliminary analysis on the MD-4<sup>®</sup> plasma-sprayed titanium acetabular component<sup>☆</sup>



Elmano de Araújo Loures, Leandro Furtado Simoni, Isabel Cristina Gonçalves Leite, Daniel Naya Loures\*, Clarice Naya Loures

Universidade Federal de Juiz de Fora, Juiz de Fora, MG, Brazil

## ARTICLE INFO

## Article history:

Received 12 February 2014

Accepted 24 February 2014

Available online 19 March 2015

## Keywords:

Osseointegration

Hip arthroplasty

Hip prosthesis

## ABSTRACT

**Objectives:** To evaluate the short-term performance of a type of implant manufactured in Brazil.

**Methods:** This study analyzed a cohort of 60 patients who underwent implantation of MD-4<sup>®</sup> acetabular components during primary hip arthroplasty procedures performed between January 1, 2010, and August 1, 2012. The patients were studied retrospectively with regard to clinical behavior, stability and radiological osseointegration. The patients were followed up for a minimum of 12 months and a maximum of 42 months (mean: 27) and were evaluated by means of the Harris Hip Score, SF-36 questionnaire and serial conventional radiographs.

**Results:** All the components were radiologically stable, without evidence of migration or progressive radiolucency lines. On average, the Harris Hip Score evolved from 36.1 to 92.1 ( $p < 0.001$ ) and the SF-36 showed significant increases in all its domains ( $p < 0.001$ ). No differences were observed among patients with osteoarthritis, osteonecrosis, hip dysplasia or other conditions.

**Conclusions:** The short-term results showed clinical and radiological signs of stability and osseointegration of the implants, which may represent a predictive factor regarding medium-term survival of this acetabular component.

© 2015 Sociedade Brasileira de Ortopedia e Traumatologia. Published by Elsevier Editora Ltda. All rights reserved.

## Análise preliminar do componente acetabular de titânio plasma-spray MD-4<sup>®</sup>

## RESUMO

**Objetivos:** avaliar o desempenho em curto prazo de um tipo de implante fabricado no Brasil.

**Métodos:** estudo de uma coorte de 60 pacientes que tiveram componentes acetabulares MD-4<sup>®</sup> implantados durante artroplastias primárias do quadril, entre 1 de janeiro de 2010 e 1 de agosto de 2012, e foram estudados retrospectivamente com relação ao comportamento

## Palavras-chave:

Osteointegração

Artroplastia de quadril

Prótese de quadril

<sup>☆</sup> Work developed at the University Hospital, Universidade Federal de Juiz de Fora, Juiz de Fora, MG, Brazil.

\* Corresponding author.

E-mail: [loures.elmano@oi.com.br](mailto:loures.elmano@oi.com.br) (D.N. Loures).

<http://dx.doi.org/10.1016/j.rboe.2015.03.003>

2255-4971/© 2015 Sociedade Brasileira de Ortopedia e Traumatologia. Published by Elsevier Editora Ltda. All rights reserved.

clínico, à estabilidade e à osteointegração radiológica. Os indivíduos foram acompanhados por 12 meses no mínimo e no máximo 42 (média: 27) e avaliados por meio do Harris Hip Score, do questionário SF-36 e de radiografias convencionais seriadas.

**Resultados:** todos os componentes estavam radiologicamente estáveis, sem evidência de migração ou de linhas de radioluzência progressivas. Em média, o Harris Hip Score evoluiu de 36,1 para 92,1 ( $p < 0,001$ ) e o SF-36 mostrou incremento significativo em todos os domínios ( $p < 0,001$ ). Nenhuma diferença foi observada entre pacientes com osteoartrose, osteonecrose, displasia do quadril ou outras condições.

**Conclusões:** os resultados de curto prazo mostraram sinais clínicos e radiológicos de estabilidade e de osteointegração dos implantes, o que pode representar um fator preditivo quanto à sobrevivência em médio prazo do componente acetabular considerado.

© 2015 Sociedade Brasileira de Ortopedia e Traumatologia. Publicado por Elsevier Editora Ltda. Todos os direitos reservados.

## Introduction

Over the last 20 years, a large variety of porous surfaces and metallic materials have been used to achieve fixation by means of bone growth (ingrowth) in total joint prostheses for the hip and other joints. The ones most commonly used are composed of titanium or titanium alloys, rough-surfaced chromium–cobalt metal alloys and woven metal fiber. The external coatings of the cups present macro or microporosity, such as that obtained through spraying the surface with titanium (plasma spray) or, more recently, through using trabeculated metal.<sup>1</sup>

Studies on animal models, clinical studies and evidence from implants removed postmortem (retrievals) have demonstrated the capacity of porous surfaces for favoring bone growth through ingrowth and generating osseointegration. They are effective for supplementing or ensuring the primary mechanical stability that is achieved through introducing the implant under pressure (i.e. press-fitting it), with or without adjuvant screws.<sup>2</sup> Weller and Volkmann<sup>3</sup> found that pores of diameters between 50 and 200  $\mu\text{m}$  favored bone ingrowth and noted that spraying with titanium is a method capable of reproducing these parameters.

Absence of early translation of the metal cup is considered to be indicative of good medium and long-term results.<sup>4,5</sup> Bone growth on the porous external surface of the implant is influenced by the size of the pores, properties inherent to the materials and close proximity between the bone and implant.<sup>6</sup> Surface roughness and osteoconductivity of the titanium coating have been correlated with the primary and secondary stability of the implants.<sup>4</sup>

The primary objectives of the present analysis were to investigate the clinical performance, stability and presence of short-term radiological signs of osseointegration of the acetabular component analyzed, and whether there might be any association between the stability and fixation of the cup and the variables of etiological diagnosis, age, positioning and primary stability of the implant. There are no studies in the literature on the performance of the acetabular component analyzed in this series.

## Materials and methods

This study was approved by our institution's research ethics committee under the number CEP 408.719. All the individuals selected explicitly agree to participate through a free and informed consent statement.

This was an observational clinical study that examined an initial group of 62 individuals, from which a cohort of 60 individuals was retrospectively evaluated for a minimum period of 12 months and a maximum of 42 months (mean: 27). The MD-4<sup>®</sup> acetabular component (MDT Ind. Com. Imp. Exp. Implantes Ltda.) was used under uniform conditions by the same surgeon at a regional teaching and referral hospital between January 2010 and August 2012. The acetabular component was used together with a polished cemented femoral nail with a centralizer and a plug to occlude the femoral canal, which were all manufactured in Brazil. A second-generation cementation technique was used.<sup>7</sup> All the individuals received two adjuvant titanium screws. Only two cases were lost during the follow-up.

The MD-4<sup>®</sup> acetabular component is composed of a hemispherical cup that is manufactured using the 6Al–4V titanium alloy.<sup>8</sup> The external coating of plasma-sprayed titanium has a mean thickness of 150  $\mu\text{m}$  and a mean pore size of 224  $\mu\text{m}$ . The component has three peripheral holes for inserting adjuvant titanium fixation screws and one central (polar) hole for the impaction guide. The insert of ultra-high molecular weight polyethylene is molded by means of a machining process. It has 18 notches and an edge raised by 10°, and it is sterilized by means of gamma rays for use with femoral heads of 22 mm (only for cups of 44–48 mm) and 28 mm (for other measurements).

The cases selected were only affected in a single joint and presented grade IV in the classification of Kellgren and Lawrence for osteoarthritis.<sup>9</sup> Complete clinical data were registered before the operation and after 6, 12, 18 and 24 months of evolution. Conventional radiographs were obtained before the operation, during the immediate postoperative period, after six weeks of evolution and after 3, 6, 12, 18 and 24 months of follow-up. The clinical and radiological evaluations were made by the senior author. The radiographs were reviewed by a second independent trained observer who was also a

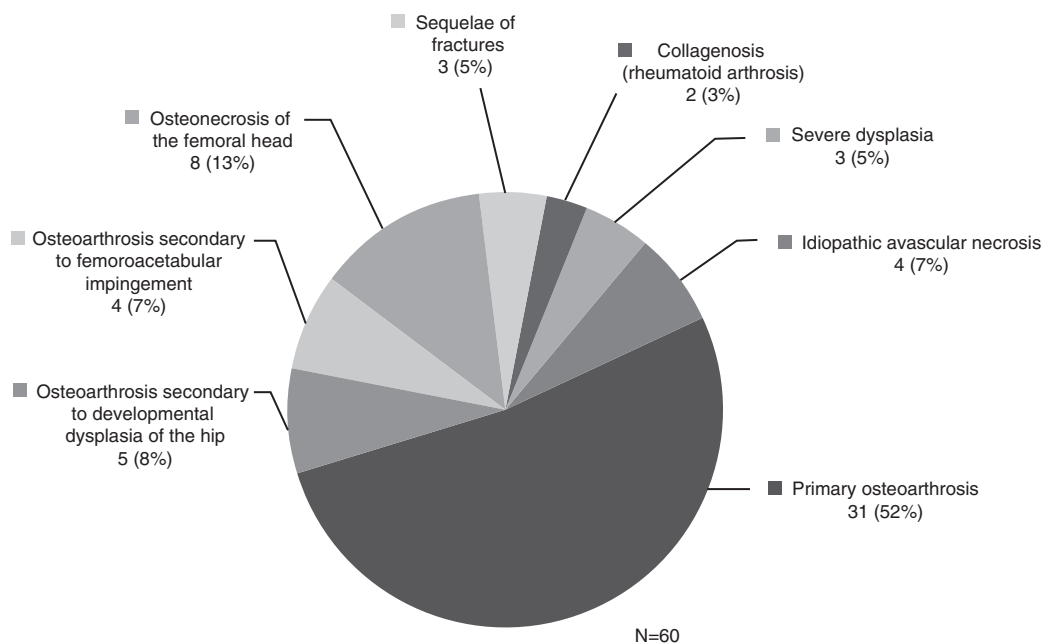


Fig. 1 – Etiological distribution of the study sample.

physician but was not involved directly with the provision of care for the individuals under analysis. Conventional radiographs were obtained in anteroposterior and lateral views of the proximal femur and coxofemoral joint, with magnification of approximately 15%. The clinical and functional variables were evaluated by means of a specific instrument, i.e. the Harris Hip Score (HHS),<sup>10</sup> which was used in association with the SF-36 questionnaire.<sup>11</sup> The Harris Hip Score (excellent: 90–100 points; good: 80–90; satisfactory: 70–79; and poor: lower than 70) and the SF-36 questionnaire were applied before the operation and at the six-month follow-up. The standard deviation was calculated for each item investigated, before and after the operation. The Mann–Whitney test was used for paired comparisons when the data were normally distributed and the Wilcoxon test was used for nonparametric data. The significance level was set as  $p < 0.05$ . The data analysis was developed using the Statistical Package for the Social Sciences (SPSS), version 15.0 (Chicago, IL, USA).

The etiologies of the cases are described in Fig. 1 and the age groups of the individuals are shown in Fig. 2.

The modified Hardinge lateral hip access<sup>12</sup> was used in lateral decubitus. A cephalic component of diameter 22 mm was used in only one case of a cup of size 44 mm, in a patient with developmental dysplasia of the hip. All the other cases received an interchangeable head of 28 mm in diameter. Second-generation cephalosporin was used as prophylaxis against infection, for the entire sample: 2 g immediately before the operation and then 1 g every 8 h. This was continued until the vacuum drain was removed, no more than 48 h after the procedure. For prophylaxis against thromboembolism, the approach recommended by Salvati et al.<sup>13</sup> was used, consisting of use of elastic stockings, stimulation of early movement and use of aspirin: 300 mg/day for 30 days, starting from the second day after the operation. Use of enoxaparin (40 mg/day for 21 days) was reserved for

cases with a high risk of thromboembolism (16.8% of the individuals).

Shavers 2 mm smaller than the external diameter of the cup were used. The external diameter had been selected previously by means of transparencies (templates), with a view to ensuring a good press fit. All the cysts identified during the surgical procedure were curetted and pasty autologous spongy graft was applied. This was obtained from the final shaving and from the femoral head. A massive autologous graft from the femoral head, fixed with spongy screws, was used in two hips to correct acetabular dysplasia. In implanting the component, the aim was to restore the anatomical center of rotation of the hip and the orientation of the so-called safety zone of Lewinnek et al.,<sup>14</sup> i.e. abduction of  $40 \pm 10^\circ$  and anteversion of  $15 \pm 10^\circ$ . The primary stability of the cup was tested

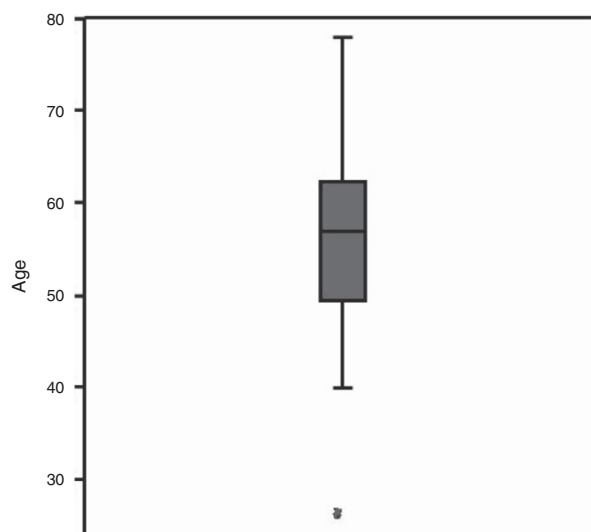


Fig. 2 – Age groups of the study sample.

intraoperatively and a visual check was made to see whether there was any level of movement after the final impaction. From the third postoperative day, partial weight-bearing using forearm crutches was authorized, and this was maintained until the 45th day, when full weight-bearing on the operated limb was allowed.

The radiographs obtained after six weeks of evolution formed the initial parameter for identifying cysts, failures at the bone-implant interface, radiolucent lines and migration of the component.

As recommended by Malizos et al.,<sup>6</sup> in the zones in which the surface of the component was not in close contact with the bone on the reference radiograph, this finding was classified as a "flaw" (gap). This was done to establish a distinction in relation to radiolucent lines that might appear on subsequent radiographs, in areas where no flaws existed initially. The subchondral cysts were identified and monitored. To evaluate the migration of the component, we used the criterion of Nunn et al.,<sup>15</sup> which is recommended for early evaluations in which the polyethylene insert is not expected to have become worn. In this methodology, the reference points are the teardrop, the center of the head and the horizontal and vertical distances between the center of the head and the ipsilateral and contralateral teardrops. The following findings were considered to be indicative of loosening and instability: a circumferential radiolucent zone >2 mm involving more than 50% of the bone-implant interface; and vertical or horizontal migration greater than or equal to 2 mm. The reference points considered were the teardrop and the distances from this to the upper and medial edges of the acetabulum and to the center of the cup<sup>16</sup> and/or changes to the inclination of the cup of 4°.<sup>17</sup>

The radiological parameters that have been reported to be indicative of failure of fixation and of osseointegration of the implant consist of observation of progressive and/or complete radiolucent lines at the bone-implant interface and the presence of flaws (gaps) at the bone-metal interface and bone cysts that do not fill over the course of time, with or without associated migration of the component. According to several authors, this parameter constitutes definitive evidence of instability and loosening.<sup>18,19</sup>

The localization of the radiological findings was based on the classification of DeLee and Charnley.<sup>20</sup>

---

## Results

Satisfactory stability (with press fit) was obtained, as verified during the operation, in 53 individuals (88.3%). Three acetabular components positioned with an abduction angle of more than 50° were observed. These were among the seven individuals (11.7%) in whom the initial press-fit stability was unsatisfactory. The mean angle of inclination (abduction) of the acetabular component was 45.5° (minimum of 35° and maximum of 56°). Six cases (10%) presented radiolucent lines of 1 or 2 mm in two zones at the six-month follow-up, but there was no radiographic progression and/or migration and/or instability of the implant at the follow-ups 12 and 18 months after the operation. An apparent increase in bone density was observed in 13 cases (21.6%), in DeLee and Charnley's zones 1 and 2.<sup>20</sup>

Six out of the 12 subchondral cysts that had been identified decreased in size between the third and sixth months, and four of them showed subtotal filling after nine months of evolution. The other six continued to present the same appearance. A small bone flaw (gap) was detected in the polar region in four cases (6.6%) in this series, with partial filling after 18 months of observation in three cases and total filling in one case.

The complications observed were as follows: one case of neuropraxia of the fibular portion of the sciatic nerve, in which the limb stretching reached 2.5 cm, with partial recovery seen after six months of evolution and full recovery after 18 months; once case of superficial infection with favorable resolution and retention of the implant; and one case of deep vein thrombosis. There were no cases of instability/dislocation or heterotopic ossification. It was also observed from the radiographic control done six months after the operation that a tiny fragment had become detached from the greater trochanter in two cases, with marked osteopenia. Both of these cases evolved to bone consolidation, without any clinical repercussions.

All the cemented femoral components were found to have remained fixed, without any signs of subsidence or radiolucent lines, and with intact homogenous cement layers. They were classified by the observers as well positioned, except in two cases, in which slight varus deviation of the nail was seen.

In the present study, there was discordance between the two observers in 14 cases (23.3%) with regard to the presence of discontinuity of the bone-metal interface (presence of gaps or radiolucency greater than 2 mm), from which low interobserver concordance was inferred. A consensus was reached at a second combined evaluation with repetition of the radiographs.

A positive association was observed in this series between absence of satisfactory primary press-fit stability and positioning of the acetabular component at an angle outside of the safety zone ( $p < 0.001$ ). However, this did not compromise the secondary stability.

During the postoperative follow-up, no occurrences of acetabular or femoral osteolytic lesions were detected. Nor was there any measurable wear on the polyethylene insert. Therefore, given the criteria used and taking implant revision for any reason as an outcome (Kaplan-Meyer analysis), 100% of the acetabular components were stable and functional at the time of the last radiological control (Tables 1 and 2, Figs. 3-6).

---

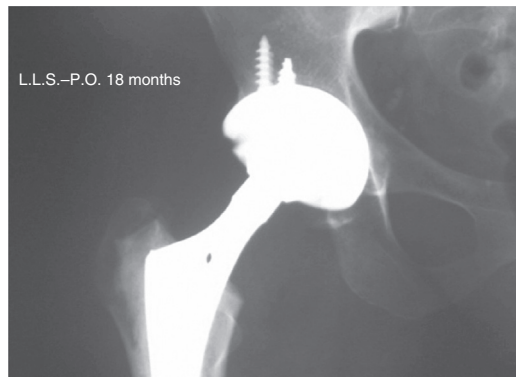
## Discussion

Implant performance can be evaluated through a variety of clinical methods and through imaging. Hirakawa et al.<sup>21</sup> emphasized that the performance of an implant and its osseointegration can be measured by performing tests and clinical assessments, but that the definitive judgment should be made after postmortem examination of the implants (retrievals). This view was corroborated by Cuckler.<sup>22</sup>

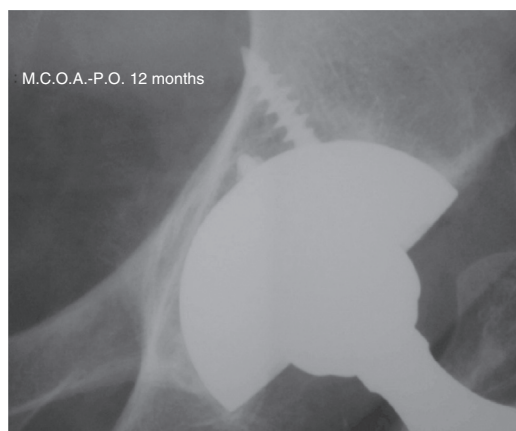
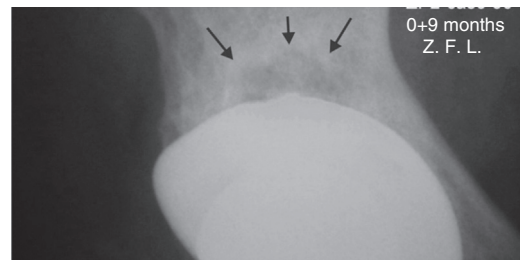
Although conventional radiographic analysis allows observers to obtain valuable data, the two-dimensional nature and technical variations of this examination are a limitation on its use.<sup>17</sup> On the other hand, its low cost and

**Table 1 – Mean scores for the eight domains that constitute the SF-36 and Harris Hip Score (HHS) and their statistical significance (*p*-value).**

Variables	Before operation Mean (SD)	After operation Mean (SD)	<i>p</i>
SF-36			
Functional capacity	12.9 (15.1)	52.6 (27.7)	<0.010
Limitation due to physical aspects	7.9 (19.9)	47.1 (41.0)	<0.001
Pain	23.6 (18.5)	62.3 (25.7)	<0.002
General state of health	55.9 (23.1)	71.0 (22.5)	<0.001
Vitality	41.6 (23.1)	69.1 (21.8)	<0.001
Social aspects	41.8 (24.2)	73.9 (25.1)	<0.001
Emotional aspects	22.9 (35.0)	66.7 (37.0)	<0.001
Mental health	54.6 (26.8)	80.3 (17.8)	<0.001
HHS	36.4 (15.1)	92.3 (5.7)	<0.001

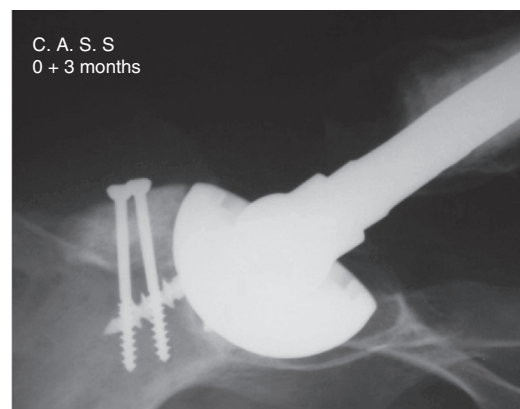
**Fig. 3 – Radiological osseointegration, 18 months after the operation.**

ease of access, and the familiarity of observers with the technique, stimulate its routine use universally. Radiostereometry techniques provide greater accuracy in evaluating implant translation and rotation, but they are not readily available in our setting.<sup>23</sup> Gruen et al.<sup>24</sup> reported on the radiographic results from evaluating an acetabular component in an extensive multicenter study that used conventional radiography. Although no consensus has been reached, some investigators have assessed the accuracy of simple radiographs in relation to the state of fixation of uncemented acetabular components and have reported that sequential radiographs in

**Fig. 4 – Radiological osseointegration, 12 months after the operation.****Fig. 5 – Partial filling of cyst, nine months after the operation.**

anteroposterior and lateral views have high sensitivity (94%) and specificity (100%), with a 100% positive prediction value for identifying the status of porous hemispherical acetabular cups.<sup>25</sup>

Some authors have taken the view that alterations to the position of the implant of 1 mm over the first years probably reduce its useful life, while others have believed that migration of up to 2 mm would not be a definitive sign of aseptic loosening.<sup>26,27</sup> Although the presence of complete radiolucent lines is suggestive of loosening, migration of the component is considered to be the only safe criterion for asserting that the acetabular component has loosened and not become integrated. Therefore, determining this is critical for the diagnosis and requires standardized serial radiographs based on correct anatomical reference points.<sup>19</sup>

**Fig. 6 – Dysplasia: graft integration and stable cup, three months after the operation.**

**Table 2 – Demographics and summary description of the cases and radiological findings.**

Patient	Age	Gender	Side	Follow-up (months)	Diagnosis	HHSi	HHSf	Relevant data
1	60	F	Left	42	Dysplasia	30.1	98.9	
2	43	M	Right	42	Femoroacetabular impingement	18.5	92.0	
3	52	M	Left	42	Primary osteoarthritis	55.3	88.4	
4	45	M	Right	42	Osteonecrosis	44.7	97.9	
5	26	M	Right	41	Osteonecrosis	32.0	100.0	
6	62	F	Right	40	Primary osteoarthritis	44.5	99.9	
7	68	F	Right	40	Primary osteoarthritis	53.9	84.0	
8	64	M	Right	40	Dysplasia	5.7	95.0	
9	57	M	Right	40	Primary osteoarthritis	52.9	84.8	
10	57	F	Left	40	Rheumatoid arthritis	13.3	97.9	
11	48	M	Left	40	Primary osteoarthritis	44.4	90.7	Ang. >50°
12	51	M	Left	40	Osteonecrosis	47.2	97.9	
13	63	F	Right	40	Primary osteoarthritis	48.4	99.4	
14	64	F	Right	39	Primary osteoarthritis	38.8	87.7	Ang. >50°
15	52	M	Right	38	Primary osteoarthritis	36.0	88.8	
16	60	M	Left	37	Sequelae of fractures	25.8	93.0	
17	53	M	Right	37	Primary osteoarthritis	54.3	89.9	Ang. >50°
18	73	F	Right	37	Primary osteoarthritis	25.8	84.8	Neuropraxia of sciatic nerve
19	45	M	Left	37	Femoroacetabular impingement	56.6	97.0	
20	42	F	Left	37	Dysplasia	42.7	90.0	
21	54	F	Right	37	Primary osteoarthritis	52.0	92.0	
22	62	F	Left	37	Primary osteoarthritis	25.4	80.8	
23	42	M	Right	37	Osteonecrosis	31.6	87.1	
24	52	F	Right	36	Dysplasia	5.4	88.5	Superficial infection
25	56	M	Right	36	Primary osteoarthritis	20.8	100.0	
26	62	M	Right	35	Osteonecrosis	55.4	100.0	
27	55	M	Right	35	Osteonecrosis	25.8	92.9	
28	72	F	Left	35	Primary osteoarthritis	44.4	84.9	
29	45	M	Left	34	Osteonecrosis	19.1	94.0	
30	78	F	Left	34	Sequelae of fractures	45.9	88.5	Trochanter frag.
31	58	M	Right	33	Osteonecrosis	22.8	100.0	
32	58	F	Right	33	Primary osteoarthritis	23.2	91.2	
33	74	F	Right	33	Rheumatoid arthritis	31.9	90.4	Trochanter frag.
34	40	M	Left	33	Primary osteoarthritis	38.7	84.0	
35	72	M	Right	32	Dysplasia	60.3	100.0	
36	62	F	Left	29	Primary osteoarthritis	30.3	98.5	
37	46	M	Left	29	Avascular necrosis	55.4	92.3	
38	57	M	Right	28	Avascular necrosis	44.8	88.0	
39	58	M	Right	28	Primary osteoarthritis	32.0	97.5	
40	67	F	Left	27	Primary osteoarthritis	45.2	99.8	
41	71	M	Left	26	Sequelae of fractures	53.6	100.0	
42	62	F	Right	26	Primary osteoarthritis	14.3	84.5	
43	65	F	Right	23	Primary osteoarthritis	43.7	95.0	
44	54	F	Left	22	Primary osteoarthritis	38.5	85.0	
45	78	M	Left	21	Primary osteoarthritis	56.3	98.0	
46	64	F	Right	21	Dysplasia	25.6	90.5	
47	54	M	Left	20	Primary osteoarthritis	48.5	97.9	
48	43	M	Right	20	Dysplasia	56.0	99.4	
49	53	F	Right	18	Primary osteoarthritis	33.7	87.5	
50	54	M	Right	18	Avascular necrosis	47.8	88.7	
51	63	F	Right	17	Primary osteoarthritis	35.9	93.2	
52	63	F	Right	17	Primary osteoarthritis	40.6	82.0	
53	66	M	Right	16	Femoroacetabular impingement	49.7	96.0	
54	68	M	Right	16	Primary osteoarthritis	31.6	85.6	
55	44	M	Left	16	Dysplasia	52.0	89.4	
56	32	F	Right	16	Primary osteoarthritis	20.7	90.5	
57	66	F	Right	16	Avascular necrosis	42.6	95.5	
59	32	F	Left	15	Avascular necrosis	52.0	100.0	
59	45	M	Right	12	Femoroacetabular impingement	23.4	81.4	DVT
60	55	F	Right	12	Primary osteoarthritis	45.6	99.5	

Ident., identification; F, female; M, male; ang., angle.

In a radiological study that evaluated cups coated with trabecular metal, Macheras et al.<sup>28</sup> demonstrated that over a 24-week follow-up period, it could clearly be seen that the flaws in the bone-implant interface had been filled and that osseointegration of the cups had occurred. Over the long term, none of these implants presented aseptic loosening. It is possible to infer from these studies that conventional radiographic methods continue to be the standard most used routinely for following up and evaluating hip prostheses.

Komarasamy et al.<sup>29</sup> and Mulier et al.<sup>30</sup> reported results with follow-ups of 32 months and 46 months, respectively. Mulier found that the density of spongy bone in zone I increased in 79% of the cases and that in zone III, it increased in 58% of the 24 hips that reached complete radiological evaluations.

The same finding was seen in the radiological evaluations after 12 and 18 months of follow-up, in 13 cases (21.6%) of the present sample.

Clinical-radiological analyses on implants with microporous coatings such as Plasmapore<sup>®</sup>,<sup>31,32</sup> which is equivalent to what is used on the MD-4<sup>®</sup> acetabular component, have highlighted the importance of early bone-implant interaction and its influence on the long-term survival of the prosthetic replacement. The type of coating, the porosity and the size of the pores are crucial factors in relation to osseointegration and secondary stability.

While the limitations of the present study (due to the small number of patients and the short duration of the follow-up) need to be borne in mind, the sample was homogenous in relation to the diverse variables considered. The observed early evidence of radiological osseointegration of the acetabular component becomes important within the context of the absence of recent published data on implants manufactured in Brazil in the indexed medical literature.

## Conclusion

The short-term clinical and radiological results obtained demonstrated that all the implants were stable. In most cases, the acetabular components evaluated showed radiographic signs of osseointegration. These results were equivalent to the performance of similar products under similar conditions, which may constitute a predictive factor with regard to the medium-term survival of the component.

Long-term follow-up of a larger number of individuals and analysis on postmortem specimens are essential for definitive conclusions to be obtained regarding the behavior of this type of implant.

## Conflicts of interest

The authors declare no conflicts of interest.

## REFERENCES

- D'Angelo F, Murena L, Campagnolo M, Zatti G, Cherubino P. Analysis of bone ingrowth on a tantalum cup. *Indian J Orthop.* 2008;42(3):275-8.
- Stallforth H, Blömer W. Biomechanical and technological aspects of cementless hip implants. In: Weller S, Volkmann R, editors. *The bicontacthip implant system.* New York: Thieme Stuttgart; 1994. p. 2-11.
- Weller S, Volkmann R, editors. *The bicontacthip implant system.* New York: Thieme Stuttgart; 1994.
- Engh CA, Bobyn JD, Glassman AH. Porous coated hip replacement: factors governing bone ingrowth, stress shielding and clinical results. *J Bone Joint Surg Br.* 1987;69(1):45-55.
- Rohrl SM, Nivbrant B, Snorrason F, Karrholm J, Nilsson KG. Porous-coated cups fixed with screws: a 12 year clinical and radiostereometric follow-up study of 50 hips. *Acta Orthop.* 2006;77(3):393-401.
- Malizos KN, Bargiotas K, Papatheodorou L, Hantes M, Karachailos T. Survivorship of monoblock trabecular metal cups in primary THA: midterm results. *Clin Orthop Relat Res.* 2008;466(1):159-66.
- Barrack RL, Mulroy RD Jr, Harris WH. Improved cementing techniques and femoral component loosening in young patients with arthroplasty: a 12 year radiographic review. *J Bone Joint Surg Br.* 1992;74(3):385-9.
- ASTM International. ASTM F136-08e1 standard specification for wrought titanium-6 aluminum-4 vanadium ELI (extra low interstitial) alloy for surgical implant applications (UNS R56401). West Conshohocken: ASTM International; 2008.
- Kellgren JH, Lawrence JS. Radiological assessment of osteoarthritis. *Ann Rheum Dis.* 1957;16(4):494-502.
- Guimarães RP, Alves DPL, Silva GB, Bittar ST, Ono NK, Honda E, et al. Tradução e adaptação transcultural do instrumento de avaliação do quadril Harris Hip Score. *Acta Ortop Bras.* 2010;18(3):142-7.
- Quintana JM, Escobar A, Aguirre U, Lafuente I, Arenaza JC. Predictors of health-related quality-of-life change after total hip arthroplasty. *Clin Orthop Relat Res.* 2009;467(11):2886-94.
- Hardinge K. The direct lateral approach to the hip. *J Bone Joint Surg Br.* 1982;64(1):17-9.
- Salvati EA, Sharrock NE, Westrich G, Potter HG, Valle AG, Sculco TP. The 2007 ABJS Nicolas Andry Award: three decades of clinical, basic, and applied research on thromboembolic disease after THA: rationale and clinical results of a multimodal prophylaxis protocol. *Clin Orthop Relat Res.* 2007;459:246-54.
- Lewinnek GE, Lewis JL, Tarr R, Compere CL, Zimmerman JR. Dislocations after total hip replacement arthroplasties. *J Bone Joint Surg Am.* 1978;60(2):217-20.
- Nunn D, Freeman MA, Hill PF, Evans SJ. The measurement of migration of the acetabular component of hip prostheses. *J Bone Joint Surg Br.* 1989;71(4):629-31.
- Lakemeier S, Aurand G, Timmesfeld N, Heyse TJ, Fuchs-Winkelmann S, Schofer MD. Results of the cementless Plasmacup in revision total hip arthroplasty: a retrospective study of 72 cases with an average follow-up of eight years. *BMC Musculoskelet Disord.* 2010;11:101.
- Latimer HA, Lachiewicz PF. Porous-coated acetabular components with screw fixation. Five to ten-year results. *J Bone Joint Surg Am.* 1996;78(7):975-81.
- Rabello BT, Cabral FP, Freitas E, Penedo J, Cury MB, Rinaldi ER, et al. Artroplastia total do quadril não cimentada em pacientes com artrite reumatoide. *Rev Bras Ortop.* 2008;43(8):336-42.
- White RE Jr. Evaluation of the painful total hip replacement. In: Callaghan JJ, Rosenberg AG, Rubash HE, editors. *The adult hip.* 2nd ed. Philadelphia: Lippincott-Wilkins; 2007. p. 1343-8.
- DeLee JG, Charnley J. Radiological demarcation of cemented sockets in total hip replacement. *Clin Orthop Relat Res.* 1976;(121):20-32.

21. Hirakawa K, Jacobs JJ, Urban R, Saito T. Mechanisms of failure of total hip replacements: lessons learned from retrieval studies. *Clin Orthop Relat Res.* 2004;(420):10-7.
22. Cuckler JM. If hip implant retrievals could speak. What would they tell us? *J Bone Joint Surg Br.* 2012;94 11 Suppl. A: 11-3.
23. Thanner J. The acetabular component in total hip arthroplasty. Evaluation of different fixation principles. *Acta Orthop Scand Suppl.* 1999;286:1-41.
24. Gruen TA, Poggie RA, Lewallen DG, Hanssen AD, Lewis RJ, O'Keefe TJ, et al. Radiographic evaluation of a monoblock acetabular component: a multicenter study with 2- to 5-year results. *J Arthroplasty.* 2005;20(3):369-78.
25. Bozic KJ, Rubash HE. The painful total hip replacement. *Clin Orthop Relat Res.* 2004;(420):18-25.
26. Kärrholm J, Herberts P, Hultmark P, Malchau H, Nivbrant B, Thanner J. Radiostereometry of hip prostheses. Review of methodology and clinical results. *Clin Orthop Relat Res.* 1997;(344):94-110.
27. Stocks GW, Freeman MA, Evans SJ. Acetabular cup migration. Prediction of aseptic loosening. *J Bone Joint Surg Br.* 1995;77(6):853-61.
28. Macheras GA, Papagelopoulos PJ, Kateros K, Kostakos AT, Baltas D, Karachalios TS. Radiological evaluation of the metal-bone interface of a porous tantalum monoblock acetabular component. *J Bone Joint Surg Br.* 2006;88(3):304-9.
29. Komarasamy B, Vadivelu R, Bruce A, Kershaw C, Davison J. Clinical and radiological outcome following total hip arthroplasty with an uncemented trabecular metal monoblock acetabular cup. *Acta Orthop Belg.* 2006;72(3):320-5.
30. Mulier M, Rys B, Moke L. Hedrocel trabecular metal monoblock acetabular cups: mid-term results. *Acta Orthop Belg.* 2006;72(3):326-31.
31. Braun A, Papp J, Reiter A. The periprosthetic bone remodelling process – signs of vital bone reaction. *Int Orthop.* 2003;27(Suppl 1):S7-10.
32. Giménez A, Llinares T, Gil A. Cementless acetabular cup: 6 years follow-up. *J Orthop Traumatol.* 2002;3(2):85-7.