



# Simple and Reproducible Microcatheter Shaping Method for Coil Embolization of Medially-directed Paraclinoid Internal Carotid Artery Aneurysms

Hiroyuki Matsumoto, Hirokazu Nishiyama, Daisuke Izawa, and Naotsugu Toki

**Objective:** It is important to guarantee intra-aneurysmal stability of microcatheters during coil embolization. We developed a simple and reproducible microcatheter shaping method for medially-directed paraclinoid internal carotid artery aneurysms.

**Methods:** An injection needle cap was used to make a smooth curve on the mandrel, which was first wound around the back end of the cap to create a primary curve. Next, a secondary curve was created using near the tip of the cap. Thus, a two-dimensional (2D), pigtail-shaped mandrel with a two-stage curve was created. The pigtail-shaped mandrel was inserted from the tip of a straight microcatheter and heat-shaped using a heat gun. Lastly, a microcatheter having a curve whose tip was approximately 6 mm longer than that of the preshaped J was created. We evaluated the ease of navigating the microcatheter into the aneurysm and its stability during coil embolization.

**Results:** In all, 34 consecutive medially-directed paraclinoid internal carotid artery aneurysms were treated using the shaped catheters. It took 50–300 seconds (intermediate value: 90 seconds) from inserting the microcatheter with a microguide wire to navigate and place it into an aneurysm. There were no cases that required reshaping of the microcatheters during navigation into the aneurysm. There were no cases that resulted in kickback of the microcatheters from the aneurysm during coil placement, and microcatheter stability was good until the end of the procedure. In all, 12 cases required the balloon-assisted technique and three cases required stent-assisted coiling. The angiographic outcomes immediately after embolization were as follows: 25 cases (73.5%) with complete occlusion; 3 cases (8.8%) with dome filling; and 6 cases (17.6%) with a neck remnant. There were no perioperative complications.

**Conclusion:** The shaping method with a pigtail-shaped mandrel using an injection needle cap is simple and reproducible, and is useful for medially-directed paraclinoid internal carotid artery aneurysms.

**Keywords** ▶ catheter shaping, internal carotid artery, paraclinoid aneurysm, coil embolization

## Introduction

Medially-directed paraclinoid internal carotid artery aneurysms (paraclinoid ICAAN) are observed at a moderate frequency in clinical practice. When treating cerebral

aneurysms at this site by direct surgery, scraping off the anterior clinoid process, and incision or abrasion of the dural ring are necessary to secure the surgical field and improve the mobility of the parent artery, which make the procedure highly invasive and difficult during direct surgeries. Recently, cerebral aneurysms at this site are often treated by coil embolization, and the results are reported to be favorable.<sup>1-4)</sup> They may appear to be easily approached for coil embolization, but the following problems may arise: (1) it is difficult to navigate the microcatheter into the aneurysm because of the three-dimensional (3D) curvature of the carotid siphon, and even if the microcatheter has been successfully navigated into the aneurysm, (2) it cannot be stabilized as imaged after its placement. We devised a simple and reproducible method to shape the microcatheter to improve its intraoperative guidability and stability

*Department of Neurological Surgery, Kishiwada Tokushukai Hospital, Kishiwada, Osaka, Japan*


Received: June 23, 2019; Accepted: January 29, 2020

Corresponding author: Hiroyuki Matsumoto. Department of Neurological Surgery, Kishiwada Tokushukai Hospital, 4-2-27, Kamoricho, Kishiwada, Osaka 596-8522, Japan  
Email: hiroyuki.matsumoto@tokushukai.jp



This work is licensed under a Creative Commons Attribution-NonCommercial-NoDerivatives International License.

©2020 The Japanese Society for Neuroendovascular Therapy



**Fig. 1** Winding a mandrel around the back end of the 18-G needle cap to create a primary curve (**A** and **C**). Next, winding a mandrel near the tip of the 18-G needle cap to create a secondary curve (**B** and **D**). Two-dimensional and two-stage curves, such as a pigtail, are easily created (**E**). Inserting the pigtail-shaped mandrel from the tip of the straight microcatheter (**F**) and holding it over the heat gun (**G**).

after placement for coil embolization of medially-directed paraclinoid ICAAN, and report its usefulness.

## Subjects and Methods

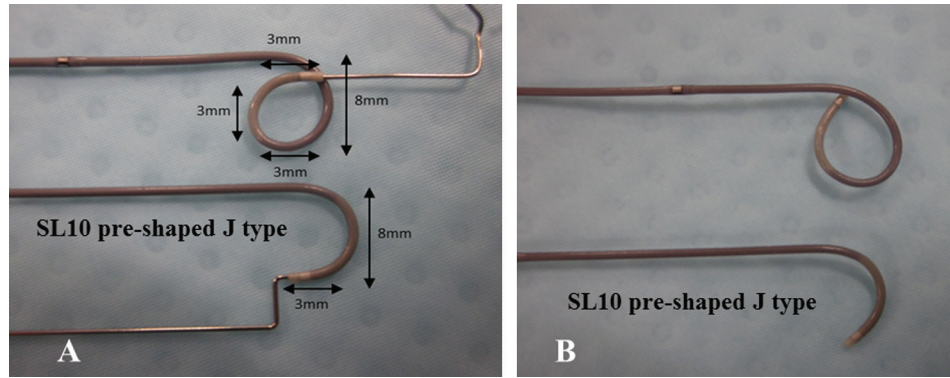
Between April 2013 and February 2019, coil embolization was performed for 306 cerebral aneurysms at our hospital. Among these lesions, coil embolization was performed for 34 (11%) medially-directed paraclinoid ICAAN in 34 consecutive patients using microcatheters shaped by the method described below. The patients consisted of 31 women and 3 men, aged 42–80 years (mean: 62 years), and they all had unruptured aneurysms. The mean maximum diameter of the aneurysms was  $5.1 \pm 1.9$  mm, and the mean dome/neck ratio was  $1.38 \pm 0.31$ .

### Method for microcatheter shaping

We shaped microcatheters using the cap of an 18-G needle (TERUMO NEEDLE; TERUMO PHILIPPINES, Co., Laguna, Philippines). A smooth curve of approximately 8 mm in diameter was made by winding the mandrel around the base end of the cap (**Fig. 1A** and **1C**). Then, a curve of approximately 3 mm in diameter was made by winding the mandrel near the tip of the cap (**Fig. 1B** and **1D**). The

mandrel was eventually shaped into a pigtail-like form with  $8 \text{ mm} \times 3 \text{ mm} \times 3 \text{ mm} \times 3 \text{ mm}$  curves as shown in **Fig. 1E**. The pigtail-shaped mandrel was inserted from the end of a straight microcatheter (**Fig. 1F**). In this state, the microcatheter was heat-shaped by applying heat 2–3 cm from the heat source of a heat gun set at  $150^\circ\text{C}$  for 90 seconds (**Fig. 1G**). The microcatheter was allowed to cool at room temperature for 30–60 seconds, and the mandrel was removed from the microcatheter. By this manipulation, the microcatheter was shaped with a curve approximately 6 mm longer at the tip than a preshaped J microcatheter (**Fig. 2A** and **2B**).

Coil embolization was performed by the standard procedure using a shaped microcatheter. When the coils protruded into the parent artery from wide-necked aneurysms, a balloon-assisted technique was used concomitantly if necessary. A stent-assisted technique was used concomitantly in wide-necked lesions if protrusion of the coils was unable to be prevented by the balloon-assisted technique. The time needed to navigate the microcatheter into the aneurysm, number of re-shaping maneuvers needed, microcatheter stability during procedure, whether the microcatheter deviated due to kickback during procedure, frequency of the use of balloon assistance, and angiographic outcomes immediately after embolization were evaluated.



**Fig. 2** A mandrel is formed into a pigtail-like shape to make a curve of sufficient length at the tip of the pre-shaped J microcatheter, and then the mandrel is inserted from the tip of the straight microcatheter (A). When the mandrel is removed from the tip of the microcatheter after heat shaping, a microcatheter with a longer tip curve than the preshaped J microcatheter is created (B).

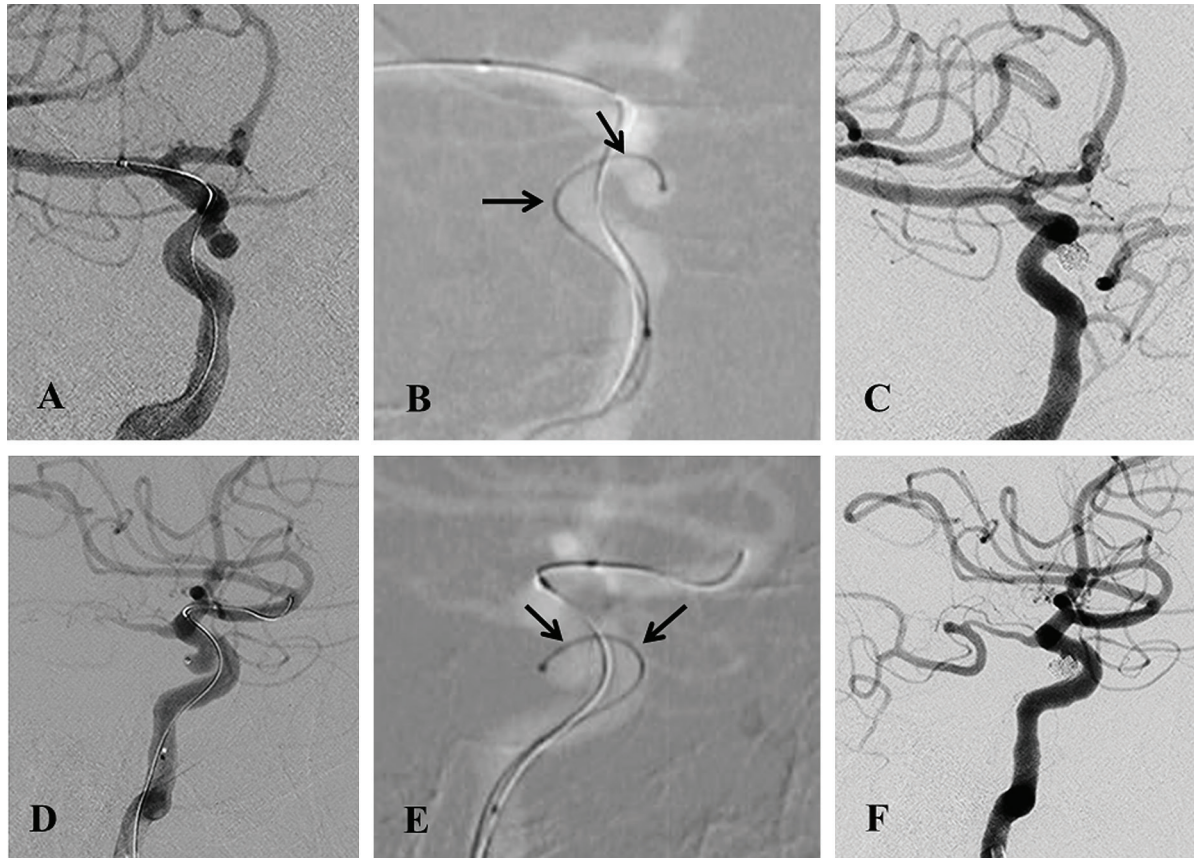
## Results

The microcatheter was directly navigated into the aneurysm using a microguidewire in all patients. There were no cases that required change or reshaping of the microcatheter during navigation into the aneurysm. The time needed from the beginning of insertion of the microcatheter using a microguidewire to its placement in the aneurysm was 50–300 seconds (median: 90 seconds). The microcatheter did not completely deviate from the aneurysm due to kickback during coil insertion in any patient, and its stability was satisfactory until the end of the procedure. A balloon-assisted technique was necessary to prevent coil protrusion in 12 (35%), and a stent-assisted technique was necessary in three patients. The angiographic state immediately after embolization was complete occlusion in 25 (73.5%), dome filling in 3 (8.8%), and neck remnant in 6 (17.6%). There were no perioperative complications.

### Representative case 1 (Fig. 3)

A 55-year-old woman was found to have a medially- and inferiorly-directed right paraclinoid ICAAN in the brain dock, and was referred to us for close evaluation and treatment. Cerebral angiography demonstrated an irregularly shaped medially- and inferiorly-directed right paraclinoid ICAAN measuring 5 mm × 3 mm × 3 mm (Fig. 3A and 3D). The neck of the aneurysm was located near the curved part of the carotid siphon, and the aneurysm size was small. It was speculated that navigation of the microcatheter into the aneurysm was difficult and catheter instability after placement was expected. The necessity of a balloon-assisted technique was also considered in the event of intraoperative

deviation of the coils and microcatheter. Therefore, the tip of a straight SL10 microcatheter (Stryker, Kalamazoo, MI, USA) was shaped using a pigtail-shaped mandrel. Under general anesthesia, a 6Fr ENVOY (Codman & Shurtleff, Raynham, MA, USA) was guided and placed before the petrous part of the internal carotid artery. For assistance, a HyperGlide 4 mm–10 mm (Medtronic, Minneapolis, MN, USA) was placed distally to the aneurysmal neck on standby. A microcatheter was directly guided and placed in the aneurysm using a microguidewire (Transend EX soft tip; Stryker, Kalamazoo, MI, USA). The microcatheter was advanced from the inflow zone to the deep area of the aneurysmal dome, and which was stabilized by having support points on the vascular wall opposite to the aneurysmal neck and at the carotid siphon (Fig. 3B and 3E). After the frame was created using a Galaxy complex fill 4 mm–10 cm (Codman & Shurtleff, Raynham, MA, USA), the coil size was reduced with caution not to allow the microcatheter to kickback, and filling coils were placed in the framing coil. The microcatheter was stable until ED extra soft 3 mm–6 cm (Kaneka Medix Corp., Osaka, Japan), ED extra soft 2 mm–3cm, and ED extra soft 2 mm–2 cm were inserted, and the coils were able to be inserted without kickback. The microcatheter was nearly pushed out from the aneurysmal neck while the ED extra soft 1.5 mm–2 cm was inserted, but it was easily repositioned by catheter control because the shape of the microcatheter was fit, and coils were able to be inserted without deviation of the microcatheter until the end of the procedure. The procedure was finished as the tip of the microcatheter was completely pushed out of the aneurysm into the parent artery at the end of coil insertion. As there was no deviation of the



**Fig. 3** Angiography shows a medially-directed paraclinoid ICA aneurysm, and a balloon catheter has already been placed (**A** and **D**). The microcatheter placed in the aneurysm has two support points (arrows), with the ICA wall opposite to the aneurysmal neck and the wall of the carotid siphon (**B** and **E**). The aneurysm has disappeared on postoperative angiography (**C** and **F**). ICA: internal carotid artery

microcatheter or coils during this procedure, the balloon on standby was not used. Complete occlusion was confirmed on the final angiography (**Figs. 3C** and **3F**).

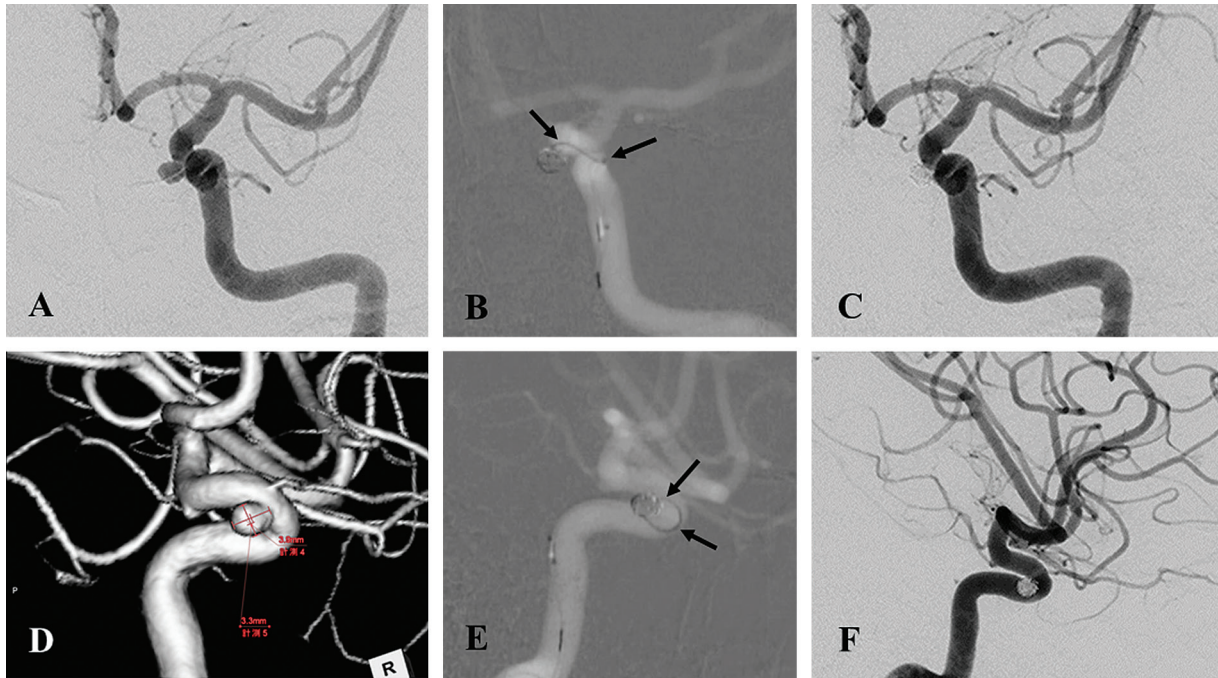
#### Representative case 2 (Fig. 4)

A 43-year-old man was found to have a medially- and inferiorly-directed left paraclinoid ICAAN in the brain dock, and was referred to us for close examination and treatment. Cerebral angiography demonstrated a medially- and inferiorly-directed left paraclinoid ICAAN measuring 4 mm × 3.5 mm × 3 mm. Under general anesthesia, a 6Fr ENVOY was guided and placed before the petrous part of the internal carotid artery. A straight SL10 microcatheter was shaped using a pigtail-shaped mandrel, and guided and placed directly into the aneurysm using a Transend EX soft tip guidewire. Although the aneurysm was relatively small, the microcatheter was stabilized by having support points on the vascular wall opposite to the aneurysmal neck and at the carotid siphon. Therefore, we decided to perform coil embolization by a simple technique.

The frame was created using a Galaxy complex extra soft 3 mm–6 cm, and the microcatheter was highly stable in the aneurysm. Thereafter, two target helical US 2 mm–2 cm coils (Stryker, Kalamazoo, MI, USA) and two target helical nano 2 mm–2 cm and target helical nano 1.5 mm–2 cm coils each were inserted, during which the microcatheter remained stable. The microcatheter was almost pushed out of the aneurysm during insertion of a target helical nano 1 mm–2 cm, but it was repositioned readily and spontaneously, and did not deviate from the aneurysm. As the microcatheter was completely pushed out into the parent artery after insertion of the coil, the procedure was finished. The aneurysm was completely occluded on the final angiography.

## Discussion

The microcatheter shaping method using the injection needle cap was simple, reproducible, and useful for coil embolization of medially-directed paraclinoid ICAAN.



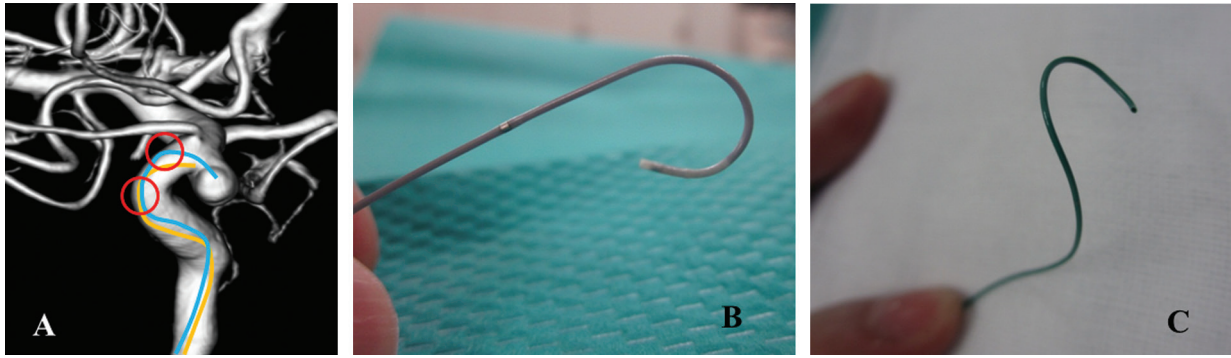
**Fig. 4** Angiography shows a medially-directed paraclinoid ICA small aneurysm (A and D). The microcatheter placed in the aneurysm has two support points (arrows) with the ICA wall opposite to the aneurysmal neck and the wall of the carotid siphon (B and E). The aneurysm has disappeared on postoperative angiography (C and F). ICA: internal carotid artery

In coil embolization of medially-directed paraclinoid ICAAN, the difficulty in navigating the microcatheter into the aneurysm and its stability after placement depend on the degree of curvature of the carotid siphon and the position of the aneurysmal neck. As the curvature of the carotid siphon is 3D, and the direction of the parent artery and that of the axis of protrusion of the aneurysm differ perpendicularly, the driving force of the microcatheter is not effectively applied when guiding the microcatheter into the aneurysm, which make navigation of the guidewire or microcatheter into the aneurysm difficult. Even if the microcatheter has been placed in the aneurysm with effort, unless the microcatheter is sufficiently supported by the vascular wall during procedure, it may be destabilized in the aneurysm. The more aneurysm is smaller and its neck becomes closer to the infra clinoid portion (ICA C3-C4), the more microcatheter navigation is difficult and its stability is poorer. Without stabilization of the microcatheter in the aneurysm, it readily deviates from the aneurysm into the parent artery during coil insertion and drifts distally to the aneurysm. Once the microcatheter has deviated into the parent artery during coil insertion, reposition of the microcatheter, especially in the case of small aneurysms, is challenging. Therefore, in coil embolization of medially-directed paraclinoid ICAAN, appropriate shaping of the microcatheter

is an important factor. Presently, many companies have lineups of preshaped microcatheters, and they are used according to the site and shape of the aneurysm. If the shape of a preshaped microcatheter does not fit the vascular shape or direction of protrusion of the aneurysm, the surgeon often shapes a straight-type microcatheter to fit to the shape and direction of protrusion of the aneurysm or vascular shape.

There are few reports on microcatheter shaping methods or their usefulness. Kwon et al. reported the usefulness of catheter shaping according to the direction of protrusion of paraclinoid aneurysms.<sup>1)</sup> They described that their original pigtail-shaped microcatheters were appropriate for medially-protruding types and that their original S-shaped, preshaped C-type, or straight-type microcatheters were appropriate for superiorly protruding aneurysms. However, details of their original shaping technique were not presented in the report. Recently, Ishibashi et al.<sup>5)</sup> reported a method to prepare simulation models of vascular shapes using a 3D printer before endovascular surgery and create a tailor-made 3D-shaped catheter based on the simulation model. They indicated that 3D printers had not been used in wide yet and much time is required to prepare a simulation model.

In coil embolization of medially-directed paraclinoid ICAAN, the location of the aneurysm and vascular shape



**Fig. 5** The yellow line has only one support point, and the tip cannot reach the aneurysmal dome sufficiently, whereas the blue line has two support points (red circles), and the tip is sufficiently inserted into the aneurysmal dome (A). The tip of the microcatheter removed after coil embolization demonstrates a 3D shape according to the vascular shape (B and C).

of the carotid siphon are often examined by 3D imaging before endovascular surgery, and tailor-made 3D microcatheter shaping is performed for individual patients by the surgeon. However, the positions of support points of the microcatheter on the vascular wall are often not as expected by preoperative simulation. On the contrary, the 3D shape of the microcatheter becomes a factor of instability after its placement. Therefore, balloon assist may be necessary to stabilize the microcatheter during coil insertion.

We previously shaped the tips of microcatheters stick to 3D shaping for individual patients with medially-directed paraclinoid ICAAN, but the catheters did not comfortably fit within the aneurysms, and we often experienced that preshaped J catheters fit best. Although preshaped J catheters were likely to be stable after positioning, the tip of the catheter was frequently stabilized just at the aneurysmal neck without sufficiently entering the aneurysmal dome because of inadequate length (**Fig. 5A**). We learned that if embolization was performed in this state, the microcatheter was readily pushed into the parent artery during coil insertion even by a slight kickback. Thus, we concluded that the length of the tip of the preshaped J microcatheter should be increased to enable its tip to sufficiently enter the aneurysmal dome and to prevent its deviation into the parent artery by obtaining a support point on the vascular wall on the opposite side of the aneurysmal neck (**Fig. 5A**). We devised a shape with the curve at the tip of a SL10 preshaped J-type microcatheter elongated by approximately 6 mm (**Fig. 2A** and **2B**). This enabled the microcatheter to have two or more support points on the vascular wall in the aneurysm, on the opposite side of the aneurysmal neck, or at the carotid siphon (**Fig. 5A**), which improved the stability of the microcatheter after its placement, and reduced the incidence of its deviation into the parent artery. It was necessary

to shape the mandrel into a pigtail form as in **Fig. 1**. Initially, we prepared the shape by manually bending the mandrel, but it was difficult to prepare smooth curves. However, this was facilitated by winding the mandrel around the cap of the injection needle. Moreover, the use of the injection needle cap made it possible for anyone to prepare a uniform mandrel shape, resulting in easy and reproducible shaping of the microcatheter tip. The tips of microcatheters prepared by this method have 2D shapes similar to preshaped J type catheters, and it is unnecessary to make complicated 3D shapes or individually adjust the shape depending on the aneurysm size or vascular shape of the carotid siphon. As the support points on the vascular wall can be any two sites on the opposite side of the aneurysmal neck and at the carotid siphon, the technique is considered to be applicable to many types of medially-directed paraclinoid ICAAN. We directly navigated the microcatheter into the aneurysm using a microguidewire in all patients. By careful navigation, the risk is low, navigation time is short, and the tip of the microcatheter can be stabilized at a position sufficiently inside the aneurysmal dome. Moreover, the stability of the microcatheter during coil insertion is satisfactory, and even in the event of kickback during coil insertion, its deviation from the aneurysm can be prevented, and it is spontaneously repositioned in the aneurysm due to having a support point on the vascular wall on the opposite side of the aneurysmal neck. During procedure, the tip of the microcatheter remained in the aneurysm and did not completely deviate. For this reason, in this series, we used balloons simply to prevent the protrusion of coils out of the aneurysm, and they were used for approximately 35% of the patients, excluding standby use. In addition, complete occlusion was achieved in 73% of the patients immediately after coil embolization, suggesting

an improvement in the packing rate due to improved stability of the microcatheter. In the above report by Kwon et al.,<sup>1)</sup> balloons were used for 54% of the patients who were treated for medially-directed paraclinoid ICAAN even when using the pigtail-shaped catheters that they devised, and the rate of complete occlusion was 53%, being slightly lower than that in our series.

On observation of the microcatheters removed after procedure, they exhibited a wide variety of 3D shapes (**Fig. 5B** and **5C**), probably due to the change in shape to adjust to the shape of the vessel in individual patients during procedure. As the microcatheter shape that we devised was 2D and had extra length, there was a high degree of flexibility in microcatheter shape, which was considered to have enabled the microcatheters to fit themselves to the shape of the vessels. There are also points of caution about catheter shaping. Heat shaping is the usual method for catheter shaping, and steam shaping and heat guns are frequently used in Japan. According to the results of microscopic examination of the tips of heat-shaped microcatheters by Adachi et al.,<sup>6)</sup> heat may have the possibility of damage or slight shortening of the microcatheter tip. Further accumulation of cases is necessary. We used injection needle caps, which were objects at hand, but other objects with similar shapes may also be used.

## Conclusion

Microcatheter shaping using a pigtail-shaped mandrel prepared by an injection needle cap is an easy and reproducible method. By 2D shaping of microcatheters with an elongated tip curvature, the freedom of setting support points of the microcatheter on the vascular wall is improved,

and the stability of the microcatheter is increased by fixing it on the vascular wall on the opposite side of the aneurysmal neck and at the carotid siphon. Therefore, stable coil embolization is possible until the end of the procedure. This shaping method is applicable to a wide range of medially-directed paraclinoid ICAAN and is highly useful.

## Disclosure Statement

The first author and all coauthors have no conflicts of interest to declare.

## References

- 1) Kwon BJ, Im SH, Park JC, et al: Shaping and navigating methods of microcatheters for endovascular treatment of paraclinoid aneurysms. *Neurosurgery* 2010; 67: 34–40.
- 2) Sorimachi T, Ito Y, Morita K, et al: Long-term follow-up of intra-aneurysmal coil embolization for unruptured paraclinoid aneurysms. *Neurol Res* 2012; 34: 864–870.
- 3) Wang Y, Li Y, Jiang C, et al: Endovascular treatment of paraclinoid aneurysms: 142 aneurysms in one centre. *J Neurointerv Surg* 2013; 5: 552–556.
- 4) Wang Y, Li Y, Jiang C, et al: Could the types of paraclinoid aneurysm be used as a criterion in choosing endovascular treatment? Neuro-radiologists' view. *Acta Neurochir (Wien)* 2013; 155: 2019–2027.
- 5) Ishibashi T, Takao H, Suzuki T, et al: Tailor-made shaping of microcatheters using three-dimensional printed vessel models for endovascular coil embolization. *Comput Biol Med* 2016; 77: 59–63.
- 6) Adachi A, Kobayashi E, Kado K, et al: The optimal conditions for microcatheter shaping. *J Neuroendovascular Ther* 2016; 10: 236–242.