



Cross-sectional Study

Diagnosis of acute nasal fractures using ultrasound and CT scan[☆]



Peyman Astaraki^a, Bahareh Baghchi^b, Maryam Ahadi^{c,*}

^a Department of Internal Medicine, School of Medicine, Lorestan University of Medical Sciences, Khorramabad, Iran

^b Department of Emergency Medicine, School of Medicine, Taleghani Hospital, Imam Reza Hospital, Kermanshah University of Medical Sciences, Kermanshah, Iran

^c Department of Emergency Medicine, School of Medicine, Lorestan University of Medical Sciences, Khorramabad, Iran

ARTICLE INFO

Keywords:

Ultrasound
CT scan
Radiography
Nasal fractures
Trauma

ABSTRACT

Objective: Nasal fractures need timely and accurate diagnosis for required treatment to prevent future deformities and unnecessary surgery. Radiography does not provide accurate finding in this case. The aim of this study is to evaluate diagnostic efficiency of ultrasound and CT scan for acute nasal fractures.

Methods: In this cross-sectional study included patients with nasal trauma referred to (XXX) from January 2020 to December 2020. Diagnostic ultrasound and CT scan was performed on all the patients and data obtained was stored in patient data collection forms along with their demographics. The data was statistically analyzed using SPSS v20.

Results: Of 32 patients included in our study, 4 (12.5%) were females and 28 (87.5%) were males. The mean age of the patients was 40.28 ± 16.9 years. The specificity and sensitivity of ultrasound was 100% and 83.33%. The accuracy of the test was 93.75%. The specificity, sensitivity and accuracy were 100%, 95% and 96.88%, respectively. Chi square test also showed that there were a significant association between nose fracture and both CT scan and ultrasound, $p < 0.001$.

Conclusion: Our study showed that both, ultrasound and CT scan are efficient for the diagnosis of nasal fractures in the patients. Further studies with greater sample size are required in this domain.

1. Introduction

Nasal fractures are one of the most common facial fractures due to trauma [1]. It is reported in 39% of maxillofacial fractures [2]. The most important causes of maxillofacial fractures are vehicle accidents, falls, injuries and sports injuries [1–3]. Nasal fractures are more common in men than women and its frequency is high among individuals aged 15–25 years and those above 60 years of age. Most common location of the fracture is middle-third and lower part of the nose [3,4].

Clinical examination is a diagnostic method in nasal trauma and X-rays are performed in legal cases. Furthermore, clinical examination can be difficult in the cases of haematoma and oedema [5]. Misdiagnosis can lead to secondary deformity and complications [6]. A study showed that radiology was negative 25% of patients with nasal fractures, requiring surgery [4]. Lee et al., reported that accuracy of radiography in detecting nasal fracture is 78.6% and Waters' view was false positive in 33% cases. Ultrasound has recently become a simple and non-invasive method in diagnosing different types of fractures that has been used in

a few studies to diagnose facial bone fractures [6]. There are many benefits to performing non-invasive procedures using ultrasound; because the ultrasound machine is cheaper, lighter, portable and easier to move than X-ray machines. Also, throughout the treatment period, ultrasound images show the stages of treatment [7].

In the present study, we decided to evaluate the results of comparing ultrasound and radiography in the diagnosis of nasal fractures, as well as the results of comparing ultrasound as a more accurate method of CT scan in diagnosing nasal fractures based on age and gender.

2. Methods

In this cross-sectional study, patients with nasal trauma, suspected of nasal fracture at (XXX) from January 2020 to December 2020 were enrolled. All the patients reported to the emergency department within 24 h of the trauma regardless of their gender and age, were included in the study. Written consent was obtained from all patients before participation of the study. Nasal trauma was confirmed through CT scan

[☆] This study was approved by the Research Ethics Board of Kermanshah University of Medical Sciences, Kermanshah, Iran (IR.KUMS.REC.1397.242). <https://ethics.research.ac.ir/ProposalCertificateEn.php?id=10930&Print=true&NoPrintHeader=true&NoPrintFooter=true&NoPrintPageBorder=true&LetterPrint=true>.

* Corresponding author. Emergency Medicine, Lorestan University of Medical Sciences, Khorramabad, Iran.

E-mail address: md.maryamahadi@gmail.com (M. Ahadi).

<https://doi.org/10.1016/j.amsu.2022.103860>

Received 10 April 2022; Received in revised form 21 May 2022; Accepted 22 May 2022

Available online 26 May 2022

2049-0801/© 2022 The Authors. Published by Elsevier Ltd on behalf of IJS Publishing Group Ltd. This is an open access article under the CC BY-NC-ND license (<http://creativecommons.org/licenses/by-nc-nd/4.0/>).

and ultrasound.

Patients with the history of nasal or facial trauma and fracture, rhinoplasty, bleeding disorders and those who did not consent to participate in the study were excluded.

After obtaining history and physical examination of patients by an emergency department physician, the results findings were recorded in the project data collection forms. Diagnostic ultrasound for patients in the emergency department was performed by ultrasound device (TOSHIBA-XAIRO 200) with a linear probe of 6–13 MHz. Ultrasound was performed in both axial and sagittal positions, and loss of bone continuity were considered as fractures on ultrasound. The patient's ultrasound was compared with a facial CT scan. The results of ultrasounds and CT scans were recorded in data collection forms and statistically evaluated. The radiologist did not know the results of the ultrasound and examination at the time of the X-ray. In this study, clinical examination and intraoperative findings are considered as gold-standard for the diagnosis of nasal fracture.

The data was statistically analyzed using SPSS v20 (I.B.M. For descriptive analysis, graphs, tables, sensitivity and specificity indices were used, and Cohen's kappa coefficient, non-parametric tests, comparison of means and chi-square test were used to obtain correlation between the variables. Significance level less than 0.05 was considered.

This study was approved by the Research Ethics Board of (XXX).

Unique identifying number is: researchregistry7799.

The study is stated in accordance with STROCSS 2021 guidelines [7].

3. Results

A total of 32 patients were included in our study where 4 (12.5%) were females and 28 (87.5%) were males. All the patients were aged more than 15 years and the mean age of the patients was 40.28 ± 16.9 years.

Results of ultrasound showed that 10 (31.3%) patients were negative for fracture and 22 (68.8%) were positive. CT scan showed that 13 (40.6%) patients were negative and 19 (59.4%) were positive for fracture.

For comparing the accuracy of CT scan and Sonography for detecting nose fracture (FX), we used Accuracy score implemented in Scikit-learn software (Fig. 1). The specificity and sensitivity of ultrasound was 100% and 83.33%. The accuracy of the test was 93.75%. The specificity, sensitivity and accuracy were 100%, 95% and 96.88%, respectively.

Chi square test also showed that there were a significant association between nose fracture and both CT scan and ultrasound, $p < 0.001$.

4. Discussion

Diagnosis of nasal fractures using imaging modalities is important to prevent future complications such as deformities and chronic fractures.

Radiography is common for the assessment of nasal injuries however, locating sidewall injuries can be challenging through radiography [8,9]. Sensitivity of radiography in detecting nasal line fracture is up to 79% only [10]. Early 6-year study by Hwang et al. on 503 patients indicated that CT scan is necessary for the diagnosis of nasal fracture [11]. CT scan also may not be effective due to partial volume effect and the cases of depressed nasal fractures can be evaluated easily with conventional lateral view radiography [8].

A retrospective study by Lee et al., compared high resolution ultrasound and CT scan for the diagnosis nasal fractures in 140 patients using 15-7 MHz sonogram probe, CT scan and conventional radiography. The sensitivity, specificity and accuracy of radiograph was 78.3%, 100% and 78.6%, respectively. The accuracy of high-resolution ultrasonography was 100% in the study. Compared to this, CT scan showed sensitivity, specificity and accuracy of 84%, 67% and 80%, respectively. The confirmed diagnosis was made using clinical examination and intraoperative findings [12]. A cross-sectional study on 40 patients with mid-facial fractures by Javadrashid et al., comparing the CT scan and ultrasound showed that among 39 patients with fracture, CT scan reported 24 positive patients. The sensitivity and specificity of ultrasound relative to CT scan was 94.9% and 100%, respectively. There was no significant difference among the two imaging modalities for the diagnosis of nasal fracture [13]. Sook Lee et al. compared the diagnostic efficiency of CT scan, ultrasonography and radiography among 41 patients with nasal bone fractures in comparative study. Overall, CT scan had the greatest sensitivity and specificity compared to other two imaging modalities. For midline nasal bone fracture, ultrasound has highest specificity and positive and negative predicative value. Ultrasound performed using hockey-stick probe was most closely in agreement to the intraoperative findings [12]. These studies suggest that the type and location of nasal fracture may be associated with the imaging modality used.

Our study has a small sample size and we have not presented that data regarding the type and location of nasal fracture which might be associated with the different outcomes. With these limitations, our study show that ultrasound and CT scan can provided significant findings for the presence of nasal fracture following trauma.

5. Conclusion

For comparing the accuracy of CT scan and Sonography for detecting nose fracture (FX), we used accuracy score implemented in Scikit-learn software. This program showed that the accuracy of CT scan is a bit more than sonography, but still sonography is a reliable detection method. We also showed a significant association between nose fracture and both CT scan and Sonography.

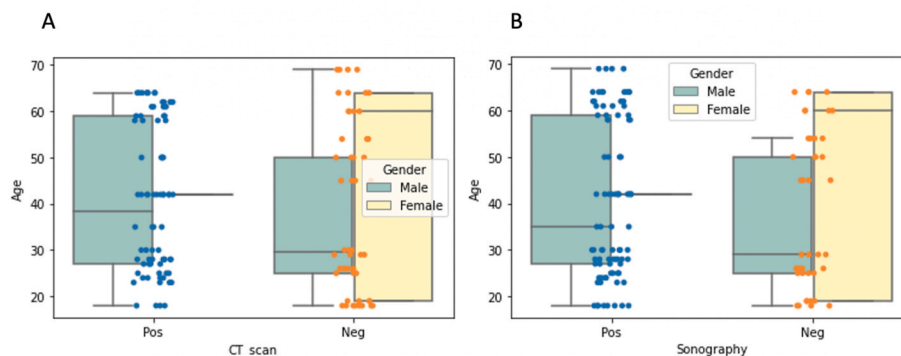


Fig. 1. Boxplot showing the number of cases detected by (A) CT scan and Sonography (B) grouped by negative and positive results. Dots colored in blue and orange showing positive and negative cases scaled by age. (For interpretation of the references to color in this figure legend, the reader is referred to the Web version of this article.)

Provenance and peer review

Not commissioned, externally peer-reviewed.

Ethical approval

All procedures performed in this study involving human participants were in accordance with the ethical standards of the institutional and/or national research committee and with the 1964 Helsinki Declaration and its later amendments or comparable ethical standards.

Please state any sources of funding for your research

No funding was secured for this study.

Author contribution

Dr. Peyman Astaraki: conceptualized and designed the study, drafted the initial manuscript, and reviewed and revised the manuscript. Dr. Bahareh Baghchi: Designed the data collection instruments, collected data, carried out the initial analyses, and reviewed and revised the manuscript. Dr. Maryam Ahadi: Coordinated and supervised data collection, and critically reviewed the manuscript for important intellectual content.

Registration of research studies

Name of the registry: N/a

Unique Identifying number or registration ID: IR.KUMS.REC.1397.242

Hyperlink to the registration (must be publicly accessible):

<https://ethics.research.ac.ir/ProposalCertificateEn.php?id=10930&Print=true&NoPrintHeader=true&NoPrintFooter=true&NoPrintPageBorder=true&LetterPrint=true>.

Consent

Not applicable.

Guarantor

Dr. Maryam Ahadi.

Consent to participate

From the under 16 years old was given by a parent or legal guardian.

Consent for publication

Not applicable.

Availability of data and material

Data sharing is not applicable to this article as no datasets were

generated or analyzed during the current study.

Funding source

No funding was secured for this study.

Contributors' Statement Page

Dr. Peyman Astaraki: conceptualized and designed the study, drafted the initial manuscript, and reviewed and revised the manuscript. Dr. Bahareh Baghchi: Designed the data collection instruments, collected data, carried out the initial analyses, and reviewed and revised the manuscript. Dr. Maryam Ahadi: Coordinated and supervised data collection, and critically reviewed the manuscript for important intellectual content.

Declaration of competing interest

The authors deny any conflict of interest in any terms or by any means during the study. All the fees provided by research center fund and deployed accordingly.

Appendix A. Supplementary data

Supplementary data to this article can be found online at <https://doi.org/10.1016/j.amsu.2022.103860>.

References

- [1] S. Samieirad, E. Tohidi, A. Shahidi-Payam, M.-A. Hashemipour, A. Abedini, Retrospective study maxillofacial fractures epidemiology and treatment plans in Southeast of Iran, *Med. Oral Patol. Oral Cir. Bucal* 20 (6) (2015) e729–e736.
- [2] A. Alvi, T. Doherty, G. Lewen, Facial fractures and concomitant injuries in trauma patients, *Laryngoscope* 113 (1) (2003) 102–106.
- [3] N. Basheeth, M. Donnelly, S. David, S. Munish, Acute nasal fracture management: a prospective study and literature review, *Laryngoscope* 125 (12) (2015) 2677–2684.
- [4] S. Atighechi, M.H. Baradaranfar, G. Karimi, M.H. Dadgarnia, H.R. Mansoorian, N. Barkhordari, et al., Diagnostic value of ultrasonography in the diagnosis of nasal fractures, *J. Craniofac. Surg.* 25 (1) (2014).
- [5] C. Rebours, R. Glatre, P. Plaisance, A. Dohan, J. Truchot, A. Chauvin, Diagnostic errors of nasal fractures in the emergency department: a monocentric retrospective study, *World J Emerg Med* 13 (2) (2022) 120–123.
- [6] S.X. Dong, N. Shah, A. Gupta, Epidemiology of nasal bone fractures, *Facial Plast Surg Aesthet Med* 24 (1) (2022) 27–33.
- [7] G. Mathew, R. Agha, Strocck 2021: Strengthening the reporting of cohort, cross-sectional and case-control studies in surgery, *Int. J. Surg.* 96 (2021) 106165.
- [8] H.S. Hong, J.G. Cha, S.H. Paik, S.J. Park, J.S. Park, D.H. Kim, et al., High-resolution sonography for nasal fracture in children, *AJR Am. J. Roentgenol.* 188 (1) (2007) W86–W92.
- [9] A. Nigam, A. Goni, A. Benjamin, A.R. Dasgupta, The value of radiographs in the management of the fractured nose, *Arch. Emerg. Med.* 10 (4) (1993) 293–297.
- [10] A. Mohammadi, M. Ghasemi-Rad, Nasal bone fracture—ultrasonography or computed tomography? *Med Ultrason* 13 (4) (2011) 292–295.
- [11] K. Hwang, S.H. You, S.G. Kim, S.I. Lee, Analysis of nasal bone fractures; a six-year study of 503 patients, *J. Craniofac. Surg.* 17 (2) (2006) 261–264.
- [12] M.H. Lee, J.G. Cha, H.S. Hong, J.S. Lee, S.J. Park, S.H. Paik, et al., Comparison of high-resolution ultrasonography and computed tomography in the diagnosis of nasal fractures, *J. Ultrasound Med.* 28 (6) (2009) 717–723.
- [13] R. Javadrashid, M. Khatoonabad, N. Shams, F. Esmaeili, H. Jabbari Khamnei, Comparison of ultrasonography with computed tomography in the diagnosis of nasal bone fractures, *Dentomaxillofacial Radiol.* 40 (8) (2011) 486–491.