

IMAGING VIGNETTE

ADVANCED

CLINICAL VIGNETTE

Combination of Double Chimney Technique and Prosthesis Post-Dilation After Valve-in-Valve Implantation



Alfredo Fede, MD,^a Michele Romano, MD,^a Francesca Buffoli, MD,^a Nicola Camurri, MD,^b Corrado Lettieri, MD^a

ABSTRACT

Valve-in-valve (ViV) transcatheter aortic valve implantation (TAVI) is an effective treatment for aortic bioprosthetic valve degeneration. ViV-TAVI could lead to coronary occlusion. We describe the case of a patient treated with double chimney technique to protect coronary ostia followed by post-dilation for high residual transvalvular gradient using "three-kissing balloon" approach. (**Level of Difficulty: Advanced.**) (J Am Coll Cardiol Case Rep 2020;2:2173-5)

© 2020 The Authors. Published by Elsevier on behalf of the American College of Cardiology Foundation. This is an open access article under the CC BY-NC-ND license (<http://creativecommons.org/licenses/by-nc-nd/4.0/>).

We report a case of valve-in-valve transcatheter aortic valve implantation (ViV-TAVI) for aortic valve bioprosthesis degeneration with high residual transvalvular gradient requiring both protection of coronary ostia and post-expansion of the prosthesis in an 83-year-old woman. She was admitted for dyspnea (New York Heart Association functional class III to IV) in March 2019. Eight years earlier, she underwent surgical aortic valve replacement with a 21-mm Mitroflow bioprosthesis (Sorin Group USA Inc., Arvada, Colorado) with a postprocedural mean gradient of 20 mm Hg. Echocardiography examination showed bioprosthesis degeneration with severe stenosis (aortic valve area 0.7 cm², mean ΔP 51 mm Hg) and insufficiency with normal left ventricular function.

Angiographic examination revealed no coronary artery stenosis, low take off of coronary arteries, and severe aortic regurgitation (Video 1). Computed tomography scans showed a virtual transcatheter valve-to-coronary ostia distance of 4.9 and 4.2 mm from the right and the left coronary ostium, respectively, and a low take of coronary ostia (10 mm) (Figure 1A).

Due to the high risk of reintervention and coronary occlusion, a ViV-TAVI in combination with coronary stent implantation on both coronary ostia was planned.

Two zotarolimus drug-eluting stents (4 × 22 mm) were positioned in left main and proximal right coronary artery with protrusion of about two-thirds of the stent's length in the aortic root to cover the highest portion of the Mitroflow leaflets (Figures 1B and 1C). While maintaining stents in position, through right common femoral artery a 23-mm Medtronic Evolut-R valve (Medtronic, Inc., Minneapolis, Minnesota) was advanced across the surgical bioprosthesis and completely unscrewed after the deployment of both stents (Figure 1D, Videos 2 and 3).

A mean 45 mm Hg residual transprosthetic peak gradient was measured; a post-dilation with 20-mm balloon was performed with a final peak gradient of 20 mm Hg and no paravalvular leak. To prevent crushing of the stents during valve post-dilation, combined simultaneous inflation of balloons of the stents was performed with patency of coronary ostia (Figure 1E and 1F, Videos 4 and 5).

From the ^aDivision of Cardiology, Carlo Poma Hospital, ASST Mantova, Italy; and the ^bDivision of Cardiac Surgery, Carlo Poma Hospital, ASST Mantova, Italy.

The authors attest they are in compliance with human studies committees and animal welfare regulations of the authors' institutions and Food and Drug Administration guidelines, including patient consent where appropriate. For more information, visit the *JACC: Case Reports* [author instructions page](#).

Manuscript received April 28, 2020; revised manuscript received August 11, 2020, accepted August 14, 2020.

**ABBREVIATIONS
AND ACRONYMS**

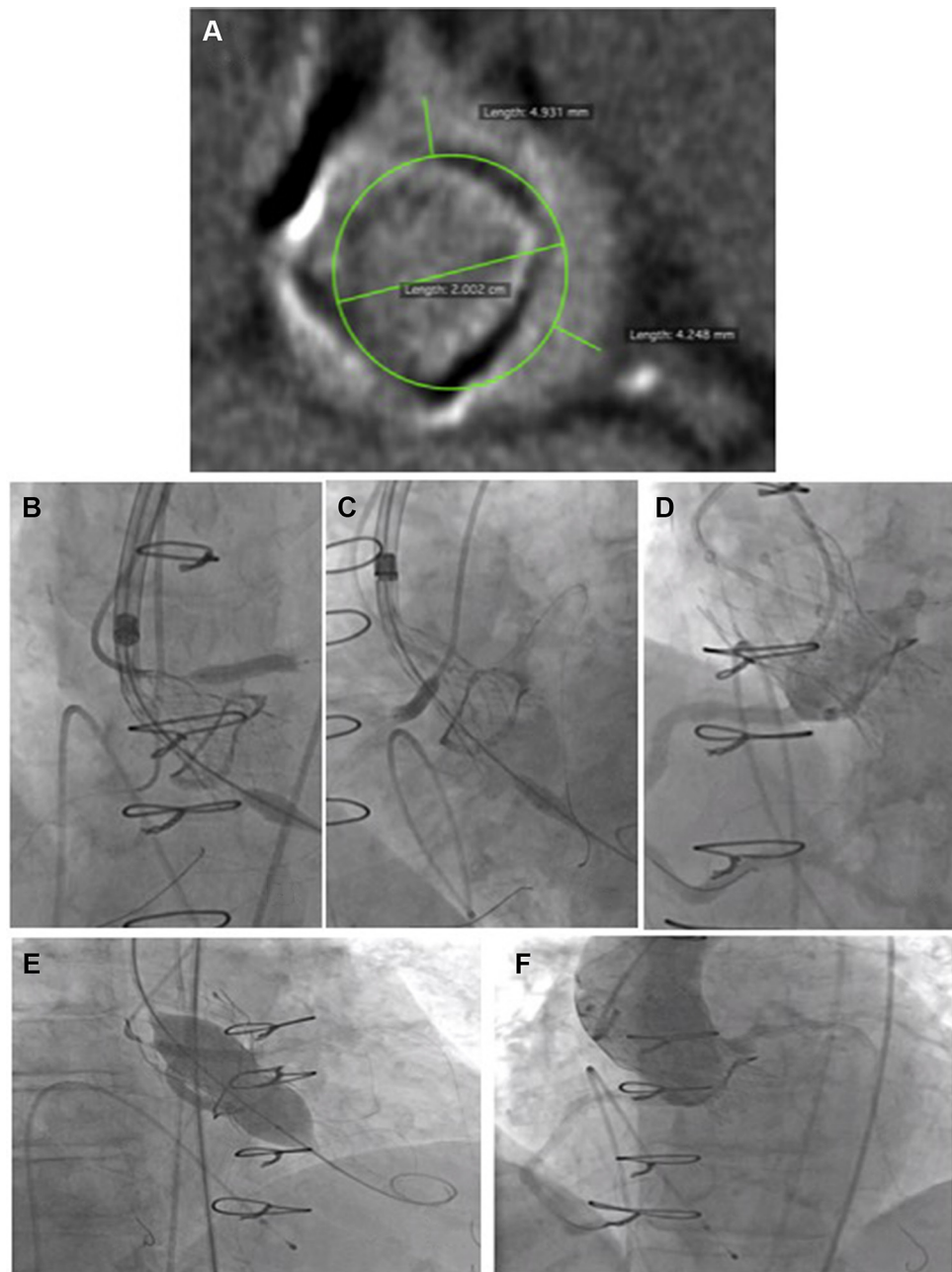
TAVI = transcatheter aortic valve implantation

VIV = valve-in-valve

The patient was discharged without symptoms with a mean residual transvalvular gradient of 15 mm Hg. No adverse events were reported at 1-year follow-up.

Coronary obstruction is a life-threatening complication that could occur during ViV-TAVI procedure performed in degenerated surgical bioprosthesis, especially if associated with narrow sinotubular junction, narrow sinuses of Valsalva, valve-to-coronary ostia distance <4 mm, or coronary

FIGURE 1 The “Double” Chimney and “Three-Kissing Balloon” Techniques



(A) Virtual transcatheter valve-to-coronary ostia distance measured during computed tomography. **(B and C)** Deployment of left main and right coronary artery stents. **(D)** Angiographic appearance of fully deployed Evolut R (Medtronic) 23 mm with coronary patency. **(E)** Simultaneous valve and stents post-dilation. **(F)** Final angiographic result.

height <12 mm. Moreover, this risk is further increased when high gradients residues after ViV-TAVI and post-dilatation is necessary (1).

Different approaches to facilitate the ViV-TAVI procedure while preventing coronary occlusion and high residual transvalvular gradient, such as Basilica, bioprosthetic valve fracture, and chimney snorkel techniques, have been previously reported (2,3). However, to date, the application of preventive ostial coronary protection combined with post-dilatation of the new implanted valve for high residual transvalvular gradient has not been described.

To plan an effective procedure, it is important to perform a careful pre-procedural multimodal imaging assessment. In addition, the maintenance of the balloons from deployed stents after the release of the transcatheter valve is crucial to prevent coronary obstruction. Finally, if post-expansion of the prosthesis is required, the “three-kissing balloon” technique can be successfully adopted to prevent crushing of the coronary stents.

AUTHOR DISCLOSURES

The authors have reported that they have no relationships relevant to the contents of this paper to disclose.

ADDRESS FOR CORRESPONDENCE: Dr. Alfredo Fede, Division of Cardiology, Carlo Poma Hospital, ASST Mantova, Str. Lago Paiolo 10, 46100 Mantova, Italy. E-mail: alfredo.fede@yahoo.it OR alfredo.fede@asst-mantova.it.

REFERENCES

1. Webb JG, Mack MJ, White JM, et al. Transcatheter aortic valve implantation within degenerated aortic surgical bioprostheses: PARTNER 2 valve-in-valve registry. *J Am Coll Cardiol* 2017; 69:2253–62.
2. Maggio S, Gambaro A, Scarsini R, Ribichini F. Preventive left main and right coronary artery stenting to avoid coronary ostia occlusion in high-risk stentless valve-in-valve transcatheter aortic valve implantation. *Interact Cardiovasc Thorac Surg* 2017;25: 147–9.
3. Nielsen-Kudsk JE, Christiansen EH, Terkelsen CJ, et al. Fracturing the ring of small Mitroflow bioprostheses by high-pressure balloon predilatation in transcatheter aortic valve-in-valve implantation. *Circ Cardiovasc Interv* 2015;8: e002667.

KEY WORDS aortic valve, percutaneous coronary intervention, valve replacement

APPENDIX For supplemental videos, please see the online version of this paper.