

# The detection and upgrade rates of prostate adenocarcinoma following transperineal template-guided prostate biopsy – a tertiary referral centre experience

David Muthuveloe<sup>1</sup>, Robert Telford<sup>1</sup>, Richard Viney<sup>2</sup>, Prashant Patel<sup>1</sup>

<sup>1</sup>University of Birmingham, School of Cancer Sciences, United Kingdom

<sup>2</sup>Queen Elizabeth Hospital, Department of Urology, Birmingham, United Kingdom

**Citation:** Muthuveloe D, Telford R, Viney R, Patel P. The detection and upgrade rates of prostate adenocarcinoma following transperineal template-guided prostate biopsy – a tertiary referral centre experience. Cent European J Urol. 2016; 69: 42-47.

## Article history

Submitted: July 22, 2015

Accepted: Nov. 22, 2015

Published online: Feb. 2, 2016

## Corresponding author

David Muthuveloe

School of Cancer Sciences

University of Birmingham

B15 2TT Birmingham, UK

phone: +44 7813821236

david.muthuveloe@

gmail.com

**Introduction** We aim to present transperineal template-guided prostate biopsy (template biopsy) outcomes at a tertiary referral centre. Furthermore, to identify the detection rate of prostate cancer in those with a previous negative transrectal ultrasound guided prostate biopsy and the upgrade rate of those on active surveillance for Gleason 3 + 3 = 6 prostate adenocarcinoma.

**Material and methods** We conducted a prospective study of 200 consecutive men who underwent template biopsy over a 22-month period in a tertiary referral centre, using a standard 24 region template prostate biopsy technique. Indications and histology results, as well as complications, were recorded.

**Results** Median age was 67 years and median PSA was 10 ng/mL. Overall detection rate was 47%. 39.5% of cases with previous negative transrectal biopsies were found to have prostate adenocarcinoma. 47.5% of cases on active surveillance for Gleason 3 + 3 = 6 prostate adenocarcinoma were upgraded. The most frequent complication was acute urinary retention at a rate of 12.5%, however, the use of a single prophylactic dose of tamsulosin was found to be beneficial, with 13 cases needed to treat to prevent one episode.

**Conclusions** Template biopsies are safe and efficacious with an overall detection rate of 47% in the present series. Due to the high detection rate, one must consider template biopsy following one negative transrectal biopsy where there is persistent clinical suspicion. Furthermore, those considering active surveillance for Gleason 3 + 3 = 6 disease should be offered template biopsy to confirm the grade of their disease.

**Key Words:** prostate adenocarcinoma <> prostate biopsy <> prostate cancer <> template biopsy <> transperineal biopsy

## INTRODUCTION

Prostate cancer is the most frequently diagnosed solid organ cancer in men and is the second most common cause of cancer death [1]. PSA screening and testing has been shown to reduce mortality from prostate cancer and increase life expectancy [2]. However, this has caused a tendency towards over-detection of low risk prostate cancer and, as a result, treatment of both indolent and aggressive prostate cancer [3]. Radical treatment is associated with sig-

nificant morbidity, predominantly with incontinence and erectile dysfunction [2]; as such, it is vital that patients are accurately staged and appropriately counselled before making their treatment decision. Currently, investigations for those with elevated PSA revolve around transrectal ultrasound guided prostate biopsies. This involves taking 12 biopsy cores in a systematic approach as supported by AUA and EAU guidelines [4, 5]. Transrectal biopsies are done in outpatient clinics under local anaesthesia. It is usually well tolerated but does have limitations.

Infection is of some concern despite the administration of prophylactic antibiotics. This is due to the risk of seeding intestinal flora into the prostate and the limited antibiotic penetration of prostatic tissue. The risk of major infection has been reported as high as 5.5% in some studies [6].

Another limitation is the relatively high proportion of false negative results that occur with transrectal biopsies, having been shown to miss up to 30% of prostate cancers [7]. Even if prostate cancer is detected on transrectal biopsy, a significant proportion is upgraded after template biopsy or after histological analysis of the radical prostatectomy specimen [8, 9]. This is due to the complex, heterogeneous and multifocal nature of prostate cancer, as well as the challenging aspect of sampling the anterior part of the prostate transrectally. As a result, there may be a proportion of patients who have been falsely reassured by being diagnosed with low-grade disease and thus chose their treatment based on incomplete information.

Transperineal template-guided prostate biopsies (template biopsies) have been shown to overcome

some of these limitations. Firstly, the rate of major sepsis has been reported at 0.2% [10]. This is likely due to the avoidance of intestinal flora when taking the biopsies. In addition, template biopsies have a greater detection rate than transrectal biopsies [8]. This is due to the greater number of biopsy cores taken, and due to the fact that the anterior portion of the gland is accessed and biopsied with greater certainty. As a result, the risk of missing small significant anterior cancers is reduced. Subsequently, the rate of detection of template biopsies in those who have previously had a negative transrectal biopsy has been reported to be as much as 39% [11]. This study aims to evaluate the use of transperineal template-guided prostate biopsy presently in use at our unit. We also aim to investigate the detection rate of prostate cancer in those with previously negative transrectal biopsies and the upgrade rate of those on active surveillance for Gleason 3 + 3 = 6 prostate adenocarcinoma following transperineal template-guided prostate biopsy.

## MATERIAL AND METHODS

All data from patients having undergone a transperineal template-guided prostate biopsy were prospectively collected over a 22-month period. The majority of patients had multifunctional prostate MRI scans prior to their template biopsy. These scans were performed and reported in a manner consistent with the standards and recommendations approved by a European Consensus Meeting [12] using the 'prostate imaging reporting and data system' (PIRADS) score (Table 1) [13]. Patients who had previously received brachytherapy or had undergone template biopsies for anorectal abnormalities were excluded. Patients were consented as per standard local practice. Case notes and electronic databases were reviewed retrospectively. Demographic data was collected. Previous transrectal biopsy results were compared to template biopsy results. Complications were also recorded and analyzed.

### Transperineal template biopsy technique

Transperineal template-guided prostate biopsies were performed as ambulatory day-case surgery under general anaesthesia by a consultant urologist. Patients were given prophylactic antibiotics (gentamicin 240 mg intravenously and metronidazole 500 mg rectally) at induction of anaesthesia and placed in the dorsal lithotomy position. The perineum was prepared with 5% chlorhexidine. No catheter was inserted. Using transrectal ultrasound guidance, the prostate was localized in transverse and

**Table 1.** PI-RADS score as adapted from the ESUR MR guidelines 2012

PI-RADS Score	The likelihood of clinically significant prostate cancer
1	Highly unlikely
2	Unlikely
3	Equivocal
4	Likely
5	Highly likely

**Table 2.** Comparison of subjects with positive transperineal template biopsies with those with negative transperineal template biopsies (excluding the cases on active surveillance and those post-radiotherapy)

	Positive template biopsy n=71	Negative template biopsy n=103
Median age/ years (range)	68 (46–81)	65 (47–78)
Median PSA ng/mL (range)	11.5 (1.2–92.5)	10 (2.7–61)
Median number of previous biopsies (range)	2 (1–5)	2 (1–7)
MRI result		
PIRADS 1	33%	44%
PIRADS 2	20%	22%
PIRADS 3	20%	24%
PIRADS 4	20%	10%
PIRADS 5	6%	1%

sagittal planes. Multiple transperineal prostatic biopsy cores were taken in a systematic fashion using a 5 mm brachytherapy template grid as previously described [14]. The total number of cores varied with the size of the prostate; however, a minimum of 24 named sectors were biopsied. Four regions were sampled anteriorly and four regions were sampled posteriorly from each of 3 transverse planes (Figure 1). If the prostate was found to have a large volume and further sampling was needed, then further regions were sampled from a fourth transverse plane at the surgeon's discretion. Specimens were labelled according to biopsy location and sent for analysis by a uropathologist. Finally, local anaesthetic was administered into the perineal and subcutaneous tissue. Following the procedure, patients were discharged to complete a 3-day course of ciprofloxacin.

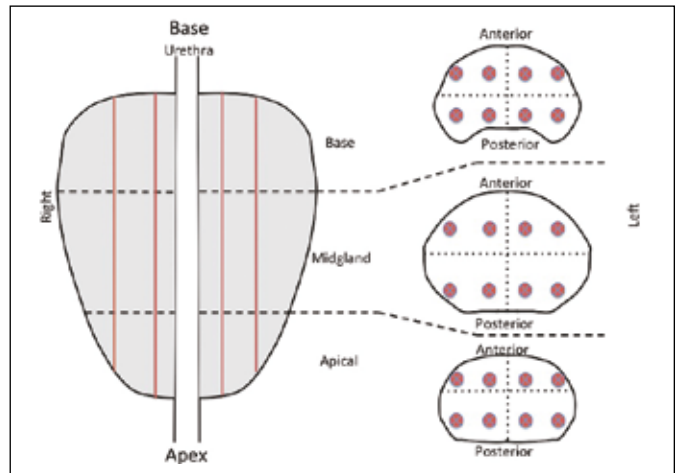
## RESULTS

We analyzed 200 cases that met our criteria between March 2013 and December 2014. Median age was 67 years (41–81). Median PSA was 10 (0.79–92.5). Median number of sectors biopsied was 24 (24–28). Indications for template biopsies are listed in Figure 2. A comparison between patients with positive template biopsy results and negative template biopsy results is presented on Table 2 (excluding those on active surveillance and those post-radiotherapy). There is no significant difference between demographic data; however, the MRI results indicate that a positive template biopsy is associated with a significantly greater PIRADS score than negative template biopsies ( $p < 0.05$ ).

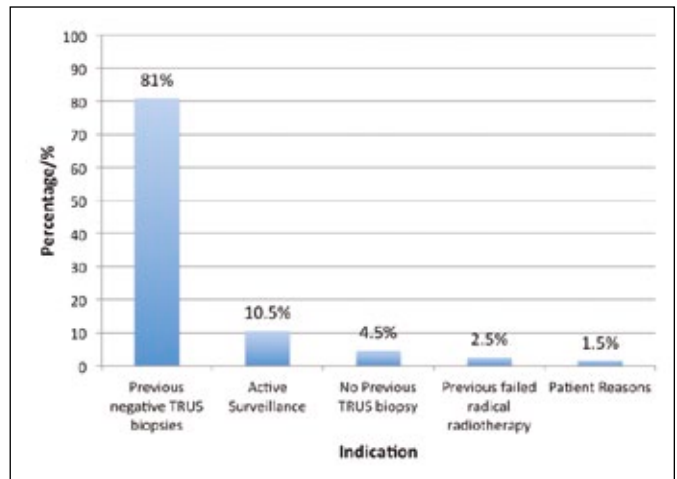
Overall, 47% of cases were found to have prostate cancer on template biopsy, of which Gleason 3 + 3 = 6 was most commonly identified (Figure 3). In those with previous negative transrectal biopsies, the majority had either one or two previous transrectal biopsies (Figure 4). Overall, 39.5% of cases with previous negative transrectal biopsies were subsequently found to have prostate cancer on template biopsy. This shows that transrectal biopsy had a 39.5% false negative rate when compared to template biopsies. This figure was maintained regardless of whether patients had undergone one, two or three negative transrectal biopsies (Figure 5).

47.5% of cases on active surveillance for Gleason 3 + 3 = 6 prostate cancer were upgraded following template biopsy (Figure 6).

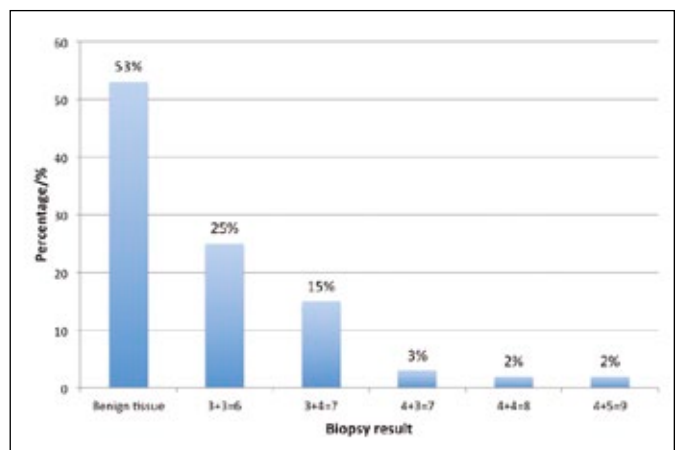
The rate of acute urinary retention (AUR) was found to be 12.5%. Haematuria and sepsis requiring admission were uncommon and occurred in 1% and 0.5% of cases respectively.



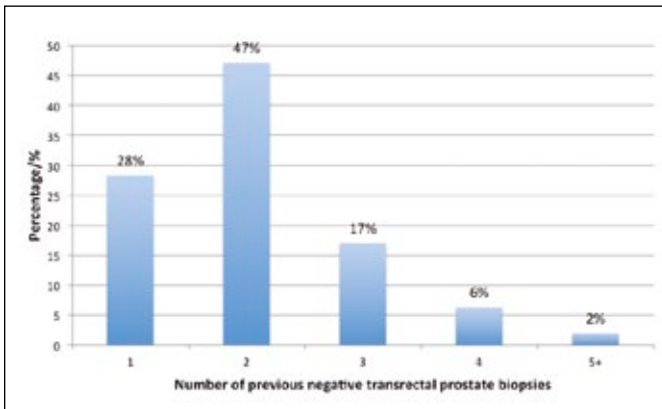
**Figure 1.** Schematic of the prostate identifying the three transverse planes and the four sagittal planes that make up the 24 named sectors that are biopsied.



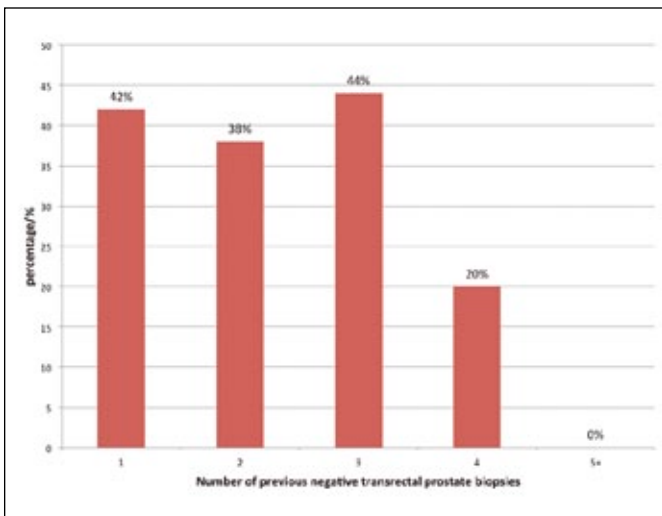
**Figure 2.** Indications of transperineal template-guided prostate biopsy.



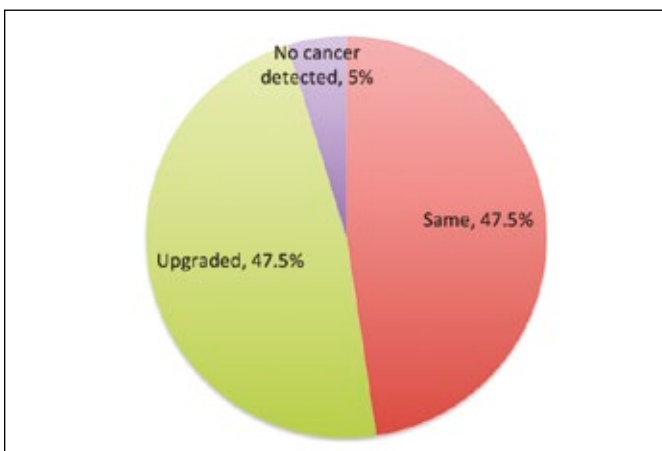
**Figure 3.** Transperineal template-guided prostate biopsy histology results.



**Figure 4.** The number of previous negative transrectal ultrasound guided biopsies.



**Figure 5.** Prostate cancer detection rate using transperineal template-guided prostate biopsies in those with previous negative transrectal prostate biopsies.



**Figure 6.** Prostate cancer upgrade rate following transperineal template-guided prostate biopsies in those with Gleason 3 + 3 = 6 prostate adenocarcinoma on active surveillance.

59 patients were given a single prophylactic dose of tamsulosin 400 mcg perioperatively. There was no significant difference in case mix between those who took tamsulosin and those who did not. The risk of AUR in those using a single prophylactic dose of tamsulosin was lower at 5.3%. The relative risk of developing retention without tamsulosin was 2.5. Therefore, the numbers needed to treat (NNT) to prevent one episode of retention was found to be 13.

## DISCUSSION

The majority of patients undergoing the template biopsies had previous negative transrectal biopsies but persistently elevated PSA and/or abnormal MRI prostate findings (Figure 2). Hodge et al. described the original sextant transrectal biopsies [15], which have been found to have a false negative result of up to 33% [9]. Our study supports this with transrectal biopsies having a 39.5% false negative rate compared to template biopsy. The greater detection rate of template biopsies is probably due to three main reasons. It makes logical sense that increasing the number of cores taken at the time of biopsy would increase the detection rate [16]. Template biopsies take a minimum of 24 cores, whereas standard transrectal biopsies require 12 cores. Another reason is the ease and greater certainty of sampling the anterior prostate using template biopsies. Approximately 1 in 5 patients with prostate cancer have anterior prostate involvement [17], and in those patients with previous negative transrectal biopsies the anterior region is found to have the greatest density of prostate cancer [18]. As a result, template biopsies are more likely to detect anteriorly located cancer. Our study shows that out of the cases that were found to have prostate cancer on template biopsy after negative transrectal biopsies, 83% of patients overall had anterior prostate cancers. Of those 44% were only located anteriorly and 39% were located both anteriorly and posteriorly. The final reason why template biopsies have a greater detection rate compared to transrectal biopsies, is due to the targeting that can be achieved using pre-template biopsy MRI scans. Almost all cases (95.5%) had a pre-template biopsy MRI scan. This means that any named sector within the prostate, with an abnormality observed on MRI, can be targeted and more cores can be taken from that location to help achieve a more accurate diagnosis. This helps reduce the false negative rates compared to transrectal biopsies.

It was also shown that the detection rate from template biopsies was maintained at a level of approximately 39.5%, regardless of whether patients had undergone one, two or three previous negative tran-



rectal biopsies (Figure 5). We therefore recommend considering a template biopsy after one negative transrectal biopsy in patients with clinical suspicion. A proportion of patients had template biopsies as part of the monitoring for active surveillance for Gleason 3 + 3 = 6 prostate cancer. We found that 47.5% of these cases were upgraded following template biopsies (Figure 6). This is supported by another study by Caster et al, which showed that the upgrade rate of those with biopsy proven Gleason 6 prostate cancer, with a PSA <10, was as much as 43% when compared to the radical prostatectomy specimen [19]. As a result we suggest that template biopsies should be considered before recommending active surveillance, or should be included as part of the active surveillance regime, rather than standard transrectal biopsies. It must be remembered, however, that this upgrade rate could be explained by the fact that the cohort of patients we have sampled are selected. According to current guidelines the active surveillance protocol requires PSA tests every 3–6 months, digital rectal examination every 6–12 months and a repeat transrectal biopsy a year after diagnosis, then every few years [20]. Currently template biopsies are not routinely performed as part of the active surveillance regime. This means that the referring clinician considered these cases to be suspicious. In addition, MRI scans had been performed on this cohort of patients. This means that the referring clinician also must have come to the conclusion, based on the MRI result, that repeat transrectal biopsies were unlikely to detect the abnormality in question, so template biopsies were ordered. This is likely to skew the results and may explain the high upgrade rate; however, the results are consistent with previously published data, which showed that the upgrade for active surveillance could be as much as 38–67.6% [21, 22].

The rate of AUR was found to be as much as 12.5%. This is significantly greater than the risk of AUR with transrectal biopsies, which in a systematic review was reported as 1.7% [23]. One reason for this increase is due to the greater number of cores taken at template biopsy. A study by Pepe et al. looked into complication rates of 3000 patients who underwent 12 vs. 18 vs. 24 core template biopsies [24]. It showed that the risk of AUR increased by 4.1%, 7.1% and 11.1% respectively. As a result, the number of cores taken has a direct correlation with the rate of AUR. Although there is no actual evidence, we believe this is probably due to the increased swelling and oedema that is caused by the increased core numbers. Furthermore, with swelling of the anterior part of the prostate being present with template biopsies, there is greater likelihood of concentric compression of the prostatic urethra. This swelling then causes temporary retention that usually resolved

once the prostate has had time to recover. As a result the overall AUR rate of 12.5% seems to be consistent with the previously published data of 11.1% [24].

Prostate gland size has also been shown to predict the rate of retention. Buskirk et al. [25] showed that there was a correlation between gland size and the likelihood of going into AUR following template biopsies. Subjects with a gland size of <50 mL exhibited an AUR rate of 4%, whereas those with a gland size of >50 mL had an AUR rate of 20% ( $p = 0.039$ ) [25].

We found that the use of a single dose of tamsulosin 400 mcg at the time of template biopsy significantly reduced the rate of AUR, with an NNT score of 13 to prevent one episode of retention. The use of tamsulosin has already been shown to help improve International Prostate Symptom Scores (IPSS) and maximum flow rates in transrectal biopsies in a randomized prospective study [26]. Our data shows that a single dose can also be used to help reduce the rate of AUR in template biopsies and so improve morbidity.

Another indication for the use of template biopsies is to provide evidence of unifocal disease. If this is the case, then the patient can be considered for focal therapy [3]. Due to the complex, heterogeneous and multifocal nature of prostate cancer, focal therapy relies on accurate patient selection. As a result, template biopsies offer an excellent approach for selecting suitable patients. However, according to the National Institute of Clinical Excellence (NICE) guidelines [27] and the European Association of Urologists (EAU) guidelines [28], cryotherapy can only be offered in those who are unsuitable for surgery or radiotherapy, furthermore high-intensity-focused ultrasound (HIFU) should only be offered as part of a trial. Consequently, our unit did not look into this indication for template biopsies and further studies would need to be performed to evaluate this further.

## CONCLUSIONS

Our unique series complements previously published data on transperineal template-guided prostate biopsies, showing it to be safe and accurate. Our study suggests that due to the relatively high detection rate one must consider template biopsies after one negative transrectal biopsy if there is clinical suspicion. In addition, those with Gleason 3 + 3 = 6 prostate cancer who are considering active surveillance should be offered template biopsies so more accurate staging can be done and appropriate counselling performed.

The overall morbidity of template biopsies was improved compared to transrectal biopsies. However,

to counter the increased risk of AUR we have found a single dose of tamsulosin to be beneficial.

#### CONFLICTS OF INTEREST

The authors declare no conflicts of interest.

#### ETHICAL APPROVAL

All procedures performed in this study were in accordance with the ethical standards of the institutional and/or national research committee, and with the 1964 Helsinki declaration and its later amendments or comparable ethical standards.

#### References

- Siegel R, Ma J, Zou Z, Jemal A. Cancer statistics, 2014. *CA Cancer J Clin.* 64: 9-29.
- Tran M, Thompson J, Böhm M, et al. Combination of multi-parametric magnetic resonance imaging (mp-MRI) and transperineal template-guided mapping biopsy (TTMB) of the prostate to identify candidates for hemi-ablative focal therapy. *BJU Int.* 2016; 117: 48-54.
- Sivaraman A, Sanchez-Salas R, Barret E, et al. Transperineal template-guided mapping biopsy of the prostate. *Int J Urol.* 2015; 22: 146-151.
- Bjurlin MA, Wysock JS, Taneja SS. Optimization of prostate biopsy: review of technique and complications. *Urol Clin North Am.* 2014; 41: 299-313.
- Heidenreich A, Bolla M, Joniau S, et al. Guidelines on Prostate Cancer. Update. 2011; 53: 31-45. Available from: <http://uroweb.org/wpcontent/uploads/EAU-Guidelines-Prostate-Cancer-2015-v2.pdf>.
- Rosario DJ, Lane JA, Metcalfe C, et al. Short term outcomes of prostate biopsy in men tested for cancer by prostate specific antigen: prospective. *BMJ.* 2012; 344: d7894.
- Serefoglu EC, Altinova S, Ugras NS, Akincioglu E, Asil E, Balbay MD. How reliable is 12-core prostate biopsy procedure in the detection of prostate cancer? *Can Urol Assoc J.* 2013; 7: 293-298.
- Chang DTS, Challacombe B, Lawrentschuk N. Transperineal biopsy of the prostate-is this the future? *Nat Rev Urol.* 2013; 10: 690-702.
- Rabbani F, Stroumbakis N, Kava BR, Cookson MS, Fair WR. Incidence and clinical significance of false-negative sextant biopsies of the prostate. *Urologe A.* 1998; 37: 660.
- Symons JL, Huo A, Yuen CL, et al. Outcomes of transperineal template-guided prostate biopsy in 409 patients. *BJU Int.* 2013; 112: 585-593.
- Moran BJ, Braccioforte MH, Conterato DJ. Re-biopsy of the Prostate Using a Stereotactic Transperineal Technique. *J Urol.* 2006; 176: 1376-13781.
- Dickinson L, Ahmed HU, Allen C, et al. Magnetic resonance imaging for the detection, localisation, and characterisation of prostate cancer: recommendations from a European consensus meeting. *Eur Urol.* 2011; 59: 477-494.
- Rosenkrantz AB, Kim S, Lim RP, et al. Prostate cancer localization using multiparametric MR imaging: comparison of Prostate Imaging Reporting and Data System (PI-RADS) and Likert scales. *Radiology.* 2013; 269: 482-492.
- Igel TC, Knight MK, Young PR, et al. Systematic transperineal ultrasound guided template biopsy of the prostate in patients at high risk. *J Urol.* 2001; 165: 1575-1579.
- Hodge KK, McNeal JE, Terris MK, Stamey TA. Random systematic versus directed ultrasound guided transrectal core biopsies of the prostate. *J Urol.* 1989; 142: 71-74.
- Eskew LA, Bare RL, McCullough DL. Systematic 5 region prostate biopsy is superior to sextant method for diagnosing carcinoma of the prostate. *J Urol.* 1997; 157: 199-202.
- Bott SRJ, Young MPA, Kellett MJ, Parkinson MC. Anterior prostate cancer: Is it more difficult to diagnose? *BJU Int.* 2002; 89: 886-889.
- Takashima R, Egawa S, Kuwao S, Baba S. Anterior distribution of Stage T1c nonpalpable tumors in radical prostatectomy specimens. *Urology.* 2002; 59: 692-697.
- Caster JM, Falchook AD, Hendrix LH, Chen RC. Risk of Pathologic Upgrading or Locally Advanced Disease in Early Prostate Cancer Patients Based on Biopsy Gleason Score and PSA: A Population-Based Study of Modern Patients. *Int J Radiat Oncol Biol Phys.* 2015; 92: 244-251.
- Klotz L. Active surveillance: the Canadian experience. *Curr Opin Urol.* 2012; 22: 222-230.
- Forde JC, Daly PJ, White S, et al. A single centre experience of active surveillance as management strategy for low-risk prostate cancer in Ireland. *Ir J Med Sci.* 2014; 183: 377-382.
- Dall'Era MA, Konety BR, Cowan JE, et al. Active surveillance for the management of prostate cancer in a contemporary cohort. *Cancer.* 2008; 112: 2664-2670.
- Loeb S, Vellekoop A, Ahmed HU, et al. Systematic review of complications of prostate biopsy. *Eur Urol.* 2013; 64: 876-892.
- Pepe P, Aragona F. Morbidity after transperineal prostate biopsy in 3000 patients undergoing 12 vs 18 vs more than 24 needle cores. *Urology.* 2013; 81: 1142-1146.
- Buskirk SJ, Pinkstaff DM, Petrou SP, et al. Acute urinary retention after transperineal template-guided prostate biopsy. *Int J Radiat Oncol Biol Phys.* 2004; 59: 1360-1366.
- Bozlu M, Ulusoy E, Doruk E, et al. Voiding impairment after prostate biopsy: Does tamsulosin treatment before biopsy decrease this morbidity? *Urology.* 2003; 62: 1050-1053.
- National Institute for Health and Care Excellence. Focal therapy using high-intensity focused ultrasound for localised prostate cancer. NICE interventional procedure guidance 424. 2012; (2009): 1-9. Available from: [www.nice.org.uk/ipg424](http://www.nice.org.uk/ipg424)
- Mottet N, Bellmunt J, Patient EB, et al. 09-Prostate-Cancer\_LRV2-2015-1. 2015; Available from: [http://uroweb.org/wp-content/uploads/09-Prostate-Cancer\\_LRV2-2015.pdf](http://uroweb.org/wp-content/uploads/09-Prostate-Cancer_LRV2-2015.pdf) ■