

## Case Report

©2015 NRITLD, National Research Institute of Tuberculosis and Lung Disease, Iran

ISSN: 1735-0344 *Tanaffos* 2015; 14(2): 149-152



# Pulmonary Mucormycosis in a Patient with Chronic Rejection of Kidney Transplant: A Case Report

**Mahshid Talebi-Taher**<sup>1</sup>, **Seyede -Nina Alavi Niakou**<sup>2</sup>, **Seied Ali Javad-Mousavi**<sup>3</sup>, **Mohammad Vaziri**<sup>4</sup>, **Aida Iranpour**<sup>2</sup>, **Maryam Dehghani**<sup>2</sup>

<sup>1</sup> Department of Infectious Diseases, <sup>2</sup> Department of Internal Medicine, <sup>3</sup> Department of Pulmonary Medicine, <sup>4</sup> Department of Thoracic Surgery, Rasoul-e-Akram General Teaching Hospital, Iran University of Medical Sciences, Tehran, Iran.

Received: 12 April 2015

Accepted: 20 May 2015

Correspondence to: Talebi-Taher M

Address: Antimicrobial Resistance Research Center, Infectious Diseases Department, Rasoul-e-Akram General Teaching Hospital, Tehran, Iran.  
Email address: Mtalebitaher2000@yahoo.com

Pulmonary mucormycosis is a rare but fatal condition that frequently occurs in immunocompromised patients. Correct diagnosis and rapid start of preferred antifungal treatment need clinical suspicion. Patient's symptoms may be confluent with other conditions such as bacterial and other fungal infections. We present a case of pulmonary mucormycosis in a patient with end stage renal disease successfully treated with a long course of amphotericin B deoxycholate (AmB) and upper lobectomy of the left lung despite of low pulmonary capacity.

**Key words:** Mucormycosis; Kidney Transplantation; Chronic; Amphotericin B

## INTRODUCTION

Mucormycosis, previously termed as zygomycosis, is a devastating life threatening infection caused by the ubiquitous filamentous fungi of the Mucorales order of the class of Zygomycetes with an often unfavorable outcome (1-3). Pulmonary mucormycosis is manifested in immunocompromised or diabetic patients by cavitation on chest radiograph in 40% of patients (4). Reports show that the lungs are the leading site of invasive fungal infection in solid organ transplant recipients (5).

The major principles of treatment of mucormycosis are based on antifungals and excision of infected tissue (2). We report a case of pulmonary mucormycosis in a renal transplant recipient with a subacute presentation in a three-month period without invasion to the chest wall that underwent an upper lobe lobectomy in the left lung.

## CASE SUMMARIES

A 40-year-old male with end stage renal disease and kidney transplantation presented with progressive dyspnea, orthopnea and paroxysmal nocturnal dyspnea four months ago. He also complained of intermittent fever and chills. Past medical history was remarkable for renal failure followed by kidney transplantation 20 years ago. The patient received mycophenolate mofetil, cyclosporine and prednisolone for 19 years. He experienced progressive increase in serum creatinine level, and chronic rejection was confirmed by renal biopsy. Hemodialysis was started for him six months prior to admission. At first, volume overload due to inadequate hemodialysis was diagnosed, but with increasing number and duration of hemodialysis, symptoms did not improve and loss of appetite, recurrent

vomiting, significant weight loss and frequent non-massive hemoptysis developed.

On physical examination, the patient was ill and cachectic (body mass index of 15 kg/m<sup>2</sup>), blood pressure was 100/60 mmHg, respiratory rate was 30 per minute, oxygen saturation rate was 90% while he was breathing ambient air and oral temperature was 38°C. Lung auscultation revealed diminished breath sounds in the upper third of the left lung and bibasilar areas and also diffuse fine crackles in both hemithoraces. The same areas were dull on percussion with slightly increased tactile fremitus. There was bilateral pitting edema up to the ankle and the remainder of examinations were normal.

Results of laboratory data showed leukopenia, anemia and thrombocytopenia (WBC=3,800 per microliter, Hb =9.5 g/dL, MCV=85.58 fL, Plt=31,000 per microliter). The serum level of protein, albumin and total calcium was low (Ca=7 mg/dL, Alb=1.9 g/dL, Total pro=5.4g/dL, ESR=13 mm/hr, CRP=59 mg/L). Smear and culture of sputum were negative for acid-fast bacilli. Other laboratory findings were normal.

Chest X-ray was done and showed a cavitory lesion in the left upper lobe. Spiral chest computed tomography (CT) confirmed findings of CXR and bilateral pleural effusion (Figure 1). There was no evidence of significant lymphadenopathy or rib involvement.

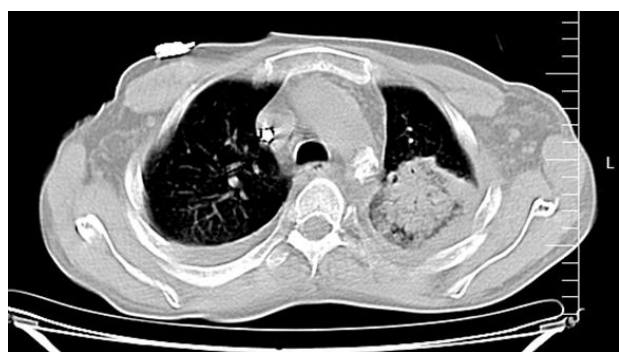


Figure 1. Cavitory lesion in the left upper lobe

A CT guided biopsy was performed. Broad-spectrum antibiotics including imipenem and vancomycin with renal

adjustment and hydrocortisone were administered but fever continued. Bone marrow aspiration and biopsy were done. Nothing was found except for a slightly hypocellular bone marrow. Electrocardiogram and transthoracic echocardiography were normal. Bronchoalveolar lavage examination was negative for acid-fast bacilli. Upper and lower gastrointestinal endoscopy were done and there was no evidence of malignancy or infection. Pathological examination of lung biopsy revealed necrotic material, which was infiltrated by broad fungal hyphae without septation suggestive of mucormycosis (Figure 2).

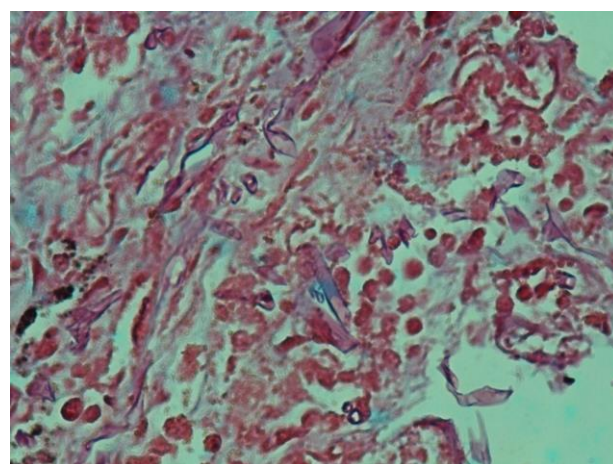


Figure 2. Broad fungal hyphae without septation suggestive of mucormycosis

A diagnosis of pulmonary mucormycosis was made and Amphotericin B deoxycholate (AmB 1mg/kg daily) was started and after one month of treatment caspofungin was added. The patient's general condition improved but fever and hemoptysis continued with less intensity. There was improvement on radiography, but the cavitory lesion persisted. Due to the poor response to medical therapy, the patient was a candidate for lung lobe resection; but because of low forced expiratory volume on spirometry (FEV1=51% predicted, 1.06 lit), and severe restrictive pattern that was observed (FEV1/FVC=85%, FVC= 50.3% predicted, 1.24 lit), pulmonary surgery was very high risk. Despite this, because of persistent fever and hemoptysis left upper lobectomy of the lung was performed and the patient was discharged without any complications 20 days later; his therapy was continued with posaconazole to

complete two additional weeks of oral antifungal therapy. The patient was in good condition at one-year follow-up.

## DISCUSSION

We report a young man with pulmonary mucormycosis following rejection of a renal transplant. Based on pathological findings and presence of distinctive hyphae a diagnosis of mucormycosis was made.

Mucormycosis typically occurs in immunocompromised patients, such as diabetes mellitus, organ or hematopoietic stem cell transplantation (HSCT), neutropenia or malignancy (2). The most common sign of pulmonary mucormycosis is prolonged high-grade fever unresponsive to broad spectrum antibiotics. Non-productive cough is seen most of the time. Hemoptysis, pleuritic chest pain and dyspnea are less common (3).

Radiologic findings of pulmonary mucormycosis are initial parenchymal manifestations such as lobar or segmental consolidation, multilobar consolidation, solitary nodule or mass and multiple nodules or masses. Other features such as cavitary consolidation, cavitary mass, air-crescent sign, unilateral or bilateral pleural effusion, hilar mass or right paratracheal mass may also be seen (4). Lately, due to recent improvement in management of immunosuppressed patients with underlying malignancy and solid organ transplantation, the incidence of mucormycosis seems to be increasing (2).

Because of the aggressive nature of mucormycosis and high mortality rate, diagnosis of mucormycosis may be less than reality (1). Diagnosis of mucormycosis is based on microbiological and histopathological findings. If tissue invasion with characteristic broad, non-septate hyphae with right angle branching are found, definite diagnosis of mucormycosis is made. In pulmonary mucormycosis, due to the devastating nature of infection, rapid progression, high mortality and the need for tissue biopsy to distinguish it from other infectious causes, diagnosis is made infrequently; sputum culture is usually non-informative (6).

Management of mucormycosis is based on two important cornerstones namely rapid initiation of antifungal therapy and debridement of affected tissue. For decades, AmB has been used for management of mucormycosis (such as our patient) (7). Recent data supports that lipid formulations of AmB are more effective and have less nephrotoxicity (2). Posaconazole should be considered for management of mucormycosis when complete regression with AmB or LAmB does not occur or in stable patients that need to switch to an oral antifungal (1,8). Adding echinocandins to AmB for at least two weeks may potentially benefit the management of mucormycosis (9), and we did just that.

Despite aggressive surgical and antifungal therapy, the mortality rate of mucormycosis is very high and is equal or more than 40% (2); in pulmonary mucormycosis the mortality rate may increase to greater than 80% in 12 months. Guidelines from the American College of Chest Physicians for pulmonary surgery state that patients with reduced FEV1 less than 1.5 L may not tolerate lobectomy and that cardiopulmonary exercise test should be considered (10). Our patient was successfully treated with lobectomy and medical therapy with preservation of pulmonary function.

When surgery is combined with AmB, the patient outcome will be improved (2,10,11). In selected cases of pulmonary mucormycosis refractory to AmB therapy, aggressive surgical debridement combined with antifungal therapy should be considered.

## REFERENCES

1. Fernandez JF, Maselli DJ, Simpson T, Restrepo MI. Pulmonary mucormycosis: what is the best strategy for therapy? *Respir Care* 2013; 58 (5): e60- 3.
2. Spellberg B, Ibrahim AS. Recent advances in the treatment of mucormycosis. *Curr Infect Dis Rep* 2010; 12 (6): 423- 9.
3. Petrikos G, Skiada A, Lortholary O, Roilides E, Walsh TJ, Kontoyiannis DP. Epidemiology and clinical manifestations of mucormycosis. *Clin Infect Dis* 2012; 54 Suppl 1: S23- 34.

4. McAdams HP, Rosado de Christenson M, Strollo DC, Patz EF Jr. Pulmonary mucormycosis: radiologic findings in 32 cases. *AJR Am J Roentgenol* 1997; 168 (6): 1541- 8.
5. Hamdi T, Karthikeyan V, Alangaden GJ. Mucormycosis in a renal transplant recipient: case report and comprehensive review of literature. *Int J Nephrol* 2014; 2014: 950643.
6. Bigby TD, Serota ML, Tierney LM Jr, Matthay MA. Clinical spectrum of pulmonary mucormycosis. *Chest* 1986; 89 (3): 435-9.
7. Roden MM, Zaoutis TE, Buchanan WL, Knudsen TA, Sarkisova TA, Schaufele RL, et al. Epidemiology and outcome of zygomycosis: a review of 929 reported cases. *Clin Infect Dis* 2005; 41 (5): 634- 53.
8. Tacke D, Koehler P, Markiefka B, Cornely OA. Our 2014 approach to mucormycosis. *Mycoses* 2014; 57 (9): 519-24.
9. Kazak E, Aslan E, Akalın H, Saraydaroğlu O, Hakyemez B, Erişen L, et al. A mucormycosis case treated with a combination of caspofungin and amphotericin B. *J Mycol Med* 2013; 23 (3): 179- 84.
10. Li JY, Yong TY, Jurisevic CA, Russ GR, Grove DI, Coates PT, et al. Successful treatment of pulmonary mucormycosis in a renal transplant recipient with limited pulmonary reserve by combined medical and surgical therapy. *Heart Lung Circ* 2009; 18 (3): 226- 8.
11. Asai K, Suzuki K, Takahashi T, Ito Y, Kazui T, Kita Y. Pulmonary resection with chest wall removal and reconstruction for invasive pulmonary mucormycosis during antileukemia chemotherapy. *Jpn J Thorac Cardiovasc Surg* 2003; 51 (4): 163- 6.