

Single Case – General Neurology

Ross Syndrome: A Patient with a 23-Year History

Zuhal Filikci^a Hans-Henrik Horsten^b Mette Lindelof^a

^aDepartment of Neurology, Sjællands Universitetshospital, Roskilde, Denmark;

^bDepartment of Dermatology and Allergy Centre, Odense University Hospital, Odense, Denmark

Keywords

Ross syndrome · Anhidrosis · Autonomic nervous system

Abstract

We present a 60-year-old female with a 23-year history of anhidrosis with concomitant heat intolerance. At examination, we found a right-sided tonic pupil, absent tendon reflexes, and a segmental patch of compensatory hyperhidrosis in the left lower quadrant of her trunk. To further confirm this finding, a minor test (a starch-iodine test, which is used to evaluate the sudomotor function, sweating) was performed. Nerve conduction studies revealed evidence of a mild distal sensory polyneuropathy of the axonal type. Tilt-table testing showed signs of orthostatic hypotension with evidence of reduced sympathetic function. Skin biopsy excluded pathology in the sweat glands. Our patient met the criteria for a diagnosis of Ross syndrome. This case describes the long-term outcome of this rare entity and highlights how careful examination and bedside autonomic testing can confirm the diagnosis of autonomic neurological disorders.

© 2020 The Author(s)
Published by S. Karger AG, Basel

Introduction

Ross syndrome was first described in 1958 as a degenerative autonomic nervous system disorder defined by the characteristic triad of segmental anhidrosis, areflexia, and tonic pupils. About 50 cases of Ross syndrome have been described so far [1]. In this paper, we present

a 60-year-old patient from Denmark with typical and severe features of Ross syndrome developed throughout 23 years.

Case Presentation

In 1996, a 60-year-old female patient presented with redness and decreased sweating over the left half of the face, which slowly progressed to all other parts of the body throughout 23 years and only left a patchy area with increased sweating on the left lower quadrant of her trunk.

The patient had not applied topical medication to any part of the body. There was no history of joint or muscular pains, but she complained of a prickly sensation anywhere in the skin.

The patient presented by inspection with dry and scaly skin. Upon physical examination, we found redness and moisture corresponding to a 20 × 30 cm, band-shaped segmental area on the left lower of the trunk (corresponding to the 6th–8th dermatomes). There was also an altered/decreased sense of touch in the area of anhidrosis. Deep tendon reflexes were absent both in the upper and lower limbs. Pupillary examination showed a tonic pupil on the right side and anisocoria with the right pupil smaller than the left (Fig. 1). There were no tremor, bradykinesia, dysarthria, or incoordination of the limbs or postural instability. There was neither motor weakness nor any wasting. Twenty-four-hour ambulatory blood pressure monitoring was normal.

A minor test (starch-iodine test) was performed to confirm hyperhidrosis (Fig. 2). Histopathological examination from the anhidrotic area showed atrophic epidermis but basally located small eccrine sweat glands, excluding a primary sweat gland disorder.

Nerve conduction studies revealed evidence of a mild distal sensory polyneuropathy of the axonal type. Magnetic resonance imaging (MRI) of the brain and the spinal canal was unremarkable. Antinuclear antibodies and Sjögren's autoantibodies were within normal limits. Tilt-table testing showed signs of orthostatic hypotension with evidence of reduced sympathetic function.

Discussion and Conclusion

Our patient presented with segmental anhidrosis that, along with the tonic pupil and areflexia, fits into the classical description of Ross syndrome. However, as reported in several studies, the main objective symptoms were the concomitant presence of a well-delimited compensatory hyperhidrosis and a disabling heat intolerance [2, 3]. The detected anhidrosis is indicating dysfunction of the sympathetic pathway to the sweat glands or a primary disease involving the sweat glands. The normal structure of the patient's sweat glands and ducts on skin biopsy from an affected segment excluded the latter.

Our patient had signs of orthostatic hypotension, which was shown by positive tilt-table testing, indicating a more widespread involvement of the autonomic nervous system. Various autoimmune autonomic neuropathies due to systemic disease, including Sjögren's syndrome, were unlikely in our patient because of the course of the disease and an absence of relevant clinical and laboratory findings.

The finding of widespread segmental anhidrosis, pupil abnormality, orthostatic hypotension, and areflexia in this patient points towards a generalized injury to the peripheral autonomic and dorsal root ganglia or their efferents [4]. A wide overlap has been suggested

between Ross syndrome, Holmes-Adie syndrome, and more widespread autonomic disease [4]. The hypothesis of a degenerative mechanism has recently been reported to involve sudomotor fibers and other skin autonomic nerve fibers, and secondarily other fiber types such as epidermal unmyelinated and myelinated sensory fibers [5].

This patient case illustrates the importance of systematic clinical evaluation and simple bedside tests in the approach to diseases of the autonomic nervous system.

Acknowledgement

We thank Dr. Martin Ballegaard, Head of The Neurophysiology Center at the Department of Neurology, Sjællands Universitetshospital, Roskilde, for advice and performing nerve conduction studies and tilt-table testing.

Statement of Ethics

The authors have no ethical conflicts to disclose. The authors confirm obtaining written consent from the patient for publication of the manuscript (including images, case history, and data).

Disclosure Statement

The authors declare that the research was conducted in the absence of any commercial or financial relationships that could be constructed as a potential conflict of interest.

Funding Sources

The authors received no funding for the publication of the manuscript.

Author Contributions

Z.F. contributed to the rationale and patient management, and all authors contributed to the manuscript development, images, and descriptions.

References

- 1 Nagane Y, Utsugisawa K. Ross syndrome associated with cytomegalovirus infection. *Muscle Nerve*. 2008 Jul;38(1):924–6.
- 2 Nolano M, Provitera V, Perretti A, Stancanelli A, Saltalamacchia AM, Donadio V, et al. Ross syndrome: a rare or a misknown disorder of thermoregulation? A skin innervation study on 12 subjects. *Brain*. 2006 Aug;129(Pt 8):2119–31.
- 3 Chemmanam T, Pandian JD, Kadyan RS, Bhatti SM. Anhidrosis: a clue to an underlying autonomic disorder. *J Clin Neurosci*. 2007 Jan;14(1):94–6.
- 4 Shin RK, Galetta SL, Ting TY, Armstrong K, Bird SJ. Ross syndrome plus: beyond horner, Holmes-Adie, and harlequin. *Neurology*. 2000 Dec;55(12):1841–6.

- 5 Perretti A, Nolano M, De Joanna G, Tugnoli V, Iannetti G, Provitera V, et al. Is Ross syndrome a dysautonomic disorder only? An electrophysiologic and histologic study. *Clin Neurophysiol*. 2003 Jan;114(1):7–16.

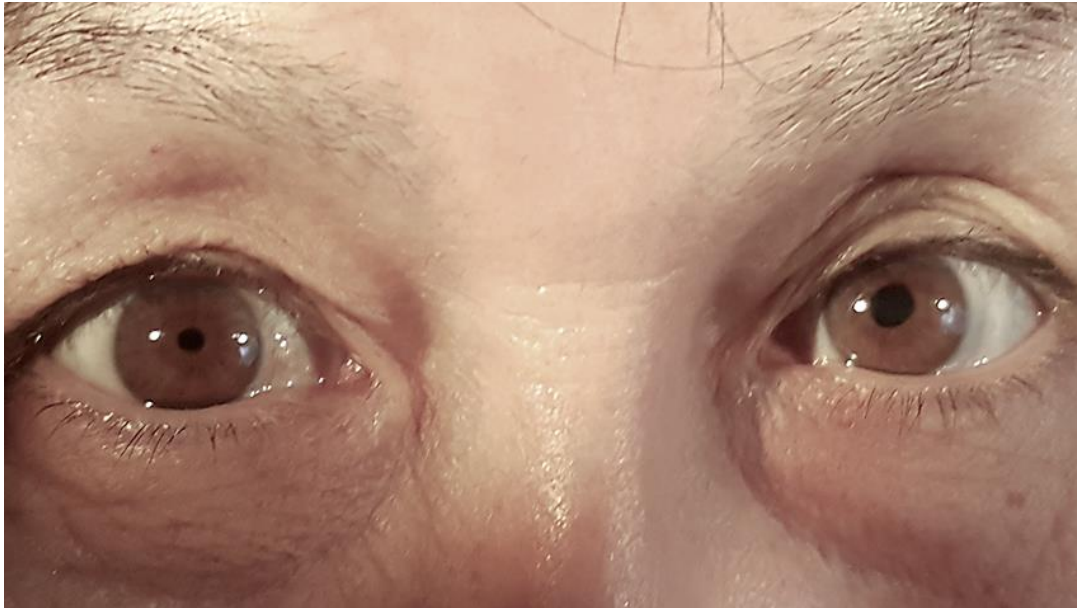

Fig. 1. The patient has a tonic pupil on the right side, and pupillary examination showed anisocoria, with the right pupil being smaller than the left one.

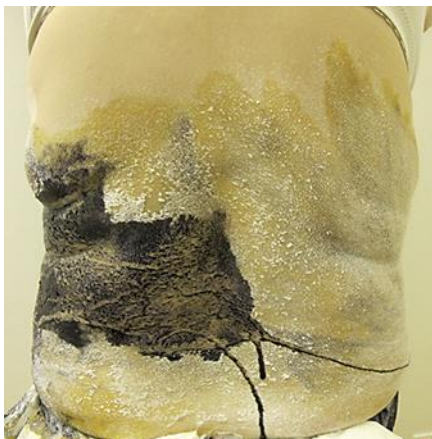


Fig. 2. The starch-iodine combination turned into a dark color on the left side, predominantly involving the skin over the 6th–8th vertebral region, wherever there was hyperhidrosis.