

# Looking Outside the “Cardiac” Box: Incidental Detection of a Metastatic Lung Tumor on Cardiac Position Emission Tomography/Computed Tomography

Mohamed Shawgi, P. Arumugam

Department of Nuclear Medicine, Central Manchester University Hospitals, Manchester, United Kingdom

## Abstract

Incidental extracardiac findings are not uncommon in patients undergoing cardiac positron emission tomography/computed tomography (PET/CT) and some of these findings can have significant clinical impact. We report a case of a 74-year-old man who presented with dyspnea and left sided chest pain. 82-rubidium PET/CT imaging showed normal myocardial perfusion. Review of the low dose CT scan performed for attenuation correction purposes (CTAC) incidentally revealed a 4 cm mass in the left lung, which was histologically shown to be a squamous cell carcinoma. A subsequent staging CT showed chest wall metastases and rib destruction in the upper left thorax, which were outside the image reconstruction field of view of the CTAC. This report illustrates the importance of vigilant review of all acquired images by the PET/CT reader to look for extracardiac abnormalities that may explain symptoms in the absence of coronary artery disease. It also raises the question as to whether a larger field of CT image acquisition should be routinely performed to scan the entire chest during cardiac PET/CT imaging. However, the latter needs to be weighed against the increase in patient dose, which we estimated to be an additional 15%.

**Keywords:** Attenuation correction, perfusion, positron emission tomography/computed tomography, rubidium

## Introduction

Cardiac position emission tomography/computed tomography (PET/CT) is a valuable noninvasive imaging modality with high sensitivity and specificity for diagnosis of coronary artery disease.<sup>[1]</sup> The majority of hybrid PET/CT scanners available commercially utilize a multi-slice CT scanner for attenuation correction (AC). This allows more robust AC with significant reduction in artefacts frequently seen on conventional single photon emission computed tomography (SPECT) imaging particularly in females and in patients with a large body habitus. We report a patient with suspected myocardial ischemia who underwent cardiac PET/CT and was

incidentally found to have a malignant lung tumor with chest wall metastases.

## Case Report

A 74-year-old man with no past history of heart disease presented to the emergency department with shortness of breath and atypical left sided chest pain. His cardiac risk factor profile included hypertension and cigarette smoking. Electrocardiography (ECG) showed normal sinus rhythm and no acute ST segment changes. Cardiac enzymes were not elevated and his basic biochemistry was normal. Echocardiography revealed hypertrophy of the left ventricle associated with global myocardial hypokinesis and left ventricular ejection fraction of 34%. The patient was referred for myocardial perfusion imaging to rule out ischemic cardiomyopathy and an ECG gated 82-rubidium PET/CT perfusion scan was performed using a Siemens Biograph mCT scanner. AC of the PET images was performed with a low-dose CT scan (CTAC) acquired using the following scanning perimeters: 120 kV tube voltage, 20 mA effective tube

### Access this article online

#### Quick Response Code:



#### Website:

www.wjnm.org

#### DOI:

10.4103/1450-1147.144822

#### Address for correspondence:

Dr. Mohamed Shawgi, Nuclear Medicine Centre, Manchester Royal Infirmary, Oxford Road, Manchester, M13 9WL, United Kingdom.  
E-mail: mshawgi@gmail.com

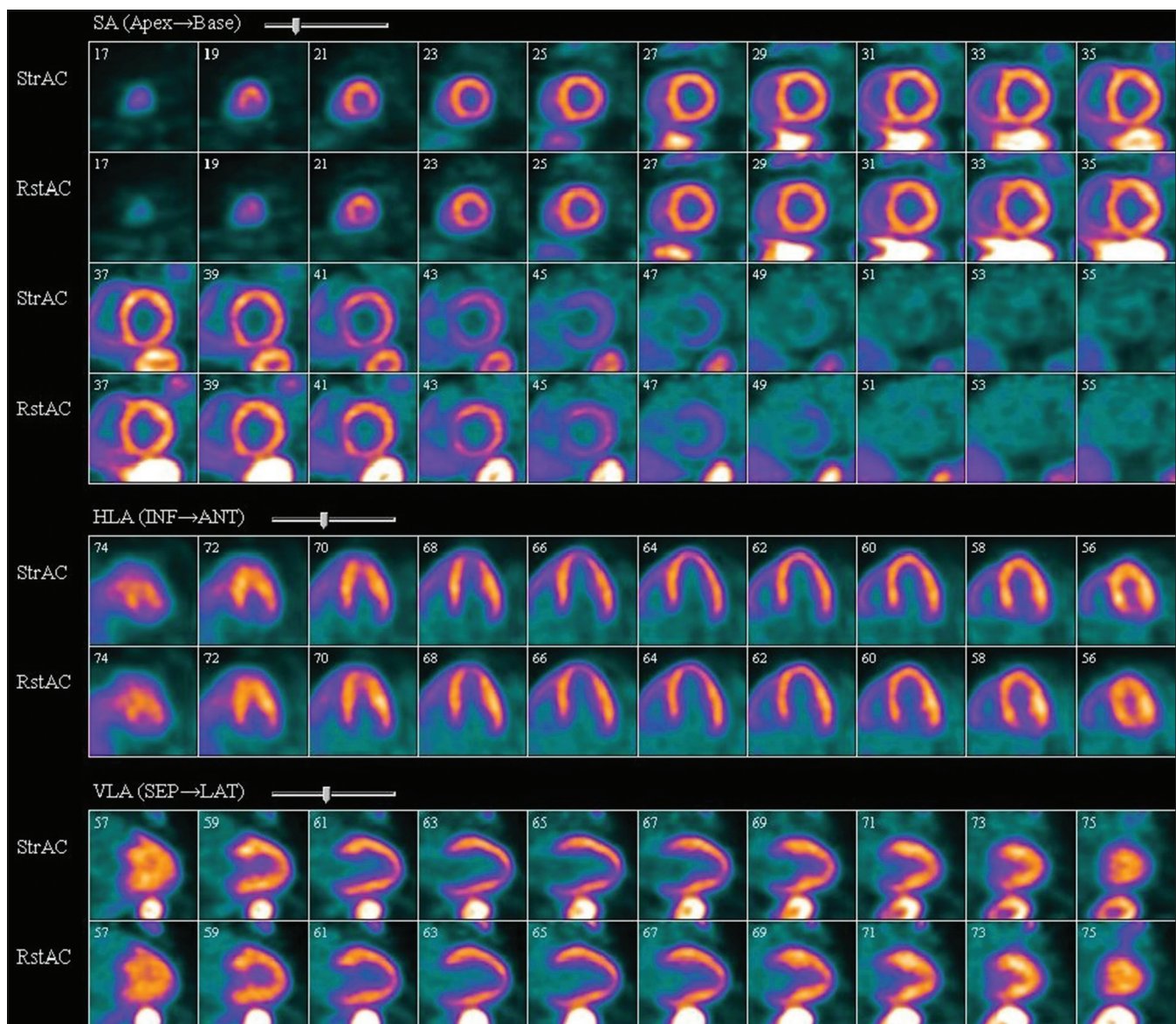
current, 1.5 pitch, gantry rotation time 0.5 s, 3 mm slice thickness. Scanning was performed from immediately above the carina to the level of the diaphragm. CT slices (3 mm) were reconstructed using a  $512 \times 512$  matrix and a  $50 \times 50$  cm field of view.

The stress-rest perfusion images showed a dilated left ventricular cavity and normal myocardial perfusion in keeping with a nonischemic dilated cardiomyopathy [Figure 1]. Review of the CT component showed a malignant looking 4 cm diameter mass in the left upper lobe and multiple mediastinal lymph nodes of varying sizes [Figure 2a]. A staging whole body CT examination was performed in the Radiology Department and showed metastatic invasion of the left anterior chest wall and rib destruction above the level of the primary

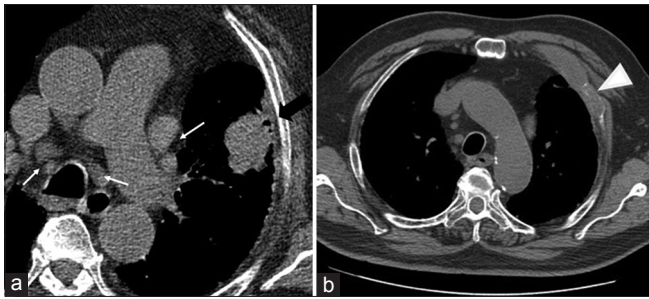
tumor [Figure 2b]. These were outside the field of view on the CTAC study and were not visible on the topogram or maximum intensity projection images. Ultrasound guided lung biopsy confirmed pulmonary squamous cell carcinoma (tumor, nodes, and metastases stage T3 N3 M1).

## Discussion

The true prevalence of significant extracardiac findings on cardiac CT is variable and is strongly influenced by patient selection.<sup>[2]</sup> Incidental extracardiac findings are reported in as many as 50% of a patients undergoing cardiac nuclear hybrid imaging, CT and magnetic resonance imaging. Some of these findings may have significant clinical impact.<sup>[3-11]</sup>



**Figure 1:** 82-Rubidium PET/CT perfusion scan showing dilatation of the left ventricular cavity with normal perfusion at peak stress and at rest. The ECG gated data confirmed left ventricular global hypokinesia and ejection fraction of 35% in keeping with non ischaemic cardiomyopathy

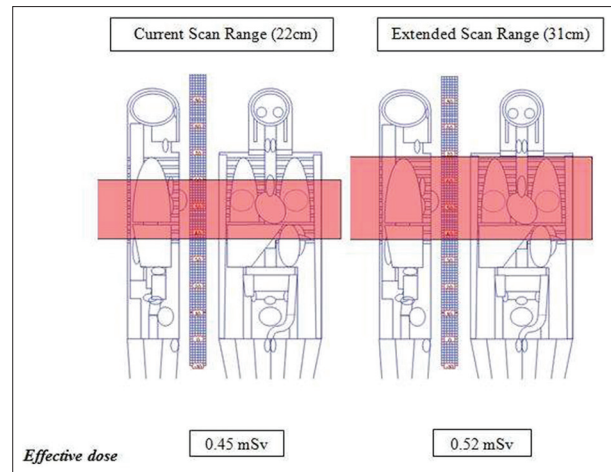


**Figure 2:** (a) Transaxial computed tomography attenuation correction slices showing the primary lung tumour (black arrow) and multiple pathological mediastinal lymph nodes (white arrows). (b) Staging CT showing anterior chest wall metastases and rib destruction (arrow head)

The main purpose of CTAC in hybrid cardiac imaging is AC of emission data. The growing use of multislice CT in cardiac nuclear hybrid imaging in recent years has allowed visualization of extracardiac structures with diagnostic-quality images. Systematic review of all acquired data (including the topogram) and not only the images of the heart is strongly advised as significant extra-cardiac findings may be observed.<sup>[12]</sup> Mirpour *et al.*<sup>[3]</sup> in their study have reported incidental extra cardiac findings in the breasts, thyroid, lungs, adrenals and bone marrow in 16.5% of cohort of patients undergoing 82-rubidium PET/CT. Husmann *et al.*<sup>[13]</sup> reported detection of a resectable pulmonary carcinoma on the topogram of the CTAC (performed as part of a SPECT perfusion study) but not on the transaxial slices as the upper thorax was not included in the field of view. The scan range that is often chosen in cardiac PET/CT imaging is from the level of the carina to the cardiac apex. This range is supposed to provide the required data for AC and allows assessment of cardiac structures whilst minimizing the effective radiation dose to the patient. We therefore proposed to evaluate the extra radiation burden to the patient as a result of CTAC imaging using an extended scan range from the apex of the lung to the diaphragm. The analysis was performed using Siemens Biograph mCT software and showed that patients scanned using the proposed extended scan range would receive an extra 0.7 mSv, that is, a 15% increase in dose [Figure 3].

## Conclusion

Incidental extracardiac findings are frequently found in patients undergoing cardiac hybrid imaging and some of these findings can be clinically significant. Extra reporting time should be allowed for the review of CT data to look for incidental abnormalities in structures surrounding the heart. Utilization of a wider scanning range to include the entire chest may allow detection of important co-incident pathology. However, this should be weighed against the associated 15% increase in effective radiation dose and may, thus, not



**Figure 3:** Computer analysis comparing our current scan range (from the level of the carina to just below the diaphragm) to an extended scan range that includes the upper thorax. The current scan range is associated with an effective dose of 0.45 mSv and the extended scan range with 0.52 mSv

be justifiable. Furthermore, the radiation burden of further imaging surveillance of these incidental findings and financial/resource implications to the health care industry (e.g. physician reporting time, cost of surveillance scanning, etc.) also needs to be considered.

## References

1. Di Carli MF, Dorbala S. Cardiac PET-CT. *J Thorac Imaging* 2007;22:101-6.
2. Douglas PS, Cerqueria M, Rubin GD, Chin AS. Extracardiac findings: What is a cardiologist to do? *JACC Cardiovasc Imaging* 2008;1:682-7.
3. Mirpour S, Khandani AH. Extracardiac abnormalities on rubidium-82 cardiac positron emission tomography/computed tomography. *Nucl Med Commun* 2011;32:260-4.
4. Onuma Y, Tanabe K, Nakazawa G, Aoki J, Nakajima H, Ibukuro K, *et al.* Noncardiac findings in cardiac imaging with multidetector computed tomography. *J Am Coll Cardiol* 2006;48:402-6.
5. Gil BN, Ran K, Tamar G, Shmuell F, Eli A. Prevalence of significant noncardiac findings on coronary multidetector computed tomography angiography in asymptomatic patients. *J Comput Assist Tomogr* 2007;31:1-4.
6. Greenberg-Wolff I, Uliel L, Goitein O, Shemesh J, Rozenman J, Di Segni E, *et al.* Extra-cardiac findings on coronary computed tomography scanning. *Isr Med Assoc J* 2008;10:806-8.
7. Law YM, Huang J, Chen K, Cheah FK, Chua T. Prevalence of significant extracoronary findings on multislice CT coronary angiography examinations and coronary artery calcium scoring examinations. *J Med Imaging Radiat Oncol* 2008;52:49-56.
8. Bhambhvani P, Dubovsky E, Nath H, Heo J, Iskandrian A. Unusual incidental findings by SPECT myocardial perfusion imaging and CT in the same patient. *J Nucl Cardiol* 2010;17:937-8.
9. Dewey M, Schnapauff D, Teige F, Hamm B. Non-cardiac findings on coronary computed tomography and magnetic resonance imaging. *Eur Radiol* 2007;17:2038-43.
10. Gedik GK, Ergün EL, Aslan M, Caner B. Unusual extracardiac findings detected on myocardial perfusion single photon emission computed tomography studies with Tc-99m sestamibi. *Clin Nucl Med* 2007;32:920-6.

11. Moinuddin A, Nguyen NC, Osman MM. Careful evaluation of CT findings of a cardiac viability F-18 FDG PET/CT study leading to detection of esophageal cancer. Clin Nucl Med 2010;35:335-7.
12. Osman MM, Cohade C, Fishman EK, Wahl RL. Clinically significant incidental findings on the unenhanced CT portion of PET/CT studies: Frequency in 250 patients. J Nucl Med 2005;46:1352-5.
13. Husmann L, Tatsugami F, Buechel RR, Pazhenkottil AP, Kaufmann PA. Incidental detection of a pulmonary adenocarcinoma on low-dose computed tomography used for

attenuation correction in myocardial perfusion imaging with SPECT. Clin Nucl Med 2010;35:751-2.

**How to cite this article:** Shawgi M, Arumugam P. Looking outside the "Cardiac" box: Incidental detection of a metastatic lung tumor on cardiac position emission tomography/computed tomography. World J Nucl Med 2014;13:197-200.

**Source of Support:** Nil. **Conflict of Interest:** None declared.