

# Dynamics study on the role of curcumin on TGF- $\beta$ 1 expression and pathological changes in acute paraquat poisoned rats

HONGGANG CHEN<sup>1</sup> and XIAOYAN FU<sup>2</sup>

<sup>1</sup>Department of Emergency, Gansu Provincial People's Hospital; <sup>2</sup>Department of Nursing, The First Hospital of Lanzhou University, Lanzhou, Gansu 730000, P.R. China

Received October 26, 2017; Accepted August 1, 2018

DOI: 10.3892/etm.2018.6667

**Abstract.** Role of curcumin on TGF- $\beta$ 1 expression and pathological changes in acute paraquat (PQ) poisoned rats were investigated. Forty-eight SD rats were divided into three groups: control group, PQ group, and PQ + curcumin group, with 16 rats in each group. PQ group rats received the lavagation of PQ every day, PQ + curcumin group was given the lavagation of curcumin treatment on the basis of the PQ group. Control group received the lavagation of physiological saline. The body weight of rats was recorded every day. Six rats were randomly selected on the 1st, 3rd and 7th day after treatment from each group and sacrificed by cervical dislocation. The blood and liver tissues of each rat were collected. The morphology change of the liver tissue was observed by hematoxylin and eosin (H&E) staining. The expression level of TGF- $\beta$ 1 in the liver tissue was detected by western blot analysis and RT-qPCR. The blood samples were sent to the inspection section of the hospital for the detection of reactive oxygen species (ROS), alanine aminotransferase (ALT), aspartate aminotransferase (AST), malondialdehyde (MDA) and superoxide dismutase (SOD). On the 1st day after poisoning, the liver cells of PQ rats had obvious edema; obvious fatty degeneration was observed on the 3rd day; and large number of cavities appeared on the 7th day due to necrosis. For the PQ + curcumin group, liver cell edema appeared on the 3rd day, and mild swelling of liver cells was observed on the 7th day. Compared with the control group, the expression of TGF- $\beta$ 1 was increased in the PQ group. The TGF- $\beta$ 1 level in PQ + curcumin group rats reached the peak on the 3rd day, then decreased, and it was lower than those in PQ group. The level of ROS, ALT, AST, MDA of the rats in PQ + curcumin

group reached the highest value on the 3rd day, while the level of SOD reached the lowest value; furthermore, the level of ROS, ALT, AST, MDA was lower than that in PQ group, while the level of SOD was higher than that of the PQ group. The results showed that curcumin can effectively inhibit the expression of TGF- $\beta$ 1, prevent PQ-induced liver cell oxidative damage and play an important role in the protection of liver function.

## Introduction

Paraquat (PQ) is one of the most widely used herbicides worldwide, especially in developing countries (1). It was reported that 5-15 ml of 20% concentration of PQ can lead to moderate or severe poisoning. There are thousands of case reports on accidental or deliberate poisoning of PQ each year (2). PQ has been classified as moderately hazardous by the World Health Organization (WHO) due to the lack of antidotes or effective strategies for the toxicity. The toxicity of PQ is mainly mediated by its redox activity (3). PQ interacts with a variety of enzymes, such as cytochrome P450 reductase, cytochrome oxidase and nitric oxide synthase. PQ is an electron receptor that acts on the intracellular redox reactions, producing large amounts of reactive oxygen species (ROS) and reactive free radicals and cause severe cell damage (4,5). A previous study has shown that the main organs of PQ distribution are the lung and the kidney (6). PQ has a structure similar to MPP, which is a metabolite of 1-methyl-4-phenylpyridine (MPTP), indicating that PQ is neurotoxic (7). For these reasons, previous studies focused on the lung, kidney and brain. Therefore, there is little information on the toxic effects of PQ on other organs. The liver is the main organ of detoxification. Recently, Kral *et al* confirmed that the liver is an important target organ for PQ (8). Curcumin, as a Chinese medicine extract, is well studied and confirmed to have anti-inflammatory and antioxidant effects and extensive biological functions in regulating the nervous system, cardiovascular disease, lung disease, immune system, and tumor development (9). However, there is no systematic study on the protective mechanism of curcumin on liver injury, especially PQ-induced liver injury. Therefore, the purpose of this study was to investigate the effect of curcumin on the dynamic processes of PQ-induced

---

*Correspondence to:* Dr Xiaoyan Fu, Department of Nursing, The First Hospital of Lanzhou University, 1 Donggang Xi Road, Lanzhou, Gansu 730000, P.R. China  
E-mail: chg06gs@163.com

**Key words:** paraquat, curcumin, TGF- $\beta$ 1, liver injury, oxidative stress

liver injury and pathological changes and its intrinsic regulatory molecules with an expectation of providing a theoretical basis for the clinical treatment of PQ.

## Materials and methods

**Experimental animal grouping.** Forty-eight male SPF grade SD rats were provided by Nanjing Animal Experimental Center (Nanjing, China) (experimental animal license no. SYXK2017-084). Rats were 6-9 weeks old and weighed 180-300 g. They were fed for a week at room temperature of 26°C, under regular lighting, and environmental noise <45 dB. Rats were divided into three groups: control group, PQ group, and PQ + curcumin group, with 16 rats in each group. Based on our preliminary data and the findings of Ishrat *et al* (10), rats in the control group were treated with gavage using 0.2 ml normal saline every day. The rats in the PQ group were treated with 50 mg/kg PQ every day. The PQ + curcumin group was given 200 mg/kg curcumin on the basis of PQ group. The weight of rats was recorded daily. All animal experiments were in strict accordance with the National Animal Ethics Association guidelines on the use and care of laboratory animals. The study was approved by the Ethics Committee of Gansu Provincial People's Hospital (Lanzhou, China).

**Sample collection and processing.** On the 1st, 3rd and 7th day after treatment, 6 rats were randomly selected from each group and were sacrificed by CO<sub>2</sub> inhalation followed by spinal dislocation. Rats were anesthetized with 10% chloral hydrate (300  $\mu$ l/g) with endotracheal intubation. From each rat 10 ml of apical blood was taken, liver tissue was collected and placed in 4% formalin buffer and stored in liquid nitrogen. All samples were collected and used for RT-qPCR and western blot analysis. Blood samples were kept at room temperature for 30 min, followed by centrifugation at 1,000 x g, 4°C for 10 min. Serum samples were sent to our laboratory for determination of alanine aminotransferase (ALT) and aspartate aminotransferase (AST) levels using the Beckman DxC 800 automated biochemical analyzer (Beckman Coulter, Inc., Shanghai, China). The rest of the serum was assayed to measure malondialdehyde (MDA) by thiobarbital colorimetric assay (cat. no. A003-1) and superoxide dismutase (SOD) by xanthine oxidation assay (cat. no. A001-3) (both from Nanjing Jiancheng Bio-Engineering Institute Co., Ltd., Nanjing, China). Liver tissue homogenate was made, and the level of ROS was measured by an active oxygen detection kit (cat. no. CA1410-100T; Beijing Solarbio Science & Technology Co., Ltd., Beijing, China). With distilled water as control, the absorbance value of each sample was measured at 550 nm. ROS concentration was calculated according to the formula, and ROS was expressed as U/mg (11-13).

**Hematoxylin and eosin (H&E) staining.** Rat liver tissue was cut into 1-2 mm thick pieces, placed in 4% formalin buffer overnight, dehydrated gradient ethanol and n-butanol, and then waxed and embedded in wax. The wax pieces were sliced at a thickness of 4  $\mu$ m and baked in a 60°C oven for 3 h. After dimethyl dewaxing, ethanol rehydration and H&E staining, the slices were examined under a Philips microscope (EM 300, Philips Healthcare, Amsterdam, The Netherlands).

**RT-qPCR.** TRIzol reagent (Invitrogen; Thermo Fisher Scientific, Inc., Waltham, MA, USA) was used to extract total RNA from rats. cDNA was synthesized from 1  $\mu$ g of RNA using one-step reverse transcription kit (no. 639505; Takara Bio, Inc., Otsu, Japan). The mRNA levels of each index were measured using a fluorescence quantitative PCR kit (FSQ-101; Toyobo Life Science, Osaka, Japan). GAPDH was taken as an internal reference. TGF- $\beta$ 1 gene localization: NC\_000019.10. Primers were designed and synthesized by Shanghai Sangon Biotechnology Co., Ltd. (Shanghai, China). Sequence: upstream, 5'-GGCCAG ATCCTGTCCAAGC-3' and downstream, 5'-GTGGGTTTC CACCATTAGCAC-3'; internal reference GAPDH: upstream, 5'-TGGCCTTCCGTGTTCTAC-3' and downstream, 5'-GAG TTGCTGTTGAAGTCGCA-3'. The relative expression level of each index was calculated by  $2^{-\Delta\Delta Cq}$  [ $\Delta Cq = Cq$  (target gene) -  $Cq$  (GAPDH)] (14-16).

**Western blot analysis.** The liver of SD rats was removed from liquid nitrogen and cut. The mixture was homogenized with 500  $\mu$ l of RIPA (tissue lysate, Beyotime Biotechnology, Guangzhou, China) and 1% cocktail (protease inhibitor; ProteinTech Group, Inc., Chicago, IL, USA) and centrifuged at 13,000 x g, 4°C for 30 min. The supernatant was measured for its protein concentration using an automatic microplate reader (PerkinElmer, Inc., Waltham, MA, USA). Protein sample (40  $\mu$ g) was taken and separated with 12% sodium dodecyl sulfate-polyacrylamide gel (SDS-PAGE). The total protein was transferred onto nitrocellulose membrane (NC) and the band at 25 kDa was incubated with TGF- $\beta$ 1 primary antibody (1:1,000, cat. no. E-CL-H0109c; Cell Signaling Technology, Inc., Danvers, MA, USA). The abundance of the target protein was measured under the ECL chemiluminescence system (Merck KGaA, Darmstadt, Germany) using ultra-sensitive chemiluminescent (Merck KGaA) and the grey value was analyzed with ImageJ software (V2.1.4.7; National Institutes of Health, Bethesda, MD, USA).

**Statistical methods.** The results were analyzed using GraphPad Prism software (version 5.01; GraphPad Software, Inc., La Jolla, CA, USA). The single factor analysis of variance and SNK-q test were used to compare the measurement data.  $P < 0.05$  was considered to indicate a statistically significant difference.

## Results

**Effects of curcumin on body weight in rats.** Table I shows that the body weight of the rats in the PQ group decreased significantly after poisoning ( $P < 0.05$ ), while the weight of the rats in the PQ + curcumin group was at the lowest level on the 3rd day and then increased. On the 1st, 3rd and 7th day, the weight of rats in PQ + curcumin group was heavier than that in PQ group, and the difference was statistically significant ( $P < 0.05$ ).

**Observation of the liver tissue morphology by H&E staining.** It can be seen from Fig. 1 that on the 1st day after poisoning, the rats in PQ group showed significant edema of liver cells, obvious fatty degeneration was observed on the 3rd day; and large number of cavities appeared on the 7th day due to necrosis. For the PQ + curcumin group, the rats showed no

Table I. Weight changes in three groups (mean  $\pm$  SD, g).

Group	Before poisoning	1st day	3rd day	7th day
Control	217.83 $\pm$ 15.27	223.53 $\pm$ 16.34	231.04 $\pm$ 16.92	243.55 $\pm$ 16.88
PQ	216.42 $\pm$ 15.76	202.17 $\pm$ 17.90 <sup>a</sup>	185.54 $\pm$ 19.48 <sup>b</sup>	165.06 $\pm$ 21.87 <sup>c</sup>
PQ + curcumin	218.59 $\pm$ 21.87 <sup>a</sup>	216.67 $\pm$ 15.26 <sup>d</sup>	210.41 $\pm$ 16.86 <sup>d</sup>	238.77 $\pm$ 18.85 <sup>e</sup>

<sup>a</sup>P<0.05, <sup>b</sup>P<0.01, <sup>c</sup>P<0.001 compared with the control group. <sup>d</sup>P<0.05, <sup>e</sup>P<0.01 compared with the PQ group. PQ, paraquat.

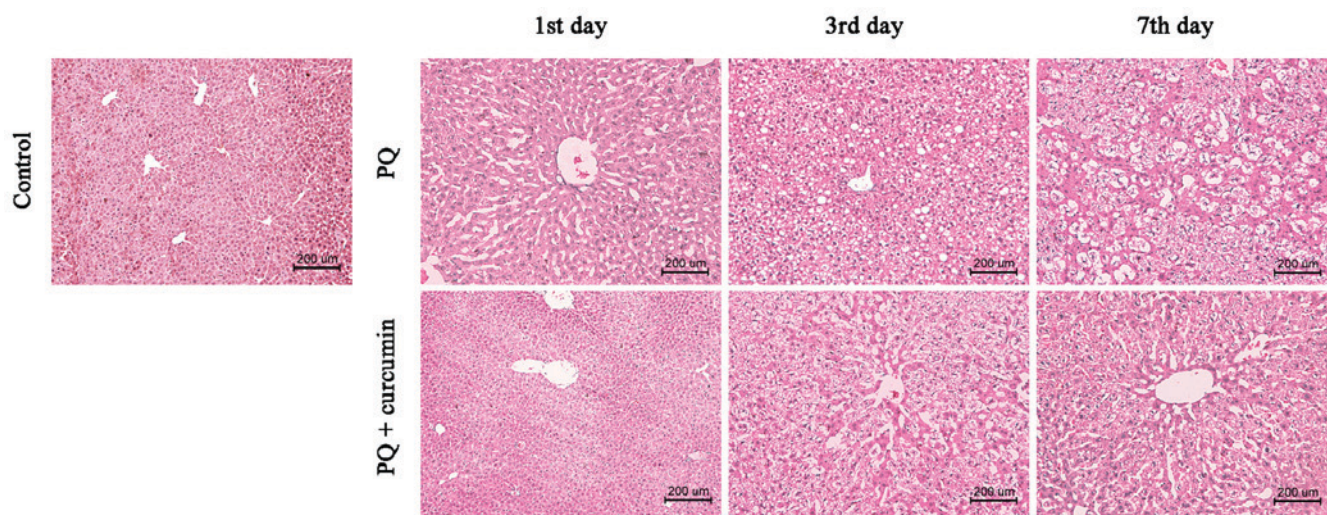


Figure 1. Observation of the liver tissue morphology by H&E staining (x200). Rats in PQ group showed obvious edema of hepatocytes on the 1st day after poisoning, obvious vacuolar degeneration on the 3rd day, and severe necrosis of hepatic cells formed on the 7th day. However, rats in PQ + curcumin group showed no significant change in liver on the 1st day, hepatocyte edema was observed on the 3rd day and mild hepatocyte edema was observed on the 7th day. H&E, hematoxylin and eosin; PQ, paraquat.

obvious change on the 1st day, while liver cell edema appeared on the 3rd day, and mild swelling of liver cells was observed on the 7th day. It is suggested that curcumin treatment can protect from liver injury caused by PQ.

**RT-qPCR detection of liver tissue TGF- $\beta$ 1 mRNA content.** It can be seen from Fig. 2 that compared with the control group, liver TGF- $\beta$ 1 of the rats in PQ group was increased on the 1st, 3rd and 7th day after poisoning (P<0.05), while for the rats in PQ + curcumin group mRNA level reached the peak on the 3rd day and then decreased. It should be noted that the levels of TGF- $\beta$ 1 in PQ + curcumin group were lower than those in PQ group at these three time-points (P<0.05).

**Detection of TGF- $\beta$ 1 protein content in liver tissue by western blot analysis.** It can be seen from Fig. 3 that, compared with the control group, liver TGF- $\beta$ 1 protein of PQ rats increased on the 1st, 3rd and 7th day after poisoning, which was consistent with the results of RT-qPCR. While in the PQ + curcumin group, TGF- $\beta$ 1 protein peaked on day 3 and subsequently decreased. At all three time-points, the content of TGF- $\beta$ 1 protein in PQ + curcumin group was lower than that in PQ group.

**Effects of curcumin on liver function.** Table II shows that ALT and AST in the blood of PQ rats continued to

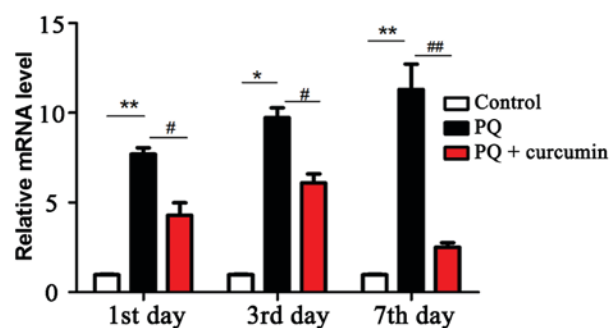


Figure 2. RT-qPCR detection of TGF- $\beta$ 1 mRNA expression in rat liver. \*P<0.05, \*\*P<0.01 compared with the control group. #P<0.05, ##P<0.01 compared with the PQ group.

increase after poisoning (P<0.05), and reached the highest value on the 7th day: 87.31 $\pm$ 13.72, 106.34 $\pm$ 25.82. ALT and AST in the PQ + curcumin group reached the peak on the 3rd day and then decreased. The ALT and AST levels of the PQ + curcumin group were lower than those of PQ group at the three time-points on day 1, 3 and 7, and the difference was statistically significant (P<0.05).

**ROS level in the liver.** The level of ROS was an indicator of oxidative stress and liver injury in rats. The results showed

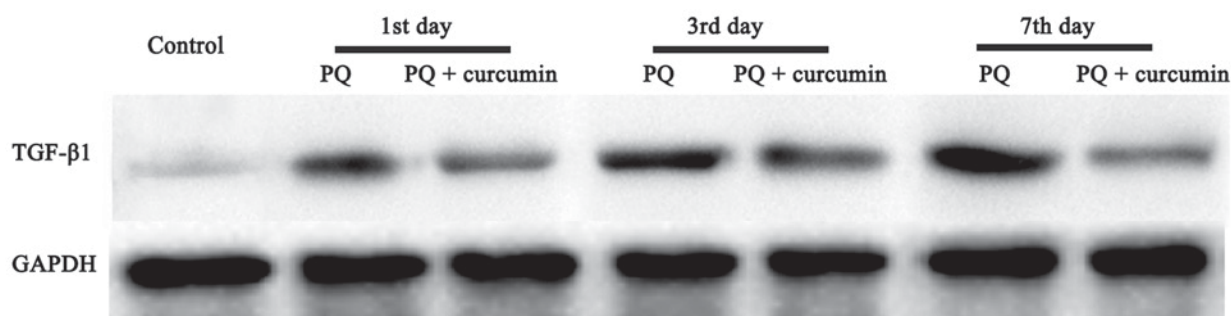


Figure 3. Detection of TGF- $\beta$ 1 protein content in liver tissue by western blot analysis.

Table II. Liver function of rats (mean  $\pm$  SD, U/l).

Group	Time	ALT	AST
Control	1st	26.86 $\pm$ 2.59	33.36 $\pm$ 3.06
	3rd	27.37 $\pm$ 2.36	32.51 $\pm$ 4.76
	7th	26.04 $\pm$ 2.94	36.24 $\pm$ 5.33
PQ	1st	37.50 $\pm$ 5.72 <sup>a</sup>	57.36 $\pm$ 6.45 <sup>a</sup>
	3rd	63.88 $\pm$ 12.67 <sup>b</sup>	83.45 $\pm$ 18.39 <sup>b</sup>
	7th	87.31 $\pm$ 13.72 <sup>b</sup>	106.34 $\pm$ 25.82 <sup>c</sup>
PQ + curcumin	1st	33.49 $\pm$ 7.45 <sup>d</sup>	40.66 $\pm$ 25.82 <sup>d</sup>
	3rd	47.04 $\pm$ 15.36 <sup>d</sup>	57.81 $\pm$ 11.05 <sup>e</sup>
	7th	36.52 $\pm$ 12.32 <sup>e</sup>	46.34 $\pm$ 8.37 <sup>f</sup>

<sup>a</sup>P<0.05, <sup>b</sup>P<0.01, <sup>c</sup>P<0.001 compared with the control group. <sup>d</sup>P<0.05, <sup>e</sup>P<0.01, <sup>f</sup>P<0.0001 compared with the PQ group. PQ, paraquat; ALT, alanine aminotransferase; AST, aspartate aminotransferase.

Table III. Rat oxidative stress (mean  $\pm$  SD).

Group	Time	MDA (mmol/l)	SOD ( $\times 10^3$ U/l)
Control	1st	0.42 $\pm$ 0.07	167.03 $\pm$ 11.42
	3rd	0.41 $\pm$ 0.06	168.71 $\pm$ 10.85
	7th	0.47 $\pm$ 0.09	165.33 $\pm$ 11.97
PQ	1st	2.58 $\pm$ 0.83 <sup>a</sup>	123.50 $\pm$ 21.86 <sup>a</sup>
	3rd	4.57 $\pm$ 2.74 <sup>b</sup>	105.36 $\pm$ 26.63 <sup>b</sup>
	7th	7.76 $\pm$ 3.12 <sup>b</sup>	94.43 $\pm$ 37.74 <sup>b</sup>
PQ + curcumin	1st	1.04 $\pm$ 0.72 <sup>c</sup>	138.72 $\pm$ 12.94 <sup>c</sup>
	3rd	2.12 $\pm$ 0.87 <sup>c</sup>	117.40 $\pm$ 28.08 <sup>c</sup>
	7th	1.45 $\pm$ 0.39 <sup>c</sup>	146.31 $\pm$ 21.65 <sup>d</sup>

<sup>a</sup>P<0.05, <sup>b</sup>P<0.01 compared with the control group. <sup>c</sup>P<0.05, <sup>d</sup>P<0.01 compared with PQ group. PQ, paraquat; MDA, malondialdehyde; SOD, superoxide dismutase.

that compared with the control group, ROS in the liver of PQ rats continued to increase after poisoning (P<0.05). ROS in the PQ + curcumin group reached the peak on the 3rd day, and then decreased. Curcumin treatment significantly reduced the level of ROS (P<0.05) (Fig. 4).

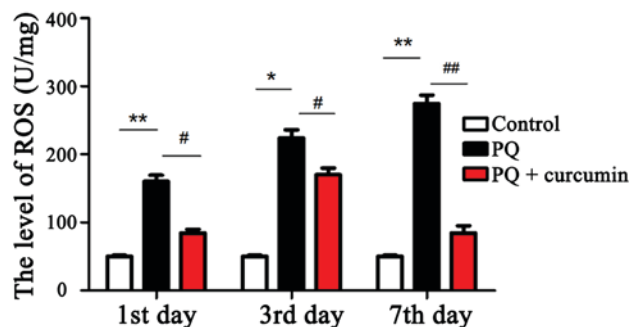


Figure 4. Rat liver ROS level. \*P<0.05, \*\*P<0.01 compared with the control group. #P<0.05, ##P<0.01 compared with the PQ group. ROS, reactive oxygen species; PQ, paraquat.

**MDA and SOD levels in the liver.** MDA and SOD were used as indicators of oxidative stress. The results (Table III) showed that compared with the control group, the levels of MDA in the PQ group were increased and the levels of SOD were decreased (P<0.05). The levels of MDA in PQ + curcumin group increased first and then decreased, and the level of SOD decreased first and then increased. For the PQ + curcumin group, the level of MDA was lower than that in PQ group at the three time-points (P<0.05), and the level of SOD was higher than that in PQ group (P<0.05).

## Discussion

The important mechanism of PQ toxicity in different experimental models (including plants, bacteria and animals) is oxidative stress (17). Antioxidants have become potential therapeutic agents. In the rat model, antioxidants were able to prevent oxidative stress-induced lipid peroxidation cell damage caused by PQ, interstitial edema and inflammatory cell infiltration (18). In this experiment, the extract of turmeric rhizome-curcumin, a low molecular weight polyphenol substance, was selected. It is the most active component of turmeric (19). It is reported that it has good anti-inflammatory, antitumor and antioxidant properties. Jha and Mishra found that curcumin nasal administration can effectively remove free radicals and inhibit lipid peroxidation (20).

SOD is the scavenger for various oxygen free radicals in the body; it can act by catalyzing the disproportional free radicals in organisms, including superoxide radicals, hydroxyl radicals and lipid peroxides (21). MDA is the terminal product of lipid peroxidation (22). The oxidative stress markers were measured

at different time-points to evaluate the antioxidant activity of curcumin. The results showed that curcumin treatment significantly increased SOD activity in rats and significantly decreased MDA levels. TGF- $\beta$ 1, as an important member of the transforming growth factor superfamily, plays an important role in promoting hepatic steatosis, hepatocyte injury, inflammatory cell infiltration, inflammatory cytokine production, HSC activation and fibrosis (23,24). More importantly, literature demonstrates that TGF- $\beta$ 1 signaling is involved in ROS production and lipid accumulation (25). TGF- $\beta$  signaling pathway is involved in the expression of fat and fatty acid  $\beta$  antioxidant genes, leading to the synthesis of triglycerides and the accumulation of hepatocyte lipids (26). In the case of further accumulation of lipids, TGF- $\beta$ 1 induces cell death through NF- $\kappa$ B/TAK1 pathway and mediates the production of reactive oxygen species (27). In addition, TGF- $\beta$ 1 affects the expression of various inflammatory factors through the oxidative stress pathway (28). Li *et al* found that oxidative stress and cell membrane lipid peroxidation are one of the mechanisms by which PQ causes lung injury. Curcumin reduces the extent of lung injury by preventing this process (29). Li *et al* studied the effects of different concentrations of PQ on serum inflammation-related cytokines, and they found that curcumin could reduce the level of serum inflammatory response in rats to improve lung pathological changes (30). Han *et al* reported that curcumin increased the activity of HO-1, NQO-1, SOD and CAT and induced the antioxidant capacity of liver cells by inducing the expression of Nrf2 (31). However, these studies were mainly focused on the mechanism of PQ-induced lung injury. The protective effects of curcumin on liver injury induced by PQ, and the involvement of TGF- $\beta$ 1 in this process remains to be further studied.

In the present study, we used RT-qPCR and western blot analysis to detect the dynamic changes of TGF- $\beta$ 1 in rat liver tissue after PQ exposure. The results showed that mRNA and protein levels of TGF- $\beta$ 1 in the liver of PQ poisoned rats tended to increase continuously. However, the mRNA and protein levels of TGF- $\beta$ 1 in liver decreased significantly after a 3-day intervention with curcumin. H&E staining was used to detect the changes of liver histomorphology at different time-points after PQ treatment in rats. H&E staining showed that for the PQ-poisoned rats, obvious fatty degeneration was observed in the liver on the 3rd day; and large number of cavities appeared on the 7th day due to necrosis. In PQ + curcumin group, there was no significant change in liver on the 1st day, hepatocyte edema appeared on the 3rd day, and mild hepatocyte edema appeared on the 7th day. In addition, curcumin can improve acute liver injury caused by PQ poisoning, by reducing AST and ALT activity.

These results indicate that TGF- $\beta$ 1 plays an important role in PQ-induced liver injury. Curcumin can effectively inhibit the expression of TGF- $\beta$ 1, prevent PQ-induced oxidative damage of liver cells and protect liver function.

#### Acknowledgements

Not applicable.

#### Funding

No funding was received.

#### Availability of data and materials

The datasets used and/or analyzed during the present study are available from the corresponding author on reasonable request.

#### Authors' contributions

HC conceived and designed the study, and drafted the manuscript. HC and XF collected the data and were responsible for RT-qPCR and western blot analysis. Both authors read and approved the final manuscript.

#### Ethics approval and consent to participate

The study was approved by the Ethics Committee of Gansu Provincial People's Hospital (Lanzhou, China).

#### Patient consent for publication

Not applicable.

#### Competing interests

The authors declare that they have no competing interests.

#### References

1. Wesseling C, van Wendel de Joode B, Ruepert C, León C, Monge P, Hermosillo H and Partanen TJ: Paraquat in developing countries. *Int J Occup Environ Health* 7: 275-286, 2001.
2. Baltazar T, Dinis-Oliveira RJ, Duarte JA, de Lourdes Bastos M and Carvalho F: Paraquat research: Do recent advances in limiting its toxicity make its use safer? *Br J Pharmacol* 168: 44-45, 2013.
3. Ortiz-Ortiz MA, Morán JM, Ruiz-Mesa LM, Bonmatty RG and Fuentes JM: Protective effect of the glial cell line-derived neurotrophic factor (GDNF) on human mesencephalic neuron-derived cells against neurotoxicity induced by paraquat. *Environ Toxicol Pharmacol* 31: 129-136, 2011.
4. Djukic MM, Jovanovic MD, Ninkovic M, Stevanovic I, Ilic K, Curcic M and Vekic J: Protective role of glutathione reductase in paraquat induced neurotoxicity. *Chem Biol Interact* 199: 74-86, 2012.
5. Dinis-Oliveira RJ, Remião F, Carmo H, Duarte JA, Navarro AS, Bastos ML and Carvalho F: Paraquat exposure as an etiological factor of Parkinson's disease. *Neurotoxicology* 27: 1110-1122, 2006.
6. Suntres ZE: Role of antioxidants in paraquat toxicity. *Toxicology* 180: 65-77, 2002.
7. Berry C, La Vecchia C and Nicotera P: Paraquat and Parkinson's disease. *Cell Death Differ* 17: 1115-1125, 2010.
8. Kral AH, Malekinejad M, Vaudrey J, Martinez AN, Lorvick J, McFarland W and Raymond HF: Comparing respondent-driven sampling and targeted sampling methods of recruiting injection drug users in San Francisco. *J Urban Health* 87: 839-850, 2010.
9. Aggarwal BB and Harikumar KB: Potential therapeutic effects of curcumin, the anti-inflammatory agent, against neurodegenerative, cardiovascular, pulmonary, metabolic, autoimmune and neoplastic diseases. *Int J Biochem Cell Biol* 41: 40-59, 2009.
10. Ishrat T, Hoda MN, Khan MB, Yousuf S, Ahmad M, Khan MM, Ahmad A and Islam F: Amelioration of cognitive deficits and neurodegeneration by curcumin in rat model of sporadic dementia of Alzheimer's type (SDAT). *Eur Neuropsychopharmacol* 19: 636-647, 2009.
11. Abdesslem M, Ramodiharilafy R, Devys L, Gacoin T, Alexandrou A and Bouzigues CI: Fast quantitative ROS detection based on dual-color single rare-earth nanoparticle imaging reveals signaling pathway kinetics in living cells. *Nanoscale* 9: 656-665, 2017.

12. Kim JY, Choi WI, Kim YH and Tae G: Highly selective in-vivo imaging of tumor as an inflammation site by ROS detection using hydrocyanine-conjugated, functional nano-carriers. *J Control Release* 156: 398-405, 2011.
13. Chan MS, Xu D, Guo L, Tam DY, Liu LS, Chen Y, Wong MS and Lo PK: Cyanine fluorophores for cellular protection against ROS in stimulated macrophages and two-photon ROS detection. *Org Biomol Chem* 13: 7307-7312, 2015.
14. Zhang H, Cao Y, Chen Y, Li G and Yu H: Apatinib promotes apoptosis of the SMMC-7721 hepatocellular carcinoma cell line via the PI3K/Akt pathway. *Oncol Lett* 15: 5739-5743, 2018.
15. Li S and Wei Y: Association of HMGB1, BRCA1 and P62 expression in ovarian cancer and chemotherapy sensitivity. *Oncol Lett* 15: 9572-9576, 2018.
16. Zhang C, Wang YQ, Jin G, Wu S, Cui J and Wang RF: Selection of reference genes for gene expression studies in human bladder cancer using SYBR-Green quantitative polymerase chain reaction. *Oncol Lett* 14: 6001-6011, 2017.
17. Soares JJ, Rodrigues DT, Gonçalves MB, Lemos MC, Gallarreta MS, Bianchini MC, Gayer MC, Puntel RL, Roehrs R and Denardin ELG: Paraquat exposure-induced Parkinson's disease-like symptoms and oxidative stress in *Drosophila melanogaster*: Neuroprotective effect of *Bougainvillea glabra* Choisy. *Biomed Pharmacother* 95: 245-251, 2017.
18. Singh S and Aggarwal BB: Activation of transcription factor NF- $\kappa$ B is suppressed by curcumin (diferuloylmethane) [corrected]. *J Biol Chem* 270: 24995-25000, 1995.
19. Anand P, Kunnumakkara AB, Newman RA and Aggarwal BB: Bioavailability of curcumin: Problems and promises. *Mol Pharm* 4: 807-818, 2007.
20. Jha NS and Mishra S: Antioxidant activity and electrochemical elucidation of the enigmatic redox behavior of curcumin and its structurally modified analogues. *Electrochim Acta* 151: 574, 2015.
21. Su X, He Y, Yang W, Wang Y, Zhang W and Wang Y: Effect of Dan Hong injection on PON1, SOD activity and MDA levels in elderly patients with coronary heart disease. *Int J Clin Exp Med* 7: 5886-5889, 2014.
22. Kassim SK, Kamal S, Shehata HH, Salib MM, Louka M, Sallam M and Nabegh LM: Evaluation of serum fibrotic markers; CTGF, IL-17 and TGF- $\beta$ 1 versus liver biopsy for detection of hepatic fibrosis in Egyptian patients with chronic hepatitis. *Meta Gene* 13: 63-69, 2017.
23. Xu MY, Hu JJ, Shen J, Wang ML, Zhang QQ, Qu Y and Lu LG: Stat3 signaling activation crosslinking of TGF- $\beta$ 1 in hepatic stellate cell exacerbates liver injury and fibrosis. *Biochim Biophys Acta* 1842: 2237-2245, 2014.
24. Li Y, Kim BG, Qian S, Letterio JJ, Fung JJ, Lu L and Lin F: Hepatic stellate cells inhibit T cells through active TGF- $\beta$ 1 from a cell surface-bound latent TGF- $\beta$ 1/GARP complex. *J Immunol* 195: 2648-2656, 2015.
25. Liu YN, Zha WJ, Ma Y, Chen FF, Zhu W, Ge A, Zeng XN and Huang M: Galangin attenuates airway remodelling by inhibiting TGF- $\beta$ 1-mediated ROS generation and MAPK/Akt phosphorylation in asthma. *Sci Rep* 5: 11758, 2015.
26. Wu J, Niu J, Li X, Wang X, Guo Z and Zhang F: TGF- $\beta$ 1 induces senescence of bone marrow mesenchymal stem cells via increase of mitochondrial ROS production. *BMC Dev Biol* 14: 21, 2014.
27. Tang H, Gao L, Mao J, He H, Liu J, Cai X, Lin H and Wu T: Salidroside protects against bleomycin-induced pulmonary fibrosis: Activation of Nrf2-antioxidant signaling, and inhibition of NF- $\kappa$ B and TGF- $\beta$ 1/Smad-2/-3 pathways. *Cell Stress Chaperones* 21: 239-249, 2016.
28. Wang JZ, Fang XT, Lv E, Yu F, Wang ZW and Song HX: TGF- $\beta$ 1 related inflammation in the posterior longitudinal ligament of cervical spondylotic myelopathy patients. *Int J Clin Exp Med* 8: 2233-2239, 2015.
29. Li H, Liu B, Li P, Feng L, Ma H, Xuan S and Cao Y: Inhibitory effects of curcumin on inflammatory cytokines in rats with paraquat poisoning. *Zhonghua Lao Dong Wei Sheng Zhi Ye Bing Za Zhi* 33: 689-692, 2015 (In Chinese).
30. Li H, Cao Y, Liu B, Feng L and Li P: Antagonistic effect of curcumin on lipid peroxidation of rats poisoned by paraquat. *Zhonghua Lao Dong Wei Sheng Zhi Ye Bing Za Zhi* 33: 609-611, 2015 (In Chinese).
31. Han W, Wu D, Liu H, Lu Y, Wang L, Hong G, Qiu Q and Lu Z: Curcumin alleviated liver oxidative stress injury of rat induced by paraquat. *Zhonghua Lao Dong Wei Sheng Zhi Ye Bing Za Zhi* 32: 352-356, 2014 (In Chinese).



This work is licensed under a Creative Commons Attribution-NonCommercial-NoDerivatives 4.0 International (CC BY-NC-ND 4.0) License.