

Available online at [www.sciencedirect.com](http://www.sciencedirect.com)

ScienceDirect

journal homepage: [www.elsevier.com/locate/radcr](http://www.elsevier.com/locate/radcr)

## Case Report

# Autoamputated pharyngeal hairy polyp presented with aero-digestive obstruction: A case report ☆☆☆

Ali K. Algaberi, MD<sup>a</sup>, Mortada A. Alhwish, MD<sup>b</sup>, Sultan Abdulwadoud Alshoabi, MD<sup>c,\*</sup>, Fahad H. Alhazmi, PhD<sup>c</sup>, Kamal D. Alsultan, PhD<sup>c</sup>, Abdullgabbbar M. Hamid, MD<sup>d</sup>

<sup>a</sup> Department of Radiology, Alsafwa General Hospital, Taiz, YEM

<sup>b</sup> Department of Pediatric, Alsafwa General Hospital, Taiz, YEM

<sup>c</sup> Department of Diagnostic Radiology Technology, College of Applied Medical sciences, Taibah University, Almadinah Almunawwarah, KSA

<sup>d</sup> Department of Radiology, Rush University Medical Center, Chicago, IL

## ARTICLE INFO

## Article history:

Received 11 March 2021

Revised 26 March 2021

Accepted 28 March 2021

## Keywords:

Pharyngeal hairy polyp

Neonate

Respiratory distress

Computed tomography

Autoamputation

## ABSTRACT

A pharyngeal hairy polyp (HP) is a rare benign mass that can be surgical detached with few complications. In this report, we describe a hairy polyp in a 7-day-old neonate presented with intermittent respiratory distress and feeding difficulties since birth. Neck computed tomography was performed, and demonstrated a well-defined pedunculated heterogeneous mass arising from the right lateral wall of the nasopharynx extending downward and nearly completely obstructing of the nasopharynx and oropharynx. The central part of the mass was found relatively dense surrounded by low attenuation fatty components with enhancement of the outer wall of the mass. The provisional diagnosis was pharyngeal HP. After autoamputation at the seventh day old, HP was analyzed via histopathology examination that showed a mixture of various ectodermal and mesodermal tissues including skin, cartilage, adipose and fibrous tissue. The patient fully recovered with no residual clinical features. We report this case to elucidate the possibility of this strange behavior of pharyngeal HP.

© 2021 The Authors. Published by Elsevier Inc. on behalf of University of Washington.

This is an open access article under the CC BY-NC-ND license

(<http://creativecommons.org/licenses/by-nc-nd/4.0/>)

## Introduction

Hairy polyp (HP) or bigerminal choristomas is a rare developmental malformation of the oronasopharyngeal epithelium,

which derived from the two germinal layers: ectoderm and mesoderm [1,2]. It is the most common congenital deformity of the oropharynx, nasopharynx and oral cavity in infants which arises from the torus tubarius, lateral aspect of the soft palate, or from the pharyngeal wall [3]. It occurs in newborns,

☆ Acknowledgement: This research did not receive any specific grant from funding agencies in the public, commercial, or not for-profit sectors. The authors would like to thank Dr. Galal Almasri and Aden diagnostic center for histopathology examination and report for this case.

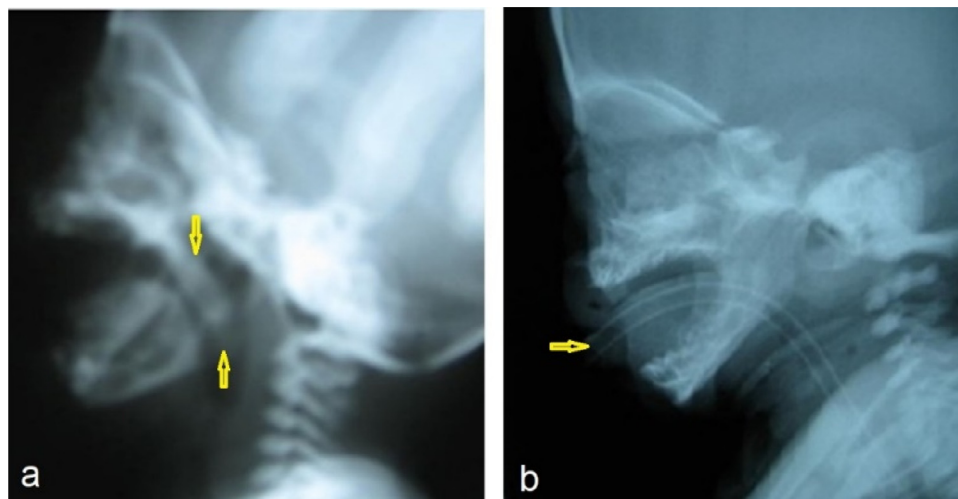
☆☆ Competing interests: None.

\* Corresponding author.

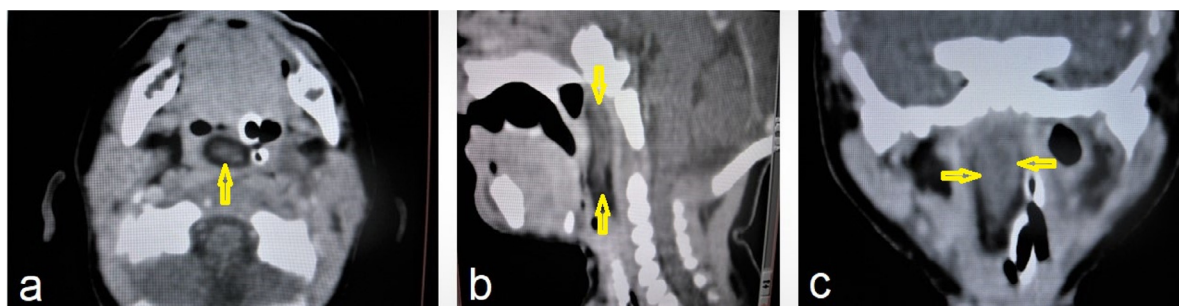
E-mail address: [alshoabisultan@yahoo.com](mailto:alshoabisultan@yahoo.com) (S.A. Alshoabi).

<https://doi.org/10.1016/j.radcr.2021.03.066>

1930-0433/© 2021 The Authors. Published by Elsevier Inc. on behalf of University of Washington. This is an open access article under the CC BY-NC-ND license (<http://creativecommons.org/licenses/by-nc-nd/4.0/>)



**Fig. 1** – Plain X-ray of the neck shows a) a well-defined pedunculated soft tissue mass in the pharynx (arrows), b) endotracheal tube inserted through the mouth to maintain an open airway (arrow).



**Fig. 2** – Selected images of neck computed tomography a) axial section, b) sagittal, and c) coronal reconstructions shows about 35 × 15 mm well-defined pedunculated soft tissue mass in the pharynx (arrows) probably arise from the right lateral wall of the nasopharynx and extends into the hypopharynx.

infants and even small children more likely in females. It is one of the unusual causes of respiratory distress in neonates, and the clinical manifestations vary regarding to tumor size and site and ranging from acute respiratory distress to snoring and slow weight gain [1–3]. On medical imaging, it appears as a pedunculated polyp of fat-density with skin, cartilage and fibrous tissues on Computed Tomography (CT) and Magnetic Resonance Imaging (MRI) [3].

In the literature, case reports of pharyngeal hairy polyps are rare and reports of autoamputation of this polyp is an extremely rare entity. Herein, we report a very rare case of HP in a neonate presented with acute respiratory distress. The novelty of this case is the autoamputation of the polyp and spontaneous recovery of the symptoms on the seventh day after birth.

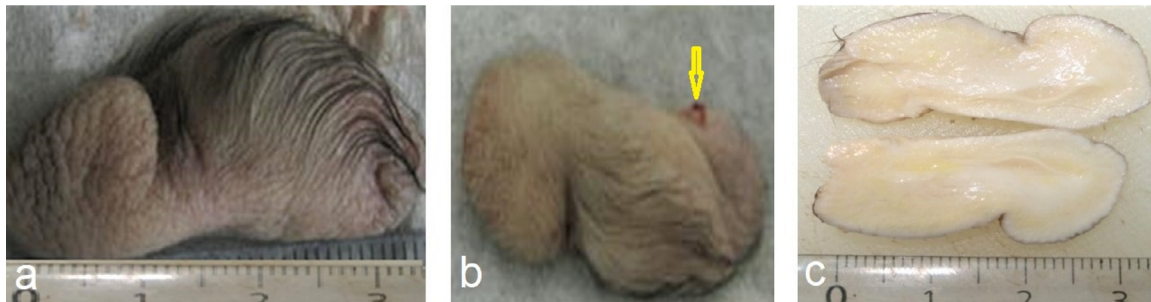
### Case report

A 7-day-old male neonate presented with difficulties in breathing and feeding as well as intermittent cyanosis since birth. The

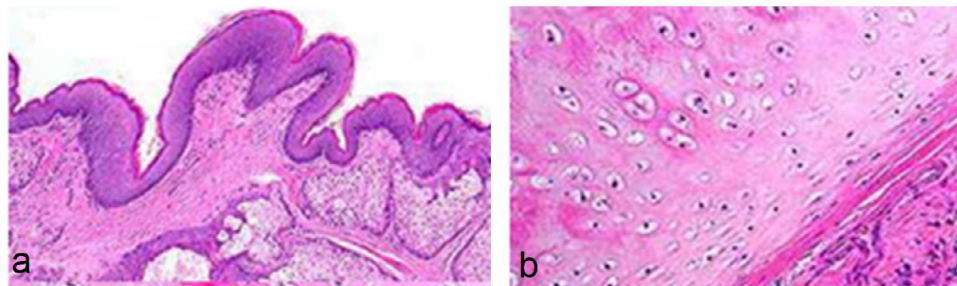
neonate was born full term by normal delivery of a thirty-two-year-old healthy mother. During pregnancy, the mother noted more enlargement of her abdomen in comparison to her previous normal pregnancy, however antenatal ultrasonography was not performed at this stage. No history of maternal illness, drug ingestion or radiation exposure during pregnancy. The parents have first degree consanguinity, otherwise no family history of gross congenital anomalies was reported.

On the second day postnatal, the child was irritable with frequent sneeze, difficulty in breathing and feeding that progressively induced by feeding and sleeping. On the sixth day, the symptoms were augmented with intermittent attacks of cyanosis, and the neonate was admitted to the hospital.

On the examination day, the neonate was irritable, tachypnoic, nasal flaring, grunting, suprasternal muscle retraction with central cyanosis. Lateral cervical x-ray showed a soft tissue mass in the nasopharynx (Fig. 1a). Endotracheal tube (ETT) was inserted through oral cavity mouth to maintain open airway (Fig. 1b). Nasogastric tube (NGT) was inserted through the left nostril with resistance in the nasopharynx into the stomach to maintain feeding.



**Fig. 3 – Gross specimen of 35 × 15 mm auto amputated pharyngeal polyp a) covered with hairy skin, b) shows pedicle attachment (arrow), and c) smooth yellowish- white soft tissue with streaks of cartilage inside.**



**Fig. 4 – Histopathological microscopic images with hematoxylin and eosin (H&E) stain show a mixture of various ectodermal and mesodermal tissues including a) skin and subcutaneous adnexa (H&E stain × 10), b) cartilage, in addition the images show fibrous and mature adipose tissue (H&E stain × 20).**

A neck CT was performed for the neonate patient, which demonstrated a well-defined pedunculated heterogeneous mass that was probably arising from the right lateral wall of the nasopharynx (Fig. 2a), extending through the oropharynx into the hypopharynx (Fig. 2b). The mass was nearly completely obstructing the nasopharynx and oropharynx, and deviated the ETT and the NGT to the left side with no intracranial connection (Fig. 2c). The central part of the mass was found relatively dense surrounded by low attenuation fatty components with enhancement of the outer wall of the mass with no calcification, no obvious lymphadenopathy. Then, the neonate patient was planned for surgery.

One day before operation, the patient had recurrent vomiting and a gray oval shape polypoid mass of 35 × 15 mm covered by hair was seen in the vomitus materials (Fig. 3). The neonate patient case improved, and the samples were sent for histopathology examination. Histopathology analysis reported a mixture of various ectodermal and mesodermal tissues including skin, cartilage, adipose and fibrous tissue (Fig. 4). On the follow up day, the neonate patient was recovered with no residual clinical features.

## Discussion

HP is a rare lesion of bigerminous origin that contains elements arise from both ectoderm and mesoderm layers, and also called dermoid polyp or teratoid polyp [4]. Sheng et al. reported that HPs arise from the left side more likely than

the right side of the pharynx and, in females more likely than males [3]. In contrast, the lesion in our patient arises from the right side of the pharynx and in a male patient. This is consistent with Dutta et al. who reported that female predominance of HP has been found to be an overestimation [5].

Medical imaging is essential to localize the origin, intracranial extension and contents of the HP. In the current case, CT showed a well-defined pedunculated heterogeneous mass arising from the right lateral wall of the nasopharynx. The lesion showed hyperdense central part with low attenuation fatty components but no calcification, no components of brain tissue with no intracranial extension and only slight peripheral enhancement after contrast administration. CT findings were consistent with the contents of dermoid cyst as reported in a previous study by Wagner et al. who had differentiated this lesion from sphenoidal meningoencephalocele, heterotopic neural tissue, and other possible differential diagnoses such as glioma and craniopharyngioma [6].

In a previous review, Sheng et al. reported that all of pharyngeal HP were well-circumscribed pedunculated with high signal intensity on both T1-weighted images and T2-weighted images of MRI with loss of signal on fat suppression sequences with no contrast enhancement that represents fat contents of the tumor [3].

In our case, histopathology showed a mixture of various ectodermal and mesodermal tissues including skin, cartilage, adipose and fibrous tissue. This is consistent with multiple previous studies reported that HPs consist of fibrous adipose tissues with cartilage, muscle, bone and skin with hair follicles and sebaceous glands [3,7].

Ultimately, HP is usually cured with complete surgical excision of the tumour at its base as reported by Lignitz et al. [8]. However, we found five case studies reported HP cases with autoamputation in the literature [9–13].

As far as we know, this is the sixth reported case of HP with autoamputation. Autoamputation was explained by torsion of the mass with ischemic necrosis [9]. This may probably have induced by the insertion of the ETT and NGT. This strange complication is still ambiguous and recommended as a topic for further future studies.

## Conclusion

Pharyngeal HP is a rare benign pedunculated mass consists of a mixture of ectodermal and mesodermal tissues that can present early in neonates with respiratory distress and feeding difficulties. It can be diagnosed via CT and MRI, and analysed via histopathology examination. Complete surgical excision might be the optimal treatment of choice. However, autoamputation may cause few possible complications that were reported in some cases.

## Authors contribution

AKA collected and organized data. MAA provided research materials. SAA wrote the initial and final draft of article. FHA revised the manuscript and edited language. KDA revised the manuscript. AMH analysed and interpreted data. All authors have critically reviewed and approved the final draft and are responsible for the content and similarity index of the manuscript.

## Patient consent

Informed consent has been taken from the parents to publish this case and images.

## REFERENCES

- [1] Teng Y, Xian Z, Han S, Liang Z, Pan H, Li L. Pharyngeal hairy polyps: Case series and literature review. *Medicine* (Baltimore). 2019;98(5):e14305. doi:10.1097/MD.00000000000014305.
- [2] Feraco P, Bragantini E, Incandela F, Gagliardo C, Silvestrini M. Oropharyngeal Hairy Polyp: A Case of respiratory failure in a newborn. *Diagnostics (Basel)* 2020;10(7):465. doi:10.3390/diagnostics10070465.
- [3] Sheng M, Mi Y, Gao F, Liang J, Zhou H. Imaging features of pharyngeal hairy polyps in infants. *Oral Radiol* 2021;37(1):95–100. doi:10.1007/s11282-020-00430-5.
- [4] Olivares-Pakzad BA, Tazelaar HD, Dehner LP, Kasperbauer JL, Bite U. Oropharyngeal hairy polyp with meningotheelial elements. *Oral Surg Oral Med Oral Pathol Oral Radiol Endod.* 1995;79(4):462–8. doi: 10.1016/s1079-2104(05)80129-5.
- [5] Dutta M, Roy S, Ghatak S. Naso-oropharyngeal choristoma (hairy polyps): an overview and current update on presentation, management, origin and related controversies. *Eur Arch Otorhinolaryngol* 2015;272:1047–59. doi:10.1007/s00405-014-3050-2.
- [6] Wagner MW, Haileselassie B, Kannan S, et al. Oropharyngeal dermoid cyst in an infant with intermittent airway obstruction. A case report. *Neuroradiol J* 2014;27(5):627–31. doi:10.15274/NRJ-2014-10085.
- [7] Freni F, Nicastro V, Costanzo D, Zagaria A, Galletti B. Nasopharynx hairy polyp as a cause of stridor in newborn. *J Craniofac Surg* 2020;31(6):e572–4. doi:10.1097/SCS.00000000000006576.
- [8] Lignitz S, Haug V, Siegmund B, Mann WJ, Coerdt W, Mildenerberger E. Intermittent dyspnea and cyanosis in a newborn caused by a hairy polyp. *Pediatr Neonatol* 2014;55(3):231–2 Jun. doi:10.1016/j.pedneo.2013.07.009.
- [9] Cheriatu JJ, Mohamed K, D'souza IE, Shamseldeen M. Autoamputation of congenital hairy polyp in neonate with stridor and respiratory failure. *Webmed Central PAEDIATRICS* 2012;3(5):WMC003379.
- [10] Unal S, Eker S, Kibar AE, Savas T, Han U, Basri H. Autoamputation of a pharyngeal hairy polyp in a neonate with intermittent respiratory distress. *International Journal of Pediatric Otorhinolaryngology Extra* 2008;3(2):90–3. doi:10.1016/j.pedex.2007.11.004.
- [11] De Caluwé D, Kealey SM, Hayes R, Puri P. Autoamputation of a congenital oropharyngeal hairy polyp. *Pediatr Surg Int* 2002;18(5-6):548–9. doi:10.1007/s00383-002-0814-3.
- [12] D'Andrea LA. Pathological case of the month. Benign pharyngeal hamartomatous polyp in a neonate with stridor. *Arch Pediatr Adolesc Med* 1998;152(1):93–4. doi:10.1001/archpedi.152.1.93.
- [13] İnce D, Turan Ö, Gemici HB, Erdoğan Ş, Çakır Ç. Congenital hairy polyp and autoamputation in an infant with acute otitis media. *Turk J Pediatr* 2014;56(3):324–6.

[1] Teng Y, Xian Z, Han S, Liang Z, Pan H, Li L. Pharyngeal hairy polyps: Case series and literature review. *Medicine*