



Feline dry eye syndrome of presumed neurogenic origin: a case report

Lionel Sebbag^{1,2}, Patricia A Pesavento³,
 Sebastian E Carrasco³, Christopher M Reilly^{3,4}
 and David J Maggs⁵

Journal of Feline Medicine and Surgery Open Reports
 1–7

© The Author(s) 2017

Reprints and permissions:

sagepub.co.uk/journalsPermissions.nav

DOI: 10.1177/2055116917746786

journals.sagepub.com/home/jfmsopenreports

This paper was handled and processed
 by the American Editorial Office (AAFP)
 for publication in *JFMS Open Reports*



Abstract

Case summary A 14-year-old female spayed Abyssinian cat, which about 1 year previously underwent thoracic limb amputation, radiotherapy and chemotherapy for an incompletely excised vaccine-related fibrosarcoma, was presented for evaluation of corneal opacity in the left eye (OS). The ocular surface of both eyes (OU) had a lackluster appearance and there was a stromal corneal ulcer OS. Results of corneal aesthesiometry, Schirmer tear test-1 (STT-1) and tear film breakup time revealed corneal hypoesthesia, and quantitative and qualitative tear film deficiency OU. Noxious olfactory stimulation caused increased lacrimation relative to standard STT-1 values suggesting an intact nasolacrimal reflex. Various lacrimostimulants were administered in succession; namely, 1% pilocarpine administered topically (15 days) or orally (19 days), and topically applied 0.03% tacrolimus (47 days). Pilocarpine, especially when given orally, was associated with notable increases in STT-1 values, but corneal ulceration remained/recurred regardless of administration route, and oral pilocarpine resulted in gastrointestinal upset. Tacrolimus was not effective. After 93 days, the cat became weak and lame and a low thyroxine concentration was detected in serum. The cat was euthanized and a necropsy performed. Both lacrimal glands were histologically normal, but chronic neutrophilic keratitis and reduced conjunctival goblet cell density were noted OU.

Relevance and novel information The final diagnosis was dry eye syndrome (DES) of presumed neurogenic origin, associated with corneal hypoesthesia. This report reinforces the importance of conducting tearfilm testing in cats with ocular surface disease, as clinical signs of DES were different from those described in dogs.

Accepted: 8 November 2017

Introduction

Dry eye syndrome (DES), characterized by decreased aqueous tear production, is common in companion animals.¹ Although little is known about feline DES, the condition is well described in dogs where reported causes include immune-mediated dacryoadenitis, congenital glandular aplasia/hypoplasia, and drug-induced or neurogenic glandular dysfunction.¹ Neurogenic DES may result from dysfunction of afferent (trigeminal nerve) and/or efferent (parasympathetic/sympathetic) innervation of the lacrimal glands but is primarily associated with parasympathetic dysfunction in dogs.² To our knowledge, neurogenic DES has been reported only in cats with dysautonomia.³ The purpose of this report is to describe a case of feline neurogenic DES not associated with dysautonomia, and to detail clinicopathologic findings, diagnostic test results and response to therapy.

¹Veterinary Medical Teaching Hospital, School of Veterinary Medicine, University of California–Davis, Davis, CA, USA

²Department of Veterinary Clinical Sciences, Iowa State University College of Veterinary Medicine, Ames, IA, USA

³Department of Pathology, Microbiology and Immunology, School of Veterinary Medicine, University of California–Davis, Davis, CA, USA

⁴Insight Veterinary Specialty Pathology, Austin, TX, USA

⁵Department of Surgical and Radiological Sciences, School of Veterinary Medicine, University of California–Davis, Davis, CA, USA

Corresponding author:

Lionel Sebbag Dr Med Vet, Lloyd Veterinary Medical Center, Iowa State University College of Veterinary Medicine, Ames, IA, USA
 Email: lsebbag@iastate.edu



Creative Commons Non Commercial CC BY-NC: This article is distributed under the terms of the Creative Commons

Attribution-NonCommercial 4.0 License (<http://www.creativecommons.org/licenses/by-nc/4.0/>) which permits non-commercial use, reproduction and distribution of the work without further permission provided the original work is attributed as specified on the SAGE and Open Access pages (<https://us.sagepub.com/en-us/nam/open-access-at-sage>).

Case description

A 13-year-old female spayed Abyssinian cat (3.5 kg) was evaluated for incompletely excised grade II thoracic wall fibrosarcoma caudal to the right scapula, presumed to be vaccine-associated. Results of complete blood count, serum biochemistry and urinalysis were within normal limits. Feline immunodeficiency virus and feline leukemia virus test results were negative (SNAP FeLV/FIV Combo; IDEXX). Evidence of tumor metastasis was not detected on thoracic radiographs or abdominal ultrasound. Complete amputation of the right forelimb was performed, followed by radiotherapy (54 Gy fractionated over 18 sessions of 3 Gy within 3 weeks) and doxorubicin chemotherapy (four doses of 18–20 mg/m² given IV 3 weeks apart). Other than localized alopecia at the radiation site, adverse effects were not noted.

One year later (day 0), the cat was re-presented for evaluation of a 1 week history of corneal opacity in the left eye (OS). Medications at that time included L-lysine (500 mg PO q12h); terbutaline (0.625 mg PO q12h) and prednisolone (2.5 mg PO q48h) for asthma; tramadol (12.5 mg PO as needed) for arthritis; and ondansetron (2 mg PO q24h as needed) for inappetence. Menace response was intact in both eyes (OU). Dazzle and palpebral reflexes, oculocephalic reflex, and direct and consensual pupillary light reflexes were all normal OU. Both eyes were open with subtle crusted discharge at the medial canthi. The eyelids and meibomian gland profiles and orifices were normal OU. The surface of the right eye (OD) had a lackluster appearance with a 4 mm diameter region of mild superficial fibrosis in the axial cornea, which did not retain fluorescein. There was mild nuclear sclerosis OD. The ocular surface OS had a lackluster appearance and mild diffuse conjunctival hyperemia. There was a 5 mm diameter, vascularized, poorly demarcated circular ulcer with approximately 30% stromal loss in the temporal region of the left cornea, with mild perilesional edema but no malacia or stromal white blood cells. Remaining ophthalmic examination findings OS were normal other than mild nuclear sclerosis. Intraocular pressures (TonoVet; Jorgensen Laboratories) were 15 mmHg OU, and Schirmer tear test-1 results (STT-1; Merck Animal Health) were 0 mm/min OU. Clinical diagnoses were corneal scar OD, corneal stromal ulceration OS and reduced aqueous tear production OU. Treatment was started with 0.3% ofloxacin ophthalmic solution (1 drop OS q8h [Ocuflox; Akorn]) and hyaluronate (1 drop OU q8h [i-drop-Vet Plus; I-MED Pharma]).

On day 11 the ulcer OS had mostly re-epithelialized, although stromal loss persisted. However, there were numerous punctate areas of fluorescein retention in the interpalpebral cornea OS, and an ill-defined area of stippled fluorescein retention in the dorsal cornea OU (Figure 1a,b). Results of STT-1 (mm/min) were 7 OD and 0 OS. Central corneal touch threshold (CTT [Cochet-Bonnet

aesthesiometer; Luneau Ophtalmologie]; 0.12 mm nylon filament) was 1.0 cm OD (equivalent to 12.8 g/mm²) and 0 cm OS. Mean values for ophthalmically normal non-brachycephalic cats are 3.5 cm (equivalent to 2.4 g/mm²).⁴ Approximately 10 mins following assessment of STT-1, the cat's nasolacrimal reflex was evaluated using a technique modified from that described in humans.⁵ Briefly, a standard STT strip was placed in the ventrotemporal conjunctival fornix OU, followed immediately by placement of a cotton ball soaked with 70% alcohol close to but not touching the cat's nostrils. After 30 s, the alcohol-soaked cotton-ball was removed, but the STT strips were left in position for another 30 s. Results (mm/min) were 7 OD and 5 OS. Tear film breakup time (TFBUT [DET; Akorn])⁶ was 4.0 s OU (reference interval [RI] 9.1–17.7 s).⁶ The clinical diagnosis was qualitative and quantitative tear film dysfunction OU, likely neurogenic in origin. Ofloxacin frequency was reduced to 1 drop OS q12h, and hyaluronate was replaced with heterologous feline serum (1 drop OU q4h) based upon reports in humans with severe dry eye disease.⁷

Re-examination on day 35 revealed resolution of the corneal ulcer OS with resultant focal fibrosis (Figure 1c). The STT-1 values (mm/min) were 5 OD and 4 OS. Figure 2 shows the lacrimostimulant and lacrimomimetic therapies used, as well as STT-1 values over the ensuing 81 days. Despite improved STT-1 values when 1% pilocarpine (Falcon Pharmaceuticals) was administered topically (days 35–50; 1 drop OU q24h) or orally using an escalating dose protocol described for dogs with neurogenic DES (days 50–69),² its use was discontinued owing to perceived adverse events. Superficial punctate corneal defects were noted with topical pilocarpine, and decreased appetite and a single episode of vomiting and excessive salivation were noted when the cat received three drops of pilocarpine orally, twice daily. The cat tolerated one or two drops orally twice daily. From days 69 to 116, tacrolimus 0.03% ointment (1/4" strip OU q12h; Stokes Pharmacy), heterologous feline serum (1 drop OU q4h) and cidofovir 0.5% (1 drop OU q12h) were used. No adverse effects were noted and the corneal ulcers healed; however, on day 116 the tear film appeared lackluster OU and STT-1 values had declined to levels similar to those prior to pilocarpine administration (5 mm/min OD, 4 mm/min OS). Beginning on day 93, the cat became weak and developed upper respiratory signs. Re-evaluation by an oncologist revealed left thoracic limb lameness and cervical pain; caudal brachial plexus dysfunction possibly due to sarcoma regrowth or a late effect from radiation was suspected. Serum thyroxine concentration (total T4) was markedly reduced (<0.5 µg/dl; RI 1.1–3.3 µg/dl).

The cat's systemic health continued to decline and on day 119 the owners elected euthanasia and consented to post-mortem examination. Non-ocular post-mortem

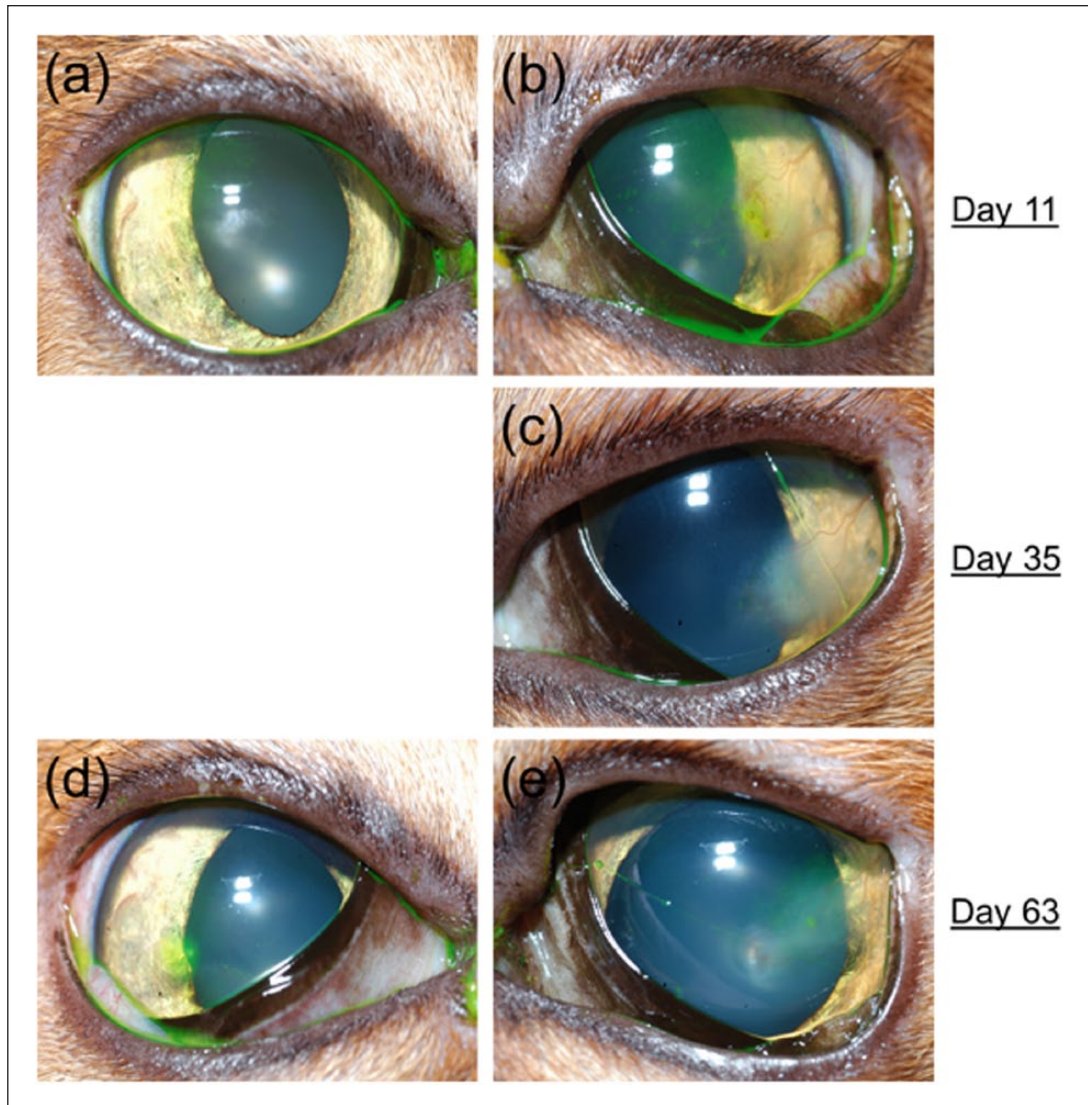


Figure 1 Clinical images of the ocular surface of the (a,d) right and (b,c,e) left eyes of a 14-year-old female spayed Abyssinian cat with neurogenic dry eye syndrome in both eyes on (a,b) days 11, (c) 35 and (d,e) 63 after initial presentation

findings included monophasic myocardial fibrosis (presumed to be due to previous infarction), generalized thyroid gland atrophy (presumed secondary to radiation therapy), and necrotic mucous and plant material within bronchioles (presumed to be due to ante-mortem aspiration). Corneal confocal microscopy performed immediately post-mortem using full-thickness scans set at 3 μ m increments (Confoscan 4; Nidek) revealed attenuated and disorganized corneal epithelium and a diminished to regionally absent sub-basal nerve plexus but normal corneal stroma and endothelium OU (Figure 3).⁸ Histologic examination revealed that both corneas had mild neutrophilic inflammation, neovascularization, anterior stromal fibrosis, epithelial attenuation with segmental erosion and detachment (Figure 4). There also was multifocal lymphoplasmacytic blepharoconjunctivitis OU and mild

lipogranulomatous blepharitis OS. Conjunctival goblet cell density (GCD) was 0% on the anterior and 3% on the posterior surfaces (Figure 5) of the third eyelid; mean reference values for these locations are 48.8% and 12.6%, respectively.⁹ Small numbers of lymphocytes and plasma cells were scattered around individual tubuloalveolar structures in the orbital lacrimal and third eyelid glands OU (Figure 6). Presence of feline herpesvirus-1 (FHV-1) DNA in both trigeminal ganglia, orbital lacrimal glands and conjunctiva was assessed using quantitative PCR (Real-time PCR Research and Diagnostics Core Facility, University of California-Davis) performed on three 20 μ m scrolls cut from formalin-fixed, paraffin-embedded blocks of each tissue.¹⁰ A new microtome blade was used for each tissue. Herpetic DNA was not detected in any tissue.

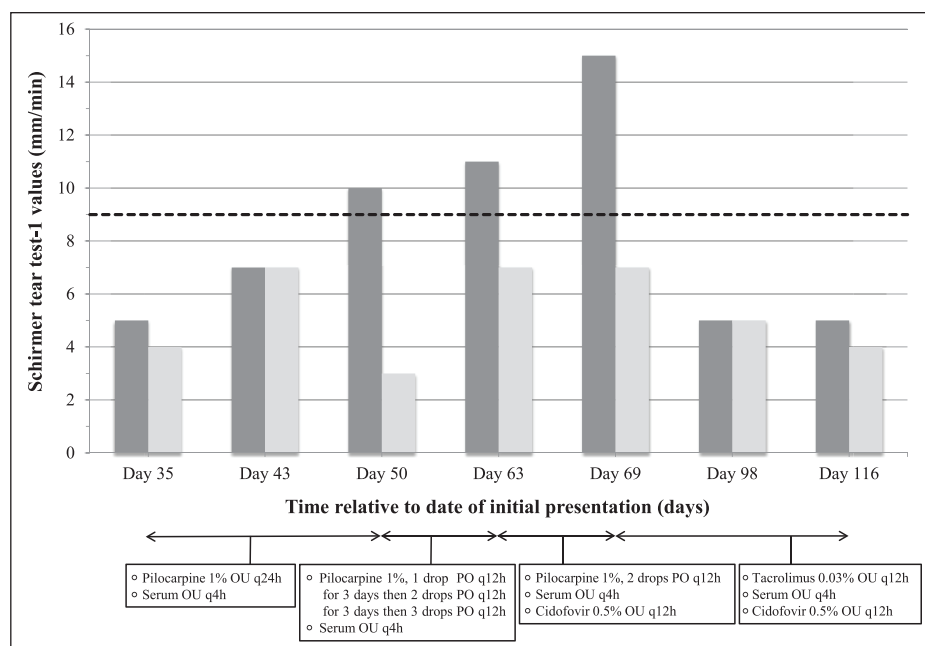


Figure 2 Time course describing lacrimostimulant and lacrimomimetic therapy, as well as Schirmer tear test-1 (STT-1) values for the right eye (dark gray) and left eye (light gray) of a 14-year-old female spayed Abyssinian cat with neurogenic dry eye syndrome in both eyes. The horizontal dashed line represents the minimum STT-1 value considered normal in cats (9 mm/min).⁶ Day number is relative to initial presentation

Discussion

To our knowledge, this is the first report of feline neurogenic DES not associated with dysautonomia. This diagnosis was based on clinically evident keratoconjunctivitis, markedly reduced corneal sensitivity, reduced to absent STT-1 values without other detected cause and clinical response to therapies that improved STT-1 values. In addition to neurogenic quantitative tear film deficiency, it is possible that this cat's qualitative tearfilm deficiency (evidenced by decreased GCD and TFBUT) was of neurogenic origin.¹¹ However, it could also be secondary to chronic ocular surface inflammation.¹² Despite such profound tearfilm deficiency, this cat did not have hallmark signs of canine DES (ie, 'keratoconjunctivitis sicca' or KCS), such as blepharospasm, mucoid discharge, or corneal vascularization, keratinization or melanosis. Rather, clinical evidence of DES in this cat was more subtle and included chronic, non-healing superficial corneal ulceration, superficial punctate fluorescein stain retention, a lackluster corneoconjunctival surface and mild-to-moderate conjunctival hyperemia. To differentiate canine and feline syndromes, here we have used the term DES rather than KCS.

Several factors indicate that neuronal dysfunction was the likely cause of DES in this cat. These include: (1) markedly decreased corneal sensitivity; (2) increased lacrimation in response to a noxious olfactory stimulus; (3) response to parasympathomimetic therapy; (4) lack of response to immunomodulatory therapy known to work in humans and dogs with immune-mediated

dacryoadenitis; and (5) lack of histologic evidence of lacrimal gland pathology sufficient to explain immune-mediated dysfunction. Furthermore, reduced corneal sensitivity, normal lacrimal gland histology, increased STT-1 values OS following stimulation of the nasolacrimal reflex and increased STT-1 values in response to pilocarpine therapy all suggest that the lacrimal glands and their parasympathetic innervation retained function, and that corneal hypoesthesia was largely or solely responsible for this cat's DES. Testing the nasolacrimal reflex was particularly illuminating in this cat and warrants further study. Physiologic tear volume regulation and reflex tearing measured with the STT-1 require functional corneal innervation via the long ciliary nerves,¹³ whereas the nasolacrimal reflex relies upon stimulation of the nasociliary nerves which are sensory to the nasal mucosa rather than the cornea, and are not involved in normal physiologic tear volume regulation.¹⁴

The cause of neurogenic dysfunction in this cat is unclear. Recurrent corneal ulceration led to initial suspicion of FHV-1 as a causative agent, especially because chronic herpetic infection in humans can lead to trigeminal nerve dysfunction and resultant corneal hypoesthesia and decreased lacrimation,¹⁵ as seen in this cat. However, failure to detect FHV-1 DNA in the lacrimal glands, trigeminal ganglia or conjunctiva bilaterally argues against this. Rather, it seems more likely that dysfunction of afferent nerve fibers responsible for lacrimation may have resulted from peripheral




Figure 3 Confocal photomicrographs of the cornea of a 14-year-old female spayed Abyssinian cat with neurogenic dry eye syndrome in both eyes. Note the (a) thin, disorganized epithelium with few hyper-reflective epithelial cells and leukocytes scattered within superficial to intermediate epithelial layers; (b) diminished to regionally absent sub-basal nerve plexus; (c) normal oval-shaped and elongated nuclei of keratocytes in the mid corneal stroma; and (d) normal corneal endothelial morphology and cell density (2400 cells/mm²; reference value 2520 cells/mm²).⁸ Bar = 50 μ m

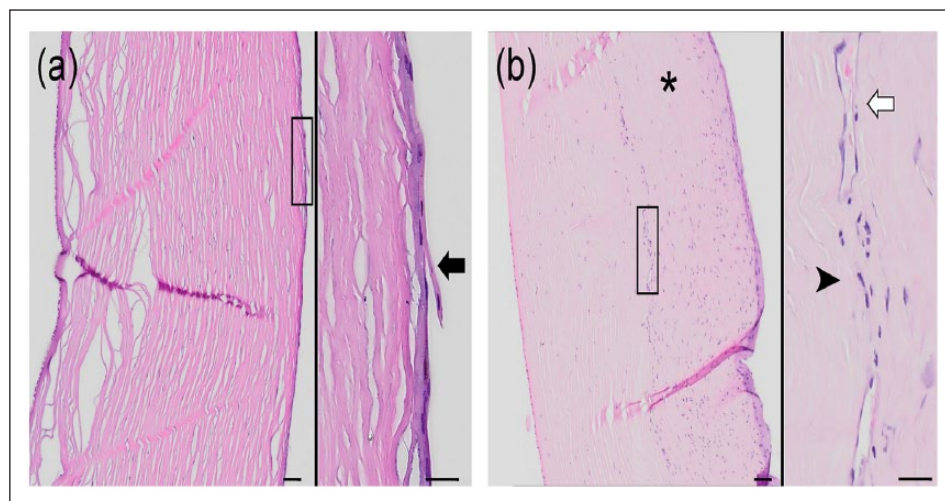


Figure 4 Photomicrographs of the cornea (a) OD and (b) OS of a 14-year-old female spayed Abyssinian cat with neurogenic dry eye syndrome OU. Both corneas had mild neutrophilic inflammation (black arrowhead), neovascularization (white arrow), anterior stromal fibrosis (asterisk), epithelial attenuation with segmental erosion and detachment (black arrow). Bar = 200 μ m for gross images and 50 μ m for insets

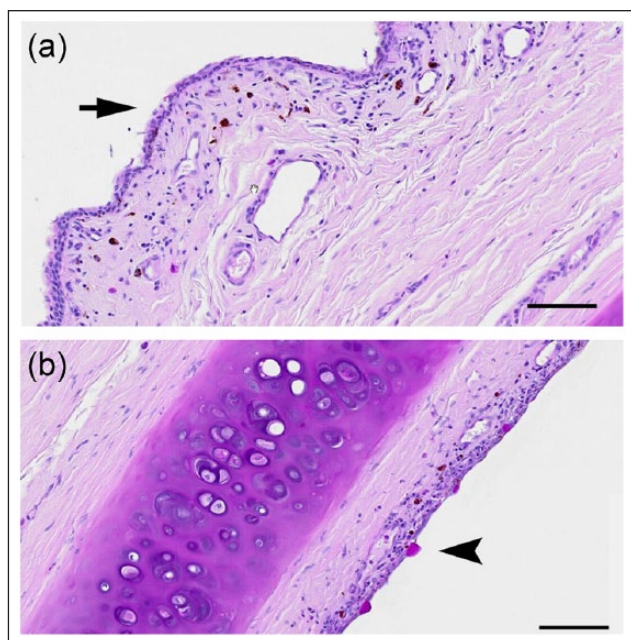


Figure 5 Photomicrographs of the third eyelid OS of a 14-year-old female spayed Abyssinian cat with neurogenic dry eye syndrome OU. Sections were stained using the periodic acid–Schiff technique and goblet cells are stained magenta. Relative to published reference intervals,⁹ conjunctival goblet cell density is markedly decreased on the (a, arrow) anterior and (b, arrowhead) posterior surfaces of the third eyelid. Bar = 100 μ m

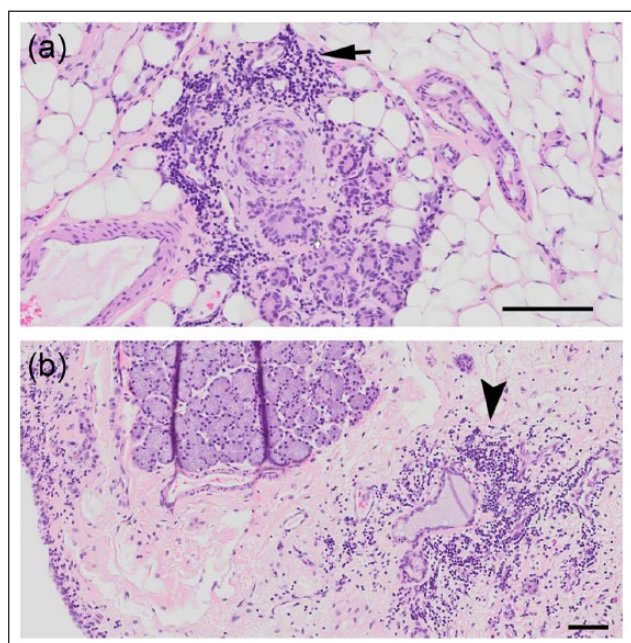


Figure 6 Photomicrographs of the (a) orbital lacrimal gland OD and (b) third eyelid gland OS of a 14-year-old female spayed Abyssinian cat with neurogenic dry eye syndrome OU. Note the (a) small aggregates of lymphocytes (arrow) around lacrimal lobules embedded in adipose tissue OD; and (b) mild-to-moderate numbers of perivascular lymphocytes and plasma cells (arrowhead) in the lamina propria of the third eyelid gland OS. Bar = 100 μ m for (a) and 200 μ m for (b)

neuropathy of a different cause, perhaps as a result of hypothyroidism or radiation injury. Hypothyroidism has been linked to DES in dogs,¹⁶ horses¹⁷ and humans,¹⁸ and peripheral neuropathy is the most common neurologic manifestation of hypothyroidism in companion animals.¹⁹ However, serum thyroid concentration was not assessed in our cat until 104 days after the diagnosis of neurogenic DES, and the cat was euthanized soon afterwards. Therefore, it is unclear whether hypothyroidism existed prior to development of neurogenic DES, or whether thyroid hormone supplementation would have restored tear production.

Therapy for patients with neurogenic DES is challenging but should include a lacrimomimetic and lacrimostimulant, and specific therapy for the cause of neurogenic dysfunction where possible. We used topically applied hyaluronate and heterologous feline serum as lacrimomimetics in this cat. Frequently applied serum may be superior to artificial tears in humans with severe dry eye disease,⁷ and was well tolerated in our patient. We also used pilocarpine in this cat for its lacrimostimulant properties; however, adverse effects were noted (punctate corneal defects and gastrointestinal disturbance). While a causal association between these events and pilocarpine administration cannot be confirmed, they limited the client's willingness to continue pilocarpine administration despite improved STT-1 values. The other lacrimostimulant used – tacrolimus – did not improve STT-1 values, which is not surprising given that post-mortem examination failed to demonstrate immune-mediated dacryoadenitis. However, the closely related compound ciclosporin exerts a direct lacrimogenic effect even in eyes without dacryoadenitis,²⁰ and improves corneo-conjunctival sensitivity in human patients with dry eye.²¹ Unfortunately, these effects were not investigated in the current case as corneal sensitivity was not reassessed after initiation of tacrolimus therapy, and ciclosporin was not used.

Conclusions

The ante- and post-mortem diagnosis in the cat presented here was neurogenic DES associated with corneal hypoaesthesia, possibly secondary to hypothyroidism. This report suggests that tearfilm deficiency should be suspected in cats with subtle ocular surface disease, and a panel of diagnostic tests to characterize the tear volume and character, as well as the health of the functional lacrimal unit,¹³ should be conducted, including assessment of STT-1, TFBUT, CTT, nasolacrimal reflex, and GCD.

Acknowledgements The authors thank Dr Sara Thomasy for assistance with confocal microscopy, John Doval and Chrisoula Agape-Toupadakis Skouritakis for assistance with image preparation, and Dr Tracy Drazenovich for technical assistance.

Funding The author(s) disclosed receipt of the following financial support for the research, authorship, and/or publication of this article: This study was funded by a generous grant from the Center for Companion Animal Health, University of California-Davis.

Conflict of interest The authors declared no potential conflicts of interest with respect to the research, authorship, and/or publication of this article.

References

- 1 Miller PE. **Lacrimal system.** In: Maggs DJ, Miller PE and Ofri R (eds). *Slatter's fundamentals of veterinary ophthalmology*. 5th ed. St Louis, MO: Elsevier Saunders, 2013, pp 165–183.
- 2 Matheis FL, Walser-Reinhardt L and Spiess BM. **Canine neurogenic keratoconjunctivitis sicca: 11 cases (2006–2010).** *Vet Ophthalmol* 2012; 15: 288–290.
- 3 Kidder AC, Johannes C, O'Brien DP, et al. **Feline dysautonomia in the Midwestern United States: a retrospective study of nine cases.** *J Feline Med Surg* 2008; 10: 130–136.
- 4 Wagner F, Meyer-Lindenberg A, Heider HJ, et al. **A comparison of corneal sensitivity between healthy cats and cats with corneal sequestra.** *Berl Munch Tierarztl Wochenschr* 2003; 116: 427–431.
- 5 Zilstorff-Pedersen K. **Quantitative measurements of the nasolacrimal reflex.** *Arch Otolaryngol* 1965; 81: 457–462.
- 6 Sebbag L, Kass PH and Maggs DJ. **Reference values, intertest correlations, and test-retest repeatability of selected tear film tests in healthy cats.** *J Am Vet Med Assoc* 2015; 246: 426–435.
- 7 Kojima T, Ishida R, Dogru M, et al. **The effect of autologous serum eyedrops in the treatment of severe dry eye disease: a prospective randomized case-control study.** *Am J Ophthalmol* 2005; 139: 242–246.
- 8 Kafarnik C, Fritsche J and Reese S. **In vivo confocal microscopy in the normal corneas of cats, dogs and birds.** *Vet Ophthalmol* 2007; 10: 222–230.
- 9 Sebbag L, Reilly CM, Eid R, et al. **Goblet cell density and distribution in cats with clinically and histologically normal conjunctiva.** *Vet Ophthalmol* 2016; 19 Suppl 1: 38–43.
- 10 Beckwith-Cohen B, Dubielzig RR, Maggs DJ, et al. **Feline epitheliotropic mastocytic conjunctivitis in 15 cats.** *Vet Pathol* 2016; 54: 141–146.
- 11 Kessler TL and Dartt DA. **Neural stimulation of conjunctival goblet cell mucous secretion in rats.** *Adv Exp Med Biol* 1994; 350: 393–398.
- 12 Contreras-Ruiz L, Ghosh-Mitra A, Shatos MA, et al. **Modulation of conjunctival goblet cell function by inflammatory cytokines.** *Mediators Inflamm* 2013; 2013: 636812.
- 13 Dartt DA. **Neural regulation of lacrimal gland secretory processes: relevance in dry eye diseases.** *Prog Retin Eye Res* 2009; 28: 155–177.
- 14 Gupta A, Heigle T and Pflugfelder SC. **Nasolacrimal stimulation of aqueous tear production.** *Cornea* 1997; 16: 645–648.
- 15 M'Garrech M, Rousseau A, Kaswin G, et al. **Impairment of lacrimal secretion in the unaffected fellow eye of patients with recurrent unilateral herpetic keratitis.** *Ophthalmology* 2013; 120: 1959–1967.
- 16 Williams DL, Pierce V, Mellor P, et al. **Reduced tear production in three canine endocrinopathies.** *J Small Anim Pract* 2007; 48: 252–256.
- 17 Schwarz BC, Sallmutter T and Nell B. **Keratoconjunctivitis sicca attributable to parasympathetic facial nerve dysfunction associated with hypothyroidism in a horse.** *J Am Vet Med Assoc* 2008; 233: 1761–1766.
- 18 Kan E, Kılıçkan E, Ecemiş G, et al. **Presence of dry eye in patients with Hashimoto's thyroiditis.** *J Ophthalmol* 2014; 2014: 754923.
- 19 Scott-Moncrieff JC. **Clinical signs and concurrent diseases of hypothyroidism in dogs and cats.** *Vet Clin North Am Small Anim Pract* 2007; 37: 709–722.
- 20 Kaswan RL, Salisbury MA and Ward DA. **Spontaneous canine keratoconjunctivitis sicca. A useful model for human keratoconjunctivitis sicca: treatment with cyclosporine eye drops.** *Arch Ophthalmol* 1989; 107: 1210–1216.
- 21 Toker E and Asfuroglu E. **Corneal and conjunctival sensitivity in patients with dry eye: the effect of topical cyclosporine therapy.** *Cornea* 2010; 29: 133–140.