

MR Venography in Gamma Knife Radiosurgery for Parasagittal Meningiomas: A Technical Note with the Rationale of Venous Protection and a Review of Literature

Abstract

Postradiosurgery symptomatic brain edema may be seen with parasagittal meningioma owing to its proximity to major venous sinuses and cortical veins. Venous preservation radiosurgery planning is less described. Here, we discuss a new method of tumor volume contouring on postcontrast magnetic resonance venogram (CEMRV) images safely excluding the adjacent cortical veins and sinuses. Six cases of parasagittal meningiomas where Gamma Knife radiosurgery was planned on CEMRV sequence were studied in detail. A double-contrast injection method was used to obtain CEMRV images. The differential contrast enhancement showed the displaced and compressed sinuses and cortical veins in the vicinity of meningioma. Tumor was contoured on both contrast magnetic resonance imaging (CEMRI) and MRV image for comparative analysis. 15 Gy at 50% marginal isodose was prescribed and quantitative assessment showed reduced exposure to the adjacent veins and sinuses on the MRV plan as compared to the CEMRI plan. All patients remain asymptomatic at a mean follow-up of 34.2 months. Postcontrast MRV is a simple sequence and can delineate the adjacent venous structures in parasagittal meningiomas. Tumor contouring directly on this sequence guides the surgeon to prescribe adequate radiation dose while sparing cortical veins and sinuses in radiosurgery planning.

Keywords: Brain edema, Gamma Knife radiosurgery, meningioma

Introduction

Gamma Knife radiosurgery (GKRS) is an established modality of treatment for meningiomas with fewer side effects.^[1] Post-GKRS brain edema at times seen following GKRS for parasagittal meningiomas.^[2,3] Radiation-induced venous compromise is one of the factors apart from tumor size, location, and histology for peritumoral brain edema.^[4] Differentiating the adjacent veins from meningiomas may be helpful to safeguard them while planning. However, this may be difficult with traditional MR imaging, especially while treating postoperative tumor residuals.

Superimposition of digital subtraction angiography (DSA) or computed tomogram venography (CTV) on contrast magnetic resonance imaging (CEMRI) is possible, although with an additional investigation and radiation exposure.^[2,5] There are however no reports on the use of MR venography (MRV) for venous protection

during radiosurgery. Here, we discuss the rationale and utility of MRV in demarcating the tumor from the adjacent veins and major sinuses during GKRS.

Technical Note

Patient population and radiology

Six consecutive patients (four male and two female) of parasagittal meningiomas where MRV images obtained in the GKRS protocol were included for evaluation. Four of them were treated with upfront GKRS and two for postoperative residual lesions.

After placing the Leksell gamma frame, MRI was performed on a 3.0T MR scanner (Verio, Siemens Medical Solutions, Erlangen, Germany) using 12 channels head coil. MRI protocol was set as per Gamma Knife requirements: TR 2140 ms, TE 6.37 ms, FoV read 245 mm, FoV phase 100%, base resolution 256, phase resolution

**Sushanta Kumar Sahoo,
Chirag Kamal Ahuja¹,
Sivashanmugam Dhandapani,
Renu Madan²,
Parsee Tomar²,
Sushil Kumar¹,
Manjeet Kaur**

Departments of Neurosurgery and ¹Department of Radiodiagnosis, ²Department of Radiotherapy PGIMER, Chandigarh, India

Address for correspondence:
Dr. Sushanta Kumar Sahoo,
Department of Neurosurgery,
PGIMER, Chandigarh, India.
E-mail: drsushantsahoo@gmail.com

Access this article online

Website: www.asianjns.org

DOI: 10.4103/ajns.AJNS_436_20

Quick Response Code:



How to cite this article: Sahoo SK, Ahuja CK, Dhandapani S, Madan R, Tomar P, Kumar S, *et al.* MR venography in gamma knife radiosurgery for parasagittal meningiomas: A technical note with the rationale of venous protection and a review of literature. Asian J Neurosurg 2021;16:307-11.

Submitted: 16-Sep-2020

Revised: 08-Dec-2020

Accepted: 24-Feb-2021

Published: 28-May-2021

This is an open access journal, and articles are distributed under the terms of the Creative Commons Attribution-NonCommercial-ShareAlike 4.0 License, which allows others to remix, tweak, and build upon the work non-commercially, as long as appropriate credit is given and the new creations are licensed under the identical terms.

For reprints contact: WKHLRPMedknow_reprints@wolterskluwer.com

100%, slice resolution 100%, slice thickness 1 mm, slice per slab 160, slice oversampling 0%, phase oversampling 25%, concentrations 1, voxel size 1 mm × 1 mm × 1 mm, and flip angle 16°. Subsequently, noncontrast T1, T2, and postcontrast T1 sequences were obtained. Gadolinium-based double-dose contrast injection method was used with a total contrast dose of 0.2 mmol/kg body weight. Half of the contrast was injected at a rate of 1.5 ml/s and the second half was injected at a rate of 3 ml/s after a gap of 90 s. Then, time-resolved contrast MRV sequence was obtained with the acquisition of fast low angle shot data. All sequences were then transported to the Elekta software for GKRS planning just like regular MR sequences for tumors.

Gamma Knife radiosurgery planning

Details of GKRS planning of the six patients are discussed in [Table 1]. T1W, T2W, CEMRI, and MRV sequences were defined in the Elekta system for GKRS. The meningioma appeared homogeneously enhancing lesion on CEMRI. However, due to differential enhancement, the meningioma appears lesser bright (inhomogeneous enhancement) than the adjacent cortical veins and SSS (homogenous enhancement) on MRV imaging. The tumor was separately contoured on both CEMRI and MRV images, but nearby veins and SSS were contoured as risk on the MRV plan. After planning the treatment with 15 Gy at 50% isodose level, dose restriction to the adjacent veins and sinuses was done by adjusting the size, number and placement of shots, dose constraints, weight, and dynamic shaping. Then, the effective dose to the adjacent veins and sinuses was calculated at 50% volume separately on the CEMRI and MRV plans.

Analysis of radiosurgery parameters

The tumor volume (TV) contoured on the CEMRI plan was greater than in the MRV plan (8.15cc vs. 7.68cc). The mean volume of the adjacent veins and sinuses that could be delineated on the MRV image was 77.91 mm³ and 858.35 mm³. The scattered dose to the nearby veins (10.73 Gy vs. 14.56 Gy) and SSS (10.23 Gy vs. 14.46 Gy) was less in the MRV plan when compared with the CEMRI plan. The final treatment was approved on the MRV plan.

Follow-up

None of the patients had additional symptoms following GKRS. The follow-up radiology did not reveal any peritumoral brain edema in any of the cases. The average follow-up is 34.2 months, and all patients are doing well.

Illustrative case

A 43-year female presented with complaints of headache for 6 months and two episodes of generalized tonic-clonic seizures. Radiology revealed left middle third parasagittal meningioma of size approximately 1.4 cm × 1.2 cm × 1 cm on CEMRI imaging. She was planned for upfront GKRS. TV was contoured both on CEMRI and MRV differentiating the displaced cortical vein at its posterior border and adjacent SSS [Figure 1]. 15 Gy marginal dose was prescribed at 50% isodose. The measured TV was 5.5cc on CEMRI and 5.1cc on MRV. The radiation exposure calculated at 50% volume of the measured cortical vein was 11.4 Gy on the MRV plan and 15.2 Gy on the CEMRI plan. For SSS, the calculated dose at 50% contoured volume was 9.2 Gy and 14.6 Gy on MRV and CEMRI plan, respectively. The patient was treated on the MRV

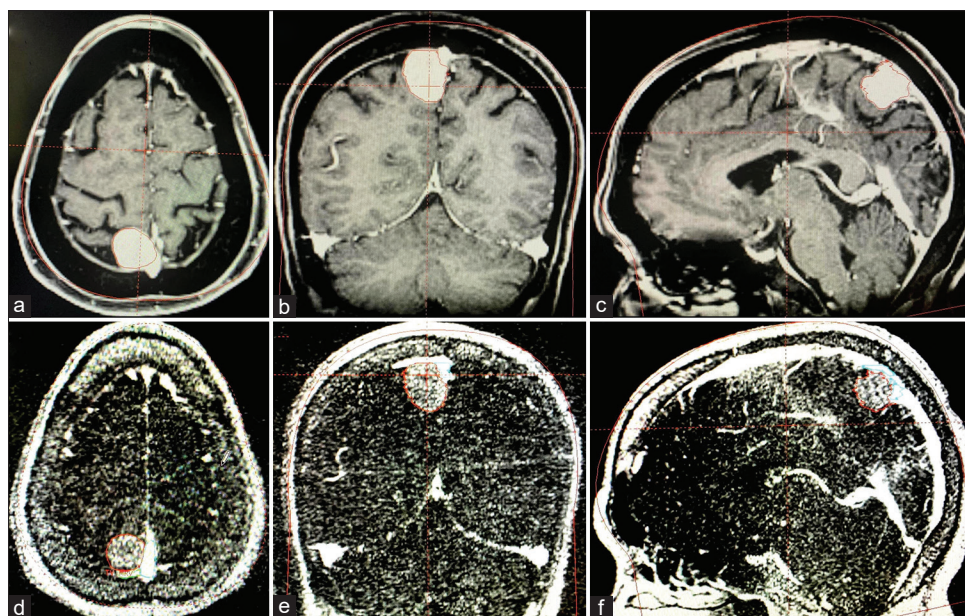


Figure 1: (a-c) showing right middle third parasagittal meningioma in axial, coronal, and sagittal contrast T1W MR images. The enhancement of tumor appears similar to superior sagittal sinus and cortical veins. (d-f) postcontrast magnetic resonance venogram images showing the same lesion in the axial, coronal, and sagittal plane. Note the differential enhancement of tumor, superior sagittal sinus, and cortical veins. Adjacent cortical veins and sinus is marked as risk on magnetic resonance venogram

plan [Figure 2]. He was discharged on the same day with a tapering dose of steroids (dexamethasone). At 30-month follow-up, the TV was relatively the same without any peritumoral brain edema.

Discussion

Radiosurgery and brain edema in parasagittal meningioma

Meningiomas are some of the most common tumors causing immense burden, requiring radiosurgery as a primary modality or as an adjunct as they cannot always be excised totally.^[6,7] Brain edema may be seen after radiosurgery for meningiomas and the incidence is as high as 38%.^[8-11] However, the pathophysiology of the development of brain edema is still not clear. The postradiosurgery edema has been noted to be not dependent on age, sex, tumor size, dose of radiation, or the number of isodoses.^[2] Many series have reported on the greater likelihood of peritumoral brain edema after radiosurgery for parasagittal meningiomas.^[11] As these tumors originate and grow in the vicinity of major venous sinuses and cortical veins, the possibility of a post-GKRS venous occlusion may be the most plausible mechanism, similar to surgical handling.

Although the effect of GKRS on normal cortical veins is not established, some believe that the partially occluded sinuses or compressed veins at the margin of the tumor are more susceptible to radiation inflammation, giving rise to symptomatic brain edema.^[4] Patil *et al.* also suggested that parasagittal meningioma was four times more likely to develop symptomatic brain edema as compared to other

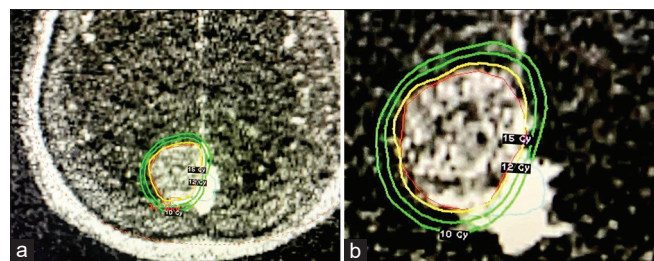


Figure 2: (a and b) Magnetic resonance venogram image showing Gamma Knife radiation dose to the tumor. The cortical vein and sinus is clearly differentiated from the tumor volume

skull base meningiomas following radiosurgery.^[3] Sheehan *et al.* in their study concluded that parasagittal location of meningioma and venous sinus compression or invasion was positively correlated with post-GKRS brain edema formation.^[11] A review of all this literature further supports the possible role of peritumoral venous compromise responsible for the development of symptomatic brain edema following GKRS in parasagittal meningiomas. This mandates a thorough evaluation of the peritumoral venous architecture while planning for GKRS.

Delineation of adjacent veins and sinuses in parasagittal meningioma

Conventionally, the TV is delineated on postcontrast T1W MR sequence for radiosurgery. Meningioma is a highly vascular tumor and avid contrast uptake makes it easier to appreciate on CEMRI. However, difficulties arise when meningioma is located adjacent to major sinuses or cortical veins. As the sinus and veins also show similar postcontrast enhancement, the demarcation of the tumor from these venous structures becomes tricky. Gradual compression of the sinus may also allow the development of collateral venous channels.^[5] These veins need to be safeguarded while demarcating the tumor for GKRS. Previously attempts have been made to incorporate computed tomography (CT) venogram images with postcontrast MR images to exclude veins and sinuses while delineating tumor margin. Conti *et al.* have described a technique of differentiating tumor and cortical veins on double-contrast CT venography images. They did the contouring of tumor on MR image and overlay these images on CT venogram to exclude adjacent cortical veins.^[2] DSA images have been used to define venous drainage patterns in meningioma.^[12] These angiographic images can be incorporated with MR images and peritumoral veins can be excluded while contouring parasagittal meningiomas for GKRS. However, these require an additional investigation and radiation exposure.

Magnetic resonance venogram guided cortical veins and sinus sparing radiosurgery

Postcontrast MRV is well described in the literature to identify the cortical veins and sinuses.^[12,13] Venous

Table 1: Stereotactic radiosurgery parameters of tumor, cortical veins and superior sagittal sinus

Serial number	Volume of tumor (cm ³)		Volume of adjacent cortical vein on MRV (mm ³)	Volume of adjacent sinus on MRV (mm ³)	Dose to 50% volume of vein (Gy)		Dose to 50% volume of sinus (Gy)	
	MRV	CEMRI			MRV	CEMRI	MRV	CEMRI
Patient 1	5.1	5.5	68.5	833.3	11.4	15.2	9.2	14.6
Patient 2	6.8	7.2	71.5	788	11.0	14.8	9.6	14.5
Patient 3	9.8	10.4	100.5	980.5	10.6	14.6	10.2	14.2
Patient 4	8.6	9.2	98	1060.2	9.8	14.1	10.7	14.8
Patient 5	7.6	8.1	74.4	821.3	10.9	13.8	11.8	14.9
Patient 6	8.2	8.5	54.6	666.8	10.7	14.9	9.9	13.8
Average	7.68	8.15	77.91	858.35	10.73	14.56	10.23	14.46

MRV – Magnetic resonance venogram; CEMRI – Contrast enhancing magnetic resonance imaging; Gy – Gray

preservation for parasagittal meningioma had been reported in the past for microsurgery but not much reported in radiosurgery.^[14] We utilized the MRV image while planning GKRS for parasagittal meningiomas to avoid possible radiation-induced damage to adjacent cortical veins and sinuses. Moreover, a double-contrast method differentially enhances the tumor and adjacent veins [Figure 1d-f]. Hence, it is possible to define both the tumor as well as the veins and sinuses in a single image, thereby avoiding the merging of a separate venogram image in radiosurgery planning. At times, the compressed venous sinus or the cortical vein may be mistaken as a dural tail and poses great difficulty to protect them from radiation exposure while contouring the tumor on contrast T1W sequence. The disparity in the enhancement of the meningioma and adjacent veins thus helps to delineate the tumor margin distinctly from veins and sinuses even when the tumor invaded the major sinuses. We have analyzed six patients with parasagittal meningiomas where one adjacent cortical vein could be demarcated on MRV at the border of the tumor in addition to the SSS. When separate planning for GKRS was done on CEMRI and MRV images, the TV was relatively higher on the CEMRI image. This is probably due to nondifferentiation of meningioma from SSS as both have a similar appearance on CEMRI. In addition, the radiation dose to the adjacent cortical vein and the sinus was significantly higher on the CEMRI protocol than on the MRV based protocol.

Another method of safeguarding the veins is to deliver a lesser dose to the meningioma with questionable long-term outcomes. Contouring the TV on the MRV sequence allows the surgeon to prescribe an adequate dose as the neighboring veins could be delineated. All our six patients did not develop any radiation-related side effects at an average 20.5 month follow-up. However, it needs to be studied on a larger population, and also a long-term follow-up is necessary to verify its advantage over traditional imaging systems. Simultaneously, the dose to cortical veins and sinuses can be documented in each case and the data can be used in future to define the maximum tolerable safe dose to the compromised venous structures adjacent to meningiomas.

Limitations

The number of cases studied is less and needs to compare with GKRS planning without venogram. Again, long-term follow-up is needed to confirm this hypothesis.

Conclusion

Venous preservation GKRS in cases of parasagittal meningiomas may help to reducing radiation-induced symptomatic brain edema. Radiological differentiation of parasagittal meningioma and adjacent venous architecture is

better with postcontrast MRV than DSA or CT venography, as it avoids additional investigation or radiation exposure. Adding this sequence to the MR planner in GKRS thus allows the surgeon to prescribe adequate radiation dose while safeguarding the nearby venous sinuses and cortical veins.

Informed consent has been obtained from patients.

Financial support and sponsorship

Nil.

Conflicts of interest

There are no conflicts of interest.

References

- Kondziolka D, Patel AD, Kano H, Flickinger JC, Lunsford LD. Long-term Outcomes After Gamma Knife Radiosurgery for Meningiomas. *Am J Clin Oncol* 2016;39:453-7.
- Conti A, Pontoriero A, Salamone I, Siragusa C, Midili F, La Torre D, *et al.* Protecting venous structures during radiosurgery for parasagittal meningiomas. *Neurosurg Focus* 2009;27:E11.
- Patil CG, Hoang S, Borchers DJ 3rd, Sakamoto G, Soltys SG, Gibbs IC, *et al.* Predictors of peritumoral edema after stereotactic radiosurgery of supratentorial meningiomas. *Neurosurgery* 2008;63:435-40.
- Singh VP, Kansai S, Vaishya S, Julka PK, Mehta VS. Early complications following gamma knife radiosurgery for intracranial meningiomas. *J Neurosurg* 2000;93 Suppl 3:57-61.
- Tanaka M, Imhof HG, Schucknecht B, Kollias S, Yonekawa Y, Valavanis A. Correlation between the efferent venous drainage of the tumor and peritumoral edema in intracranial meningiomas: Superselective angiographic analysis of 25 cases. *J Neurosurg* 2006;104:382-8.
- Dhandapani M, Gupta S, Mohanty M, Gupta SK, Dhandapani S. Prevalence and Trends in the Neuropsychological Burden of Patients having Intracranial Tumors with Respect to Neurosurgical Intervention. *Ann Neurosci* 2017;24:105-10.
- Dhandapani S, Sharma K. Is “en-bloc” excision, an option for select large vascular meningiomas? *Surg Neurol Int* 2013;4:102.
- Conti A, Pontoriero A, Siddi F, Iati G, Cardali S, Angileri FF, *et al.* Post-treatment edema after meningioma radiosurgery is a predictable complication. *Cureus* 2016;8:e605.
- Hoe Y, Choi YJ, Kim JH, Kwon DH, Kim CJ, Cho YH. Peritumoral brain edema after stereotactic radiosurgery for asymptomatic intracranial meningiomas: Risks and pattern of evolution. *J Korean Neurosurg Soc* 2015;58:379-84.
- Morgan TM, Zaenger D, Switchenko JM, Eaton BR, Crocker IR, Ali AN, *et al.* Fractionated radiotherapy is associated with lower rates of treatment-related edema than stereotactic radiosurgery in magnetic resonance imaging-defined meningiomas. *World Neurosurg* 2019;121:e640-6.
- Sheehan JP, Cohen-Inbar O, Ruangkanhasetr R, Bulent Omay S, Hess J, Chiang V, *et al.* Post-radiosurgical edema associated with parasagittal and parafalcine meningiomas: A multicenter study. *J Neurooncol* 2015;125:317-24.
- Bozzao A, Finocchi V, Romano A, Ferrante M, Fasoli F, Trillò G, *et al.* Role of contrast-enhanced MR venography in the preoperative evaluation of parasagittal meningiomas. *Eur Radiol*

- 2005;15:1790-6.
13. Sahoo SK, Ghuman MS, Salunke P, Vyas S, Bhar R, Khandelwal NK. Evaluation of anterior third of superior sagittal sinus in normal population: Identifying the subgroup with dominant drainage. *J Neurosci Rural Pract* 2016;7:257-61.
14. Tomasello F, Conti A, Cardali S, Angileri FF. Venous preservation-guided resection: A changing paradigm in parasagittal meningioma surgery. *J Neurosurg* 2013;119:74-81.