



ELSEVIER

Contents lists available at [ScienceDirect](https://www.sciencedirect.com)

Respiratory Medicine Case Reports

journal homepage: www.elsevier.com/locate/rmcr

Case report

A case of pulmonary tumor thrombotic microangiopathy following lymphedema on the lower extremities

Yuri Shiraiwa^{a,*}, Yuri Taniguchi^a, Mari Hyoudou^a, Aya Shiba^a, Masaharu Aga^a, Kazuhito Miyazaki^a, Yusuke Hamakawa^a, Yuki Misumi^a, Yoko Agemi^a, Tsuneo Shimokawa^a, Chie Hasegawa^b, Hiroyuki Hayashi^b, Hiroaki Okamoto^a

^a Department of Respiratory Medicine, Yokohama Municipal Citizen's Hospital, 1-1 Mitsuzawa-nishimachi, Kanagawa-ku, Yokohama, Kanagawa, 221-0855, Japan

^b Department of Pathology, Yokohama Municipal Citizen's Hospital, Japan

ARTICLE INFO

Keywords:

Pulmonary tumor thrombus microangiopathy
PTTM
Lymphedema
Adenocarcinoma
Unknown origin

ABSTRACT

Pulmonary tumor thrombotic microangiopathy (PTTM) is a rare manifestation of malignancy. The antemortem diagnosis is difficult, since patients present with rapidly progressive symptoms. We recently observed a case of PTTM following lymphedema of the lower extremities. We did not reach a diagnosis, even after performing BAL and TBLB. The patient manifested pulmonary hypertension and died on the 9th day of admission. Autopsy revealed a tumor embolism in the pulmonary arterioles accompanied by fibrocellular epithelial cell proliferation, but the primary organ was not identified. To our knowledge, this is the first reported case of PTTM with lymphedema.

1. Introduction

PTTM is a rare form of malignancy that was first described by von Herbay in 1990 [1]. They selected 630 patients with carcinoma and reviewed their autopsy reports, including their histology findings. Among the selected cases, 21 showed distinct tumor-related microangiopathic lesions in small pulmonary arteries. Three of the 21 patients presented severe dyspnea and marked pulmonary hypertension of unknown origin. All of these patients died shortly after the onset, and carcinoma was not found before autopsy. They considered that these pathological findings were related to pulmonary hypertension and suggested the term pulmonary tumor thrombotic microangiopathy (PTTM). Due to the rapid and intense clinical course, an antemortem diagnosis is rarely achieved, especially in cases where malignant disease is not suspected. Previous reports suggest that the primary organs that commonly cause PTTM are the stomach, esophagus, mammary glands, pancreas, and urinary tracts. We herein report a case of PTTM that was diagnosed by a postmortem examination, in which the patient first presented with lymphedema of the lower extremities with no known cancer history. Despite a thorough examination of all organs, and immunostaining of the tumor cells, we concluded that this cancer was of unknown origin.

2. Case presentation

A 55-year-old male, whose significant medical history included hypertension and type 2 diabetes, was referred to our surgery

* Corresponding author.

E-mail address: shiraiwa@keio.jp (Y. Shiraiwa).

<https://doi.org/10.1016/j.rmcr.2022.101631>

Received 24 December 2021; Received in revised form 19 January 2022; Accepted 7 March 2022

Available online 15 March 2022

2213-0071/© 2022 Published by Elsevier Ltd. This is an open access article under the CC BY-NC-ND license (<http://creativecommons.org/licenses/by-nc-nd/4.0/>).

department with bulging in his right inguinal region, and was diagnosed with inguinal hernia. He is an ex-smoker, who quit smoking 1 year ago with Brinkman index of 680 (20 cigarettes per day for 34 years). He underwent surgical repair, and was discharged without any complications. One month later, he returned with swelling on his right lower extremity, lower abdomen, and testicles. A thorough systemic examination was performed including an abdominal CT scan, a contrast-enhanced CT scan to detect venous thrombus embolism, and blood tests, as well as referral to a urologist, all of which failed to detect the cause. Lymphoscintigraphy showed lymphatic leakage from the scrotum to the right lateral thigh and disturbance in the lymphatic drainage on both lower extremities (Fig. 1). This eventually led us to a diagnosis of postoperative lymphedema. One month later, he was referred to the respiratory department due to a mild dyspnea on exertion and an abnormal chest X-ray. The chest X-ray showed mild infiltration in the bilateral middle and lower lung fields (Fig. 2), while the CT scan found thickening of the broncho-vascular bundle, tree-in-bud appearance, and interlobular septal thickening (Fig. 3 [A]). Although interstitial pneumonia, including hypersensitivity pneumonia and sarcoidosis, was suspected according to the imaging findings, the blood test did not detect any findings related to it (Table 1). In addition, bronchoalveolar lavage (BAL) and *trans*-bronchial lung biopsy (TBLB) were performed, which both showed normal results. On the 6th day after bronchoscopy, he was transported to the emergency department by ambulance because he temporarily lost consciousness after feeling palpitation and chest tightness during urination. He had mild respiratory dysfunction, which necessitated nasal oxygen therapy (1 L/min).

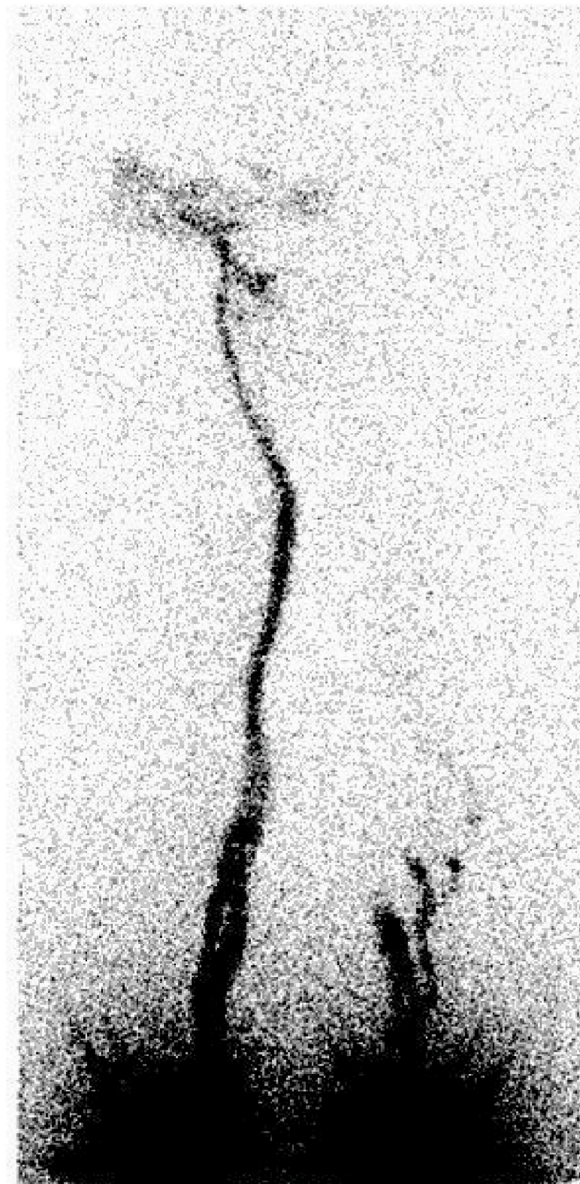


Fig. 1. Lymphoscintigraphy showed lymphatic leakage from the scrotum to the right lateral thigh and disturbance in the lymphatic drainage on both lower extremities.

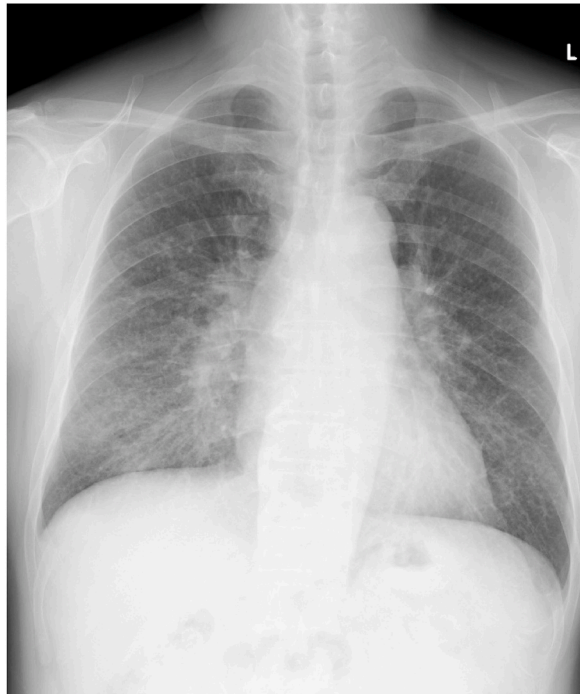

Fig. 2. Chest X-ray on the patient's first visit shows mild infiltration in the bilateral middle and lower lung fields.

Percutaneous echocardiography showed right ventricular pressure overload (Fig. 4), but contrast-enhanced CT did not detect any pulmonary embolism. Electrocardiography showed S1Q3T3 pattern and negative T wave in leads V1–V4, which was compatible with the findings of pulmonary hypertension (Fig. 5). He was admitted to our department under the suspicion of group 3 pulmonary hypertension caused by underlying lung disease. Despite our effort to find the explanation for all of these symptoms, additional gallium scintigraphy also produced normal results. High-dose intravenous methylprednisolone pulse therapy (1000mg/day for 3 days) was initiated, followed by oral prednisolone (60 mg/day [1mg/kg/day]), which unfortunately did not improve his symptoms or chest X-ray findings. On the 8th day of admission, his respiratory condition suddenly deteriorated after urination. Contrast-enhanced CT was repeated but showed no significant findings (Fig. 3 [B]); however, transcutaneous echocardiography showed that the pulmonary hypertension was worse than at the initial examination on the day of admission. The tricuspid regurgitation pressure gradient (TRPG) was 56 mmHg, the tricuspid regurgitant velocity (TRV) max was 3.6 m/sec, and the D-shaped left ventricle created by shifted septum due to right ventricle overload was more obvious. Anticoagulant therapy was not initiated due to the absence of visible thrombosis in the contrast-enhanced CT, despite the slightly elevated d-dimer level. We carefully started diuretic therapy, furosemide 20mg/day intravenously, assuming that the right ventricle pressured the left ventricle on exertion, ultimately leading to circulatory insufficiency. The following day, he woke up with severe dyspnea, and immediately progressed to cardiopulmonary arrest. Despite full cardiopulmonary resuscitation, he did not regain spontaneous circulation.

An autopsy was performed in accordance with his family's wish to find the definite cause of his death. The gross findings of his lung identified small hilar lymphadenopathies and thickening of the interlobular septa and peribronchiolar connective tissue (Fig. 6). The histopathological examination of the lung showed multiple lymphovascular invasion of signet-ring-cell type carcinoma (Fig. 7 [A]), and hilar lymph node metastasis (Fig. 7 [B]). Moreover, the lymphatic vessels around the adrenal glands and liver capsule were occupied with the same tumor cells (Fig. 7 [C] [D]). Metastasis to the thyroid glands and bilateral common iliac lymph nodes was also identified despite the lack of significant findings on CT images (Fig. 7 [E]). Tumor emboli were seen in pulmonary arterioles along with intimal proliferation confirmed by Elastica van Gieson staining (Fig. 7 [F]). PTTM was diagnosed due to this pathological insight. A gross examination found no obvious sign of malignancy in any organ, including the anus and salivary glands, which were unresectable in autopsy. Of special importance, the stomach was cut into thin segments and each piece was examined thoroughly, yet there was no sign of malignancies. Although the tumor cells were histologically adenocarcinoma, further immunostaining investigations consisting of CK7 (+), CK20 (+), TTF-1 (–), CDX2 (–), AMACR (–), PAX8 (–), and ER (–) could not lead to the primary organ. Considering that the tumor had metastasized into the bilateral common iliac lymph nodes and invaded the surrounding lymphatic vessels, his presenting symptom of lymphedema of the lower extremities was possibly attributed to this cancer of unknown origin.

3. Discussion

PTTM is distinguished from pure tumor embolism histologically by occlusive fibrocellular intimal proliferation in small pulmonary arteries and veins, which is induced by tumor microemboli [2]. It starts with the formation of microscopic tumor cell emboli, which

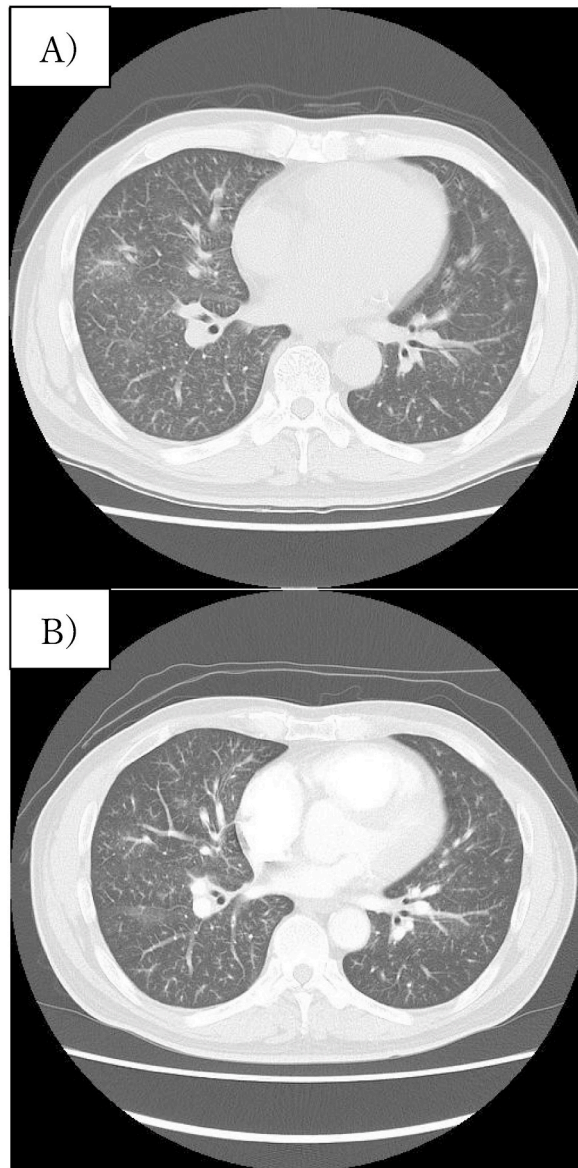


Fig. 3. (A) Chest high-resolution CT (HRCT) on the first day shows thickening of the broncho-vascular bundle, tree-in-bud appearance, and interlobular septal thickening.

(B) HRCT obtained one day before his death showed a similar appearance to (A). It also showed mild cardiac hypertrophy and a small amount of pericardial effusion.

induces pulmonary vessel injury leading to local activation of coagulation and recruitment of inflammatory markers [3]. The tumor emboli also increase the expression of vascular endothelial growth factor (VEGF), tissue factor (TF), and platelet-derived growth factor (PDGF) on the tumor cells, which possibly contribute to the onset and progression of fibrocellular intimal proliferation [4]. Widespread vascular stenosis and occlusion result in increased pulmonary vascular resistance, which causes pulmonary hypertension [5].

This patient, who presented with no known history of malignancy quickly developed pulmonary hypertension following ipsilateral lymphedema after inguinal hernia repair. These two independent phenomena were eventually found to have been caused by the same disease. Based on multiple metastasis of the bilateral common iliac lymph nodes, we assume that cancer cells of unknown origin plugged the lymphatic vessels in the right lower limb and disturbed the lymph circulation to the thoracic duct. In fact, the abdominal cavity was untouched during the hernia repair procedure, and autopsy did not detect any sign of inflammation inside the cavity, which could have only explained lymphedema caused by surgery. The presenting symptom of lymphedema in an advanced cancer is rare, and only 17 cases have been reported previously [6,7]. 10 out of 17 cases also presented chylothorax which can be explained by the tumor emboli or compression of thoracic duct resulting in the dilation of collateral lymph vessels and malfunctioning of the lymphatic valves [6]. Since the thoracic duct originates from the confluence of the lumbar trunks and the intestinal trunk, the coincidents of lower limb's lymphedema and chylothorax can be naturally attributed to the same cause. Skin biopsies of the lymphedema could have been useful

Table 1
Laboratory findings on admission.

<Peripheral blood>			<Blood chemistry>			<Other findings>		
WBC	8330	/ μ L	AST	15	IU/L	KL-6	201	U/mL
RBC	103	$\times 10^4$ / μ L	ALT	10	IU/L	SP-D	77.6	ng/mL
Hgb	14.7	g/dL	γ GTP	30	IU/L	β -D glucan	17.3	Pg/mL
Hct	44.9	%	LDH	149	IU/L	T-SPOT	(-)	
Plt	22.9	$\times 10^4$ / μ L	CK	110	U/L	Anti-IL-2R antibody	646	U/mL
<Coagulation markers>			TP	6.8	g/dL	ACE	16.0	U/L
PT/INR	1.17		Alb	3.3	g/dL	LIPASE	7.0	U/L
APTT	26.9	sec	Na	139	mEq/L	Trichosporon asahii antibody	(-)	
Fib	489	mg/dL	K	4.4	mEq/L	ANA	(-)	
D-dimer	2.79	μ g/mL	Cl	104	mEq/L	Anti-dsDNA	(-)	
			BUN	14.5	mg/dL	Anti-CCP	(-)	
			Cre	0.82	mg/dL	Anti-Scl-70	(-)	
			UA	5.6	mg/dL	Anti-MDA5Ab	(-)	
			CRP	1.5	mg/dL	Anti-ARSAb	(-)	
			HbA1c	7.0	%			

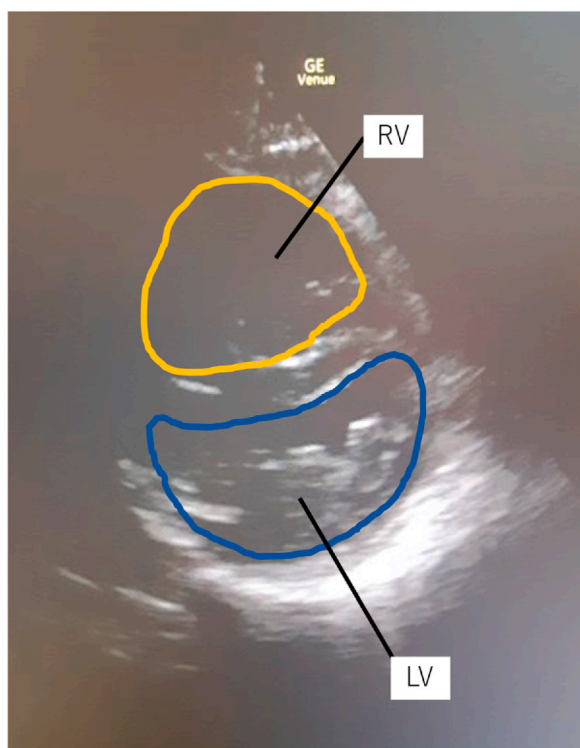


Fig. 4. Ultrasound cardiography from the short-axis view shows a D-shaped left ventricular (LV) cavity alongside a grossly hypertrophied right ventricle (RV).

in order to prove the correlation between lymphedema and cancer of unknown primary site because three case reports had highlighted the presence of cancer cells in dermal lymphatic vessels [8–10]. To the best of our knowledge, this is the first case of PTTM accompanied by lower extremity lymphedema.

In our case, CT showed thickening of the broncho-vascular bundle, tree-in-bud appearance, and interlobular septal thickening. The diagnosis based on these findings was challenging because a tree-in-bud appearance usually suggests infectious bronchiolitis or hypersensitivity pneumonitis [5,11], and the TBLB and BAL results in our case were not informative. Although tree-in-bud appearance in bronchiolitis is caused by dilatation and plugging of the small airways with mucus and inflammatory materials, the same imaging patterns seen in PTTM largely resulted from the filling of centrilobular arteries with tumor cells. One systemic review examined 160 patients from 79 publications, and concluded that 55% and 45% of PTTM originated from gastric cancers and non-gastric cancers showing tree-in-bud imaging features, respectively [12]. Other findings of PTTM that are expected on high-resolution CT include consolidation, ground-glass opacity, small nodules, mediastinal/hilar adenopathy, and septal thickening [11]. Centrilobular nodularity is often present as an early sign in PTTM [13,14]. PTTM should be listed as a differential diagnosis when these CT findings are

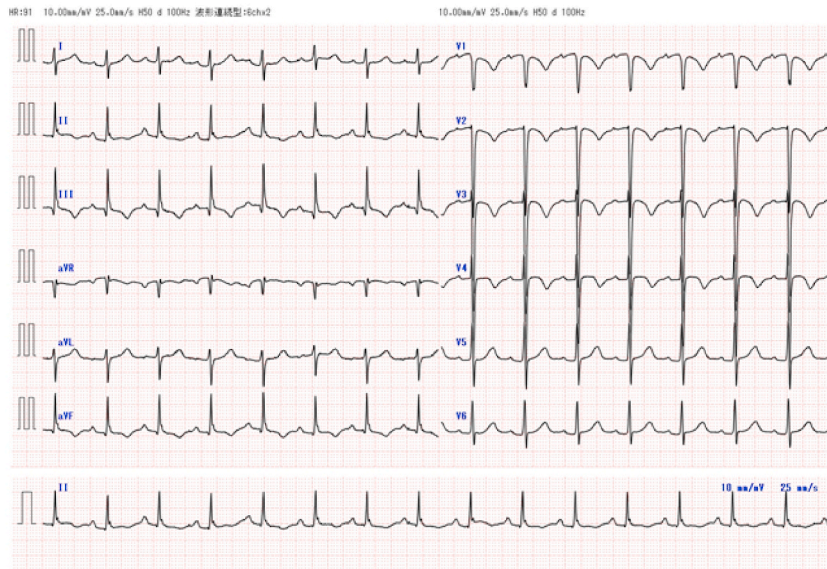


Fig. 5. S1Q3T3 pattern and negative T wave in leads V1–V4 were seen on electrocardiography, which suggests pulmonary hypertension.

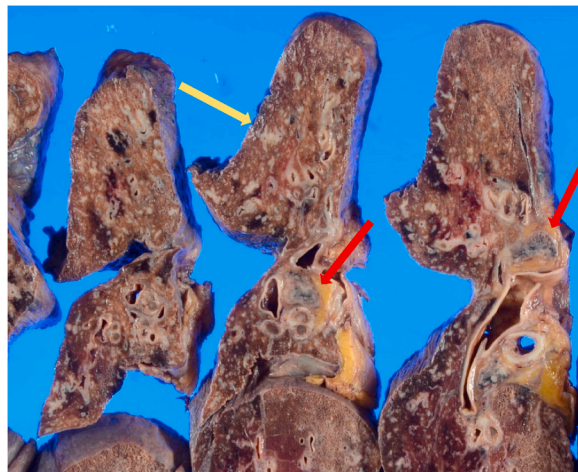


Fig. 6. The gross findings of the lung identified thickening of the interlobular septa and peribronchiolar connective tissue (as pointed by the yellow arrow), along with small hilar lymphadenopathies (as pointed by the red arrows). (For interpretation of the references to colour in this figure legend, the reader is referred to the Web version of this article.)

observed, especially for patients with a history of malignancy.

PTTM has been found in 0.9–3.3% of autopsy case studies of cancer patients [1,4,11], and this may occur in almost every type of adenocarcinoma, although we found no cases of PTTM in ovarian cancer, thyroid carcinoma, or fallopian tube carcinoma [1,11]. PTTM was most commonly found in cases with stomach cancer, especially the mucinous, signet-ring-cell and poorly differentiated subtypes [2]. In our case, despite a thorough examination of all organs, especially the stomach, and a search using immunostaining, we could not determine the primary site of the adenocarcinoma found in the small pulmonary arterioles, lymphatic vessels, and multiple metastatic sites. To our knowledge, there are only 4 cases of PTTM of unknown primary origin reported in the relevant literature [15–18]. The characteristics are summarized in Table 2. Interestingly, all 5 cases, including ours, were histologically diagnosed as signet-ring-cell carcinoma, and 2 out of 4 had developed a Krukenberg tumor. Immunostaining of the tumor cells, which at times directs physicians to a correct diagnosis and appropriate treatment, was not helpful in these cases.

PTTM is often rapidly progressive and difficult to diagnose early. There are some case reports of treatment, which has included conventional pulmonary vasodilators, chemotherapy, and anti-inflammatory/antiproliferative approaches. In some cases, endothelin receptor antagonists, including bosentan [13] and ambrisentan [19], were used in combination with imatinib, a tyrosine kinase inhibitor that inhibits the phosphorylation of the PDGF receptor, which resulted in the improvement of PTTM. The reduction in the number of malignant cells by chemotherapy may be effective. Reports suggest that the early use of chemotherapy may improve cough

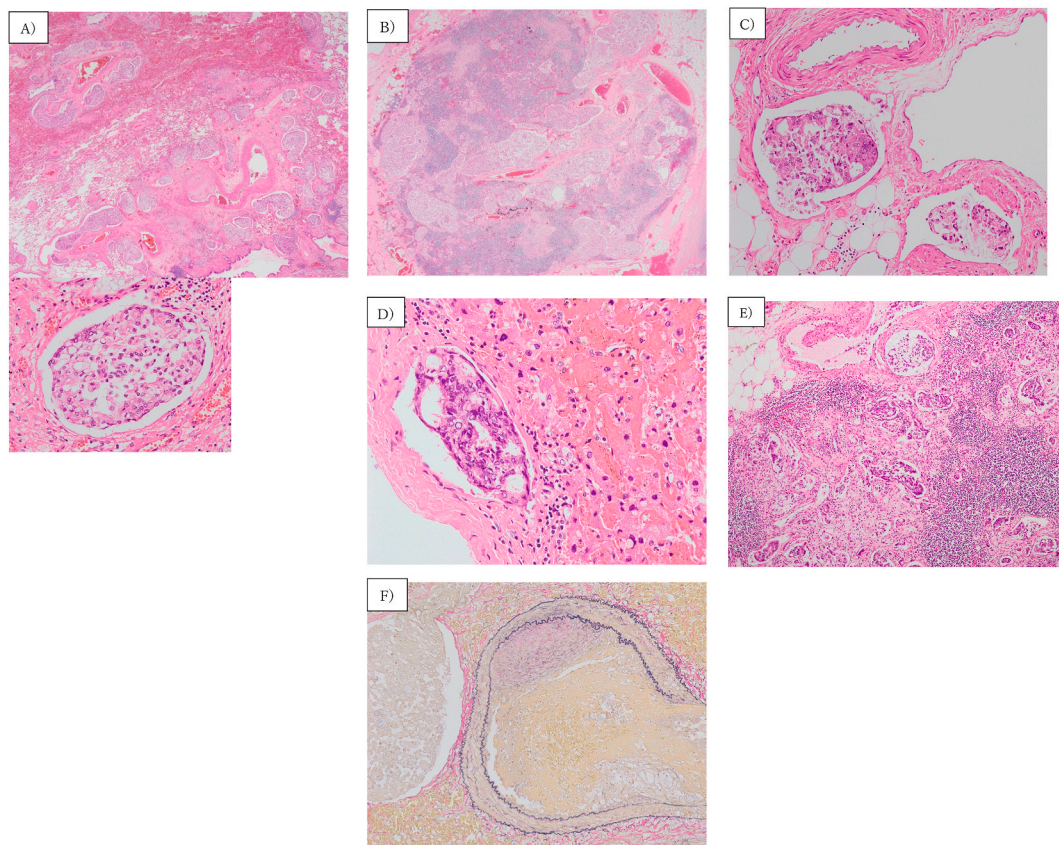


Fig. 7. Histopathological findings. (A) Multiple lymphovascular invasion of adenocarcinoma is observed in the lung (HE, $\times 4$, $\times 400$). (B) The specimens showed metastasis of the hilar lymph nodes, along with lymphatic invasion (HE, $\times 4$). (C)(D) The lymphatic vessels around the adrenal glands (C) and liver capsule (D) were occupied by the same tumor cells (HE, C; $\times 40$, D; $\times 400$). (E) Metastasis to the bilateral common iliac lymph nodes was identified (HE, $\times 100$). (F) In the small pulmonary arterioles, fibrocellular intimal proliferation and tumor embolism were apparent, resulting in stenosis (Elastica van Gieson staining, $\times 400$).

Table 2

PTTM cases with cancer of unknown primary site.

Patient	Age	Sex	Histology	Immunostaining	Krukenberg tumor	Onset to death	Published year
1	58	Female	Signet-ring-cell carcinoma	CK7 (+), CK20 (+), CA19-9(+), CEA(+), GCDFP-15(-), ER(-), PgR(-), S100(-), CA-125(-), PLAP(-).	(+)	2 days	2000
2	52	Female	Signet-ring-cell carcinoma	CK7(+), CK20(+), MUC5AC(+), MUC2(+), CA19-9(+)	(-)	40 days	2009
3	47	Male	Signet-ring-cell carcinoma	Pan keratin (+), CK7(-), CK10(-), TTF1(-), PSA(-)	(-)	suddenly	2014
4	64	Female	Signet-ring-cell carcinoma	not examined	(+)	14 days	2018

and centrilobular nodules on HRCT [20]. Anti-inflammatory approaches, such as glucocorticoid therapy may also be encouraging. In this case, systemic glucocorticoid therapy did not improve the patient's respiratory condition or X-ray/HRCT findings. Being mindful of the disease and making an early diagnosis are essential to appropriate treatment. Pulmonary wedge aspiration cytology using a Swan-Gantz catheter or the recent technique of bronchoscopic cryobiopsy could be beneficial for the antemortem diagnosis.

4. Conclusion

We encountered a rare case of adenocarcinoma of unknown origin that simultaneously caused PTTM and lymphedema of the lower extremities. PTTM patients show extremely progressive symptoms and it is difficult to make a definitive pathological diagnosis while the patient is alive. PTTM should be suspected in patients with pulmonary hypertension, even if cancer is not clinically diagnosed.

Statement of ethics

The authors declare no conflicts of interest in association with the present study. Written informed consent was obtained from our patient for the publication of this case report.

Declaration of competing interest

The authors declare no conflicts of interest in association with the present study.

References

- [1] A. von Herbay, A. Illes, R. Waldherr, H.F. Otto, Pulmonary tumor thrombotic microangiopathy with pulmonary hypertension, *Cancer* 66 (1990) 587–592, [https://doi.org/10.1002/1097-0142\(19900801\)66:3%3C587::aid-cnrcr2820660330%3E3.0.co;2-j](https://doi.org/10.1002/1097-0142(19900801)66:3%3C587::aid-cnrcr2820660330%3E3.0.co;2-j).
- [2] L.C. Price, A.U. Wells, S.J. Worst, Pulmonary tumour thrombotic microangiopathy, *Curr Opin Plum Med* 22 (5) (2016 Sep) 421–428, <https://doi.org/10.1097/mcp.0000000000000297>.
- [3] R. Godbole, A. Ghatol, J. Betancourt, et al., Pulmonary tumor thrombotic microangiopathy: clinical, radiologic, and histologic correlation, *J Clin Imaging Sci* 5 (2015) 44, <https://doi.org/10.4103/2156-7514.161978>.
- [4] S. Miyano, S. Izumi, Y. Takeda, et al., Pulmonary tumor thrombotic microangiopathy, *J. Clin. Oncol.* 25 (2007) 597–599, <https://doi.org/10.1200/jco.2006.09.0670>.
- [5] T. Franquet, A. Gimenez, R. Prats, et al., Thrombotic microangiopathy of pulmonary tumors: a vascular cause of tree-in-bud pattern on CT, *AJR Am. J. Roentgenol.* 179 (2002) 897–899, <https://doi.org/10.2214/ajr.179.4.1790897>.
- [6] S. Nguyen, D. Ouvrier, D. Massalou, et al., Lymphedema of the lower limbs: initial manifestation of gastric linitis plastica, *Ann. Dermatol. Venereol.* 144 (8–9) (2017) 530–535, <https://doi.org/10.1016/j.annder.2017.03.008>.
- [7] G. Lanznaster, M. Adami, C. Crivellaro, et al., Gastric signet-ring cell carcinoma: unilateral lower extremity lymphedema as the presenting feature, *Sci. World J.* 7 (2007) 1189–1192, <https://doi.org/10.1100/tsw.2007.199>.
- [8] N. Mogulkoc, B. Onal, N. Okyay, et al., Chylothorax, chylopericardium and lymphedema—the presenting features of signet-ring cell carcinoma, *Eur. Respir. J.* 13 (6) (1999) 1489–1491.
- [9] B. Hegemann, P. Helmbold, W.C. Marsch, Genital inflammatory lymphedema: peculiar microvascular long-distance metastasis of gastric carcinoma, *Br. J. Dermatol.* 144 (2) (2001) 419–420, <https://doi.org/10.1046/j.1365-2133.2001.04042.x>.
- [10] K. Shibata, S. Kitagawa, M. Fujimura, et al., Chylothorax associated with inflammatory carcinoma, *Intern. Med.* 37 (6) (1998) 538–541, <https://doi.org/10.2169/internalmedicine.37.538>.
- [11] H. Uruga, T. Fujii, A. Kurosaki, et al., Pulmonary tumor thrombotic microangiopathy: a clinical analysis of 30 autopsy cases, *Intern. Med.* 52 (2013) 1317–1323, <https://doi.org/10.2169/internalmedicine.52.9472>.
- [12] R.H. Godbole, R. Saggarr, N. Kamangar, et al., Pulmonary tumor thrombotic microangiopathy: a systemic review, 2045894019851000, *Pulm. Circ.* 9 (2) (2019), <https://doi.org/10.1177/2045894019851000>.
- [13] A. Ogawa, I. Yamadori, O. Matsubara, H. Matsubara, Pulmonary tumor thrombotic microangiopathy with circulatory failure treated with imatinib, *Intern. Med.* 52 (2013) 1927–1930, <https://doi.org/10.2169/internalmedicine.52.0718>.
- [14] N. Kumar, L.C. Price, M.A. Montero, et al., Pulmonary tumour thrombotic microangiopathy: unclassifiable pulmonary hypertension? *Eur. Respir. J.* 46 (2015) 1214–1217, <https://doi.org/10.1183/13993003.00052-2015>.
- [15] N. Hazeki, K. Kobayashi, M. Yamamoto, et al., Pulmonary tumor thrombotic microangiopathy associated with cancer of unknown origin, *J. Jpn. Respir. Soc.* 47 (11) (2009).
- [16] P.A. Gayathri, D.J. Kusum, P. Sandhya, Pulmonary tumor thrombotic microangiopathy in an unknown primary cancer, *Lung India* 31 (4) (2014), <https://doi.org/10.4103/0970-2113.142153>.
- [17] M. Tanaka, K. Takahashi, Y. Kurihara, et al., Signet ring cell carcinoma of unknown primary complicated with pulmonary tumor thrombotic microangiopathy and krukenberg tumor, *Case Rep Oncol* 11 (2018) 412–417, <https://doi.org/10.1159/000490528>.
- [18] J. Keith Pinckard, Mark R. Wich, Tumor-related thrombotic pulmonary microangiopathy: review of pathologic findings and pathophysiologic mechanisms, *Ann. Diagn. Pathol* 4 (2000) 154–157, [https://doi.org/10.1016/s1092-9134\(00\)90038-8](https://doi.org/10.1016/s1092-9134(00)90038-8).
- [19] S. Minatsuki, I. Miura, A. Yao, et al., Platelet-derived growth factor receptor-tyrosine kinase inhibitor, imatinib, is effective for treating pulmonary hypertension induced by pulmonary tumor thrombotic microangiopathy, *Int. Heart J.* 56 (2015) 245–248, <https://doi.org/10.1536/ihj.14-220>.
- [20] H. Kayatani, K. Matsuo, Y. Ueda, et al., Pulmonary tumor thrombotic microangiopathy diagnosed antemortem and treated with combination chemotherapy, *Intern. Med.* 51 (2012) 2767–2770, <https://doi.org/10.2169/internalmedicine.51.7682>.