

REVIEW

Bone metabolism in Langerhans cell histiocytosis

Athanasios D Anastasilakis¹, Marina Tsoi², Gregory Kaltsas² and Polyzois Makras³¹Department of Endocrinology, 424 General Military Hospital, Thessaloniki, Greece²1st Propaedeutic Department of Internal Medicine, National and Kapodistrian University of Athens, Athens, Greece³Department of Endocrinology and Diabetes, 251 Hellenic Air Force & VA General Hospital, Athens, GreeceCorrespondence should be addressed to A D Anastasilakis: a.anastasilakis@gmail.com

Abstract

Langerhans cell histiocytosis (LCH) is a rare disease of not well-defined etiology that involves immune cell activation and frequently affects the skeleton. Bone involvement in LCH usually presents in the form of osteolytic lesions along with low bone mineral density. Various molecules involved in bone metabolism are implicated in the pathogenesis of LCH or may be affected during the course of the disease, including interleukins (ILs), tumor necrosis factor α , receptor activator of NF- κ B (RANK) and its soluble ligand RANKL, osteoprotegerin (OPG), periostin and sclerostin. Among them IL-17A, periostin and RANKL have been proposed as potential serum biomarkers for LCH, particularly as the interaction between RANK, RANKL and OPG not only regulates bone homeostasis through its effects on the osteoclasts but also affects the activation and survival of immune cells. Significant changes in circulating and lesional RANKL levels have been observed in LCH patients irrespective of bone involvement. Standard LCH management includes local or systematic administration of corticosteroids and chemotherapy. Given the implication of RANK, RANKL and OPG in the pathogenesis of the disease and the osteolytic nature of bone lesions, agents aiming at inhibiting the RANKL pathway and/or osteoclastic activation, such as bisphosphonates and denosumab, may have a role in the therapeutic approach of LCH although further clinical investigation is warranted.

Key Words

- ▶ Langerhans cell histiocytosis (LCH)
- ▶ receptor activator of NF- κ B ligand (RANKL)
- ▶ denosumab
- ▶ bisphosphonates
- ▶ osteoporosis

Endocrine Connections
(2018) **7**, R246–R253

Introduction

Langerhans cell histiocytosis (LCH) is a predominantly pediatric disease with an annual incidence ranging from 2 to 9 cases per million while it is even more rarely encountered in adults, with an estimated annual incidence of approximately 1 case per 560,000 inhabitants (1, 2, 3). It is considered as an 'orphan disease' due to the paucity of information regarding its pathogenesis, clinical course, management and long-term prognosis. The adult form of the disease can develop at any age with a mean age of 33 years at diagnosis and may exert a different course than in children (2).

LCH may affect any organ or system and, depending on the organ involvement, it can be classified either as a single-system or a multisystem disease (4). Most frequently affected organs include the bones, lungs, pituitary gland and skin while the lymph nodes, liver, spleen, intestine and central nervous system are less frequently involved. Clinical manifestations are various according to the tissue involved, and the course of the disease varies widely from being a self-limiting condition to a chronic disease with several remissions and recurrences (4). Bone involvement is the most common manifestation, observed in about

40% of adults while in children a painful bone lesion is the most usual manifestation with skin being the second most commonly involved organ (2, 5).

The aim of the present review is to provide an update on the skeletal manifestations of LCH, focusing on the lesional and systemic alterations of factors involved in bone metabolism, and the potential therapeutic implications for both bone and multisystem LCH management.

LCH pathogenesis

LCH is characterized by clonal proliferation and dissemination of specific dendritic cells (DCs) resembling normal epidermal Langerhans cells (LCs) that exhibit positive immunohistochemistry for cluster designation 1a (CD1a), Langerin (CD207) and S100 protein (Fig. 1) (6, 7, 8). It has been proposed to be either an inflammatory or a neoplastic disorder with the latter to be favored by most experts; however, the pathogenesis of the disease remains largely unknown, whereas another distinct feature of the disease is that it may resolve spontaneously. Altered expression of cytokines and cellular adhesion molecules important for the migration and homing of LCs has been described (9). On the other hand, the infiltration of organs by a monoclonal cell population and the discovery of v-Raf murine sarcoma viral oncogene homolog B (BRAF) mutations in LCH lesions point toward a neoplastic rather than an inflammatory nature of the disease (1, 10). A combining hypothesis considers LCH to be an inflammatory neoplasia as LCH cells harboring oncogenic mutations proliferate and accumulate in LCH lesions recruiting and activating inflammatory cells, including T-lymphocytes, macrophages, plasma cells, eosinophils, neutrophils, natural killer cells and osteoclast-like multinucleated giant cells (MGCs) (11, 12). These infiltrating cells produce a variety of cytokines and chemokines that stimulate each other and lead to

a cytokine ‘storm’ that facilitates the recruitment of LCH cells progenitors as well as their maturation and inhibits their apoptosis. Multiple cytokines released in LCH lesions lead to local amplification cascades of cellular proliferation and activation through autocrine and paracrine stimulatory pathways (13). Granulocyte/macrophage colony-stimulating factor (GM-CSF), interleukin-1 (IL-1) and tumor necrosis factor α (TNF- α) play an important role in the maturation and migration of LCs (14). In addition, IL-2, IL-3, IL-4, IL-6, IL-7, IL-10, interferon- γ , CD-40 ligand, receptor activator of nuclear factor κ B (NF- κ B) ligand (RANKL), osteoprotegerin (OPG), IL-17 and soluble IL-2 receptor have been found to be increased in both the serum and the LCH lesions (9, 15, 16, 17, 18). Particularly macrophage colony-stimulating factor (M-CSF) and RANKL have been proposed to stimulate the fusion of normal dendritic cells in forming osteoclast-like MGCs that are present in osseous and non-osseous lesions and produce enzymes that play a major role in tissue destruction (19, 20).

IL-1 α , IL-1 β and TNF- α are abundantly expressed in these lesions and may synergistically enhance osteoclastic activity leading to the development of osteolytic LCH bone lesions. Furthermore, interferon- γ (IFN- γ) may enhance the osteolytic capacity of LCH cells through increased release of IL-1 (13, 15). Fibrosis developed in later stages during the LCH course could be attributed to the lesional production of transforming growth factor- β (TGF- β), which is considered to be a potent sclerosing agent (21).

Recent genomic studies have identified somatic mutations in mitogen-activated protein kinase pathway genes and specifically, BRAF V600E mutations that account for around 50% of cases. Mutations in the mitogen-activated protein kinase kinase 1 (MAP2K1) and v-Raf murine sarcoma viral oncogene homolog A (ARAF) genes have also been recently associated with LCH (22). The identification of these genomic changes has led to

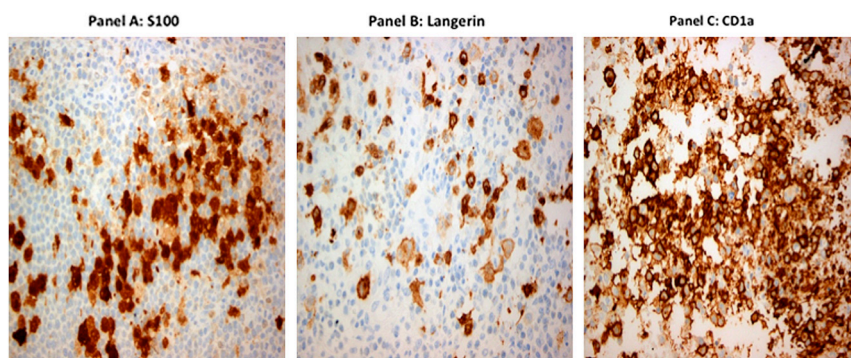


Figure 1
S-100 (panel A), Langerin (panel B) and CD1a (panel C) immunorexpression in Langerhans cell histiocytosis lesions (magnification $\times 400$). Immunostains are indicated in brown color from bone lesions.

the introduction of agents, such as vemurafenib and trametinib, which target the proteins encoded by these genes, as new treatment options (23, 24). In addition, some studies have implicated the expression of vascular endothelial growth factor (VEGF), Bcl-2 family proteins, Fas-signaling and E-cadherin-beta-catenin-Wnt signaling pathways in the pathogenesis of LCH (25, 26, 27).

Bone metabolism and inflammation in LCH

The interaction between the skeletal and immune system has long been recognized since the two systems share a lot of regulatory mechanisms including cytokines, signaling molecules, receptors and transcription factors (28).

Osteoclasts are multinucleated cells derived from macrophage/monocyte precursors that are specialized in bone degradation (29). As DCs and osteoclasts originate from the same myeloid precursor, common factors usually regulate their function (30). Osteoblasts, the principal bone-forming cells, and osteocytes stimulate osteoclast formation, differentiation and activation mainly by secreting RANKL, which binds to the receptor activator of nuclear factor- κ B (RANK) on the surface of osteoclast precursors and mature osteoclasts leading to their activation (31). Additionally, osteoblasts produce M-CSF, thereby amplifying the effect of RANKL on osteoclastogenesis. Furthermore, both osteoblasts and osteocytes secrete a decoy receptor, OPG, which binds to RANKL and blocks its actions, thus controlling osteoclastic bone resorption (32). RANK, RANKL and OPG are members of the TNF superfamily.

Besides bone, RANK and RANKL are also expressed by various cells of the immune system, as RANKL is found on T and B cells and RANK on DCs, macrophages and monocytes. The interplay between T cells and DCs through RANK/RANKL interaction ameliorates the growth and activation of T cells and enhances the activation and survival of DCs rendering them more efficient antigen presenters (33, 34, 35).

In LCH patients, giant osteoclast-like multinucleated cells have been observed in osseous and non-osseous lesions that can be activated by M-CSF and RANKL expressed in T cells or LCH cells (20). In children with active LCH serum RANKL/OPG ratio was positively correlated with osteolytic activity (36). In a recent study, high serum OPG and low serum RANKL levels have been found in LCH patients with and without bone involvement, irrespectively of the disease activity, extent, duration and treatment. It was speculated that a shift of

circulating RANKL in LCH lesions with a concomitant increase in cell-bound concentrations and a compensatory increase in OPG, which acts as a circulating decoy receptor could be responsible for these findings (16). In accordance with this hypothesis, immunohistochemical staining of LCH lesions has revealed abundant expression of RANKL in pathological LCs and/or other cells within osseous and non-osseous lesions (37). In addition, RANKL was associated with concomitant activation of NF- κ B, which is the main downstream effector of RANKL signaling, suggesting that RANKL may cause local cell activation (37).

LCH has been associated with a tendency for inflammation-related bone loss (38). Cytokine production in LCH lesions increases bone turnover and accelerates the rate of bone loss (28, 39). It has been speculated that DCs differentiate into osteoclast-like cells or that RANKL-expressing CD4+ T cells directly cause osteoclastogenesis and bone loss (40, 41). Indeed, a recent study in mice showed that *in vivo* ablation of LCs was associated with increased bone resorption secondary to an increased number of RANKL-expressing CD4+ T cells (30). Therefore, LCs are considered to display a protective role in bone tissue homeostasis, which is probably lost in pathological LCH cells. In addition, bone loss can be attributed to the conventional treatment with glucocorticoids or chemotherapy as well as to anterior pituitary hormone deficiencies (42, 43).

Periostin is a secreted extracellular matrix protein expressed in collagen-rich connective tissues. Through its interaction with cell-surface integrins, periostin plays a variety of roles in tissue remodeling after injury and tumor development (44). In bones, periostin serves both as a structural molecule of the bone matrix and a signaling molecule that stimulates osteoblast functions and bone formation through inhibition of sclerostin production and subsequent Wnt/ β -catenin pathway stimulation (45). In postmenopausal women, periostin serum levels have been associated with increased fracture risk, independently of bone mineral density, suggesting an effect on the organic rather than the mineral component of the bone (46, 47). In addition, circulating periostin has been explored as a potential biomarker in several diseases such as in asthma and various cancer types (48). Adult patients with active LCH were reported to have lower serum periostin levels than controls independently of the presence of bone involvement and of bone markers of osteoblastic or osteoclastic activity (49). Furthermore, patients with active disease had lower periostin levels compared to those with inactive disease independently of the site of involvement, extent of disease or treatment

administered, suggesting that serum periostin could serve as a biomarker for LCH activity.

Sclerostin is a small protein, produced mainly by the osteocytes, that inhibits osteoblastic bone formation through downregulation of the Wnt/ β -catenin pathway (50). In the same study reporting the periostin levels in LCH patients, no difference in sclerostin levels between LCH patients and controls was observed while LCH patients were lacking the typical inverse correlation between sclerostin and periostin, suggesting a bone-independent mechanism driving the serum periostin decrease (49). Therefore, lowering of periostin levels in LCH could represent a protective mechanism against disease-induced tissue changes in order to prevent fibrosis although further investigation is warranted (49, 51).

Skeletal manifestations in LCH

Osseous involvement in LCH presents mainly in the form of osteolytic lesions (2). It could present as a single lytic lesion either isolated or as part of multisystem disease or as multiple bone lesions in the context of single-system LCH or as part of a multisystem disease. The majority of lesions are asymptomatic but painful swelling leading to significant morbidity as well as pathologic fractures may occur. On physical examination, a soft and sensitive protuberance can be detected. Lytic skull lesions and jaw lesions are frequently observed while vertebrae, ribs, pelvic bones and proximal long bones can also be affected (52). Lytic skull lesions are the most frequent finding in

children while in adults the most commonly affected site is the mandible (Fig. 2), whereas skull lesions are not always lytic. Intracranial extension or impingement on the dura can be developed. Patients with involvement of the central nervous system (CNS) ‘risk’ bones (skull base, maxillofacial bones, orbital bones) are at greater risk for development of diabetes insipidus and CNS infiltration. In addition, depending on the location of the lesions, otitis media, orbital proptosis or tooth loss due to mandible infiltration may occur. Occasionally, osteolytic lesions can lead to fractures or vertebral collapse and spinal cord compression (1, 2, 53).

Imaging characteristics differ according to the stage of the disease. During the active phase, plain radiographs (Fig. 2) can reveal single or multiple lytic lesions with poorly defined margins. Medullary destruction, cortical erosion and a periosteal reaction could be observed (54, 55). Later on during the course of the disease, remodeling of the lesion begins and a sclerotic reaction could be seen. On MRI, tissues surrounding the lesion may appear edematous (Fig. 2). Radionuclide bone scanning has been proposed to evaluate the extent of skeletal involvement, but its sensitivity is lower than that of the x-rays (54, 55). Fluorodeoxyglucose (FDG) positron emission tomography (PET) scanning has recently been used for the evaluation of patients with LCH (Fig. 2) and has been proved to be highly sensitive in identifying active bone lesions (56).

In a recent study, 20% of adult patients with LCH had bone mineral density (BMD) below the expected age range. All patients over 50 years of age had osteopenia or osteoporosis, whereas patients with active disease

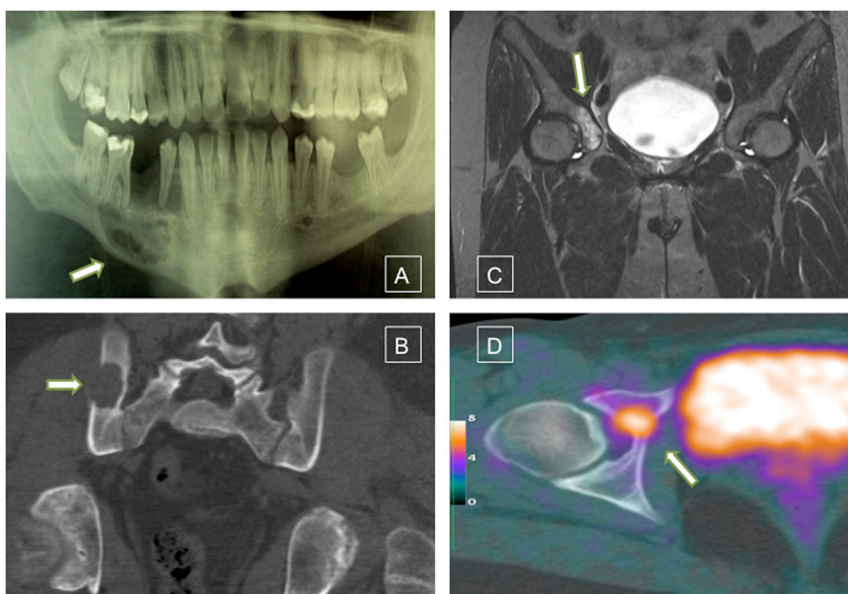


Figure 2 Mandibular osteolytic lesion depicted in plain radiograph evaluation (panel A); CT image of an osteolytic iliac bone lesion (panel B); circumscribed osteolytic lesion at the inner section of the right acetabulum with surrounding edema showed in an MRI image (panel C) and the same lesion as depicted in a PET-CT scan image (panel D).

have lower BMD compared to controls and patients with inactive disease (38).

Although the radiographic appearance of LCH lesions is sometimes characteristic and thus frequently suggested in the radiology reports, the diagnosis should be solely based on histopathologic and immunophenotypic examination of a lesional biopsy. In biopsy specimens from active lesions, diffuse sheets of LCH cells and bone destruction are observed (8). The LCs are antigen-presenting cells that stain positive for CD1a and/or Langerin but pathologic LCs are immature cells that proliferate moderately and present antigens inefficiently. In LCH lesions, LCH cells, macrophages, eosinophils and T-lymphocytes are observed while multinucleated osteoclastic giant cells can also be present (8). In addition, infoldings of the cell membrane form intracytoplasmic structures that are specific for LCs and are called Birbeck granules (57, 58). Immunological staining for Langerin or CD1a or presence of Birbeck granules on electronic microscopy in combination with clinical-pathological evidence on microscopic examination are required for definite LCH diagnosis (4). Rarely, plasma cells or bone cyst formation can be observed (8).

Treatment strategies in LCH bone lesions

Recommended management

In patients with single-system LCH and unifocal bone involvement of non-CNS-risk bones local therapy or follow-up can be recommended. Intralesional corticosteroid injection, low-dose irradiation or surgical curettage have been used. However, complete surgical excision is not always recommended as it may sometimes increase the healing time and/or leave a large bone deficit that would be difficult to be filled. Systemic chemotherapy is administered in case of multisystem disease or single-system disease with multiple lesions or involvement of high-risk organs (CNS, liver, spleen, bone marrow) (4). A recent study has reported that cytosine arabinoside (ARA-C) is the most effective and least toxic regimen for treatment of LCH bone lesions (59). However, due to the increased incidence of adverse effects with chemotherapy, less toxic approaches such as antiresorptive agents are often considered, especially when there is solely or predominantly skeletal involvement (37, 60).

Bisphosphonates are chemical analogs of pyrophosphates that inhibit osteoclast activity and reduce bone resorption (61). They have been successfully

used as a therapeutic and preventive treatment strategy in management of patients with bone metastases from various tumors (62). Their beneficial effect in LCH bone lesions was first reported in 1989 when clodronate was used to treat multifocal eosinophilic granuloma of bone (63). Subsequently, several case reports confirmed the effectiveness of bisphosphonates in treating bone disease in patients with LCH (64, 65).

In a Japanese survey, pamidronate resulted in the resolution of bone lesions in 75% of children with reactivated LCH (66). In a recent study, in both children and adults, bisphosphonates significantly improved bone pain and restored functional status without significant adverse effects (60). Complete remission of active bone LCH was observed in 92% of the patients. These outcomes were not related to the type or the dose of the agent used. More importantly, bisphosphonates, especially pamidronate, have been proved to be beneficial in cases of non-ostotic LCH such as skin and soft tissue lesions (60, 67). The most common adverse effects of bisphosphonates are hypocalcemia and acute phase reaction while a rare but clinically significant adverse effect is osteonecrosis of the jaw (62, 68). No serious adverse effects have been reported in patients with LCH treated with bisphosphonates (60).

Novel treatment approaches

Denosumab, an antibody targeting RANKL, has been used as a treatment in osteoporosis and has recently been approved for diminishing the risk of skeletal-related events in patients with bone metastases from solid tumors (69, 70). In addition, there is expanding evidence that denosumab has anti-tumor effect either by changing the bone microenvironment or via RANKL inhibition in non-cancerous cells like immune cells (35). As patients with and without bone involvement have high OPG and low RANKL serum levels (16), and RANKL is highly expressed in active LCH lesions concomitantly with activation of p56 NF- κ B (37), the inhibition of RANKL could benefit not just skeletal but all cases of LCH regardless of the lesions location (37, 71). This hypothesis was tested and confirmed in two patients with multisystem LCH in whom the administration of denosumab resulted in almost full resolution of bone and lung lesions with concomitant rapid and significant remission of pain (6). The dose used was 120 mg every other month with a total of four doses. No adverse effects were developed during denosumab treatment while no relapse was observed during the 6 months that followed the last denosumab

injection. A phase II trial is currently on-going aiming to verify these findings in a larger number of LCH patients (NCT03270020).

Conclusion

In conclusion, LCH is a rare disease with frequent skeletal involvement. Various aspects of bone metabolism are implicated in the pathogenesis of LCH or are affected during the course of the disease. Significant changes of serum and lesional RANKL levels have been observed in LCH patients with and without bone involvement. Antiresorptive agents such as bisphosphonates and denosumab have a role in the therapeutic approach of LCH bone involvement although further clinical investigation is warranted.

Declaration of interest

A D A has received lecture fees from Amgen and VIANEX. P M has received lecture fees and research grants from Amgen and lecture fees from ELPEN, Vianex. M T and G K have nothing to declare in respect to the subject.

Funding

This work did not receive any specific grant from any funding agency in the public, commercial, or not-for-profit sector.

References

- 1 Arico M, Girschikofsky M, Genereau T, Klersy C, McClain K, Grois N, Emile JF, Lukina E, De Juli E & Danesino C. Langerhans cell histiocytosis in adults. Report from the International Registry of the Histiocyte Society. *European Journal of Cancer* 2003 **39** 2341–2348. ([https://doi.org/10.1016/S0959-8049\(03\)00672-5](https://doi.org/10.1016/S0959-8049(03)00672-5))
- 2 Malpas JS. Langerhans cell histiocytosis in adults. *Hematology/Oncology Clinics of North America* 1998 **12** 259–268. ([https://doi.org/10.1016/S0889-8588\(05\)70509-8](https://doi.org/10.1016/S0889-8588(05)70509-8))
- 3 Stålemark H, Laurencikas E, Karis J, Gavhed D, Fadeel B & Henter JI. Incidence of Langerhans cell histiocytosis in children: a population-based study. *Pediatric Blood and Cancer* 2008 **51** 76–81. (<https://doi.org/10.1002/pbc.21504>)
- 4 Girschikofsky M, Arico M, Castillo D, Chu A, Doberauer C, Fichter J, Haroche J, Kaltsas GA, Makras P, Marzano AV, *et al.* Management of adult patients with Langerhans cell histiocytosis: recommendations from an expert panel on behalf of Euro-Histio-Net. *Orphanet Journal of Rare Diseases* 2013 **8** 72. (<https://doi.org/10.1186/1750-1172-8-72>)
- 5 PDQ Pediatric Treatment Editorial Board. *Langerhans Cell Histiocytosis Treatment (PDQ®): Health Professional Version. PDQ Cancer Information Summaries*. Bethesda, MD, USA: National Cancer Institute (US), 2017. (available at: <https://www.ncbi.nlm.nih.gov/books/NBK65799/>)
- 6 Arceci RJ. The histiocytoses: the fall of the Tower of Babel. *European Journal of Cancer* 1999 **35** 747–767. ([https://doi.org/10.1016/S0959-8049\(99\)00039-8](https://doi.org/10.1016/S0959-8049(99)00039-8))
- 7 Lau SK, Chu PG & Weiss LM. Immunohistochemical expression of Langerin in Langerhans cell histiocytosis and non-Langerhans cell histiocytic disorders. *American Journal of Surgical Pathology* 2008 **32** 615–619. (<https://doi.org/10.1097/PAS.0b013e31815b212b>)
- 8 Picarsic J & Jaffe R. Nosology and pathology of Langerhans cell histiocytosis. *Hematology/Oncology Clinics of North America* 2015 **29** 799–823. (<https://doi.org/10.1016/j.hoc.2015.06.001>)
- 9 Imashuku S & Arceci RJ. Strategies for the prevention of central nervous system complications in patients with Langerhans cell histiocytosis: the problem of neurodegenerative syndrome. *Hematology/Oncology Clinics of North America* 2015 **29** 875–893. (<https://doi.org/10.1016/j.hoc.2015.06.006>)
- 10 Badalian-Very G, Vergilio JA, Fleming M & Rollins BJ. Pathogenesis of Langerhans cell histiocytosis. *Annual Review of Pathology* 2013 **8** 1–20. (<https://doi.org/10.1146/annurev-pathol-020712-163959>)
- 11 Berres ML, Allen CE & Merad M. Pathological consequence of misguided dendritic cell differentiation in histiocytic diseases. *Advances in Immunology* 2013 **120** 127–161. (<https://doi.org/10.1016/B978-0-12-417028-5.00005-3>)
- 12 Bechan GI, Egeler RM & Arceci RJ. Biology of Langerhans cells and Langerhans cell histiocytosis. *International Review of Cytology* 2006 **254** 1–43. ([https://doi.org/10.1016/S0074-7696\(06\)54001-X](https://doi.org/10.1016/S0074-7696(06)54001-X))
- 13 Egeler RM, Favara BE, van Meurs M, Laman JD & Claassen E. Differential in situ cytokine profiles of Langerhans-like cells and T cells in Langerhans cell histiocytosis: abundant expression of cytokines relevant to disease and treatment. *Blood* 1999 **94** 4195–4201.
- 14 Hart DN. Dendritic cells: unique leukocyte populations which control the primary immune response. *Blood* 1997 **90** 3245–3287.
- 15 Garabedian L, Struyf S, Opendakker G, Sozzani S, Van Damme J & Laureys G. Langerhans cell histiocytosis: a cytokine/chemokine-mediated disorder? *European Cytokine Network* 2011 **22** 148–153. (<https://doi.org/10.1684/ecn.2011.0290>)
- 16 Makras P, Polyzos SA, Anastasilakis AD, Terpos E, Kanakis G, Schini M, Papatheodorou A & Kaltsas GA. Serum osteoprotegerin, RANKL, and Dkk-1 levels in adults with Langerhans cell histiocytosis. *Journal of Clinical Endocrinology and Metabolism* 2012 **97** E618–E621. (<https://doi.org/10.1210/jc.2011-2962>)
- 17 Hogarty MD. IL-17A in LCH: systemic biomarker, local factor, or none of the above? *Molecular Therapy* 2011 **19** 1405–1406. (<https://doi.org/10.1038/mt.2011.150>)
- 18 Makras P, Polyzos SA, Anastasilakis AD, Terpos E, Papatheodorou A & Kaltsas GA. Is serum IL-17A a useful systemic biomarker in patients with Langerhans cell histiocytosis? *Molecular Therapy* 2012 **20** 6–7. (<https://doi.org/10.1038/mt.2011.239>)
- 19 Abla O, Egeler RM & Weitzman S. Langerhans cell histiocytosis: current concepts and treatments. *Cancer Treatment Reviews* 2010 **36** 354–359. (<https://doi.org/10.1016/j.ctrv.2010.02.012>)
- 20 da Costa CE, Annels NE, Faaij CM, Forsyth RG, Hogendoorn PC & Egeler RM. Presence of osteoclast-like multinucleated giant cells in the bone and nonostotic lesions of Langerhans cell histiocytosis. *Journal of Experimental Medicine* 2005 **201** 687–693. (<https://doi.org/10.1084/jem.20041785>)
- 21 Border WA & Noble NA. Transforming growth factor beta in tissue fibrosis. *New England Journal of Medicine* 1994 **331** 1286–1292. (<https://doi.org/10.1056/NEJM199411103311907>)
- 22 Allen CE & Parsons DW. Biological and clinical significance of somatic mutations in Langerhans cell histiocytosis and related histiocytic neoplastic disorders. *Hematology American Society of Hematology Education Program* 2015 **2015** 559–564. (<https://doi.org/10.1182/asheducation-2015.1.559>)
- 23 Haroche J, Cohen-Aubart F, Emile JF, Donadieu J & Amoura Z. Vemurafenib as first line therapy in BRAF-mutated Langerhans cell histiocytosis. *Journal of the American Academy of Dermatology* 2015 **73** 29–30. (<https://doi.org/10.1016/j.jaad.2014.10.045>)
- 24 Papanagiotou M, Griewank KG, Hillen U, Schimming T, Moeller L, Fuhrer D, Zimmer L, Roesch A, Sucker A, Schadendorf D, *et al.* Trametinib-induced remission of an MEK1-mutated Langerhans cell histiocytosis. *JCO Clinical Cancer Informatics* 2017 **1** 1–5. (<https://doi.org/10.1200/PO.16.00070>)

- 25 Bank MI, Gudbrand C, Rengtved P, Carstensen H, Fadeel B, Henter JI & Petersen BL. Immunohistochemical detection of the apoptosis-related proteins FADD, FLICE, and FLIP in Langerhans cell histiocytosis. *Journal of Pediatric Hematology/Oncology* 2005 **27** 301–306. (<https://doi.org/10.1097/01.mph.0000168725.57143.52>)
- 26 Dina A, Zahava V & Iness M. The role of vascular endothelial growth factor in Langerhans cell histiocytosis. *Journal of Pediatric Hematology/Oncology* 2005 **27** 62–66. (<https://doi.org/10.1097/01.mph.0000154069.81149.5f>)
- 27 Marchal J, Kambouchner M, Tazi A, Valeyre D & Soler P. Expression of apoptosis-regulatory proteins in lesions of pulmonary Langerhans cell histiocytosis. *Histopathology* 2004 **45** 20–28. (<https://doi.org/10.1111/j.1365-2559.2004.01875.x>)
- 28 Takayanagi H. Osteoimmunology: shared mechanisms and crosstalk between the immune and bone systems. *Nature Reviews Immunology* 2007 **7** 292–304. (<https://doi.org/10.1038/nri2062>)
- 29 Hanaoka H. The origin of the osteoclast. *Clinical Orthopaedics and Related Research* 1979 **145** 252–263.
- 30 Arizon M, Nudel I, Segev H, Mizraji G, Elnekave M, Furmanov K, El-Berchoer L, Clausen BE, Shapira L, Wilensky A, *et al.* Langerhans cells down-regulate inflammation-driven alveolar bone loss. *PNAS* 2012 **109** 7043–7048. (<https://doi.org/10.1073/pnas.1116770109>)
- 31 Anastasilakis AD, Toulis KA, Polyzos SA & Terpos E. RANKL inhibition for the management of patients with benign metabolic bone disorders. *Expert Opinion on Investigational Drugs* 2009 **18** 1085–1102. (<https://doi.org/10.1517/13543780903048929>)
- 32 Asagiri M & Takayanagi H. The molecular understanding of osteoclast differentiation. *Bone* 2007 **40** 251–264. (<https://doi.org/10.1016/j.bone.2006.09.023>)
- 33 Anderson DM, Maraskovsky E, Billingsley WL, Dougall WC, Tometsko ME, Roux ER, Teepe MC, DuBose RF, Cosman D & Galibert L. A homologue of the TNF receptor and its ligand enhance T-cell growth and dendritic cell function. *Nature* 1997 **390** 175–179. (<https://doi.org/10.1038/36593>)
- 34 Wong BR, Josien R, Lee SY, Sauter B, Li HL, Steinman RM & Choi Y. TRANCE (tumor necrosis factor (TNF)-related activation-induced cytokine), a new TNF family member predominantly expressed in T cells, is a dendritic cell-specific survival factor. *Journal of Experimental Medicine* 1997 **186** 2075–2080. (<https://doi.org/10.1084/jem.186.12.2075>)
- 35 de Groot AF, Appelman-Dijkstra NM, van der Burg SH & Kroep JR. The anti-tumor effect of RANKL inhibition in malignant solid tumors – a systematic review. *Cancer Treatment Reviews* 2018 **62** 18–28. (<https://doi.org/10.1016/j.ctrv.2017.10.010>)
- 36 Ishii R, Morimoto A, Ikushima S, Sugimoto T, Asami K, Bessho F, Kudo K, Tsunematu Y, Fujimoto J & Imashuku S. High serum values of soluble CD154, IL-2 receptor, RANKL and osteoprotegerin in Langerhans cell histiocytosis. *Pediatric Blood and Cancer* 2006 **47** 194–199. (<https://doi.org/10.1002/pbc.20595>)
- 37 Makras P, Salagianni M, Revelos K, Anastasilakis AD, Schini M, Tsoli M, Kaltsas G & Andreakos E. Rationale for the application of RANKL inhibition in the treatment of Langerhans cell histiocytosis. *Journal of Clinical Endocrinology and Metabolism* 2015 **100** E282–E286. (<https://doi.org/10.1210/jc.2014-2654>)
- 38 Makras P, Terpos E, Kanakis G, Papatheodorou A, Anastasilakis AD, Kokkoris P & Kaltsas GA. Reduced bone mineral density in adult patients with Langerhans cell histiocytosis. *Pediatric Blood and Cancer* 2012 **58** 819–822. (<https://doi.org/10.1002/pbc.23166>)
- 39 Guerrini MM & Takayanagi H. The immune system, bone and RANKL. *Archives of Biochemistry and Biophysics* 2014 **561** 118–123. (<https://doi.org/10.1016/j.abb.2014.06.003>)
- 40 Alnaeeli M, Penninger JM & Teng YT. Immune interactions with CD4+ T cells promote the development of functional osteoclasts from murine CD11c+ dendritic cells. *Journal of Immunology* 2006 **177** 3314–3326. (<https://doi.org/10.4049/jimmunol.177.5.3314>)
- 41 Ju JH, Cho ML, Moon YM, Oh HJ, Park JS, Jhun JY, Min SY, Cho YG, Park KS, Yoon CH, *et al.* IL-23 induces receptor activator of NF-kappaB ligand expression on CD4+ T cells and promotes osteoclastogenesis in an autoimmune arthritis model. *Journal of Immunology* 2008 **181** 1507–1518. (<https://doi.org/10.4049/jimmunol.181.2.1507>)
- 42 Dalle Carbonare L, Arlot ME, Chavassieux PM, Roux JP, Portero NR & Meunier PJ. Comparison of trabecular bone microarchitecture and remodeling in glucocorticoid-induced and postmenopausal osteoporosis. *Journal of Bone and Mineral Research* 2001 **16** 97–103. (<https://doi.org/10.1359/jbmr.2001.16.1.97>)
- 43 Makras P, Alexandraki KI, Chrousos GP, Grossman AB & Kaltsas GA. Endocrine manifestations in Langerhans cell histiocytosis. *Trends in Endocrinology and Metabolism* 2007 **18** 252–257. (<https://doi.org/10.1016/j.tem.2007.06.003>)
- 44 Liu AY, Zheng H & Ouyang G. Periostin, a multifunctional extracellular matrix protein in inflammatory and tumor microenvironments. *Matrix Biology* 2014 **37** 150–156. (<https://doi.org/10.1016/j.matbio.2014.04.007>)
- 45 Bonnet N, Garnero P & Ferrari S. Periostin action in bone. *Molecular and Cellular Endocrinology* 2016 **432** 75–82. (<https://doi.org/10.1016/j.mce.2015.12.014>)
- 46 Rousseau JC, Sornay-Rendu E, Bertholon C, Chapurlat R & Garnero P. Serum periostin is associated with fracture risk in postmenopausal women: a 7-year prospective analysis of the OFELY study. *Journal of Clinical Endocrinology and Metabolism* 2014 **99** 2533–2539. (<https://doi.org/10.1210/jc.2013-3893>)
- 47 Anastasilakis AD, Polyzos SA, Makras P, Savvides M, Sakellariou GT, Gkiomisi A, Papatheodorou A & Terpos E. Circulating periostin levels do not differ between postmenopausal women with normal and low bone mass and are not affected by zoledronic acid treatment. *Hormone and Metabolic Research* 2014 **46** 145–149. (<https://doi.org/10.1055/s-0033-1351250>)
- 48 Idolazzi L, Ridolo E, Fassio A, Gatti D, Montagni M, Caminati M, Martignago I, Incorvaia C & Senna G. Periostin: the bone and beyond. *European Journal of Internal Medicine* 2017 **38** 12–16. (<https://doi.org/10.1016/j.ejim.2016.11.015>)
- 49 Anastasilakis AD, Polyzos SA, Tsoli M, Papatheodorou A, Kokkoris P, Kaltsas G, Terpos E & Makras P. Low periostin levels in adult patients with Langerhans cell histiocytosis are independently associated with the disease activity. *Metabolism* 2017 **71** 198–201. (<https://doi.org/10.1016/j.metabol.2017.03.017>)
- 50 Winkler DG, Sutherland MK, Geoghegan JC, Yu C, Hayes T, Skonier JE, Shpektor D, Jonas M, Kovacevich BR, Staehling-Hampton K, *et al.* Osteocyte control of bone formation via sclerostin, a novel BMP antagonist. *EMBO Journal* 2003 **22** 6267–6276. (<https://doi.org/10.1093/emboj/cdg599>)
- 51 Ashley SL, Wilke CA, Kim KK & Moore BB. Periostin regulates fibrocyte function to promote myofibroblast differentiation and lung fibrosis. *Mucosal Immunology* 2017 **10** 341–351. (<https://doi.org/10.1038/mi.2016.61>)
- 52 Haupt R, Minkov M, Astigarraga I, Schafer E, Nanduri V, Jubran R, Egeler RM, Janka G, Micic D, Rodriguez-Galindo C, *et al.* Langerhans cell histiocytosis (LCH): guidelines for diagnosis, clinical work-up, and treatment for patients till the age of 18 years. *Pediatric Blood and Cancer* 2013 **60** 175–184. (<https://doi.org/10.1002/pbc.24367>)
- 53 Haupt R, Nanduri V, Calevo MG, Bernstrand C, Braier JL, Broadbent V, Rey G, McClain KL, Janka-Schaub G & Egeler RM. Permanent consequences in Langerhans cell histiocytosis patients: a pilot study from the Histiocyte Society-Late Effects Study Group. *Pediatric Blood and Cancer* 2004 **42** 438–444. (<https://doi.org/10.1002/pbc.20021>)
- 54 Hoover KB, Rosenthal DI & Mankin H. Langerhans cell histiocytosis. *Skeletal Radiology* 2007 **36** 95–104. (<https://doi.org/10.1007/s00256-006-0193-2>)

- 55 Khung S, Budzik JF, Amzallag-Bellenger E, Lambilliotte A, Soto Ares G, Cotten A & Boutry N. Skeletal involvement in Langerhans cell histiocytosis. *Insights into Imaging* 2013 **4** 569–579. (<https://doi.org/10.1007/s13244-013-0271-7>)
- 56 Phillips M, Allen C, Gerson P & McClain K. Comparison of FDG-PET scans to conventional radiography and bone scans in management of Langerhans cell histiocytosis. *Pediatric Blood and Cancer* 2009 **52** 97–101. (<https://doi.org/10.1002/pbc.21782>)
- 57 Favara BE, Feller AC, Pauli M, Jaffe ES, Weiss LM, Arico M, Bucky P, Egeler RM, Elinder G, Gadner H, *et al.* Contemporary classification of histiocytic disorders. The WHO Committee On Histiocytic/Reticulum Cell Proliferations. Reclassification Working Group of the Histiocyte Society. *Medical and Pediatric Oncology* 1997 **29** 157–166. ([https://doi.org/10.1002/\(SICI\)1096-911X\(199709\)29:3<157::AID-MPO1>3.0.CO;2-C](https://doi.org/10.1002/(SICI)1096-911X(199709)29:3<157::AID-MPO1>3.0.CO;2-C))
- 58 Valladeau J, Ravel O, Dezutter-Dambuyant C, Moore K, Kleijmeer M, Liu Y, Duvert-Frances V, Vincent C, Schmitt D, Davoust J, *et al.* Langerin, a novel C-type lectin specific to Langerhans cells, is an endocytic receptor that induces the formation of Birbeck granules. *Immunity* 2000 **12** 71–81. ([https://doi.org/10.1016/S1074-7613\(00\)80160-0](https://doi.org/10.1016/S1074-7613(00)80160-0))
- 59 Cantu MA, Lupo PJ, Bilgi M, Hicks MJ, Allen CE & McClain KL. Optimal therapy for adults with Langerhans cell histiocytosis bone lesions. *PLoS ONE* 2012 **7** e43257. (<https://doi.org/10.1371/journal.pone.0043257>)
- 60 Chellapandian D, Makras P, Kaltsas G, van den Bos C, Naccache L, Rampal R, Carret AS, Weitzman S, Egeler RM & Abla O. Bisphosphonates in Langerhans cell histiocytosis: an international retrospective case series. *Mediterranean Journal of Hematology and Infectious Diseases* 2016 **8** e2016033. (<https://doi.org/10.4084/mjhjd.2016.033>)
- 61 Shaw NJ & Bishop NJ. Bisphosphonate treatment of bone disease. *Archives of Disease in Childhood* 2005 **90** 494–499. (<https://doi.org/10.1136/adc.2003.036590>)
- 62 Drake MT, Clarke BL & Khosla S. Bisphosphonates: mechanism of action and role in clinical practice. *Mayo Clinic Proceedings* 2008 **83** 1032–1045. (<https://doi.org/10.4065/83.9.1032>)
- 63 Elomaa I, Blomqvist C, Porkka L & Holmstrom T. Experiences of clodronate treatment of multifocal eosinophilic granuloma of bone. *Journal of Internal Medicine* 1989 **225** 59–61. (<https://doi.org/10.1111/j.1365-2796.1989.tb00038.x>)
- 64 Arzoo K, Sadeghi S & Pullarkat V. Pamidronate for bone pain from osteolytic lesions in Langerhans'-cell histiocytosis. *New England Journal of Medicine* 2001 **345** 225. (<https://doi.org/10.1056/NEJM200107193450318>)
- 65 Montella L, Merola C, Merola G, Petillo L & Palmieri G. Zoledronic acid in treatment of bone lesions by Langerhans cell histiocytosis. *Journal of Bone and Mineral Metabolism* 2009 **27** 110–113. (<https://doi.org/10.1007/s00774-008-0001-2>)
- 66 Kamazono J, Okada Y, Shirahata A & Tanaka Y. Bisphosphonate induces remission of refractory osteolysis in langerhans cell histiocytosis. *Journal of Bone and Mineral Research* 2002 **17** 1926–1928. (<https://doi.org/10.1359/jbmr.2002.17.11.1926>)
- 67 Morimoto A, Shioda Y, Imamura T, Kanegane H, Sato T, Kudo K, Nakagawa S, Nakadate H, Tauchi H, Hama A, *et al.* Nationwide survey of bisphosphonate therapy for children with reactivated Langerhans cell histiocytosis in Japan. *Pediatric Blood and Cancer* 2011 **56** 110–115. (<https://doi.org/10.1002/pbc.22703>)
- 68 King AE & Umland EM. Osteonecrosis of the jaw in patients receiving intravenous or oral bisphosphonates. *Pharmacotherapy* 2008 **28** 667–677. (<https://doi.org/10.1592/phco.28.5.667>)
- 69 Makras P, Delaroudis S & Anastasilakis AD. Novel therapies for osteoporosis. *Metabolism* 2015 **64** 1199–1214. (<https://doi.org/10.1016/j.metabol.2015.07.011>)
- 70 Macedo F, Ladeira K, Pinho F, Saraiva N, Bonito N, Pinto L & Goncalves F. Bone metastases: an overview. *Oncology Reviews* 2017 **11** 321. (<https://doi.org/10.4081/oncol.2017.321>)
- 71 Makras P, Tsoli M, Anastasilakis AD, Thanou M & Kaltsas G. Denosumab for the treatment of adult multisystem Langerhans cell histiocytosis. *Metabolism* 2017 **69** 107–111. (<https://doi.org/10.1016/j.metabol.2017.01.004>)

Received in final form 27 June 2018

Accepted 2 July 2018

Accepted Preprint published online 2 July 2018