

# Injectable autologous chondrocyte implantation (ACI) in acetabular cartilage defects—three-year results

David R. Krueger<sup>1</sup>, Markus Gesslein<sup>2</sup>, Michael Schuetz<sup>1</sup>, Carsten Perka<sup>1</sup> and Joerg H. Schroeder<sup>1\*</sup>

<sup>1</sup>Center for Musculoskeletal Surgery, Charité-Universitätsmedizin Berlin, Charitéplatz 1, 10117 Berlin, Germany and <sup>2</sup>Department of Trauma and Orthopaedic Surgery, Paracelsus Medical University, Breslauer Straße 201, 90471 Nuremberg, Germany.

\*Correspondence to: J. H. Schroeder. E-mail: joerg.schroeder@charite.de

Submitted 7 May 2018; Revised 10 July 2018; revised version accepted 20 October 2018

## ABSTRACT

To evaluate the clinical outcome after arthroscopic matrix-associated injectable autologous chondrocyte implantation (ACI) in patients with large full-thickness acetabular cartilage defects. ACI was performed in young patients with full-thickness acetabular cartilage defects  $\geq 2$  cm<sup>2</sup> in a two-step arthroscopic procedure. The patients were followed closely with clinical examinations and pre- and postoperative scores. The modified Harris Hip Score (mHHS), iHOT33 questionnaire (iHOT33) and the Subjective Hip Value (SHV) were surveyed. Demographic patient data was evaluated for influencing factors for the pre- and postoperative results. Thirty-two consecutive cases (4 female, 28 male, mean age 33 years) were included. The average defect size was 4.9 (range: 2–6) cm<sup>2</sup>. They were followed at 6, 12, 24 and 36 months postoperatively. Patients had improved significantly from 64 to 91 points ( $P < 0.001$ ) in the mHHS, from 44% to 86% ( $P < 0.001$ ) in the iHOT33 and from 54% to 87% ( $P < 0.001$ ) in the SHV. No surgery related complications were noted. Cell cultivation failed in two cases (7%) and the patients decided for a repeated harvesting of cartilage cylinders followed by a successful ACI. Patients age and size of the cartilage defect showed no significant correlation with the pre- or postoperative results. Injectable ACI is a reliable procedure treating full-thickness acetabular cartilage defects leading to promising results 3 years postoperatively with a significant increase in all scores despite large acetabular cartilage defects in the weight-bearing zone.

## INTRODUCTION

Acetabular cartilage defects due to femoroacetabular impingement (FAI) represent a challenging condition in a mostly young patient population [1]. Cartilage defects resemble a severe pathology due to its limited healing potential and have shown to be the major prognostic factor in FAI surgery [2, 3]. Therefore, optimal therapy of acetabular cartilage defects is of great interest.

Autologous cartilage implantation (ACI) is an established therapy option for cartilage defects in the knee showing significant better functional scores and tissue regeneration in large defects compared with the microfracture procedure [4–7]. In hip surgery, microfracture has been the treatment

of choice for acetabular cartilage defects regardless of its size so far [3, 8–11]. Microfracture leads to a good filling of the cartilage defect but showed mostly fibrocartilaginous tissue regeneration in histopathologic evaluations [12].

With the good long-term results of ACI in knee surgery the technique has been transferred to the hip for the treatment of acetabular cartilage defects. First investigations showed excellent results of the ACI procedure using scaffold material in the hip [13, 14], but the use of a scaffold is technically demanding in the concave acetabulum and has the risk of a scaffold dislocation [15]. Therefore, scaffold free matrix-associated injectable agents have been developed with the potential of an easier and less invasive

implantation process. Those agents have no need of a scaffold material as they are applied as highly adhesive spheres or gel. First studies could proof the feasibility of this procedure even in the 'overhanging' situation of the typical anterolateral acetabular defects in patients in supine position [16, 17]. Early results are promising but only showed a limited follow-up time of 12 months [18].

### PURPOSE

To evaluate the clinical outcome after arthroscopic matrix-associated injectable autologous chondrocyte implantation (ACI) in patients with large full-thickness acetabular cartilage defects.

Our hypothesis was that modern cellular cartilage procedures allow favorable results despite large acetabular cartilage defects.

### MATERIALS AND METHODS

Patients with symptomatic FAI after failed conservative therapy were offered an ACI procedure in case of a suspected cartilage defect in the routinely performed preoperative MRI. In case of an intraoperative confirmation of a full-thickness cartilage defect  $\geq 2 \text{ cm}^2$  and the patient request an ACI procedure was initiated by harvesting osteochondral cylinders from the head neck junction for cell cultivation. In a second arthroscopic surgery, the cultivated chondrocytes were implanted directly into the debrided defect area.

The study was approved by the local institutional review board (EA2/154/14).

#### Inclusion criteria

Patients under the age of 50 years with an isolated acetabular full-thickness cartilage defect  $\geq 2 \text{ cm}^2$  in a contained defect situation and a minimum of follow-up of 36 months.

#### Exclusion criteria

Patients older than 50 years, patients with a Kellgren and Lawrence Score [19]  $>1$ , combined acetabular and femoral cartilage defects, radiological signs for dysplasia (Center Edge Angle  $<25^\circ$ , Tonnis Angle  $>10^\circ$ ) and patients unwilling to undergo a two-step ACI procedure.

#### Surgical technique

The patient was placed in supine position on a radiolucent carbon extension device (MAQUET, Rastatt, Germany). Special care was taken that the perineal post and feet were well padded. Hip arthroscopy was performed starting peripheral first and the underlying cam deformity was corrected thoroughly using a burr. After safely establishing portals to the central compartment [20], the labral and

cartilage damage was investigated. In case of an acetabular cartilage defect  $\geq 2 \text{ cm}^2$  the defect area was debrided using a curette to create a stable margin (Fig. 1). The size of the cartilage defect was measured using an arthroscopic probe with a defined 5 mm marking at the tip. The width and length of the defect area were then multiplied for the calculation of the defect size. Labral tears were repaired in either labral base or loop technique depending on the quality of the labrum [21, 22]. If a segmental labral defect was present, a labral reconstruction was performed. Finally, cartilage-bone cylinders were harvested from the head-neck junction using an arthroscopic cartilage punch (Karl Storz, Tuttlingen, Germany). The cylinders along with patient's serum were sent to the laboratory (co.don AG, Teltow, Germany) for further cell cultivation.

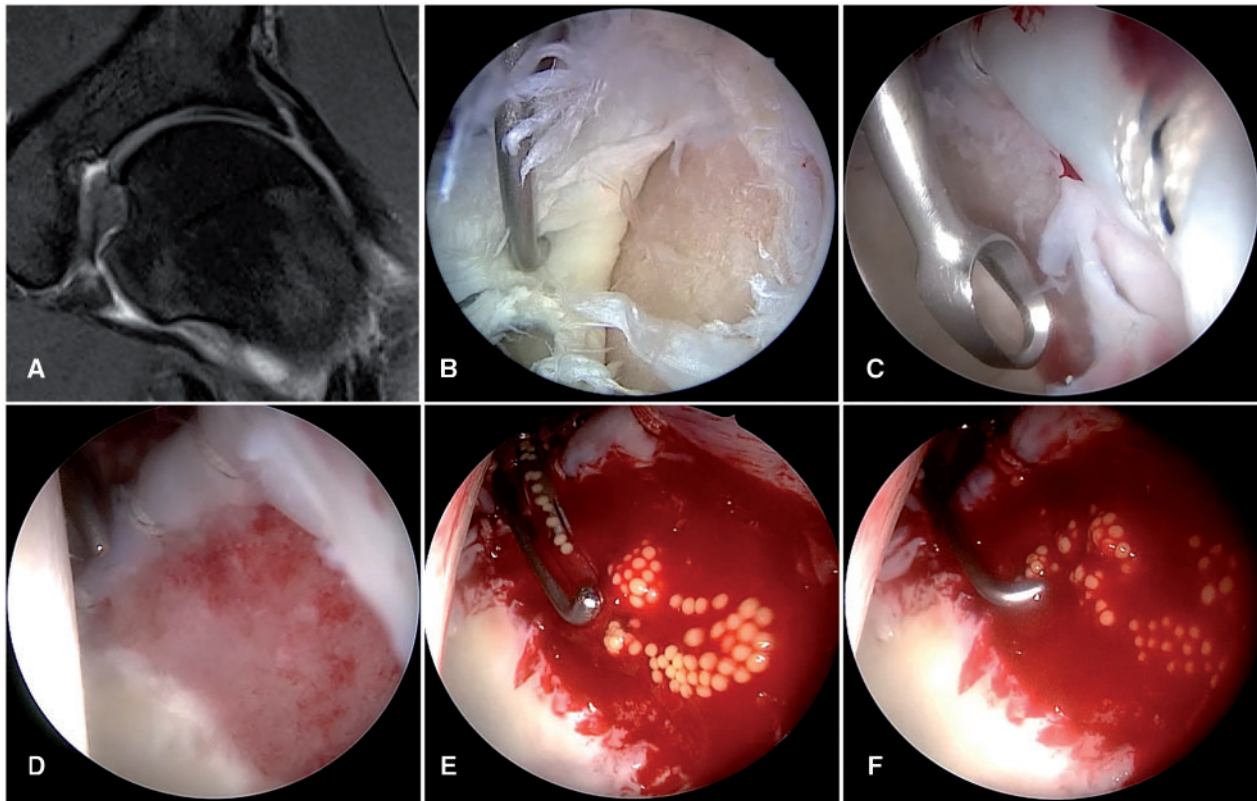
After cell cultivation, the chondrocyte spheroids were implanted in a second arthroscopic surgery usually 6–8 weeks later. Intraoperatively the stability of the labrum as well as the integrity and the margins of the healthy cartilage were reinsured to reconfirm a contained defect situation. The defect area was debrided again using a curette. After removing all fluid out of the joint, the chondrocytes were injected directly into the defect and evenly distributed (Fig. 1). The joint was kept dry and under traction for another 20 min to ensure a proper adhesion of the spheroids.

#### Rehabilitation protocol

Indomethacin was administered for 3 weeks postoperatively for heterotopic ossification prophylaxis. Patients were kept with 15 kg partial weight bearing for 6 weeks after the ACI. Physiotherapy and continuous passive motion (CPM) or static cycling was executed from the first postoperative day. Non-impact sports were allowed after 3 months and impact sports 6 months after the procedure. Full contact sports were not recommended until 1 year postoperatively.

#### Evaluation

Patients were evaluated before the index surgery and 6, 12, 24 and 36 months postoperatively by a clinical consultation using the following hip specific questionnaires: modified Harris Hip Score (mHHS), international Hip Outcome Tool (iHOT33) and a subjective hip assessment (Subjective Hip Value; SHV) [23, 24]. For the subjective hip value, comparable with the subjective shoulder value [25], the patient was asked to give the affected hip a value between 0% and 100% compared with an unimpaired normal hip. All data until the last available follow-up data is provided. The minimal clinically important difference (MCID) was calculated for the mHHS and the iHOT33 regarding the previously determined MCID standards



**Fig. 1.** Arthroscopy of the central compartment of a left hip of a 26-year-old male patient. (A) MRI showing a large inverted ‘Oreo’ cookie sign [37]. (B) The diagnostic evaluation shows a large full-thickness acetabular cartilage flap with disruption of the chondrolabral transition zone. (C) The defect is debrided using a curette. (D) Contained cartilage defect after debridement of the unstable cartilage parts and refixation of the labrum. (E and F) Eight weeks after the initial hip arthroscopy the spheroids are inserted using the applicator.

[26]. The percentage of patients meeting the minimal clinically important difference was calculated. For the Subjective Hip Value, there is no defined MCID yet.

#### Statistical evaluation

The statistical analysis was performed using the IBM SPSS Statistics software (IBM Corp. Released 2013. IBM SPSS Statistics, Version 22.0. Armonk, NY: IBM Corp.). Differences between preoperative and postoperative scores were evaluated for significance using the Wilcoxon Test. The level of significance was set at  $P < 0.05$ . The correlation coefficient  $r$  was calculated for exploration of influencing demographic and patient specific data, like age and size of the cartilage defect, on the preoperative and postoperative results.

#### RESULTS

Thirty-two consecutive hips (Table I) with a minimum follow-up of 36 months who were treated with an ACI for acetabular cartilage defects. One male patient was treated

with a bilateral ACI procedure. There were 4 female and 28 male cases and the mean age was 33 (range: 18–49) years. In 13 cases the left and in 19 cases the right hip was affected. The average defect size measured 4.9 (range: 2–6)  $\text{cm}^2$ . In 7 cases a cam FAI and in 25 cases a combined cam and pincer impingement was present.

The average time between the initial procedure with harvesting of the chondrocytes and the autologous chondrocyte implantation was 9 (6–10) weeks. Two patients were not available after the 1-year-follow-up (one patient not contactable, one female patient in treatment for breast cancer, follow-up rate at the 2- and 3-year follow-up 94%).

The arthroscopic ACI application was feasible in all cases. No surgery related complications were noted. In two cases (7%) cell cultivation failed due to unknown reason. These two patients decided to undergo a second harvest procedure and the repeated cell cultivation was successful. Despite a third surgery the two patients were satisfied with the surgical result, reporting 95 and 96 points in the mHHS, 98% and 100% in the iHOT33 and 95% and 100% in the SHV.

**Table I. Patient demographics**

Characteristics	Results (range)
Age in years	32 (18–49)
Cases	32
Male	28
Female	4
Defect size in cm <sup>2</sup>	4.9 (2–6)
Average follow-up in months	35.5 (24–49)
FAI type	
Cam	7
Pincer	0
Combined	25

Evaluation of the outcome measurements showed a significant increase ( $P < 0.05$ ) between the preoperative scores and all follow-up data in the mHHS, iHOT33 and the SHV (Fig. 2). At the final follow-up of 3 years, the scores had improved from 64 to 91 points ( $P < 0.001$ ) in the mHHS, from 44% to 86% ( $P < 0.001$ ) in the iHOT33 and from 54% to 87% ( $P < 0.001$ ) in the SHV. The percentage of patients meeting the MCIS was 93% for the mHHS and 100% for the iHOT33. In the mHHS the scores consolidated after the 6-month follow-up, showing higher average scores without statistically significant differences ( $P > 0.05$ ). For the iHOT33 the patients improved statistically significant between all follow-up times except between 12 and 24 ( $P = 0.21$ ) and 24 and 36 months ( $P = 0.065$ ). The same improvements could be seen for the SHV were the differences between the 12 and 24 ( $P = 0.61$ ) and the 24- and 32-month follow up showed no statistically significant differences.

The age did not show a relevant influence on the pre- or postoperative results in the mHHS, iHOT33 or the SHV. Interestingly, the age at the time of operation had a significant correlation with the size of the cartilage defect ( $r = 0.41$ ,  $P = 0.038$ ). Patients with a smaller cartilage defect ( $<$ median defect size of 4.75 cm<sup>2</sup>) were significantly younger than patients with larger defects in this patient population (29.6 versus 34.2 years,  $P = 0.044$ ). The size of the cartilage defect showed no relevant correlation with the pre- or postoperative results in the mHHS, iHOT33 and the SHV at any time.

Gender specific evaluation showed lower average preoperative scores in the four female patients compared with

the male patients. They presented with lower average scores in the mHHS (50 versus 65 points), iHOT33 (37 versus 45%) and SHV (45 versus 54). In the postoperative follow-up controls, relevant differences could no longer be seen in the mHHS (88 versus 92 points) in the iHOT33 (87 versus 86%) and in the SHV (85 versus 88%). The four female patients were slightly older (37 versus 33 years) and the initial size of the cartilage defect was marginally larger in female patients (5, 1 versus 4, 8 cm<sup>2</sup>). Due to the small sample size of female patients in this cohort, no statistical analysis of the differences in male and female patients was performed.

### Complications

No surgery related complications were noted. In two cases (7%) cell cultivation failed due to unknown reason. These two patients decided to undergo a second harvest procedure and the repeated cell cultivation was successful. Despite a third surgery the two patients were satisfied with the surgical result, reporting 95 and 96 points in the mHHS, 98% and 100% in the iHOT33 and 95% and 100% in the SHV.

### DISCUSSION

In this investigation, we could show that that ACI in large cartilage defects creates good to excellent 3-year results. The patients continuously improved from preoperative to the latest postoperative follow-up with 93% of the patients meeting the MCID in the mHHS and 100% in the iHOT33. This was seen best in the nuanced and rather subjective scoring systems like the iHOT33 and the SHV although the higher average scores among 12, 24 and 36 months showed no statistically significant differences. In contrast to that, the mHHS rapidly improved in the early postoperative stage to a maximum. This reveals the limitations and the known sealing effect of this score [26], who was not designed as a score for hip preservation surgery in the first place. It is known that the mHHS does not capture any differences in 25% of the observations at the upper end of the scales [27, 28] and may therefore overestimate the patients' function after hip arthroscopy and may not resemble the patients' satisfaction in the typical young and active patient population [29]. The results also show that the biggest improvements are seen within 1 year after surgery, which tend to show further improvements after 1 year but without statistical significance.

Cartilage defects resemble the most important prognostic factor in FAI surgery with several investigations reporting poorer outcome in patients with large cartilage defects [2, 30–32]. According to this we detected low average scores preoperatively in the mHHS (64 points) as well as in patient reported outcome tools like the iHOT33 (44%)



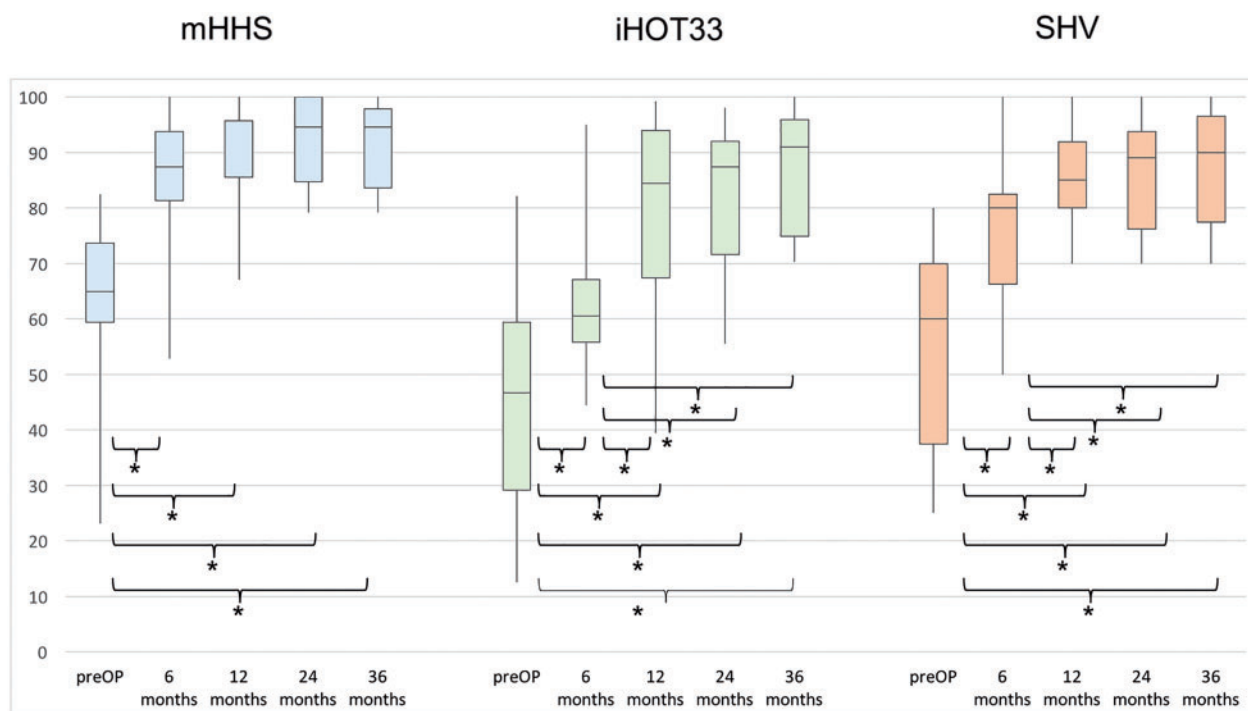


Fig. 2. Outcome measurement tools at the different follow-up times. \* $P < 0.05$ .

and the SHV (54%), reflecting relevant complaints in daily living of the patients. Despite the large cartilage defects (average  $4.9 \text{ cm}^2$ ) in this series, the patients improved significantly after FAI correction and the ACI procedure, showing excellent mid-term results (mHHS 91 points, iHOT33 86%, SHV 87%) after 36 months.

Compared with previous reported results we could find no correlation between the size of the cartilage defect and the postoperative results in the scores. A medium but not significant correlation ( $r = -0.52$ ) was reported before between the cartilage defect size and the subjective patient satisfaction 12 months postoperatively [18]. In this investigation with a larger patient population and a longer follow-up, this effect could not be confirmed any more.

Interestingly the data showed that the size of the cartilage defect correlated significantly with the age of the patient ( $r = 0.41$ ,  $P = 0.038$ ). Patient with a cartilage defect size smaller than the median size in this population were significantly younger. This might be caused by the longer duration of the FAI and emphasizes early diagnosis and treatment of symptomatic patients.

Age itself resembled no predicting factor for the pre- or postoperative results in this patient population. This is supported by findings that hip arthroscopy is a valuable tool even in the elderly patient without relevant signs of osteoarthritic changes [33].

Only 13% of this population consisted of female patients. This may be interpreted by the higher incidence of cam impingement in male patients [34]. Although we could show poorer preoperative results in those four female patients compared with the male population, the results equaled in the postoperative controls.

Though no surgery related complications could be seen, cell cultivation failed in two patients. This is a relevant problem as it either means an additional surgery for the patient for repeated cartilage–bone cylinder harvesting with a prolonged rehabilitation due to the delayed ACI procedure or a complete failure of the ACI procedure leaving the large defect only with a cartilage debridement from the initial surgery. In the two cases the patients decided to undergo a second cartilage harvesting with a successful ACI procedure. The patients were satisfied with their outcome showing excellent results in the scores.

Treatment options for large acetabular cartilage defects are still a matter of debate. The injectable autologous chondrocyte implantation resembles a new treatment option. As there is no need for a scaffold material, it offers a technically less demanding arthroscopic option without the risk of a dislocation of the scaffold material [15, 35]. Early studies could show the feasibility of this procedure in the setting of hip arthroscopy [16, 17] and short-term results have been promising [18, 36].

### Limitations

One limitation is the relatively small sample size, but still this study represents the largest published number of patients treated with an injectable ACI in the hip. The lack of a randomized control group comparing the ACI with other cartilage therapies like the microfracture procedure is a weakness of the study. Generating a numerically sufficient control cohort is difficult in those patients, as most of the patients choose the potentially more successful ACI in large cartilage defects.

### CONCLUSION

Injectable ACI is a reliable procedure treating full-thickness acetabular cartilage defects leading to promising results 3 years postoperatively with a significant increase in all scores despite large acetabular cartilage defects in the weight-bearing zone.

### CONFLICT OF INTEREST STATEMENT

None declared.

### REFERENCES

1. Byrd JW, Jones KS. Arthroscopic femoroplasty in the management of cam-type femoroacetabular impingement. *Clin Orthop Relat Res* 2009; **467**: 739–46.
2. Egerton T, Hinman RS, Takla A *et al*. Intraoperative cartilage degeneration predicts outcome 12 months after hip arthroscopy. *Clin Orthop Relat Res* 2013; **471**: 593–9.
3. Haviv B, Singh PJ, Takla A *et al*. Arthroscopic femoral osteochondroplasty for cam lesions with isolated acetabular chondral damage. *J Bone Jt Surg Br* 2010; **92-B**: 629–33.
4. Saris DB, Vanlauwe J, Victor J. Treatment of symptomatic cartilage defects of the knee: characterized chondrocyte implantation results in better clinical outcome at 36 months in a randomized trial compared to microfracture. *Am J Sports Med* 2009; **37**(Suppl. 1): 10S–9S.
5. Saris DBF, Vanlauwe J, Victor J *et al*. Characterized chondrocyte implantation results in better structural repair when treating symptomatic cartilage defects of the knee in a randomized controlled trial versus microfracture. *Am J Sports Med* 2008; **36**: 235–46.
6. Kon E, Filardo G, Berruto M. Articular cartilage treatment in high-level male soccer players: a prospective comparative study of arthroscopic second-generation autologous chondrocyte implantation versus microfracture. *Am J Sports Med* 2011; **39**: 2549–57.
7. Fu FH, Zurakowski D, Browne JE *et al*. Autologous chondrocyte implantation versus debridement for treatment of full-thickness chondral defects of the knee: an observational cohort study with 3-year follow-up. *Am J Sports Med* 2005; **33**: 1658–66.
8. Wright TM, Maher SA. Current and novel approaches to treating chondral lesions. *J Bone Jt Surg Am* 2009; **91**(Suppl. 1): 120–5.
9. Yen YM, Kocher MS. Chondral lesions of the hip: microfracture and chondroplasty. *Sports Med Arthrosc Rev* 2010; **18**: 83–9.
10. Philippon MJ, Schenker ML, Briggs KK *et al*. Can microfracture produce repair tissue in acetabular chondral defects? *Arthroscopy* 2008; **24**: 46–50.
11. Crawford K, Philippon MJ, Sekiya JK *et al*. Microfracture of the hip in athletes. *Clin Sports Med* 2006; **25**: 327–35.
12. Karthikeyan S, Roberts S, Griffin D. Microfracture for acetabular chondral defects in patients with femoroacetabular impingement: results at second-look arthroscopic surgery. *Am J Sports Med* 2012; **40**: 2725–30.
13. Mancini D, Fontana A. Five-year results of arthroscopic techniques for the treatment of acetabular chondral lesions in femoroacetabular impingement. *Int Orthop* 2014; **38**: 2057–64.
14. Fontana A, Bistolfi A, Crova M *et al*. Arthroscopic treatment of hip chondral defects: autologous chondrocyte transplantation versus simple debridement—a pilot study. *Arthroscopy* 2012; **28**: 322–9.
15. Thorey F, Budde S, Ezechieli M *et al*. Feasibility of arthroscopic placement of autologous matrix-induced chondrogenesis grafts in the cadaver hip joint. *Orthop Rev (Pavia)* 2013; **5**: 26.
16. Krueger DR, Karczewski D, Ballhausen M *et al*. Is a minimal invasive autologous chondrocyte implantation (ACI) in the hip possible? A feasibility and safety study of arthroscopic treatment of full thickness acetabular cartilage defects with an injectable ACI. *Sci Pages Orthop Surg* 2017; **1**: 1–6.
17. Fickert S, Schattenberg T, Niks M *et al*. Feasibility of arthroscopic 3-dimensional, purely autologous chondrocyte transplantation for chondral defects of the hip: a case series. *Arch Orthop Trauma Surg* 2014; **134**: 971–8.
18. Schroeder JH, Hufeland M, Schutz M *et al*. Injectable autologous chondrocyte transplantation for full thickness acetabular cartilage defects: early clinical results. *Arch Orthop Trauma Surg* 2016; **136**: 1445–51.
19. Kellgren JH, Lawrence JS. Radiological assessment of osteoarthritis. *Ann Rheum Dis* 1957; **16**: 494–502.
20. Dienst M, Seil R, Kohn DM. Safe arthroscopic access to the central compartment of the hip. *Arthroscopy* 2005; **21**: 1510–4.
21. Fry R, Domb B. Labral base refixation in the hip: rationale and technique for an anatomic approach to labral repair. *Arthroscopy* 2010; **26**: S81–S9.
22. Jackson TJ, Hanypsiak B, Stake CE *et al*. Arthroscopic labral base repair in the hip: clinical results of a described technique. *Arthroscopy* 2014; **30**: 208–13.
23. Harris WH. Traumatic arthritis of the hip after dislocation and acetabular fractures: treatment by mold arthroplasty. An end-result study using a new method of result evaluation. *J Bone Jt Surg Am* 1969; **51**: 737–55.
24. Mohtadi NG, Griffin DR, Pedersen ME *et al*. The development and validation of a self-administered quality-of-life outcome measure for young, active patients with symptomatic hip disease: the International Hip Outcome Tool (iHOT-33). *Arthroscopy* 2012; **28**: 595–605; quiz 06–10 e1.
25. Gilbert MK, Gerber C. Comparison of the subjective shoulder value and the Constant score. *J Shoulder Elbow Surg* 2007; **16**: 717–21.

26. Kemp JL, Collins NJ, Roos EM *et al.* Psychometric properties of patient-reported outcome measures for hip arthroscopic surgery. *Am J Sports Med* 2013; **41**: 2065–73.
27. Øvre S, Sandvik L, Madsen JE *et al.* Comparison of distribution, agreement and correlation between the original and modified Merle d'Aubigne-Postel Score and the Harris Hip Score after acetabular fracture treatment: moderate agreement, high ceiling effect and excellent correlation in 450 patients. *Acta Orthop* 2005; **76**: 796–802.
28. Wamper KE, Sierevelt IN, Poolman RW *et al.* The Harris hip score: do ceiling effects limit its usefulness in orthopedics? *Acta Orthop* 2010; **81**: 703–7.
29. Aprato A, Jayasekera N, Villar RN. Does the modified Harris hip score reflect patient satisfaction after hip arthroscopy? *Am J Sports Med* 2012; **40**: 2557–60.
30. McCarthy JC, Jarrett BT, Ojeifo O *et al.* What factors influence long-term survivorship after hip arthroscopy? *Clin Orthop Relat Res* 2011; **469**: 362–71.
31. Singh PJ, O'Donnell JM. The outcome of hip arthroscopy in Australian football league players: a review of 27 hips. *Arthroscopy* 2010; **26**: 743–9.
32. Bogunovic L, Gottlieb M, Pashos G *et al.* Why do hip arthroscopy procedures fail? *Clin Orthop Relat Res* 2013; **471**: 2523–9.
33. Domb BG, Linder D, Finley Z *et al.* Outcomes of hip arthroscopy in patients aged 50 years or older compared with a matched-pair control of patients aged 30 years or younger. *Arthroscopy* 2015; **31**: 231–8.
34. Nepple JJ, Riggs CN, Ross JR *et al.* Clinical presentation and disease characteristics of femoroacetabular impingement are sex-dependent. *J Bone Jt Surg Am* 2014; **96**: 1683–9.
35. Libera J, Luethi U, Alasevic O. Autologous matrix-induced engineered cartilage transplantation. In: S Zanasi, M Bittenberg, M Marcacci (eds). *Basic science, clinical repair and reconstruction of articular defects: current status and prospects, Vol. 1.* Italy, 2006, 591–600.
36. Thier S, Weiss C, Fickert S. Arthroscopic autologous chondrocyte implantation in the hip for the treatment of full-thickness cartilage defects—a case series of 29 patients and review of the literature. *SICOT J* 2017; **3**: 72.
37. Beaulé PE, Zaragoza EJ. Surgical images: musculoskeletal acetabular cartilage delamination demonstrated by magnetic resonance arthrography: inverted “Oreo” cookie sign. *Can J Surg* 2003; **46**: 463–4.