

Cocaine-induced vasculitis with cutaneous manifestation: A recurrent episode after 2 years

Thein Swe¹, Mona Pervil-Ulysse², AAM A. Baqui³

Departments of ¹Internal Medicine and ³Pathology, Interfaith Medical Center, ²Division of Rheumatology, Interfaith Medical Center, Brooklyn, New York, USA

ABSTRACT

Cocaine is a popular recreational drug in the United States, and up to 70% of the seized cocaine contains levamisole which is an antihelminthic that can cause cutaneous vasculitis with necrosis and positive antineutrophil cytoplasmic antibodies (ANCA). Here, we report a unique case of recurrent cocaine-induced vasculitis in a patient who smokes cocaine for more than 20 years. A 38-year-old woman complained of painful erythematous rash in her right arm and right thigh which appeared some hours after smoking cocaine. Physical examination revealed tender, erythematous base, retiform purpura with necrosis and bullae. Serological test showed high atypical perinuclear ANCA titer of 1:320 and antimyeloperoxidase antibody level of 20.4 U/mL. Cocaine-induced vasculitis should be one of the differential diagnoses in cocaine abusers who present with painful rash and areas of necrosis. Early diagnosis is important since it is an emerging public health concern.

Keywords: Atypical perinuclear antineutrophil cytoplasmic antibody, cocaine-induced vasculitis, retiform purpura

Introduction

Levamisole is an imidazothiazole derivative with immunomodulatory properties used currently in the United States as an antihelminthic drug in veterinary medicine. It was used in the past to treat inflammatory conditions and malignancies, such as rheumatoid arthritis, leukemia, and as an adjuvant therapy to 5-fluorouracil for colorectal cancer. However, levamisole was discontinued for human use in the United States in 2000 due to neutropenia, agranulocytosis, skin necrosis, and vasculitis.^[1,2] The United States Drug Enforcement Agency first found levamisole mixed with cocaine in 2003. In 2009, levamisole was adulterant in about 70% of seized cocaine.^[3]

Case Report

A 38-year-old woman with a medical history of hypertension, chronic obstructive pulmonary disease, osteoarthritis of knees,

chronic smoker, and cocaine abuser presented to the emergency department with complaints of painful body rash which appeared within some hours after smoking cocaine. The rash first appeared on her right arm, followed by rash on the right thigh, left thigh, and left arm. This rash was associated with a burning pain, ten out of ten in intensity without radiation and mostly located on her right arm and right thigh. There was no skin peeling or purulent discharge noted. She denied having any oral or genital mucosal ulcer. She denied any physical injury, fall, pruritus, gastrointestinal symptoms, genitourinary symptoms, fever, chills, chest pain, dyspnea, headache, blurring of vision, dizziness or urinary symptoms. She denied any other systemic complaint. Her home medications include amlodipine, albuterol inhaler as needed, and acetaminophen as needed. She has never been prescribed any anticoagulant including warfarin.

Although she has been smoking cocaine for more than 20 years, the first episode of skin rash post cocaine use did not occur until 3 years ago. At that time, the rash also occurred on bilateral legs

Address for correspondence: Dr. Thein Swe,
400 Herkimer Street, Apt 1K, Brooklyn, New York 11213, USA.
E-mail: mglay2004@gmail.com

Access this article online

Quick Response Code:



Website:
www.jfmpc.com

DOI:
10.4103/2249-4863.197294

This is an open access article distributed under the terms of the Creative Commons Attribution-NonCommercial-ShareAlike 3.0 License, which allows others to remix, tweak, and build upon the work non-commercially, as long as the author is credited and the new creations are licensed under the identical terms.

For reprints contact: reprints@medknow.com

How to cite this article: Swe T, Pervil-Ulysse M, Baqui AA. Cocaine-induced vasculitis with cutaneous manifestation: A recurrent episode after 2 years. *J Family Med Prim Care* 2016;5:712-5.

and she was admitted to a local hospital. She underwent skin biopsy and it revealed vasculitis with fibrin-platelet thrombi consistent with levamisole-induced vasculitis. She was counseled to stop using cocaine and was treated with intravenous steroid followed by tapered dose of prednisone. The next episode of similar rash lesions of bilateral legs developed in 2014 after smoking cocaine and she again responded to steroids treatment. Six days prior admission to our hospital, she used a larger amount of cocaine than usual (200 dollar-worth). She denied any allergy to cold weather, food, or medications.

Initial vital signs included a temperature of 98°F, pulse rate 98 beats/min, respiratory rate 18 breaths/min, blood pressure 105/72 mmHg, and oxygen saturation 97% on room air.

Physical examination revealed tender, retiform, violaceous necrotic purpuric lesions with overlying bullae and healed old scars on both lower extremities on posterior aspect of the right thigh and right arm [Figures 1 and 2]. There was no pus or discharge. Pulmonary examination as well as cardiovascular, central nervous system, abdominal examinations were within normal limits.

Initial laboratory tests showed white blood cells $4.1 \times 10^9/L$, normal differentials, erythrocyte sedimentation rate 52 mm/h, C-reactive protein 22.1 mg/L, hemoglobin 12 g/dL, hematocrit 35.3%, platelets 363,000/ μL , blood urea nitrogen 22 mg/dL, creatinine 0.8 mg/dL, glomerular filtration rate 85.32 ml/min, and total creatine kinase 51 IU/L. Comprehensive metabolic panel, kidney function test, liver function tests, and coagulation profile were within normal limits. Urinalysis revealed high specific gravity with proteinuria (100 mg/dL) and 5–15 red blood cells per high power field. Urine toxicology test was positive for cocaine. Levamisole levels were not done. Serological tests for human immunodeficiency virus, hepatitis A, B, C virus, and rapid plasma regain were negative. Immunologic tests revealed positive antinuclear antibody with nucleolar pattern, high atypical perinuclear antineutrophil cytoplasmic antibody (atypical P-ANCA), 1:320

titer (normal: <1:20), antimyeloperoxidase (MPO) antibody 20.4 U/mL (normal: 0–9 U/mL) with negative P-ANCA. Cytoplasmic ANCA (C-ANCA) and anti-proteinase 3 (PR3) antibody were negative. Rheumatoid factor, JO-1 antibody, Sjögren’s antibody, Sjögren’s syndrome type B antibody, antinuclear antibody, antidouble-strand deoxyribonucleic acid, anti-Smith antibody, centromere B antibody, complement C3, C4, total complement (CH50) levels, and chest X-ray were within normal limits. Testing for cryoglobulins, lupus anticoagulant, anticardiolipin antibody, antiphospholipid antibody, and antihuman neutrophil elastase (HNE) antibodies was not done. Serology tests results done during episodes of cocaine-induced vasculitis within 3 years showed high titers of P-ANCA [Table 1].

In 2013 and 2014, vasculitic panels showed a positive P-ANCA with high anti-MPO antibody. However, in 2016, atypical P-ANCA pattern with high anti-MPO antibody was found.

A punch skin biopsy of 3 mm in diameter and 2 mm in length was performed from her right upper leg lesion. Low

Table 1: Summary of serology tests results within 3 years of recurrent vasculitis episodes

Test	Normal range	2013	2014	2016
Antinuclear antibody	Negative	Negative	Negative	Positive
Anti-Scl 70 antibody	Negative	Negative	Negative	Negative
Anti-SS-B antibody	Negative	Negative	Negative	Negative
Rheumatoid factor	Negative	Negative	Negative	Negative
Anticardiolipin IgM	Negative	Negative	Negative	Not done
Cryoglobulin	Negative	Negative	Negative	Not done
Complement C3 (mg/dL)	82-167	90	86	101
Complement C4 (mg/dL)	14-44	20	22	16
P-ANCA	<1:20 titer	1:640	1:640	<1:20
Atypical P-ANCA	<1:20 titer	<1:20	<1:20	1:320
MPO antibody (U/mL)	0-9	27	23	20.4
C-ANCA	<1:20 titer	<1:20	<1:20	<1:20
PR3 antibody (U/mL)	0-3.5	2	2.1	3

P-ANCA: Perinuclear antineutrophil cytoplasmic antibody; MPO: Myeloperoxidase; C-ANCA: Cytoplasmic antineutrophil cytoplasmic antibodies; PR3: Proteinase 3; SS-B: Sjögren’s syndrome type B

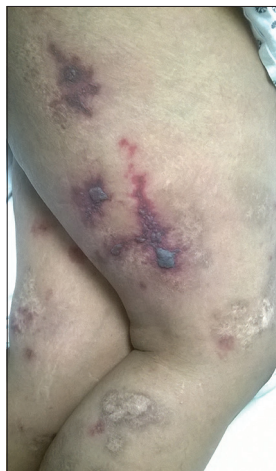

Figure 1: Retiform, violaceous necrotic purpuric lesions with overlying bullae and healed old scars on the right thigh

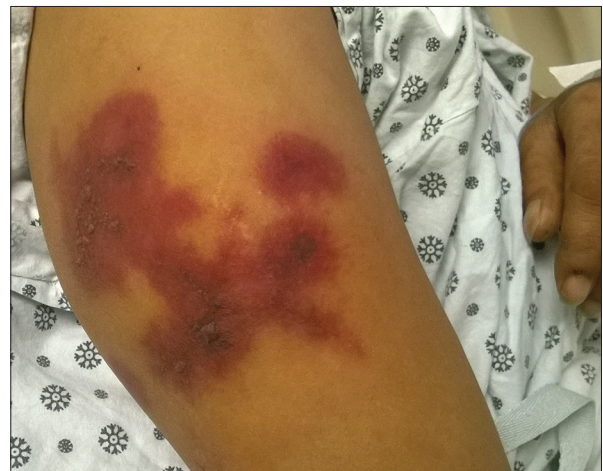

Figure 2: Retiform, violaceous necrotic purpuric lesions with overlying bullae on the right arm

magnification (×10) hematoxylin and eosin (H and E) stain showed superficial and deep vasculitis and perivasculitis [Figure 3]. In higher magnification (×40), the H and E section revealed leukocytoclastic vasculitis with fibrinoid necrosis and a mixed inflammatory cell infiltrate composed of neutrophils, eosinophils, and lymphocytes. There was marked leukocytoclasia (karyorrhexis and nuclear dust). Focal area showed marked red cell extravasation and vascular thrombosis [Figure 4].

The patient was counseled to stop using cocaine and was treated with methylprednisolone 125 mg intravenously on the admission day. Oral prednisone 60 mg daily was started on day 1 and continued for 3 days. The improvement from skin lesions was seen after 72 h from admission [Figures 5 and 6]. Tenderness over skin lesions was resolved. Prednisone 40 mg per os was given on day 4 and she was discharged with oral prednisone 20 mg daily for 1 week, followed by 10 mg daily for another week. She was recommended to follow-up with rheumatology clinic; however, she did not follow-up.

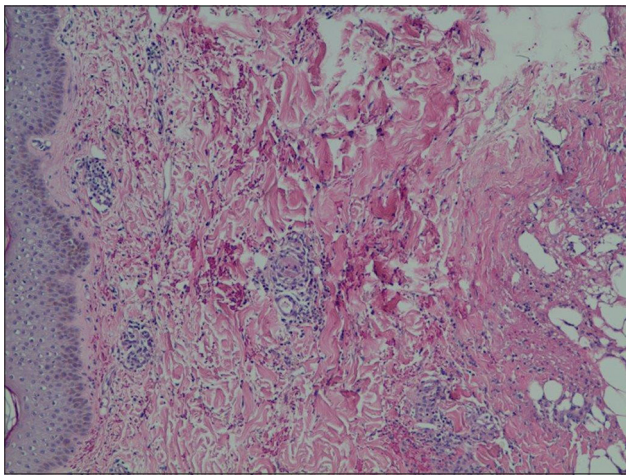


Figure 3: Low magnification hematoxylin and eosin skin section showed superficial and deep vasculitis and perivasculitis (×10)

Discussion

Complications related to levamisole-adulterated cocaine users were first reported in 2009. There is high level of recurrence about 27% of symptoms in cocaine users after reexposure to cocaine that is mixed with levamisole.^[1] Cutaneous manifestations include reticulated purpuric lesions with hemorrhagic bullae and necrosis and have a predilection for the ears, cheeks, zygomatic arch, and lower extremities. The possible mechanism of levamisole causing vasculitis is immune mediated, with antibodies directed against neutrophils and vasculitis caused by antibody deposition. P-ANCA found in levamisole-adulterated cocaine exposure is often directed against atypical P-ANCA-associated antigens in the neutrophil granules such as HNE, lactoferrin, and cathepsin G.^[4,5] Moreover, antiphospholipid antibodies and antinuclear antibodies are also often present.

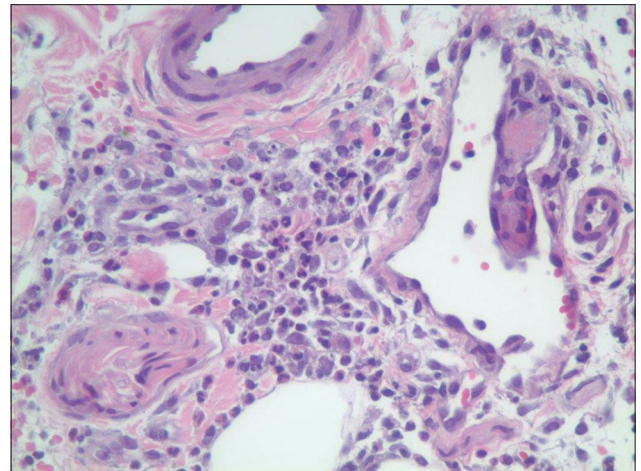


Figure 4: High magnification hematoxylin and eosin section showed leukocytoclastic vasculitis with fibrinoid necrosis and a mixed inflammatory cell infiltrate composed of neutrophils, eosinophils, and lymphocytes. There were leukocytoclasia (karyorrhexis and nuclear dust), focal red cell extravasation, and vascular thrombosis (×40)

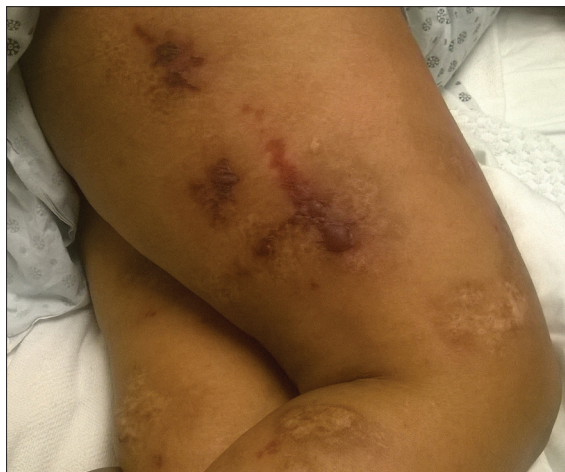

Figure 5: Improvement of necrotic areas and redness on the right thigh 72 h after steroid treatment and cessation of cocaine

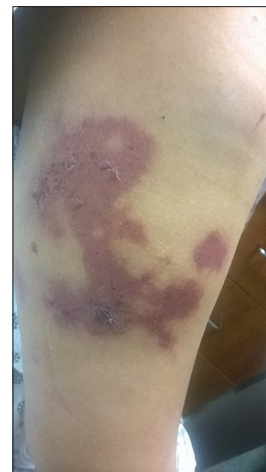

Figure 6: Improvement of necrotic areas and redness on right arm 72 h after steroid treatment and cessation of cocaine

Differential diagnoses of tender, purpuric rash include autoimmune connective tissue disorders, Wegener's granulomatosis, microscopic polyangiitis, idiopathic thrombocytopenic purpura, and warfarin- or heparin-induced skin necrosis. Specific antibodies and other systemic signs and symptoms can distinguish them. Wegener's granulomatosis typically has C-ANCA directed against PR3 and microscopic polyangiitis mostly revealed P-ANCA targeting MPO.^[2]

Biopsies of the skin lesions often demonstrate thrombotic vasculitis or leukocytoclastic vasculitis with or without vascular occlusion.^[6,7] The inflammation infiltrates the vascular walls and into the perivascular zones and often reveals prominent leukocytoclastic debris (nuclear dust). Furthermore, fibrinoid necrosis of vascular walls can be found and extends into the adjacent perivascular connective tissue. Extravasation of red blood cells is also a frequent histologic finding.^[4]

Treatment is usually supportive and most skin lesions improve upon cessation of cocaine use. Extensive skin necrosis requires treatment in a special burn unit as well as debridement, skin grafts, and reconstructive procedures.^[8] Steroid use is controversial. However, Pavenski *et al.* reported three cases of levamisole/cocaine-induced skin necrosis and they were treated with plasmapheresis and immunosuppression with rapid stabilization and/or improvement of the lesions.^[9]

Conclusion

Cocaine-induced vasculitis should be one of the differential diagnoses in cocaine abusers who present with painful rash and skin necrosis. Early diagnosis is important since it is an emerging public health concern. There is high level of recurrence of symptoms in cocaine users after reexposure to cocaine.

Financial support and sponsorship

Nil.

Conflicts of interest

There are no conflicts of interest.

References

1. Larocque A, Hoffman RS. Levamisole in cocaine: Unexpected news from an old acquaintance. *Clin Toxicol (Phila)* 2012;50:231-41.
2. Lawrence LA, Jiron JL, Lin HS, Folbe AJ. Levamisole-adulterated cocaine induced skin necrosis of nose, ears, and extremities: Case report. *Allergy Rhinol (Providence)* 2014;5:132-6.
3. Centers for Disease Control and Prevention (CDC). Agranulocytosis associated with cocaine use - Four states, March 2008-November 2009. *MMWR Morb Mortal Wkly Rep* 2009;58:1381-5.
4. Nolan AL, Jen KY. Pathologic manifestations of levamisole-adulterated cocaine exposure. *Diagn Pathol* 2015;10:48.
5. Graf J. Rheumatic manifestations of cocaine use. *Curr Opin Rheumatol* 2013;25:50-5.
6. Gross RL, Brucker J, Bahce-Altuntas A, Abadi MA, Lipoff J, Kotlyar D, *et al.* A novel cutaneous vasculitis syndrome induced by levamisole-contaminated cocaine. *Clin Rheumatol* 2011;30:1385-92.
7. Trimarchi M, Gregorini G, Facchetti F, Morassi ML, Manfredini C, Maroldi R, *et al.* Cocaine-induced midline destructive lesions: Clinical, radiographic, histopathologic, and serologic features and their differentiation from Wegener granulomatosis. *Medicine (Baltimore)* 2001;80:391-404.
8. Souied O, Baydoun H, Ghandour Z, Mobarakai N. Levamisole-contaminated cocaine: An emergent cause of vasculitis and skin necrosis. *Case Rep Med* 2014;2014:434717.
9. Pavenski K, Vandenberghe H, Jakubovic H, Adam DN, Garvey B, Streutker CJ. Plasmapheresis and steroid treatment of levamisole-induced vasculopathy and associated skin necrosis in crack/cocaine users. *J Cutan Med Surg* 2013;17:123-8.