

Spontaneous evisceration of small bowel through the rectum in the background of rectal prolapse

SAGE Open Medical Case Reports
Volume 9: 1–4
© The Author(s) 2021
Article reuse guidelines:
sagepub.com/journals-permissions
DOI: 10.1177/2050313X211011809
journals.sagepub.com/home/sco



Oshan Basnayake^{1,2}, Umesh Jayarajah¹
and AM Thilak Wijerathne²

Abstract

Small bowel evisceration secondary to rectal prolapse is an uncommon complication with significant morbidity and mortality if left untreated. We report a rare case of the spontaneous evisceration of the small bowel through the rectum in the background of rectal prolapse. A 73-year-old female presented to the emergency treatment unit with sudden worsening of her rectal procidentia (rectal prolapse) and pain for 3 h precipitated by straining at defecation. She had a history of complete rectal prolapse for 4 years and three uncomplicated vaginal deliveries. On examination, she was found to have evisceration of the small bowel through the anus without any evidence of strangulation. Emergency laparotomy was performed and small bowel was reduced into the abdomen with ease. She was found to have a linear tear on the anterior wall of the rectum. Primary repair of the rectal defect was carried out and a proximal defunctioning ileostomy was created. Histology was unremarkable and the recovery was uneventful. Old age, history of previous vaginal deliveries, and long-standing rectal prolapse were probable risk factors in this patient. Delay in treating this condition may result in significant morbidity and even mortality. Therefore, timely intervention is necessary.

Keywords

Rectal prolapse, spontaneous evisceration, surgery

Date received: 8 January 2021; accepted: 30 March 2021

Introduction

Rectal procidentia or prolapse is a manifestation of pelvic floor disorder. Due to the weakness in the pelvic floor muscles and anal sphincter complex, there is a protrusion of the rectal mucosa or all layers of the rectal wall through the anus. It is common among elderly females with a past history of vaginal deliveries or pelvic surgeries which are associated with pelvic floor muscle weakness.¹ Depending on the degree of prolapse, it may cause local complications such as bleeding, ulceration, mucous discharge, and anal incontinence with a significant reduction in quality of life. Small bowel evisceration secondary to rectal prolapse is an uncommon complication with significant morbidity and mortality if left untreated. The evisceration of the bowel through the vaginal cuff, incisional hernia, and stoma has been described in the literature.^{2–4}

The evisceration of the bowel through the rectum was first described in 1827 by Brodie⁵ in a middle-aged female with a long-standing rectal prolapse after a violent straining

during vomiting. Since then, only several rare cases of spontaneous anal evisceration have been reported worldwide.⁶ We report a rare case of a spontaneous evisceration of the small bowel through the rectum in the background of rectal prolapse.

Case presentation

A 73-year-old otherwise healthy female presented to the emergency treatment unit with sudden worsening of rectal procidentia (rectal prolapse) and pain for 3 h after straining at defecation. She had a history of reducible complete rectal prolapse for 4 years, for which she did not seek treatment.

¹Faculty of Medicine, University of Colombo, Sri Lanka

²Department of Surgery, District General Hospital, Kegalle, Sri Lanka

Corresponding Author:

Oshan Basnayake, Faculty of Medicine, University of Colombo, 25, Kynsey Road, Colombo 08, Sri Lanka.

Email: oshan@anat.cmb.ac.lk



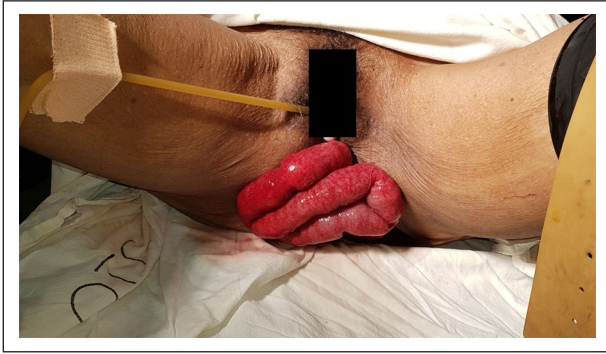

Figure 1. Eviscerated small intestinal loops through anus.

She had three uncomplicated vaginal deliveries in the past. On examination, she was found to have evisceration of the small bowel through the anus rather than a rectal prolapse, without any macroscopic evidence of strangulation (Figure 1). There was associated uterovaginal prolapse and perineal descent suggestive of pelvic floor dysfunction. She was hemodynamically stable with normal blood pressure and heart rate. Her biochemical investigations including serum lactate were all normal. Emergency laparotomy was performed and the small bowel was reduced into the abdomen with ease. She was found to have a linear tear, 6 cm from the anal verge on the anterior wall of the middle part of the rectum without any macroscopic evidence of ischemia or neoplasm (Figure 2). The reduced small bowel was normal in appearance with good peristalsis. Primary repair of the rectal defect was carried out after obtaining a biopsy from the rectal tear and a proximal defunctioning ileostomy was created. Histological examination of the rectal biopsy was unremarkable. She was managed in the intensive care unit for 2 days post-operatively and had an uneventful recovery. The patient was discharged on the fifth post-operative day.

Discussion

We report a rare case of a spontaneous evisceration of the small bowel through the rectum in the background of rectal prolapse. Old age, history of previous vaginal deliveries, and long-standing rectal prolapse were probable risk factors. The sudden rupture and evisceration were probably precipitated by a sudden rise in intra-abdominal pressure precipitated by straining at defecation. Reported cases in the literature described a wide variety of causes.⁷⁻¹⁴ The age groups ranged from infancy to the more common elderly population.^{9,10}

The cause for the evisceration may be secondary to increased abdominal pressure, impalement-type rectal injuries, and external suction injuries.¹¹ These causes can precipitate evisceration through the rectum in people with the healthy rectum or associated pathologies like rectal prolapse, rectal ulcers, carcinomas, diverticular disease, or colitis.¹⁵ In young patients, the described cases were mostly related to blunt abdominal trauma where a sudden increase in

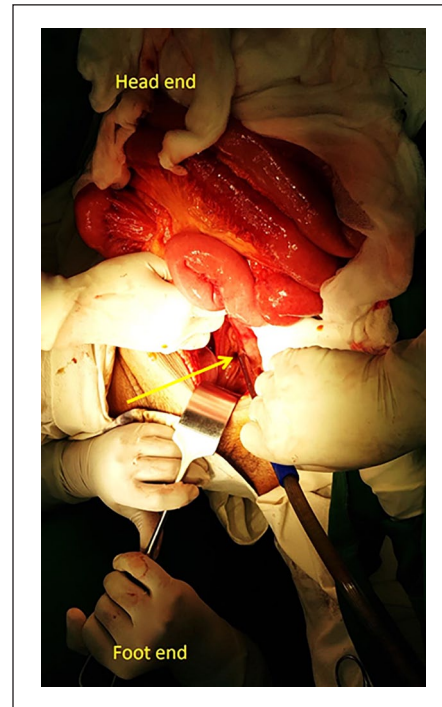


Figure 2. Intra-operative image showing anterior rectal wall tear (yellow arrow).

intra-abdominal pressure caused a tear of the rectum and evisceration of visceral contents.^{12,13} Another well-documented cause in the young was suction-type injuries with associated perineal trauma in swimming pools.¹⁴ In addition to the small intestine, an evisceration of intra-peritoneal contents such as sigmoid colon and omentum has also been described.^{15,16}

Similar to the reported patient, most elderly patients had a long-standing rectal prolapse. The first described case in the literature was also related to chronic rectal prolapse.⁵ Almost all patients had a tear in the anterior rectal wall. The probable reason may be due to the long-standing pressure-related ischemia of the region leading to the weakening of the anterior wall to a point where the precipitating factors facilitate the rupture of the rectal wall.¹⁷ The site is commonly related to the pouch of Douglas.¹⁸ In our patient, the event was precipitated by straining at defecation. The histological examination did not reveal any findings suggestive of carcinoma or inflammatory changes. Digitalization for the manual evacuation of feces or attempts of manual reduction of rectal prolapse has also caused perforations and evisceration of small intestines.¹⁹

Although there are no guidelines for the management of this condition, general principles in managing evisceration of bowel contents should be followed. A delay in the presentation may occur as the patient's perception of evisceration may be similar to the rectal prolapse unless there is intense pain which leads to early seeking of treatment. Initial delay may cause strangulation of prolapsed bowel

which may be detrimental.¹⁵ After initial stabilization and basic investigations, most patients were managed with laparotomy and reduction of eviscerated intestines via the abdominal route than the total perianal approach. However, a case of trans-anal reduction and repair with a favorable outcome has also been described.²⁰ Almost all other trans-anal reduction attempts at the emergency department have failed.¹⁹ Cases which were managed in a palliative manner due to unfavorable patient condition had 100% mortality.²¹ Surgical procedure for the correction of rectal prolapse was not attempted in any of the reported cases. The most probable reason for this might be the acute condition of the patient which hindered a lengthy surgical intervention.

Based on the macroscopic appearance of the rectal tear and probable associated pathology, surgical procedures such as primary repair with or without a proximal defunctioning stoma or Hartman's procedure with a proximal end stoma have been attempted.^{22–24} In the reported patient, a decision was made to proceed with proximal defunctioning ileostomy due to the concern of an underlying pathology.

Conclusion

We report a rare case of a spontaneous evisceration of the small bowel through the rectum in the background of rectal prolapse. Old age, history of previous vaginal deliveries, and long-standing rectal prolapse were probable risk factors. Small bowel evisceration secondary to rectal prolapse is an uncommon complication with significant morbidity and mortality if left untreated. Therefore, timely intervention is necessary.

Author contributions

O.B., U.J., and A.M.T.W. contributed to collection of information and writing of the manuscript. O.B. and U.J. contributed to writing and final approval of the manuscript. All authors read and approved the final version of the manuscript.

Availability of data and material

All data generated or analyzed during this study are included in this published article.

Declaration of conflicting interests

The author(s) declared no potential conflicts of interest with respect to the research, authorship, and/or publication of this article.

Ethical approval

Our institution does not require ethical approval for reporting individual cases or case series.

Funding

The author(s) received no financial support for the research, authorship, and/or publication of this article.

Informed consent

Written informed consent was obtained from the patient for patient information, and images to be published in this article.

ORCID iDs

Oshan Basnayake  <https://orcid.org/0000-0002-1239-7506>

Umesh Jayarajah  <https://orcid.org/0000-0002-0398-5197>

References

1. Madiba TE, Baig MK and Wexner SD. Surgical management of rectal prolapse. *Archiv Surg* 2005; 140(1): 63–73.
2. Matthews CA and Kenton K. Treatment of vaginal cuff evisceration. *Obstetric Gynecol* 2014; 124(4): 705–708.
3. Basnayake O, Jayarajah U, Jayasinghe J, et al. Spontaneous rupture of a parastomal hernia with evisceration of small bowel: a case report. *BMC Surg* 2019; 19(1): 43.
4. Thalahitiyage N, Ravindrakumar S, Nandasena J, et al. Spontaneous evisceration of incisional hernia with strangulation of small bowel: a life threatening complication. *Case Rep Surg* 2021; 2021: 6684360.
5. Brodie BC. Case of a singular variety of hernia. *Lond Med Phys J* 1827; 2(12): 529–530.
6. Budipramana VS and Putra DA. Rectal prolapse concomitant with uterovaginal prolapse protects the ileum from necrosis in transanal ileum evisceration through a traumatic tear on the sigmoid wall. *Case Rep Gastroenterol* 2020; 14(2): 420–425.
7. Al-Abkari HA. Spontaneous rupture of the rectum with evisceration of omentum through the anus: a case report and review of the literature. *Ann Saudi Med* 2000; 20(3-4): 246–247.
8. Berwin JT, Ho T and D'Souza R. Small bowel evisceration through the anus—report of a case and review of literature. *BMJ Case Rep* 2012; 2012: 5316.
9. Sengar M, Neogi S and Mohta A. Prolapse of the rectum associated with spontaneous rupture of the distal colon and evisceration of the small intestine through the anus in an infant. *J Pediatr Surg* 2008; 43(12): 2291–2292.
10. Komarowska MD, Matuszczak E, Debek W, et al. Traumatic evisceration after blunt trauma in a 20-month-old boy. *Ulus Travma Acil Cerrahi Derg* 2018; 24(2): 175–177.
11. Vincenzi R and Cruz RJ Jr. Transanal small bowel evisceration: an unusual presentation of rectal impalement. *Eur J Trauma Emerg Surg* 2008; 34(6): 606.
12. Corduk N, Koltuksuz U, Karabul M, et al. A rare presentation of crush injury: transanal small bowel evisceration. *Pediatr Surg Int* 2011; 27(9): 1021–1024.
13. Adisa A, Onyegbule C and Mbanaso A. Transanal evisceration of the small bowel from blunt abdominal trauma. *Niger J Surg Res* 2006; 8(3–4): 182–184.
14. Price NR, Soundappan SV, Sparnon AL, et al. Swimming pool filter-induced transrectal evisceration in children: Australian experience. *Med J Aust* 2010; 192(9): 534–536.
15. Li JZ, Kittmer T, Forbes S, et al. Case report: sigmoid strangulation from evisceration through a perforated rectal prolapse ulcer—an unusual complication of rectal prolapse. *Int J Surg Case Rep* 2015; 10: 238–240.
16. Kumar A, Jakhmola CK, Kukreja Y, et al. An adolescent with prolapsed omentum per rectum: spontaneous rectal perforation managed laparoscopically. *J Minimal Access Surg* 2017; 13(2): 151–153.

17. Furuya Y, Yasuhara H, Naka S, et al. Intestinal evisceration through the anus caused by fragile rectal wall. *Int J Colorectal Dis* 2008; 23(7): 721–722.
18. Jeong J, Park JS, Byun CG, et al. Rupture of the rectosigmoid colon with evisceration of the small bowel through the anus. *Yonsei Med J* 2000; 41(2): 289–292.
19. Trinidad A, Shakeel M and Jehan S. Transanal small bowel evisceration following digital reduction of a chronically prolapsing rectum. *J Coll Physicians Surg Pak* 2010; 20(11): 760–762.
20. Shoab SS, Saravanan B, Neminathan S, et al. Thiersch repair of a spontaneous rupture of rectal prolapse with evisceration of small bowel through anus—a case report. *Ann R Coll Surg Engl* 2007; 89(1): W6–W8.
21. Gheewala H, Iqbal M, McNaught C, et al. Evisceration of small bowel through rectum: a case report. *Maedica* 2019; 14(4): 428–430.
22. Akbulut S, Bozkurt MA, Kabuli HA, et al. Small bowel prolapse from anus: a typical presentation of rectal perforation. *Ulus Travma Acil Cerrahi Derg* 2019; 25(6): 628–630.
23. Kornaropoulos M, Makris MC, Yettimis E, et al. Transanal evisceration of the small bowel a rare complication of rectal prolapse. *Int J Surg Case Rep* 2016; 19: 38–40.
24. Ahmad A, Kumar S, Sonkar AA, et al. Evisceration of the small bowel through a perforated and prolapsed sigmoid colon: an unusual presentation of rectal prolapse. *BMJ Case Rep* 2016; 2016: 214811.