

Contents lists available at [ScienceDirect](https://www.sciencedirect.com)

International Journal of Surgery Case Reports

journal homepage: www.casereports.com

Arthroscopic Bankart revision using all suture anchor in recurrent anterior shoulder dislocation: A case report

Andri Maruli Tua Lubis*, Prima Rizky Oktari

Department of Orthopedic & Traumatology, Cipto Mangunkusumo Hospital and Faculty of Medicine, Universitas Indonesia, Jalan Diponegoro No. 71, Jakarta Pusat, Jakarta, 10430, Indonesia

ARTICLE INFO

Article history:

Received 9 December 2020
Received in revised form 5 January 2021
Accepted 8 January 2021
Available online 15 January 2021

Keywords:

Arthroscopic Bankart repair
All suture anchor
Recurrent dislocation of shoulder

ABSTRACT

INTRODUCTION: Arthroscopic Bankart revision after recurrent shoulder dislocation is still a matter of discussion. Several factors are contributing to this injury. Recently the development of all suture anchors has grown in popularity in arthroscopic stabilization. It was proven to preserve bone stock, smaller in size thus more anchors can be made.

PRESENTATION OF CASE: We presented a case of 27-year-old woman with recurrent anterior dislocation after seven years of arthroscopic Bankart repair. Seven years before, we performed Bankart repair using three 2.8 mm fiber-wire anchor (FASTak® (Arthrex, Karsfield Germany)). For the revision surgery we performed arthroscopic revision using four all suture anchor technique (Y-Knot® Flex All-Suture Anchor, 1.3 mm – One strand of #2 Hi-Fi® (Conmed, New York)).

DISCUSSION: From preoperative and intraoperative assessment, we found no anchor failure and no massive bony lesion. To preserve the bone stock we insert four all suture anchors between the old anchor. One year post-operative follow up showed that patient could gain normal range of movement. No early or late complications were observed.

CONCLUSION: Compared to the conventional metallic anchor, all suture anchor has the same biomechanical strength. Moreover due to its relatively small size, it can reserve bone stock and more anchors can be made thus adding more stability to the shoulder.

© 2021 The Authors. Published by Elsevier Ltd on behalf of IJS Publishing Group Ltd. This is an open access article under the CC BY-NC-ND license (<http://creativecommons.org/licenses/by-nc-nd/4.0/>).

1. Introduction

Recurrent shoulder dislocation after arthroscopic Bankart repair is still a matter of discussion. The recurrence rate varies between four to fourteen percent in the general population. Most of the recurrences occur in the first year after the arthroscopic repair and in traumatic injury [1].

A lot of study tried to divine the risk factors of recurrent dislocation. Shibata et al. mentioned several factors which contributes to recurrent dislocation. Re-injury of the first year, large Hill's-Sach lesion and less than four suture anchors are the factors of re-dislocation after arthroscopic Bankart's repair (ABR). Another study stated that the age of the patient, mechanism of injury and glenoid and humeral defects are the causes [2]. These risk factors contribute to the pathomechanism of the injury, thus no consensual treatment has been established in term of algorithm for these entity.

The choice of suture anchor has very important role. There are multiple design and composition of glenoid anchors. Tradition-

ally, surgical repair of shoulder instability was achieved by using solid suture anchor. As minimally invasive technique for upper extremity surgery become more widely embraced suture anchor fixation become more important. All suture anchor has been developed recently with several potential advantages over conventional suture anchor. The main proposed advantage is preservation of host bone through the use of smaller pilot hole hence more number of anchors can be placed in the glenoid [3]. Multiple design and materials used to form the anchor. Polyether ether ketone, ultra-high molecular weight poly ethylene (UHMWPE) which was proven to have higher resistance to break compares to metal based suture [4]. We present a re-dislocation of right shoulder with history of arthroscopic Bankart repair seven years before, on which previously we used the 2.8 mm fiber-wire anchor (FASTak® (Arthrex, Karsfield Germany)) to repair the Bankart lesion, and revising it using the 1.3 mm all suture anchor (Y-Knot® Flex All-Suture Anchor, 1.3 mm – One strand of #2 Hi-Fi® (Conmed, Newyork)).

2. Presentation of case

A 27-year-old woman experience right shoulder dislocation after trying to hold on a ladder grip several weeks before the outpatient clinic visit. The patient was a cardiologist resident, she did

* Corresponding author.
E-mail address: andrilubisresearch@gmail.com (A.M.T. Lubis).

not practice professional sports. Seven years before, she underwent arthroscopic Bankart repair with 3 suture anchor using 2.8 mm suture anchor FASTak® (Arthrex, Karsfield Germany) due to a significant trauma that caused her shoulder to dislocate.

Upon physical examination of the right shoulder we found positive apprehension test, positive relocation test and positive anterior drawer test. Meanwhile on computed tomography scan we found small and non-engaging Hill's-Sach lesion. On magnetic resonance imaging, we found that there was detachment in anterior inferior glenoid labrum yet intact parts on rotator cuff tendon and posteroinferior labrum area.

The patient was operated under general anesthesia in a beach chair position. Three standard portals were used. A standard posterior portal was created as a viewing portal and we made additional anterosuperior portal (upper rotator cuff interval), anteroinferior portal (above upper border of subscapularis tendon). First, we performed diagnostic arthroscopic in the anteroinferior glenoid rim. We mobilized the capsulolabral complex with periosteal elevator. The glenoid neck is then debrided with rasp. *Footprint of the labrum attachment and the glenoid is prepared until the denuded surface bleeds and facilitate bone to capsule healing.* The capsulolabral structure was ruptured from 3 clock to 5 clock direction. No suture failure nor additional lesions was found, such as rotator cuff tears or superior Labral Antero-Posterior lesion (SLAP lesion). We use 70° scope to better evaluate the anteroinferior glenoid rim and its capsulolabral attachment (Fig. 1). We mobilized the capsulolabral complex with periosteal elevator. The glenoid neck is then debrided with rasp. *Footprint of the capsule attachment to the glenoid is prepared until the denuded surface bleeds and facilitate bone to capsule healing.* The most inferior anchor was placed in 05.30 clock position. The drill hole and anchor placed 2 mm on the glenoid surface to achieve appropriate restoration of the labrum. Drill guide was inserted through anteroinferior portal and the first suture anchor was inserted through the drill guide. The anchor was started by hand to make sure it is seated properly before it was impacted to the final position. The anchor was then pulled back to expand and make a seat inside the bone tunnel. The repair suture was then retrieved. A handheld grasper was inserted to shift and stabilize capsule meanwhile a shuttling device penetrated lateral to glenoid and inferior to anchor. Capsulolabral complex was then reduced to the glenoid with the help of the grasper. The repair suture was placed into wire loop, shuttled into soft tissue, and exits out through anteroinferior portal. A 25° angulated shuttling device is then inserted through interoinferior cannula and capsule is penetrated lateral to glenoid and inferior to anchor. Grasper was used to stabilize the tissue while shuttling device was passed through labrum, intra-articular again between osteochondral junction of the glenoid medially and labrum ring laterally. The capsulolabral complex can be reduced to glenoid rim with grasper through anteroinferior portal. The repair suture is put into wire loop shuttled into soft tissue and exist through anteroinferior portal. For the self-locking mechanism, the repair suture is passed back to anteroinferior portal. The repair suture passed through the end of shuttle suture and the free end of shuttle suture is pulled until the repair suture pass back into self-locking mechanism of the anchor. The self-locking mechanism is buried through bone tunnel. After that, using mini-suture cutter, the free suture end is cut, making it a knotless construct. We were using Y-Knot® Flex All-Suture Anchor, 1.3 mm – One strand of #2 Hi-Fi®. The process was repeated three times more from inferior to anterior direction 5.30, 4.30, 3.30 and 2.30 clock position. Four implants were used.

Following the surgery, the patient was kept in a shoulder sling for three weeks. Patient could do gentle passive motion, limited external rotation and pendulum exercise as tolerated after three weeks. In the sixth weeks after the surgery, sling was removed, and full passive range of motion exercise was permitted. At 6–7 weeks

patient was encouraged to do closed chain exercise and isometric exercise. Rotator cuff exercise begun at twelve weeks after surgery and sport participation began at 6 months after surgery.

After two years follow up, there is no complications. Patient also did not complain any pain or instability when doing daily activity. This work has been reported in line with SCARE criteria [5].

3. Discussion

Recent studies showed that recurrence rate for shoulder dislocation after arthroscopic Bankart repair varies from 4 to 19% with mean follow up ranging from 5.5–13.3 years [1,2]. Half of the patient with recurrent dislocation had traumatic injury priory [6]. In our case, the patient had recurrent dislocation after seven years of the first arthroscopic Bankart repair. This is not in accordance with Shibata et al. who proposed that re-injury that occur within one year after the first ABR was one of re-dislocation factor in post arthroscopic Bankart repair. Moreover, Shibata explained that re-dislocation rates tend to decrease over time [1]. According to Aboalata et al., gender and hand dominance are not significantly related to the risk of re-dislocation. On the other hand, she was 20 years old at the first arthroscopic Bankart repair. Age less than 20 was significantly related to the risk of recurrent dislocation. Besides, the re-dislocation rate drops significantly with advancement of age [2].

Several anatomical conditions that greatly contribute to the re-dislocation after ABR were large Hill's-Sach lesion (lesion surface area more 250 mm³) and large glenoid bone defect (more than 20%) but in this case the bony lesion is less than 20%.

Patient was going down on a ladder when she slipped off and her right arm was trying to hold her body from falling down. Her right arm was abducted and externally rotated while handholding the ladder grip. This is in accordance with Sheehan et al. who proposed that anterior dislocation most commonly involving indirect mechanism and most often due to sudden load to the arm with varying degree of extension, abduction and external rotation [7]. The contact of humeral head and glenoid is about 30%. Therefore, the joint has limited osseous constrain and the primary stability is due to the soft tissue components. This fact allows a very large range of motion. On the other hand, it also predisposes to subluxation and dislocation as well. The labrum especially the anterior part had key role in anteroposterior stability as it deepens the glenoid cavity up to 50%. This explains why recurrent dislocation occurs in a detached labrum [8].

Arthroscopic Bankart repair has advanced to provide safer and stronger fixation for anterior shoulder fixation. Back in the past, surgical repair of shoulder instability is achieved using solid suture anchor. The all suture anchor has grown in popularity recently due to the advantageous. Y knot all suture anchor is a suture-based anchor. This anchor typically have a 1–3 mm wide sleeve of suture material (braided polyester) through which the suture is passed. This design influence the shape of the anchor when it is tightened [4]. Herein, we will explain the advantageous of using all suture anchor technique. First is the small size of the anchors which enable multiple point of fixation without bone removal, second is the anchor material which is small and strong, and last is the ability to tension the repair under direct visualization using grasper and knotless construct.

Healing of labral to bone requires a device that allows the teared labrum part to strongly fixed to the bone during healing phase (approximately 12 weeks). If the fixation is not secured and does not maintain the strength until the labral is completely healed to the bone, failure might occur [9]. Previously, we repaired the Bankart lesion using 2.8 mm fiber-wire anchor (FASTak® (Arthrex, Karsfield Germany)). On our arthroscopic Bankart revision, intraoperatively

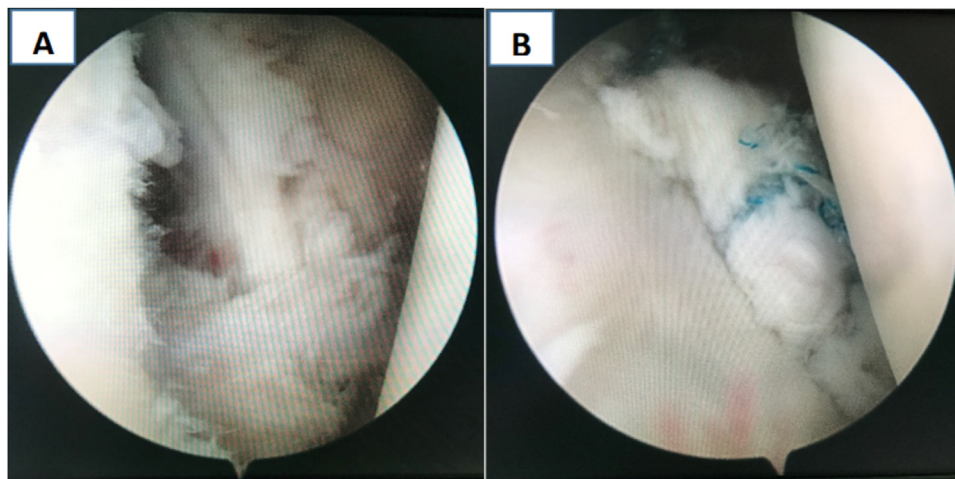


Fig. 1. A. Teared labral before we repair; B. The final construct of for all anchor suture. The anchors were put on 5.30, 4.30, 3.30 and 2.30 clock position.

we found no suture failure and the knot was still intact. We decided not to remove the old anchor because if we do so, there would be bony defect from the detached implant that would create inadequate surface area for the new suture. The anchor portion of all suture anchor consists of a sleeve like or tape made with suture material through which the UHMWPE is woven. When all suture anchor is inserted to the bone and the main suture is pulled, the sleeve or tape is chinged up to compress the overlying cortical bone. It creates a ball-like structure which serve as an anchor [10]. Bone preservation is maximized because only 1.3 mm diameter bone tunnel is required to be drilled. This is one of the reasons why we prefer all suture anchor in an active young patient. Not only is the anchor good for the young with good quality of bone but also suitable for older patients as well [11].

The size of all anchor suture small that enable us to make four anchors in 2 mm distance along the labral tear (from 3 o'clock to 5 o'clock). This is in accordance with the study held by Kramer that 2 mm is the optimal size that contributes to the strength of the anchors grip [12]. Inferior glenoid rim lesion can be difficult to access. Sometimes it requires another trans tendon anteroinferior portal through the lower subscapularis muscle. All suture anchor, which is lacking of rigid component, enable us to drill inferior glenoid lesion with cruded guide. The glenoid rim at 5.30 position can be accessed by standard anteroinferior portal by curved drill and guide wire.

Bone preservation is maximized because only 1.3 mm diameter bone tunnel is required to be drilled. This is one of the reasons why we prefer all suture anchor in an active young patient.

4. Conclusion

Compared to the conventional metallic anchor, all suture anchor has the same biomechanical strength. We did revision using all suture anchor technique and after two years of follow up the patient was satisfied, no complications and good range of motions. The all suture anchor technique offers benefit of bone preservation, strong fixation, time saving and knotless repair construct.

Declaration of Competing Interest

The authors declare no conflicts of interest.

Funding

The authors report no external source of funding during the writing of this article.

Ethical approval

Ethical approval was not required in the treatment of the patient in this report.

Consent

Written informed consent was obtained from the patient for publication of this case report and accompanying images. A copy of the written consent is available for review by the Editor-in-Chief of this journal on request.

Author contribution

Andri Maruli Tua Lubis contributes in the study concept or design, data collection, analysis and interpretation, oversight and leadership responsibility for the research activity planning and execution, including mentorship external to the core team.

Prima Rizky Oktari contributes to the study concept or design, data collection and writing the paper.

Registration of research studies

Not Applicable.

Guarantor

Andri Maruli Tua Lubis is the sole guarantor of this submitted article.

Provenance and peer review

Not commissioned, externally peer-reviewed.

Transparency document

The [Transparency document](#) associated with this article can be found in the online version.

CRediT authorship contribution statement

Andri Maruli Tua Lubis: Conceptualization, Methodology, Investigation, Resources, Writing - review & editing, Supervision, Resources. **Prima Rizky Oktari:** Conceptualization, Validation, Writing - original draft, Project administration.

References

- [1] H. Shibata, M. Gotoh, Y. Mitsui, Y. Kai, H. Nakamura, T. Kanazawa, T. Okawa, F. Higuchi, M. Shirahama, N. Shiba, Risk Factors for Shoulder Re-dislocation After Arthroscopic Bankart Repair, 2014, pp. 1–7, <http://dx.doi.org/10.1186/s13018-014-0053-z>.
- [2] M. Aboalata, J.E. Plath, G. Seppel, J. Juretzko, S. Vogt, A.B. Imhoff, P < P results of arthroscopic Bankart repair for anterior-inferior shoulder, *Am. J. Sports Med.* (2016), <http://dx.doi.org/10.1177/0363546516675145>.
- [3] T. Dwyer, T.L. Willett, A.P. Dold, D.B. Whelan, J.S. Theodoropoulos, Maximum Load to Failure and Tensile Displacement of an All-suture Glenoid Anchor Compared With a Screw-in Glenoid Anchor, 2013, <http://dx.doi.org/10.1007/s00167-013-2760-0>.
- [4] F.A. Barber, M.A. Herbert, Cyclic loading biomechanical analysis of the pullout strengths of rotator cuff and glenoid anchors: 2013 update, *Arthroscopy* 29 (2013) 832–844, <http://dx.doi.org/10.1016/j.arthro.2013.01.028>.
- [5] R.A. Agha, T. Franchi, C. Sohrabi, G. Mathew, A. Kerwan, A. Thoma, A.J. Beamish, A. Nouredin, A. Rao, B. Vasudevan, B. Challacombe, B. Perakath, B. Kirshtein, B. Ekser, C.S. Pramesh, D.M. Laskin, D. Machado-Aranda, D. Miguel, D. Pagano, F.H. Millham, G. Roy, H. Kadioglu, I.J. Nixon, I. Mukhejee, J.A. McCaul, J. Chi-Yong Ngu, J. Albrecht, J.G. Rivas, K. Raveendran, L. Derbyshire, M.H. Ather, M.A. Thorat, M. Valmasoni, M. Bashashati, M. Chalkoo, N.Z. Teo, N. Raison, O.J. Muensterer, P.J. Bradley, P. Goel, P.S. Pai, R.Y. Afifi, R.D. Rosin, R. Coppola, R. Klappenbach, R. Wynn, R.L. De Wilde, S. Surani, S. Giordano, S. Massarut, S.G. Raja, S. Basu, S.A. Enam, T.G. Manning, T. Cross, V.K. Karanth, V. Kasivisvanathan, Z. Mei, The SCARE 2020 guideline: updating consensus surgical Case REport (SCARE) guidelines, *Int. J. Surg.* 84 (2020) 226–230, <http://dx.doi.org/10.1016/j.ijvs.2020.10.034>.
- [6] P. Boileau, The Instability Severity Index Score Arthroscopic or Open Shoulder Stabilisation, 2021, pp. 1470–1477, <http://dx.doi.org/10.1302/0301-620X.89B11.18962> (n.d.).
- [7] A.F.M. Analysis, S.E. Sheehan, G. Gaviola, R. Gordon, S.E. Smith, S. Se, G. Gaviola, R. Gordon, Traumatic Shoulder Injuries: and Instability, 2013, pp. 378–393, <http://dx.doi.org/10.2214/AJR.12.9986>.
- [8] G. Di Giacomo, L. Piscitelli, M. Pugliese, Shoulder & elbow the role of bone in glenohumeral stability, *Efort Open Rev.* 3 (2018), <http://dx.doi.org/10.1302/2058-5241.3.180028>.
- [9] F.A. Barber, M.A. Herbert, All-suture anchors: biomechanical analysis of pullout strength, displacement, and failure mode, *Arthroscopy* (2016) 1–9, <http://dx.doi.org/10.1016/j.arthro.2016.09.031>.
- [10] M. Ozbaydar, B. Elhassan, J.J.P. Warner, The use of anchors in shoulder surgery: a shift from metallic to bioabsorbable anchors, *Arthroscopy* 23 (2007) 1124–1126, <http://dx.doi.org/10.1016/j.arthro.2007.05.011>.
- [11] B. Goldenberg, P.J. Millett, M. Sc, Arthroscopic knotless, tensionable all-suture anchor bankart repair, *Arthrosc. Tech.* 8 (2019) e647–e653, <http://dx.doi.org/10.1016/j.eats.2019.02.010>.
- [12] J.D. Kramer, S. Robinson, E. Hohn, C. Purviance, E.M. Wolf, Fixation methods and implants in shoulder stabilization: a historical perspective, *J. Orthop.* 15 (2018) 630–635, <http://dx.doi.org/10.1016/j.jor.2018.05.029>.

Open Access

This article is published Open Access at [sciencedirect.com](https://www.sciencedirect.com). It is distributed under the [IJSCR Supplemental terms and conditions](#), which permits unrestricted non commercial use, distribution, and reproduction in any medium, provided the original authors and source are credited.