

# Efficacy of Reciproc<sup>®</sup> and Profile<sup>®</sup> Instruments in the Removal of Gutta-Percha from Straight and Curved Root Canals *ex Vivo*

Karem Marfisi<sup>1</sup>, Montserrat Mercadé<sup>1</sup>, Gianluca Plotino<sup>2</sup>, Tatiana Clavel<sup>1</sup>, Fernando Duran-Sindreu<sup>1</sup>, Miguel Roig<sup>1</sup>

<sup>1</sup>Department of Restorative Dentistry and Endodontics, Universitat Internacional de Catalunya, Sant Cugat del Vallès, Barcelona, Spain.

<sup>2</sup>Department of Endodontics, “Sapienza” - University of Rome, Rome, Italy.

## Corresponding Author:

Montserrat Mercadé

Universitat Internacional de Catalunya, Dentistry Faculty  
C/Josep Trueta s/n, 08195 Sant Cugat del Vallès, Barcelona  
Spain

Phone: + 34 504 2000

Fax: +34 504 2031

E-mail: [mmercade@uic.es](mailto:mmercade@uic.es)

## ABSTRACT

**Objectives:** To compare the efficacy of Reciproc<sup>®</sup> (VDW GmbH) and ProFile<sup>®</sup> (Dentsply Maillefer) instruments at removing gutta-percha from straight and curved root canals *ex vivo* filled using the cold lateral condensation and GuttaMaster<sup>®</sup> (VDW GmbH) techniques.

**Material and Methods:** Forty mesial roots of mandibular molars with two curved canals and 80 single-rooted teeth with straight root canals, a total of 160 root canals, were randomly assigned to eight groups (canals per group = 20) according to filling technique, retreatment instrument and root canal curvature as follows: Group I, cold lateral condensation/ProFile<sup>®</sup>/straight; Group II, cold lateral condensation/ProFile<sup>®</sup>/curved; Group III, cold lateral condensation/Reciproc<sup>®</sup>/straight; Group IV, cold lateral condensation/Reciproc<sup>®</sup>/curved; Group V, GuttaMaster<sup>®</sup>/ProFile<sup>®</sup>/straight; Group VI, GuttaMaster<sup>®</sup>/ProFile<sup>®</sup>/curved; Group VII, GuttaMaster<sup>®</sup>/Reciproc<sup>®</sup>/straight; and Group VIII, GuttaMaster<sup>®</sup>/Reciproc<sup>®</sup>/curved. The following data were recorded: procedural errors, retreatment duration and canal wall cleanliness. Means and standard deviations were calculated and analysed using the Kruskal-Wallis test, one-way analysis of variance and Tukey's test ( $P < 0.05$ ).

**Results:** Reciproc<sup>®</sup> instruments were significantly faster than ProFile<sup>®</sup> instruments at removing GuttaMaster<sup>®</sup> from both straight ( $P = 0.0001$ ) and curved ( $P = 0.0003$ ) root canals. Reciproc<sup>®</sup> were statistically more effective than ProFile<sup>®</sup> instruments in removing GuttaMaster<sup>®</sup> from straight root canals ( $P = 0.021$ ). Regardless of filling technique or retreatment instrument, gutta-percha was removed more rapidly from curved than from straight root canals ( $P = 0.0001$ ).

**Conclusions:** Neither system completely removed filling material from the root canals. Compared with ProFile<sup>®</sup> instruments, Reciproc<sup>®</sup> instruments removed GuttaMaster<sup>®</sup> filling material from straight and curved root canals more rapidly.

**Keywords:** endodontics; retreatment; root canal.

Accepted for publication: 10 September 2015

### To cite this article:

Marfisi K, Mercadé M, Plotino G, Clavel T, Duran-Sindreu F, Roig M.

Efficacy of Reciproc<sup>®</sup> and Profile<sup>®</sup> Instruments in the Removal of Gutta-Percha from Straight and Curved Root Canals *ex Vivo*. J Oral Maxillofac Res 2015;6(3):e1.

URL: <http://www.ejomr.org/JOMR/archives/2015/3/e1/v6n3e1.pdf>

doi: [10.5037/jomr.2015.6301](https://doi.org/10.5037/jomr.2015.6301)

## INTRODUCTION

Post-treatment dental disease may emerge or endure because of the persistence of bacteria in the root canal system as a result of insufficient cleaning, untreated canals, inadequate filling or coronal leakage [1]. Non-surgical root canal retreatment is often the first choice for the elimination or reduction of microbial infection. Different techniques have been proposed for the removal of filling materials from the root canal system, including the use of hand files [2,3], Gates Glidden burs [3], nickel-titanium (NiTi) rotary and reciprocating instruments [2-4], heat pluggers [5], ultrasonic instruments [6] and lasers [7], with or without the use of adjunctive solvents [8]. Several studies evaluated the efficacy of different systems, such as the ProFile® (Dentsply-Maillefer; Ballaigues, Switzerland) [9,10], ProTaper® (Dentsply-Maillefer) [11], GT® (Dentsply-Maillefer) [12], Mtwo® (VDW GmbH) and ProTaper® Universal retreatment files (Dentsply-Maillefer) [4,13,14], in the removal of different filling materials and root canal re-instrumentation.

The effectiveness of gutta-percha removal also depends on anatomical factors, such as the degree of root canal curvature [8], the initial cross-sectional shape of the root canal (oval or circular) [15] and any previous shaping and filling procedures [15,16]. Several techniques have been advocated to achieve complete filling of the root canal system, including lateral condensation, warm vertical compaction the continuous wave of condensation technique and carrier-based systems [17]. Many studies were conducted on straight root canals [13,18,19]; however, studies on the removal of root fillings from curved root canals are rare [10,11,20,21]. To date, no studies have investigated the removal of filling materials from both straight and curved root canals that have been instrumented, filled and retreated with the same techniques. Therefore, this study aimed to compare the efficacy of Reciproc® (VDW GmbH, Munich, Germany) and ProFile® instruments in removing gutta-percha from straight and curved root canals filled by cold lateral condensation or GuttaMaster® (VDW GmbH).

## MATERIAL AND METHODS

### Specimen selection

Forty mesial roots of mandibular molars with two curved canals and 80 single-rooted teeth with straight root canals (160 root canals) were selected for

this study from a pool of extracted teeth, and they were kept in saline until its use. We captured preoperative mesio-distal and bucco-lingual radiographs of each tooth to select samples that met the following inclusion criteria: completely formed apices, absence of calcifications or internal root resorption, absence of previous root filling or prosthetic restoration and, for mandibular molars, two completely separate root canals in the mesial root with a similar radius and angle of curvature [22]. The distal root of mandibular molars was removed and the length of all samples was standardized to 16 mm.

### Root canal preparation and filling

Canal patency and working length were established by inserting a stainless steel K file 15 (VDW GmbH) in the canal until its tip could be seen through the apical foramen under operating microscope (Vasconcellos, Sao Paulo, Brazil). The tooth length was checked and 1 mm was subtracted to determine the working length. All root canals were instrumented to a size 30, 0.05 taper using Mtwo® NiTi rotary instruments (VDW GmbH) operated by an endodontic motor (VDW Silver®, VDW GmbH) as previously reported [23]. During instrumentation, the root canals were irrigated between instruments with 2 mL of 5.25% sodium hypochlorite (Dentaflux, Madrid, Spain). After root canal instrumentation, the smear layer was removed with 2 mL of 17% EDTA (Dentaflux) followed by 2 mL of 5.25% sodium hypochlorite. The residual irrigants were removed with a final rinse of 5 mL of sterile distilled water. Finally, the root canals were dried with size 30, 0.05 taper paper points (VDW GmbH), and the teeth were randomly assigned to different filling techniques. Twenty mesiobuccal and 20 mesiolingual curved root canals of mandibular molars and 40 straight root canals of single-rooted teeth were filled by the cold lateral condensation technique with a 30, 0.04 gutta-percha master cone and accessory cones, and 2Seal easymiX® Root Canal Sealer (VDW GmbH), whereas the other 20 mesiobuccal and 20 mesiolingual curved root canals of mandibular molars and 40 straight root canals of single-rooted teeth were filled using a size 30 GuttaMaster® carrier-based technique (VDW GmbH). A very light coating of 2Seal easymiX® Root Canal Sealer was applied to the canal walls using a size 30, 0.05 taper paper point to the working length and any excess sealer was removed using another paper point. After heating samples in the GuttaMaster® oven (VDW GmbH) for the prescribed time, a size 30 GuttaMaster® obturator (VDW GmbH) was inserted into the canals to the working length according to the manufacturer's

instructions. After the gutta-percha had cooled, the obturators were cut at the canal orifice using a bur in a high-speed handpiece and the quality and apical extent of the root fillings were confirmed radiographically in both the mesio-distal and bucco-lingual planes. The access cavity of all specimens was sealed with Cavit™ (3M ESPE Seefeld, Seefeld, Germany) and the teeth were stored at 37 °C at 100% humidity for 8 weeks to ensure complete setting of the sealer.

The 160 specimens were randomly assigned to eight different groups of 20 root canals according to filling technique, retreatment instrument, root canal curvature and the amount of filling material in straight canals. Curved canals were distributed consecutively to the different groups to avoid differences in canal curvature between groups. The straight root canals were distributed evenly between groups by measuring the amount of filling material with mesio-distal radiographs.

### Removal of filling material

In Groups I, II, V and VI, the filling material was removed using ProFile® instruments sizes 40, 0.06 taper, 35, 0.06, 30, 0.06, 25, 0.06 and 20, 0.06 in a crown-down sequence at a speed of 300rpm. The canals were then re-instrumented to the working length with a size 35, 0.04 taper ProFile® instrument. In Groups III, IV, VII and VIII, filling material was removed using a Reciproc® R25 instrument in an up-and-down pecking motion according to the manufacturer's instructions and as previously described [23]. The canals were then re-instrumented to the working length with a size 35, 0.04 taper Mtwo® instrument (VDW GmbH). Retreatment was judged complete when the working length was reached and no more gutta-percha could be seen on the instrument used. After instrumentation, the root canals were irrigated with 2 mL of 5.25% sodium hypochlorite. All instruments were used in two root canals only and were then discarded.

The numbers of fractured or deformed instruments and procedural errors, such as perforations, blockages or ledges, were recorded. Furthermore, the time in seconds required for each retreatment procedure, not including the time taken to change instruments and irrigate the root canals, was measured with a stopwatch and recorded for each canal.

### Analysis of residual filling material

For each specimen, digital radiographs were taken in the mesio-distal projection (6100 Digital Radiography System; Kodak, Rochester, NY, USA) according

to the technique described by Gergi and Sabbagh [11] and the images were analysed using AutoCAD 2009 (Mechanical Desktop Power Pack; Microsoft Corporation, Redmond, WA, USA). The root canals were divided into thirds (coronal, middle and apical) and the area of the entire root canal and of each third was calculated and expressed in mm<sup>2</sup>. Two observers, blinded to the techniques used, assessed the area of residual filling material but no attempt was made to distinguish between gutta-percha and sealer. The ratio between the area of each root canal covered by residual filling material and the total root canal area was calculated for the entire root canal length and for each third, and expressed as a percentage.

### Statistical analysis

Pearson's correlation coefficient was calculated to assess the similarity between the measurements made by the two observers. The normality of the distribution of the groups was analysed using the Kolmogorov-Smirnov test ( $P < 0.05$ ) and the homogeneity of variance was tested with Bartlett's test ( $P < 0.05$ ).

Parametric data were expressed as mean and standard deviation (M [SD]) for each parameter in all groups. The Kruskal-Wallis non-parametric test was used to analyse the remnants of filling materials, followed by the least significant difference (LSD) post-hoc test. A P-value of  $< 0.05$  was considered statistically significant. One-way analysis of variance and Tukey's test were used to evaluate the parametric data on the time required for filling removal. A P-value of  $< 0.05$  was considered statistically significant.

## RESULTS

The mean radii of curvature of the root canals in Groups II, IV, VI and VIII were 7.4°, 7.16°, 7° and 7.4°, respectively. The mean angles of curvature of the root canals in Groups II, IV, VI and VIII were 30.6°, 35.2°, 34.42° and 30.42°. No statistically significant differences were found among the four groups for either the radii ( $P = 0.97$ ) or the angle ( $P = 0.34$ ) of curvature.

The value of Pearson's correlation coefficient for the similarity of the measurements made by the two observers was very high ( $P = 0.98$ ).

### Procedural errors

One Reciproc® R25 instrument and one size 20, 0.06 ProFile® instrument fractured during GuttaMaster®

retreatment procedures in curved root canals. No perforations, blockages or ledges were recorded in any group.

**Time required for the removal of the obturation material**

The mean operating time required to remove the filling material in each group is presented in Table 1. For teeth filled using the lateral condensation technique, there were no significant differences between the instruments used to remove the laterally condensed gutta-percha in straight and curved root canals ( $P > 0.05$ ). In contrast, Reciproc® instruments were significantly faster than ProFile® instruments at removing GuttaMaster® from both straight ( $P = 0.0001$ ) and curved ( $P = 0.0003$ ) root canals. ProFile® instruments removed the filling material significantly faster from root canals filled using the lateral condensation technique than from those filled using GuttaMaster® ( $P = 0.0003$ ); no statistically significant differences were found in the Reciproc® groups ( $P > 0.05$ ).

Both systems removed the filling material significantly faster from curved canals than from straight canals ( $P = 0.001$ ), regardless of the filling technique used.

**Effectiveness of the retreatment technique**

The mean area of residual filling material in the different groups is shown in Table 2. Figure 1 shows one example of pre and post treatment X-rays from each group. Reciproc® instruments were significantly more efficient than ProFile® instruments in the removal of GuttaMaster® from straight root canals ( $P = 0.0006$ ). ProFile® instruments removed more filling material from curved root canals filled by lateral condensation than from straight canals filled using the same technique ( $P = 0.001$ ). Both systems left more filling material inside straight canals than curved canals, in both the lateral condensation ( $P = 0.001$ ) and GuttaMaster® ( $P = 0.012$ ) groups. Reciproc® instruments performed better than ProFile® instruments in removing filling material from the apical third of straight root canals filled with GuttaMaster® ( $P = 0.0022$ ).

**Table 1.** Time (seconds) required for the removal of the filling material in each group

Group	Filling technique	Retreatment system	Straight/Curved canal	Mean time (SD)
I	LC	ProFile®	Straight	148.1 (64.3) <sup>a</sup>
II	LC	ProFile®	Curved	98.59 (39.71) <sup>bf</sup>
III	LC	Reciproc®	Straight	147.8 (67.9) <sup>a</sup>
IV	LC	Reciproc®	Curved	84.27 (22.62) <sup>bg</sup>
V	GM	ProFile®	Straight	275.1 (110.2) <sup>c</sup>
VI	GM	ProFile®	Curved	218.82 (129.32) <sup>d</sup>
VII	GM	Reciproc®	Straight	145.4 (88.5) <sup>af</sup>
VIII	GM	Reciproc®	Curved	70.56 (32.96) <sup>eg</sup>

SD = Standard deviation, LC = Lateral condensation, GM = GuttaMaster®.

Different lower case letters indicate statistically significant differences in the vertical columns. One-way analysis of variance and Tukey’s test were used to evaluate the parametric data on the time required for filling removal.  $P < 0.05$  was considered statistically significant.

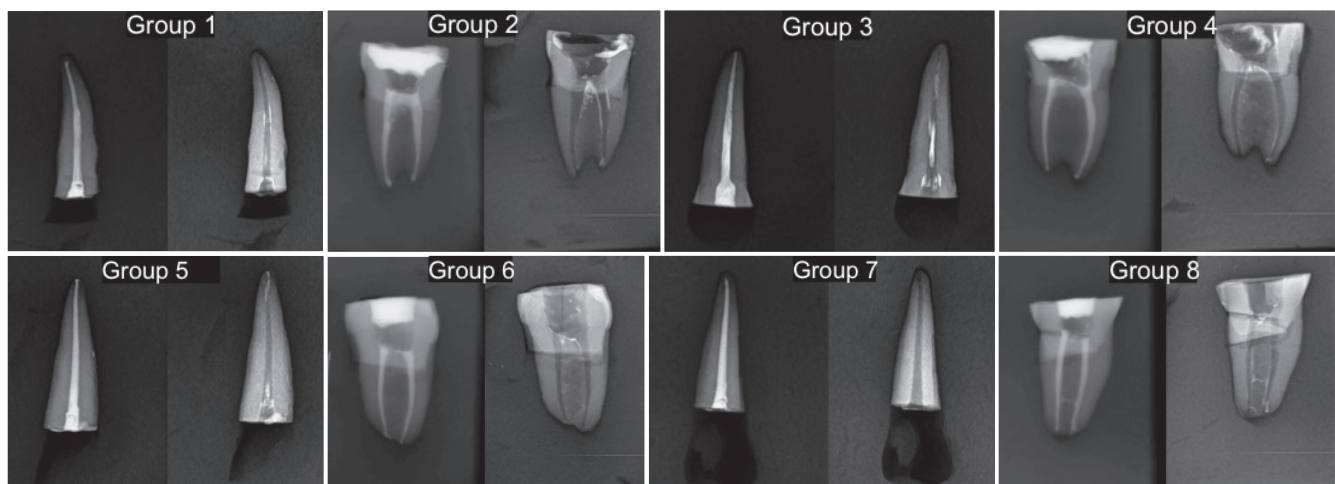
**Table 2.** Mean scores of percentage (standard deviation) for canal wall remnants for the different groups

	LC/Profile		LC/Reciproc®		GM/ProFile®		GM/Reciproc®	
	Straight canal	Curved canal	Straight canal	Curved canal	Straight canal	Curved canal	Straight canal	Curved canal
C	32.78 (14.88) <sup>Aa</sup>	5.33 (6.81) <sup>Ba</sup>	22.43 (14.45) <sup>CDa</sup>	17.85 (13.66) <sup>CEa</sup>	27.31 (17.18) <sup>ADa</sup>	11.92 (13.52) <sup>BEa</sup>	25.02 (19.81) <sup>ACa</sup>	11.59 (12.42) <sup>BEa</sup>
M	17.81 (16.63) <sup>Ab</sup>	9.06 (10.95) <sup>Aa</sup>	20.61 (23.33) <sup>Aa</sup>	20.80 (15.38) <sup>Aa</sup>	21.49 (25.9) <sup>Aa</sup>	22.15 (32.65) <sup>Aa</sup>	15.94 (22.83) <sup>Aa</sup>	16.11 (15.8) <sup>Aa</sup>
A	16.6 (21.15) <sup>Ab</sup>	21.35 (19.12) <sup>Ab</sup>	15.70 (14.75) <sup>Aa</sup>	18.58 (14.96) <sup>Aa</sup>	36.09 (30.36) <sup>Ba</sup>	12.92 (16.65) <sup>Aa</sup>	14.58 (15.78) <sup>Aa</sup>	11.50 (11.09) <sup>Aa</sup>
Total	22.4 (18.96) <sup>AC</sup>	11.91 (6.26) <sup>BD</sup>	17.34 (17.91) <sup>AD</sup>	19.07 (0.9) <sup>AE</sup>	28.3 (25.39) <sup>C</sup>	15.66 (10.26) <sup>ADE</sup>	18.52 (19.91) <sup>AF</sup>	13.07 (2.43) <sup>BDEF</sup>

LC = Lateral Condensation; GM = GuttaMaster®; C = Coronal third; M = Median third; A = apical third.

Different letters indicate statistically significant differences within the vertical columns (upper case) or within horizontal rows (lower case). The Kruskal-Wallis non-parametric test was used to analyse the remnants of filling materials, followed by the least significant difference (LSD) post-hoc test.  $P < 0.05$  was considered statistically significant. The “Total” row was excluded from the vertical statistical comparison.





**Figure 1.** Examples of before and after treatment X-rays for the different groups.

In straight canals, more filling material remained in the coronal third than in the middle third ( $P < 0.05$ ), whereas in curved canals, more filling material remained in the apical third than in the coronal third ( $P < 0.05$ ).

## DISCUSSION

The removal of old filling materials represents an important step in root canal retreatment, because it enables chemomechanical re-instrumentation and re-disinfection of the root canal system [24]. It has never been proven that removing all obturation material ensures the success of endodontic retreatment, nor that remaining gutta-percha or sealer causes retreatment to fail. However, removal of as much filling material as possible from inadequately prepared and filled root canals seems essential to uncover remaining necrotic tissue or bacteria that may be responsible for periapical inflammation and treatment failure.

Several techniques have been proposed to evaluate the filling material remaining after retreatment procedures, including: stereomicroscope evaluation [25], scanning electron microscopy [18], cone-beam computed tomography (CT) [13], radiography [11,26], clearing techniques [27] and micro-CT [19,20]. In this study, we used radiography according to the method of Gergi and Sabbagh [11]. This method is reportedly more reliable because residual gutta-percha or sealer may be dispersed by splitting the roots [26], and it remains the most common way to evaluate clinical results [28]. However, this method has limitations: radiographic images provide only two-dimensional information on a three-dimensional structure and may be subject to magnification and distortion [10]. It is also known that radiographs may not reveal all residual material, because small volumes of debris

may not be visualized [27]. To date, micro-CT represents the most precise method for this evaluation but it is extremely time-consuming [19].

The removal of filling materials and further cleaning and shaping may be more difficult in curved root canals than in straight canals and instrument distortion or breakage is more likely to occur [10]. In this study, more remnants of filling material were found in straight than in curved root canals regardless of the filling technique (lateral condensation: straight canals 19.87%/curved canals 15.49%; GuttaMaster<sup>®</sup>: straight canals 23.41%/curved canals 14.37%). One possible explanation for these results may be that, in this study, straight root canals were selected from single-rooted teeth, while curved canals were obtained from mandibular molars. Single-rooted teeth usually have larger diameters and more oval-shaped root canals than mesial canals of mandibular molars, which are usually rounder with smaller dimensions [29-31]. Even if additional instrumentation is used to refine root canal preparation, the apical diameter of the instruments generally used for retreatment is usually smaller than that of the file used for the original instrumentation [14]. The final diameter of the instrument chosen in this study (size 35, 0.04 taper) seems to be insufficient to clean properly straight root canals from single-rooted teeth, whereas it was more appropriate for separate mesial root canals of mandibular molars. The use of a larger file in the retreatment of straight root canals from single-rooted teeth may achieve better results.

The results of this study showed no statistically significant differences between Reciproc<sup>®</sup> and ProFile<sup>®</sup> systems in the time required for the removal of laterally condensed gutta-percha and in the evaluation of remnants of filling materials ( $P > 0.05$ ). However, the Reciproc<sup>®</sup> system left less filling material and required significantly less time to remove GuttaMaster<sup>®</sup> from both straight and curved

canals ( $P < 0.05$ ). One possible explanation for these results may be that the reciprocating motion and the “S”-shaped cross-section with two blades may enable Reciproc® files to pick-up the plastic carrier of GuttaMaster® and remove it more rapidly than the continuous rotation and radial lands cross-section of ProFile® instruments. Zuolo et al. [3] found that the time required to remove filling materials from maxillary central incisors was significantly shorter with Reciproc® instruments compared with Gates Glidden burs, stainless-steel hand files and Mtwo® retreatment files, supporting the hypothesis that reciprocating movement may be the most important factor because the Reciproc® and Mtwo® instruments have the same cross-section. Recently, Rödiger et al. [21] reported similar findings when comparing Reciproc® with Hedström files and ProTaper® Universal Retreatment instruments in the removal of laterally condensed gutta-percha from curved root canals. Recently, Silva et al. [32], compared the efficacy of reciprocation motion, WaveOne® and ProTaper® Retreatment system for removing gutta-percha and sealer from root canals, they concluded that WaveOne® was faster than ProTaper®. The authors explain that the better time-related results were due to they was used only one file in the WaveOne® group, whereas four files were needed to perform the retreatment in the ProTaper® group.

However, in both these studies, the percentage of remaining filling material was significantly lower than in this study (4.57% in straight canals, 8.3% in curved canals). Possible explanations for this discrepancy include the use of solvents or the type of analysis; in fact, one of the studies used imaging software [3] and the other used micro-CT scanning [21].

The results of the present study were also similar to those reported by Fruchi et al. [20], who concluded that Reciproc® and WaveOne® instruments (Dentsply-

Maillefer) removed the filling material from curved roots canals efficiently but not completely. The efficacy of reciprocating systems in removing filling materials from root canals was also reported by Rios et al. [33], who concluded that Reciproc® and WaveOne® reciprocating files were as effective as ProTaper® Universal rotary retreatment files in removing gutta-percha and sealer from the root canals of maxillary incisors.

In this study, the mean time required to remove the plastic carriers with ProFile® instruments was similar to that reported by Royzenblat and Goodell [34] in their study on moderately curved mesiobuccal root canals of mandibular molars and to that reported by Baratto Filho et al. [15] in their study on single-rooted mandibular canines.

Regardless of the technique, more residual filling material remained in the apical third than in the middle and coronal thirds of curved root canals, as previously reported [8,11,35].

## CONCLUSIONS

In conclusion, the use of a Reciproc® reciprocating file may be beneficial in the retreatment of carrier-based filling materials, given that it removed the plastic carrier, gutta-percha and sealer from both straight and curved root canals faster and better than ProFile® instruments.

## ACKNOWLEDGMENTS AND DISCLOSURE STATEMENTS

The authors acknowledge Dr Jaume Llopis for his statistical support. The authors report no conflicts of interest related to this study.

## REFERENCES

1. Siqueira JF Jr. Aetiology of root canal treatment failure: why well-treated teeth can fail. *Int Endod J.* 2001 Jan;34(1):1-10. [Medline: [11307374](#)] [doi: [10.1046/j.1365-2591.2001.00396.x](#)]
2. Hammad M, Qualtrough A, Silikas N. Three-dimensional evaluation of effectiveness of hand and rotary instrumentation for retreatment of canals filled with different materials. *J Endod.* 2008 Nov;34(11):1370-3. [Medline: [18928849](#)] [doi: [10.1016/j.joen.2008.07.024](#)]
3. Zuolo AS, Mello JE Jr, Cunha RS, Zuolo ML, Bueno CE. Efficacy of reciprocating and rotary techniques for removing filling material during root canal retreatment. *Int Endod J.* 2013 Oct;46(10):947-53. [Medline: [23506150](#)] [doi: [10.1111/iej.12085](#)]
4. Somma F, Cammarota G, Plotino G, Grande NM, Pameijer CH. The effectiveness of manual and mechanical instrumentation for the retreatment of three different root canal filling materials. *J Endod.* 2008 Apr;34(4):466-9. [Medline: [18358899](#)] [doi: [10.1016/j.joen.2008.02.008](#)]
5. Wolcott JF, Himel VT, Hicks ML. Thermafil retreatment using a new “System B” technique or a solvent. *J Endod.* 1999 Nov;25(11):761-4. [Medline: [10726547](#)] [doi: [10.1016/S0099-2399\(99\)80127-7](#)]
6. Wilcox LR. Endodontic retreatment: ultrasonics and chloroform as the final step in reinstrumentation. *J Endod.* 1989 Mar;15(3):125-8. [Medline: [2607281](#)] [doi: [10.1016/S0099-2399\(89\)80133-5](#)]

7. Viducić D, Jukić S, Karlović Z, Bozić Z, Miletić I, Anić I. Removal of gutta-percha from root canals using an Nd:YAG laser. *Int Endod J.* 2003 Oct;36(10):670-3. [Medline: [14511223](#)] [doi: [10.1046/j.1365-2591.2003.00710.x](#)]
8. Aydin B, Köse T, Calişkan MK. Effectiveness of HERO 642 versus Hedström files for removing gutta-percha fillings in curved root canals: an ex vivo study. *Int Endod J.* 2009 Nov;42(11):1050-6. [Medline: [19825041](#)] [doi: [10.1111/j.1365-2591.2009.01624.x](#)]
9. Giuliani V, Cocchetti R, Pagavino G. Efficacy of ProTaper universal retreatment files in removing filling materials during root canal retreatment. *J Endod.* 2008 Nov;34(11):1381-4. [Medline: [18928852](#)] [doi: [10.1016/j.joen.2008.08.002](#)]
10. Unal GC, Kaya BU, Taç AG, Keçeci AD. A comparison of the efficacy of conventional and new retreatment instruments to remove gutta-percha in curved root canals: an ex vivo study. *Int Endod J.* 2009 Apr;42(4):344-50. [Medline: [19220515](#)] [doi: [10.1111/j.1365-2591.2008.01518.x](#)]
11. Gergi R, Sabbagh C. Effectiveness of two nickel-titanium rotary instruments and a hand file for removing gutta-percha in severely curved root canals during retreatment: an ex vivo study. *Int Endod J.* 2007 Jul;40(7):532-7. [Medline: [17511787](#)] [doi: [10.1111/j.1365-2591.2007.01254.x](#)]
12. Hülsmann M, Bluhm V. Efficacy, cleaning ability and safety of different rotary NiTi instruments in root canal retreatment. *Int Endod J.* 2004 Jul;37(7):468-76. [Medline: [15189436](#)] [doi: [10.1111/j.1365-2591.2004.00823.x](#)]
13. Marfisi K, Mercade M, Plotino G, Duran-Sindreu F, Bueno R, Roig M. Efficacy of three different rotary files to remove gutta-percha and Resilon from root canals. *Int Endod J.* 2010 Nov;43(11):1022-8. [Medline: [20726911](#)] [doi: [10.1111/j.1365-2591.2010.01758.x](#)]
14. Marques da Silva B, Baratto-Filho F, Leonardi DP, Henrique Borges A, Volpato L, Branco Barletta F. Effectiveness of ProTaper, D-RaCe, and Mtwo retreatment files with and without supplementary instruments in the removal of root canal filling material. *Int Endod J.* 2012 Oct;45(10):927-32. [Medline: [22486933](#)] [doi: [10.1111/j.1365-2591.2012.02051.x](#)]
15. Baratto Filho F, Ferreira EL, Fariniuk LF. Efficiency of the 0.04 taper ProFile during the re-treatment of gutta-percha-filled root canals. *Int Endod J.* 2002 Aug;35(8):651-4. [Medline: [12196217](#)] [doi: [10.1046/j.1365-2591.2002.00514.x](#)]
16. Wilcox LR, Van Surksun R. Endodontic retreatment in large and small straight canals. *J Endod.* 1991 Mar;17(3):119-21. [Medline: [1940725](#)] [doi: [10.1016/S0099-2399\(06\)81742-5](#)]
17. De-Deus G, Gurgel-Filho ED, Magalhães KM, Coutinho-Filho T. A laboratory analysis of gutta-percha-filled area obtained using Thermafil, System B and lateral condensation. *Int Endod J.* 2006 May;39(5):378-83. [Medline: [16640636](#)] [doi: [10.1111/j.1365-2591.2006.01082.x](#)]
18. Bramante CM, Fidelis NS, Assumpção TS, Bernardineli N, Garcia RB, Bramante AS, de Moraes IG. Heat release, time required, and cleaning ability of MTwo R and ProTaper universal retreatment systems in the removal of filling material. *J Endod.* 2010 Nov;36(11):1870-3. [Medline: [20951303](#)] [doi: [10.1016/j.joen.2010.08.013](#)]
19. Roggendorf MJ, Legner M, Ebert J, Fillery E, Frankenberger R, Friedman S. Micro-CT evaluation of residual material in canals filled with Activ GP or GuttaFlow following removal with NiTi instruments. *Int Endod J.* 2010 Mar;43(3):200-9. [Medline: [20158531](#)] [doi: [10.1111/j.1365-2591.2009.01659.x](#)]
20. Fruchi Lde C, Ordinola-Zapata R, Cavenago BC, Hungaro Duarte MA, Bueno CE, De Martin AS. Efficacy of reciprocating instruments for removing filling material in curved canals obturated with a single-cone technique: a micro-computed tomographic analysis. *J Endod.* 2014 Jul;40(7):1000-4. [Medline: [24935552](#)] [doi: [10.1016/j.joen.2013.12.011](#)]
21. Rödiger T, Reicherts P, Konietzschke F, Dullin C, Hahn W, Hülsmann M. Efficacy of reciprocating and rotary NiTi instruments for retreatment of curved root canals assessed by micro-CT. *Int Endod J.* 2014 Oct;47(10):942-8. [Medline: [24386931](#)] [doi: [10.1111/iej.12239](#)]
22. Pruett JP, Clement DJ, Carnes DL Jr. Cyclic fatigue testing of nickel-titanium endodontic instruments. *J Endod.* 1997 Feb;23(2):77-85. [Medline: [9220735](#)] [doi: [10.1016/S0099-2399\(97\)80250-6](#)]
23. Plotino G, Grande NM, Porciani PF. Deformation and fracture incidence of Reciproc instruments: a clinical evaluation. *Int Endod J.* 2015 Feb;48(2):199-205. [Medline: [24754602](#)] [doi: [10.1111/iej.12302](#)]
24. Ergenholtz G, Lekholm U, Milthorpe R, Heden G, Odesjö B, Engström B. Retreatment of endodontic fillings. *Scand J Dent Res.* 1979 Jun;87(3):217-24. [Medline: [29388](#)] [doi: [10.1111/j.1600-0722.1979.tb00675.x](#)]
25. Imura N, Kato AS, Hata GI, Uemura M, Toda T, Weine F. A comparison of the relative efficacies of four hand and rotary instrumentation techniques during endodontic retreatment. *Int Endod J.* 2000 Jul;33(4):361-6. [Medline: [11307212](#)] [doi: [10.1046/j.1365-2591.2000.00320.x](#)]
26. Ferreira JJ, Rhodes JS, Ford TR. The efficacy of gutta-percha removal using ProFiles. *Int Endod J.* 2001 Jun;34(4):267-74. [Medline: [11482137](#)] [doi: [10.1046/j.1365-2591.2001.00379.x](#)]
27. Schirrmeyer JF, Wrbas KT, Meyer KM, Altenburger MJ, Hellwig E. Efficacy of different rotary instruments for gutta-percha removal in root canal retreatment. *J Endod.* 2006 May;32(5):469-72. [Medline: [16631851](#)] [doi: [10.1016/j.joen.2005.10.052](#)]
28. Abramovitz I, Relles-Bonar S, Baransi B, Kfir A. The effectiveness of a self-adjusting file to remove residual gutta-percha after retreatment with rotary files. *Int Endod J.* 2012 Apr;45(4):386-92. [Medline: [22283664](#)] [doi: [10.1111/j.1365-2591.2011.01988.x](#)]
29. Bellucci C, Perrini N. A study on the thickness of radicular dentine and cementum in anterior and premolar teeth. *Int Endod J.* 2002 Jul;35(7):594-606. [Medline: [12190899](#)] [doi: [10.1046/j.1365-2591.2002.00537.x](#)]

30. Plotino G, Grande NM, Mazza C, Petrovic R, Testarelli L, Gambarini G. Influence of size and taper of artificial canals on the trajectory of NiTi rotary instruments in cyclic fatigue studies. *Oral Surg Oral Med Oral Pathol Oral Radiol Endod*. 2010 Jan;109(1):e60-6. [Medline: [19926504](#)] [doi: [10.1016/j.tripleo.2009.08.009](#)]
31. Sauáia TS, Gomes BP, Pinheiro ET, Zaia AA, Ferraz CC, Souza-Filho FJ, Valdrighi L. Thickness of dentine in mesial roots of mandibular molars with different lengths. *Int Endod J*. 2010 Jul;43(7):555-9. [Medline: [20636516](#)] [doi: [10.1111/j.1365-2591.2010.01694.x](#)]
32. Silva EJ, Orłowsky NB, Herrera DR, Machado R, Krebs RL, Coutinho-Filho Tde S. Effectiveness of rotatory and reciprocating movements in root canal filling material removal. *Braz Oral Res*. 2015;29:1-6. [Medline: [25466331](#)] [doi: [10.1590/1807-3107BOR-2015.vol29.0008](#)]
33. Rios Mde A, Villela AM, Cunha RS, Velasco RC, De Martin AS, Kato AS, Bueno CE. Efficacy of 2 reciprocating systems compared with a rotary retreatment system for gutta-percha removal. *J Endod*. 2014 Apr;40(4):543-6. [Medline: [24666908](#)] [doi: [10.1016/j.joen.2013.11.013](#)]
34. Royzenblat A, Goodell GG. Comparison of removal times of Thermafil plastic obturators using ProFile rotary instruments at different rotational speeds in moderately curved canals. *J Endod*. 2007 Mar;33(3):256-8. [Medline: [17320708](#)] [doi: [10.1016/j.joen.2006.10.004](#)]
35. Masiero AV, Barletta FB. Effectiveness of different techniques for removing gutta-percha during retreatment. *Int Endod J*. 2005 Jan;38(1):2-7. [Medline: [15606816](#)] [doi: [10.1111/j.1365-2591.2004.00878.x](#)]

**To cite this article:**

Marfisi K, Mercadé M, Plotino G, Clavel T, Duran-Sindreu F, Roig M.

Efficacy of Reciproc® and Profile® Instruments in the Removal of Gutta-Percha from Straight and Curved Root Canals *ex Vivo*. *J Oral Maxillofac Res* 2015;6(3):e1.

URL: <http://www.ejomr.org/JOMR/archives/2015/3/e1/v6n3e1.pdf>

doi: [10.5037/jomr.2015.6301](#)

**Copyright** © Marfisi K, Mercadé M, Plotino G, Clavel T, Duran-Sindreu F, Roig M. Published in the JOURNAL OF ORAL & MAXILLOFACIAL RESEARCH (<http://www.ejomr.org>), 30 September 2015.

This is an open-access article, first published in the JOURNAL OF ORAL & MAXILLOFACIAL RESEARCH, distributed under the terms of the [Creative Commons Attribution-Noncommercial-No Derivative Works 3.0 Unported License](#), which permits unrestricted non-commercial use, distribution, and reproduction in any medium, provided the original work and is properly cited. The copyright, license information and link to the original publication on (<http://www.ejomr.org>) must be included.