

end-to-side, and the concomitant veins of the radial artery end-to-end. Saaristo et al. [5] combined the breast reconstruction using abdominal flaps with the transfer of vascularized inguinal lymph nodes based on the superficial circumflex iliac vessels or the superficial inferior epigastric vessels, and the anastomoses were performed from the deep inferior epigastric vessels end-to-end to the thoracodorsal vessels.

According to the research, there is no consensus on the staging of lymphedema. Only three studies [2-4] have reported precise preoperative staging systems; however, each study used different criteria. Fifty-seven of 73 patients (78%) had postoperative improvement of the affected limb. In every study, a different postoperative evaluation method was used, and the relationship between the lymph node recipient site (axilla, elbow, or wrist) and the anatomical site with the maximum improvement was not clearly reported.

Becker et al. [2] reported that from the 18 patients, the upper limb perimeter returned to normal in 10 cases, remained unchanged in 2 cases, and decreased by more than 50% of its value in 6 patients and less than 50% of its value in 6 other patients. Two years later, Becker et al. [3] evaluated the influence of LNT in postmastectomy neuropathic pain in 6 patients. All of the patients had relief of the symptoms and in 5 patients the lymphedema resolved. Gharb et al. [4] compared the classic groin lymph node flap with a groin flap based on hilar perforators and reported that differences between the preoperative and postoperative measurements were statistically significant only in the perforator-based group at the levels below the elbow, wrist, and midpalm. Saaristo et al. [5] achieved reduction of the affected limb in 7 of 9 patients.

Even though it is implied that at early stage lymphedema, the LNT has better results, the influence of LNT at each stage of lymphedema is not clear. In addition, 17.8% of the patients required an additional procedure (suction assisted lipectomy [SAL] or skin excision) due to lack of sufficient improvement after LNT.

According to existing clinical studies, LNT is able to alleviate postmastectomy upper extremity lymphedema. However, the improvement is variable and no conclusions have been drawn regarding which technique, group of donor lymph nodes, or recipient site can ensure the maximum reduction of the affected limb.

More clinical studies are needed, and a consensus about the staging system of lymphedema and the evaluation methods for postoperative results should be established to enable drawing more certain conclusions.

References

1. Lin CH, Ali R, Chen SC, et al. Vascularized groin lymph node transfer using the wrist as a recipient site for management of postmastectomy upper extremity lymphedema. *Plast Reconstr Surg* 2009;123:1265-75.
2. Becker C, Assouad J, Riquet M, et al. Postmastectomy lymphedema: long-term results following microsurgical lymph node transplantation. *Ann Surg* 2006;243:313-5.
3. Becker C, Pham DN, Assouad J, et al. Postmastectomy neuropathic pain: results of microsurgical lymph nodes transplantation. *Breast* 2008;17:472-6.
4. Gharb BB, Rampazzo A, Spanio di Spilimbergo S, et al. Vascularized lymph node transfer based on the hilar perforators improves the outcome in upper limb lymphedema. *Ann Plast Surg* 2011;67:589-93.
5. Saaristo AM, Niemi TS, Viitanen TP, et al. Microvascular breast reconstruction and lymph node transfer for postmastectomy lymphedema patients. *Ann Surg* 2012;255:468-73.

Abdominoplasty Access for Desmoid Tumor Resection in the Rectus Abdominis Muscle

Gabriel Djedovic, Ralph Verstappen, Gerhard Pierer, Ulrich M. Rieger
Department of Plastic, Reconstructive and Aesthetic Surgery, Innsbruck Medical University, Innsbruck, Austria

Correspondence: Gabriel Djedovic
Department of Plastic, Reconstructive and Aesthetic Surgery, Innsbruck Medical University, 35 Anichstrasse, A-6020 Innsbruck, Austria
Tel: +43-512-504-81687, Fax: +43-512-504-22735, E-mail: gabriel.djedovic@i-med.ac.at

No potential conflict of interest relevant to this article was reported.

Received: 18 Mar 2013 • Revised: 3 Apr 2013 • Accepted: 4 May 2013
pISSN: 2234-6163 • eISSN: 2234-6171
<http://dx.doi.org/10.5999/aps.2013.40.4.451> • Arch Plast Surg 2013;40:451-453

Copyright © 2013 The Korean Society of Plastic and Reconstructive Surgeons
This is an Open Access article distributed under the terms of the Creative Commons Attribution Non-Commercial License (<http://creativecommons.org/licenses/by-nc/3.0/>) which permits unrestricted non-commercial use, distribution, and reproduction in any medium, provided the original work is properly cited.

With great interest we read the article “desmoid tumor of the rectus abdominis muscle in a postpartum patient” by Choi et al. [1]. In their article, the authors describe a case of a 36-year-old woman who presented with a painless mass in the right rectus abdominis muscle after delivery of two children, the latter three years before presentation. The authors resected the desmoid tumor with parts of the surrounding muscle through a small skin incision, localized directly over the tumor mass. Besides the aforementioned direct approach to the tumor mass and the usage of preexisting scars, other methods have also been described [2,3]. We would like to share our surgical approach in a similar case in our department that we think is superior for several reasons.

A 26-year-old female patient presented with a painless mass on the right abdominal region next to the umbilicus, which she had noticed 2 weeks earlier (Fig. 1). Similar to the case presented by Choi et al. [1], our patient did not have any family history of desmoid tumors, familial adenomatous polyposis syndrome, or Gardner syndrome. She was a non-smoker, did not drink alcohol, and had no history of

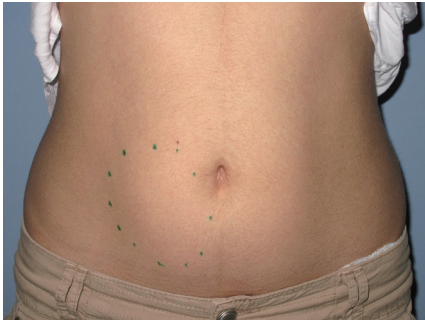

Fig. 1.
The patient presented with an 8 cm × 3.2 cm × 1.8 cm painless mass on the right abdominal region next to the umbilicus.

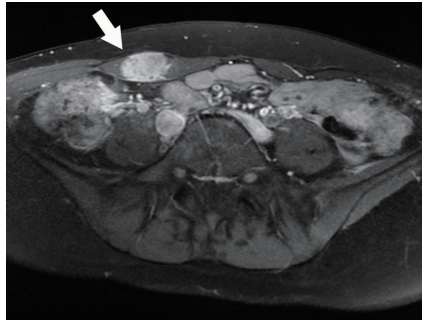


Fig. 2.
Preoperative magnetic resonance imaging findings of a hypodense mass in the right rectus abdominis muscle (white arrow).

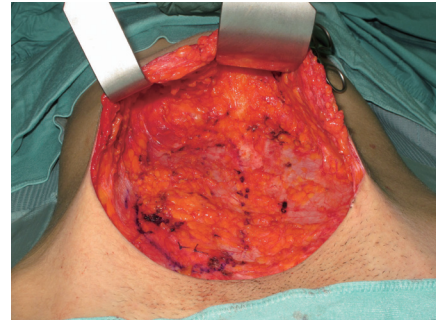


Fig. 3.
Intraoperative photo of the intramuscular tumor with a 3 cm circumferential resection margin of healthy tissue in the right rectus muscle.

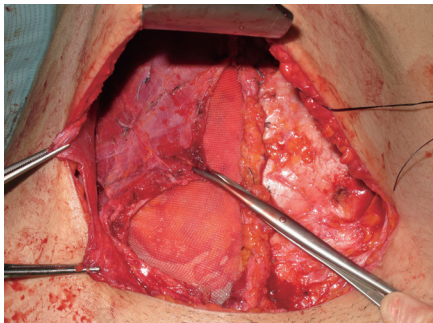


Fig. 4.
The abdominal wall was reconstructed with nonabsorbable polypropylene surgical mesh and the defect closed in layers.

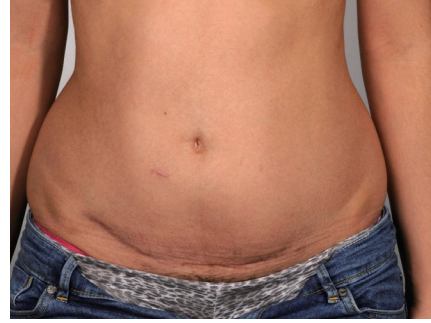

Fig. 5.
Final appearance of the abdominal region after 6 months.

trauma. She had given birth to one child by cesarean section 2 years earlier. Ultrasound revealed an undefined vascularized tumor in the right rectus abdominis muscle. A T1-weighted magnetic resonance image (MRI) revealed an 8 cm × 3.2 cm × 1.8 cm tumor mass in the right rectus abdominis muscle with high contrast medium enhancement without signs of infiltration of the surrounding fatty tissue or intra-abdominal structures, strongly resembling a desmoid tumor (Fig. 2). After punch biopsy, the histological examination revealed a strong suspicion of a desmoid tumor. After having discussed this case in our interdisciplinary tumor board, the decision for wide resection was made. Exposure of the anterior layer of the rectus sheath was performed via the preexisting scar of the cesarean section through an abdominoplasty approach (Fig. 3). Abdominoplasty was basically performed as described by Pitanguy et al. [4]. A solid mass was palpable in the right rectus abdominis muscle without macroscopic signs of tumor invasion of the rectus sheath. A wide local excision with a 3 cm circumferential resection margin of healthy tissue was performed. The abdominal wall was reconstructed with nonabsorbable polypropylene surgical mesh (Surgipro, Covidien, Mansfield, MA, USA) and the defect closed in layers (Fig. 4). Histological examination yielded clear resection margins with a minimum of 32 mm on circumferential

measurement after wide excision. After 6 months the patient showed no signs of relapse of the desmoid tumor and an excellent aesthetic outcome (Fig. 5). Follow-up MRI was performed 6 months postoperatively. Regular long-term follow-up visits are scheduled as desmoid tumors show aggressive clinical behavior such as repeated local recurrence.

Abdominoplasty has been described before for aesthetically pleasing results for defect coverage after wide resection of abdominal dermatofibrosarcoma protuberans [5]. Similarly our abdominoplasty approach for resection of desmoid tumors in this location allows for a naturally appearing abdomen with very little to no donor site morbidity and almost invisible scarring, which can easily be hidden by the patient's underwear. The cosmetic result achieved with this surgical technique is excellent (Fig. 5) and in our opinion is far superior to the aforementioned described techniques, especially in postpartum patients who frequently benefit from a full abdominoplasty. In addition, coverage of wide resection defects is easily achievable.

The advantages of the abdominoplasty approach for desmoid tumor resection and abdominal wall repair are improved and unparalleled cosmetic outcome, and minimal donor site morbidity achieved by a single-stage procedure. To our knowledge, this is the first report

of an abdominoplasty approach for desmoid tumor resection and abdominal wall repair in the literature. In conclusion, we recommend this technique for its technical ease and superior outcome provided that there is no evidence of infiltration of adjacent tissue. We would like to emphasize that our abdominoplasty approach is by no means a technique for each and every case. Of course, some cases will yield functional deficits, for example, if extensive resections have to be carried out. However, in selected cases, this technique is a worthwhile alternative to be considered. Clearly, in each case, tumor- and patient-specific factors such as localization, size, anatomic structures affected, and estimated resection margins have to be taken into account, and therefore deliberate consideration has to be given to other reconstructive methods available as well.

References

1. Choi SH, Lee JH, Seo BF, et al. Desmoid tumor of the rectus abdominis muscle in a postpartum patient. *Arch Plast Surg* 2012;39:439-41.
2. Berri RN, Baumann DP, Madewell JE, et al. Desmoid tumor: current multidisciplinary approaches. *Ann Plast Surg* 2011;67:551-64.
3. Li MH, Leng JH, Jiang Y, et al. Abdominal wall lump after cesarean delivery. *Obstet Gynecol* 2012;120:494-7.
4. Pitanguy I, Mayer B, Labrakis G. Abdominoplasty: personal surgical guidelines. *Zentralbl Chir* 1988;113:765-71.
5. Dagregorio G, Darsonval V. Aesthetic surgery techniques after excision of dermatofibrosarcoma protuberans: a case report. *Br J Plast Surg* 2005;58:556-60.