



Ossifying Fibroma of the Mandible: A Case Report Using Vascularized Free Fibula Flap Reconstruction

My-Phong Hoang, DDS*
 Thai-Thanh Nguyen, DDS*
 Long-Khanh Nguyen, PhD,
 DDS*
 Seng-Feng Jeng, MD†

Summary: We report a case of ossifying fibroma of the mandible in a 38-year-old woman. The mandibular resection involved the disarticulation of the condyle while preserving the articular disc. The segmental bony defect was then reconstructed with free fibula flap; the additional contouring of the distal fibular flap was performed during surgery to restore the patient's condylar function. A 2-year follow-up revealed the maintenance of excellent functional and aesthetic outcomes. (*Plast Reconstr Surg Glob Open* 2015;3:e470; doi: 10.1097/GOX.0000000000000450; Published online 22 July 2015.)

Ossifying fibroma (OF) is classified as a benign bone neoplasm. In 2005, the World Health Organization classified OF to be synonymous with cementifying fibroma and cemento-ossifying fibroma. Complete removal of the lesion is recommended once the diagnosis is established.¹

Based on the 8 permutations described (C, L, H, LC, HC, LCL, HCL, and HH), our patient belonged to the H group where the “hemimandibular” defect involved the resection of the lateral mandible and the condyle.²

The condylar reconstruction typically consists of the sole use of reconstruction plates, autogenous bone grafting, or pedicled bone grafting.

We report a case of OF of the mandible in a 38-year-old patient. The treatment involved condylar resection and mandibular reconstruction with free fibular flap. Furthermore, the distal end of the flap was contoured to restore the patient's condylar

function. Our 2-year follow-up revealed excellent functional and aesthetic outcomes for the patient.

CASE REPORT

A 38-year-old woman presented with a complaint of swelling and facial asymmetry in the left angle of the mandible that started 3 months prior.

Panoramic radiograph revealed a large intraosseous lesion with radiopacity from the left angle of the mandible to the condyle. A biopsy of the lesion and the subsequent histological test confirmed the diagnosis of OF (Fig. 1).

Segmental mandibulectomy was done and resulted in a bone defect 7 cm in length; the condyle was disarticulated from the joint while the articular disc was preserved.

A free fibular flap was harvested from the patient's left leg, and the distal end of the fibula was rounded to simulate the contour of a condyle. The masseter muscle was sutured to the angle of the reconstruction plate to fix the distal end into the glenoid fossa.

The postoperative cone beam computed tomography showed the flap inset and its position to be within the glenoid fossa. Intermaxillary fixation was used during the initial 4 weeks of postoperative period to maintain correct occlusion for the patient. The patient was then followed up for 2 years showing excellent functional and aesthetic results (Figs. 2, 3).

From the *Department of Plastic and Maxillofacial Surgery, Vietnam-Cuba Friendship Hospital, Hanoi, Vietnam; and †Department of Plastic and Reconstructive Surgery, E-DA Hospital, Kaohsiung, Taiwan.

Received for publication April 16, 2015; accepted June 11, 2015.

Copyright © 2015 The Authors. Published by Wolters Kluwer Health, Inc. on behalf of The American Society of Plastic Surgeons. All rights reserved. This is an open-access article distributed under the terms of the Creative Commons Attribution-Non Commercial-No Derivatives License 4.0 (CCBY-NC-ND), where it is permissible to download and share the work provided it is properly cited. The work cannot be changed in any way or used commercially.

DOI: 10.1097/GOX.0000000000000450

Disclosure: The authors have no financial interest to declare in relation to the content of this article. The Article Processing Charge was paid for by the authors.

The cone beam computed tomography showed that the distal end of the fibula positioned appropriately in the glenoid fossa (Fig. 4).

DISCUSSION

The differential diagnosis for OF includes fibrous dysplasia, odontogenic cysts, chondrosarcoma, osteosarcoma, and squamous cell carcinoma. Generally, the recommended treatment for OF is complete excision of the tumor. The entire tumor should be removed along with the involved site.

In the event where the tumor directly invades the condyle, incorporating the native condyle into the free graft would not be feasible; out of necessity, surgeons have placed the distal end of the fibular flap directly into the glenoid fossa with or without contouring. To optimize the function of the temporomandibular joint after condylar reconstructions, preserving the articular disc after disarticulation then becomes critical. Wax et al reported that in a series of 17 reconstructions in which a suture was placed to stabilize the preserved disc against the upper end of the fibula flap, patients

were able to maintain excellent functional and cosmetic results.^{3,4} In a follow-up study (average follow-up of 31 months) based on radiographic and clinical examination, Guyot et al³ evaluated the surgical and functional outcomes of 11 patients who had undergone temporomandibular joint reconstruction with a free fibular flap following condylar resection; they reported that patients maintained sufficient mouth opening and an absence of joint ankylosis. In addition, they observed structural remodeling and rounding of the reconstructed condyle in most patients during follow-up. The authors suggested that the disc preservation might have played an important role in controlling the form of the mandibular condyle through remodeling.³

In the management of our patient with OF, our surgical approach was supported by sound evidence as mentioned previously. The reconstructed condyle maintained appropriate position in the glenoid fossa, the interincisal opening was preserved, and the occlusion was unchanged.⁵⁻⁷ The patient was

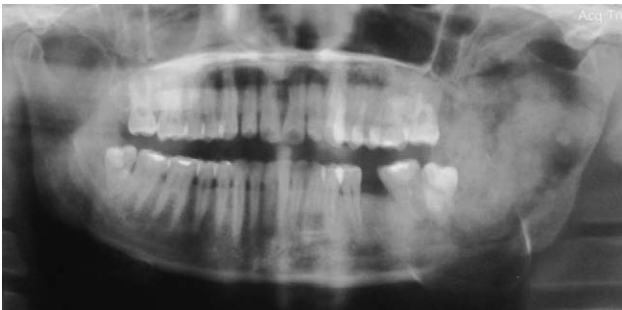


Fig. 1. A large intraosseous lesion with radiopacity from the left angle of the mandible to the condyle on the preoperative panorex.

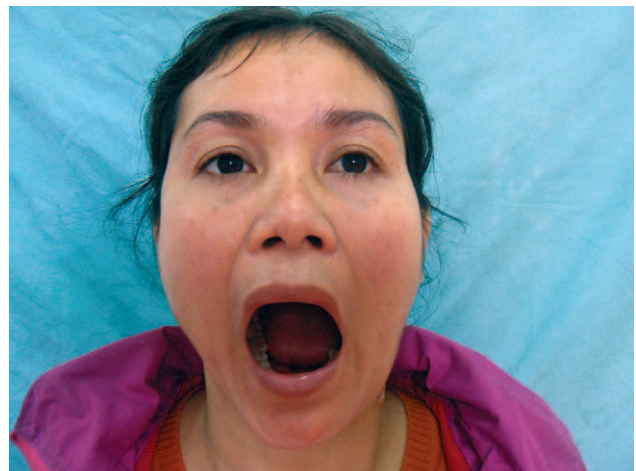

Fig. 3. The mouth opening was preserved.

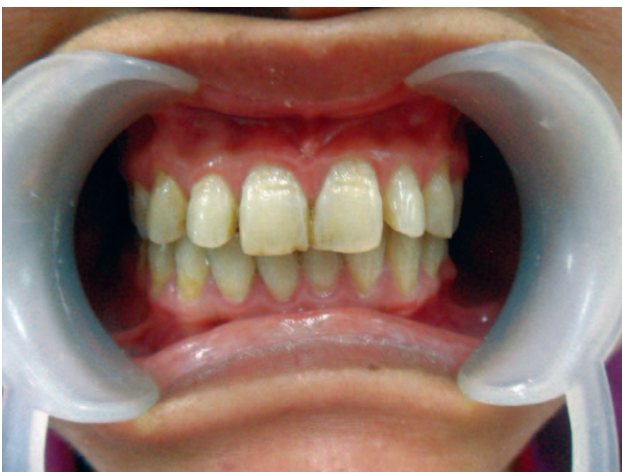

Fig. 2. Postoperative dental occlusion.

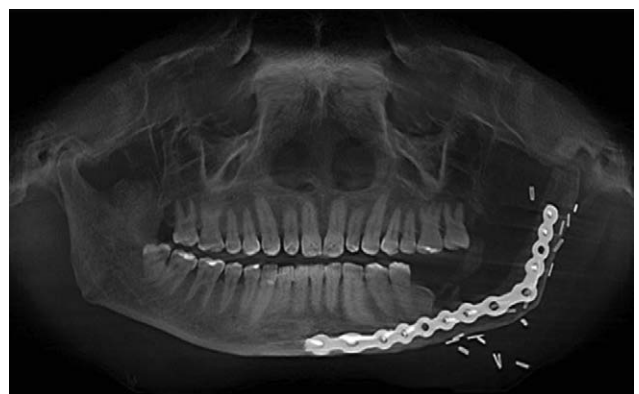

Fig. 4. Mandibular and condylar reconstruction by fibular flap and postoperative 2-year follow-up on cone beam computed tomography.

followed up for 2 years with promising prognosis and excellent functional and aesthetic outcomes.

Seng-Feng Jeng, MD

Department of Plastic Surgery
E-Da Hospital, No. 1, Yi-Da Road
Jiao-Su Village, Yan-Chao District
Kaohsiung City 824, Taiwan
E-mail: ed105839@edah.org.tw

PATIENT CONSENT

The patient provided written consent for the use of her image.

REFERENCES

1. Slootweg PJ, El Mofty SK. *Pathology and Genetics of Head and Neck Tumors*. Lyon, France: IARC Press; 2005:319–321.
2. Hidalgo DA. Fibula free flap: a new method of mandible reconstruction. *Plast Reconstr Surg*. 1989;84:71–72.
3. Guyot L, Richard O, Layoun W, et al. Long-term radiological findings following reconstruction of the condyle with fibular free flaps. *J Craniomaxillofac Surg*. 2004;32:98–102.
4. Wax MK, Winslow CP, Hansen J, et al. A retrospective analysis of temporomandibular joint reconstruction with free fibula microvascular flap. *Laryngoscope* 2000;110:977–981.
5. Carlson ER. Disarticulation resections of the mandible: a prospective review of 16 cases. *J Oral Maxillofac Surg*. 2002;60:176–181.
6. Thor A, Rojas RA, Hirsch JM. Functional reconstruction of the temporomandibular joint with a free fibular microvascular flap. *Scand J Plast Reconstr Surg Hand Surg*. 2008;42:233–240.
7. Chim H, Salgado CJ, Chen H-C. Reconstruction of mandibular defects. *Semin Plast Surg*. 2010;24:188–197.