

Clear Cell Hepatocellular Carcinoma with Spontaneous Regression of Primary and Metastatic Lesions

Seong-Woo Jeon, M.D., Myung-Kwon Lee, M.D., Young-Doo Lee, M.D.,
Hyang-Eun Seo, M.D., Chang-Min Cho, M.D.,
Won-Young Tak, M.D. and Young-Oh Kweon, M.D.,

*Division of Gastroenterology and Hepatology, Department of Internal Medicine,
Kyungpook National University School of Medicine, Daegu, Korea*

The prognosis of advanced hepatocellular carcinoma (HCC) tends to be poor. Spontaneous regression of this lesion is extremely rare. In this report, we describe a case of HCC which spontaneously regressed along with a metastatic lesion of the chest wall. A huge HCC in the right lobe, the largest diameter of which was about 15×12 cm, developed in a 72-year-old man. He and his family refused further treatment. Three months after the diagnosis, metastasis to the chest wall was detected. We prescribed a painkiller for him in order to alleviate chest pain. Fourteen months after the diagnosis, the tumor size of the primary lesion was downsized to 3×4 cm in diameter. A biopsy taken from the chest wall proved to be clear cell HCC (CHCC). Since then, the metastatic lesion has also disappeared. Here, we report this unusual histologically proven CHCC with literature reviews.

Key Words : Carcinoma, Hepatocellular, Neoplasm regression, Spontaneous

INTRODUCTION

Hepatocellular carcinoma (HCC) is one of the most prevalent cancers, especially in Asia. If it is not diagnosed early, it is difficult to manage by surgical techniques or local therapy. The prognosis of advanced HCC is grave and the average survival time of advanced HCC is less than 6 months¹⁾. Poor prognosis is related to several factors, such as the biological malignant property of cells, accompanied cirrhosis, and higher stages. Spontaneous regression of HCC is extremely rare. To our knowledge, however, several cases have been reported. The causes of spontaneous regression of HCC are not well defined. Proposed mechanisms are biologic effects, infarction secondary to vascular insult, and immune responses. Here, we report a case of spontaneous regression of the primary and metastatic lesions in a patient with HCC.

CASE REPORT

A previously healthy 72-year-old man visited Kyungpook National University Hospital in August 2002 because of intermittent right-upper quadrant discomfort which had recently developed. Physical examination revealed a hard, tender liver that extended to 5cm below the right costal margin. He had been consuming more than 70 g/day alcohol for the last 20 years. A biological evaluation showed a normal complete blood count (WBC 7800/mm³, Hemoglobin 14.2 g/dL, Platelet 164000/mm³), a normal total protein/albumin (7.4 and 4.5 g/dL, respectively), and a normal bilirubin (total bilirubin 0.6 mg/dL), but his liver enzymes were elevated (AST/ALT 118/43 IU/L). Prothrombin time was 89.8%. He was negative for surface antigen and antibodies to HBV, HBc-IgG, and HCV. Ultrasonography of the abdomen revealed a huge mass of about 9×11 cm on the right lobe of the liver. Abdominal enhanced computerized tomography (CT) scanning also revealed

• Received : December 7, 2004

• Accepted : March 14, 2005

• Correspondence to : Young-Oh Kweon, M.D., Division of Gastroenterology and Hepatology, Department of Internal Medicine Kyungpook National University Hospital, 50, Samduk 2-Ga, Chung-gu, Daegu, 700-721, Korea Tel : 82-53-420-5512, Fax : 82-53-426-8773, E-mail : yokweon@knu.ac.kr

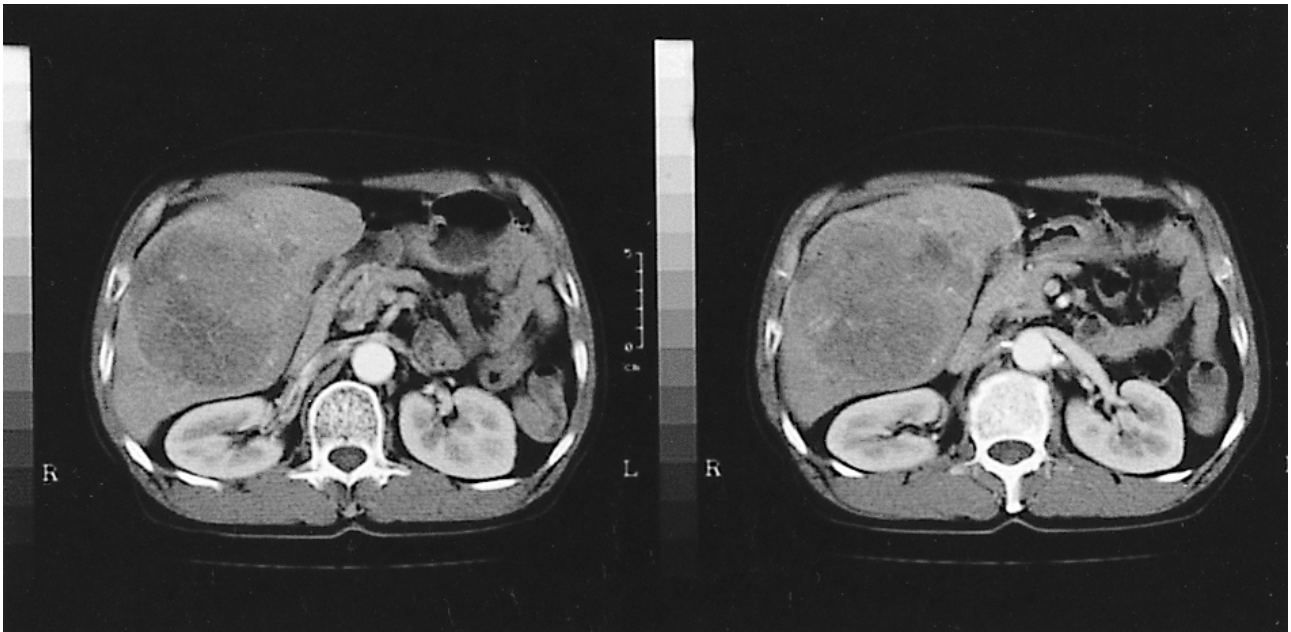


Figure 1. Computed tomography showing a huge hepatic mass on arterial phase.

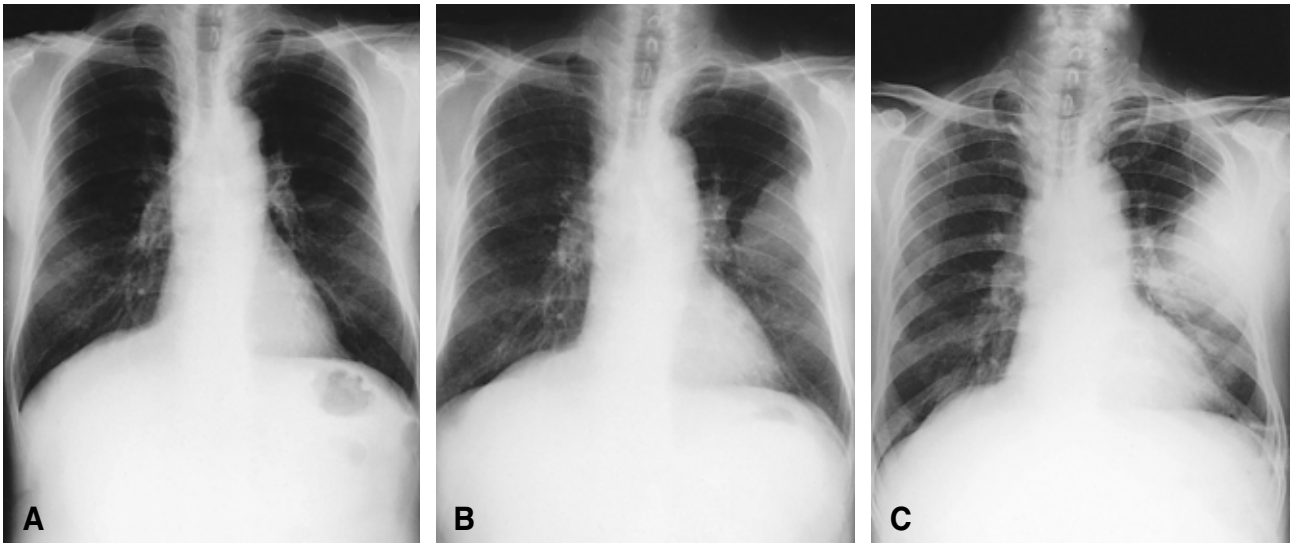


Figure 2. (A) Initial chest X-ray showing no abnormalities. (B) Chest X-ray showing chest wall metastasis with invading adjacent ribs after 3 months. (C) Chest X-ray showing growing chest wall mass compared to previous images.

the same findings with right portal vein invasion (Figure 1). The lesion was shown not to be high-density on an arterial phase because of the hugeness and central necrosis. Instead, it was low-density on a portal phase. There were no abnormalities on either kidney or on other intra-abdominal organs. His serum alpha-fetoprotein (AFP) was above 500 ng/mL. His Child-Pugh score was 5 (class A). HCC (modified UICC stage IV-A, T₄N₀M₀) was clinically diagnosed, and we recommended him for transarterial chemoembolization (TACE). However, he refused

the procedure, and we decided to follow-up regularly. Three months later (November 2002), he complained of pain in the left anterior chest region. A chest X-ray showed a lesion which was invading the rib on the left upper lung (Figure 2). A follow-up CT scan revealed an aggravated primary lesion of the liver, and he attended the outpatient clinic regularly where he received painkillers. He was later hospitalized because of the intermittent aggravated pain in the left anterior chest region. The mass size slowly increased up to 10×10 cm in diameter during the

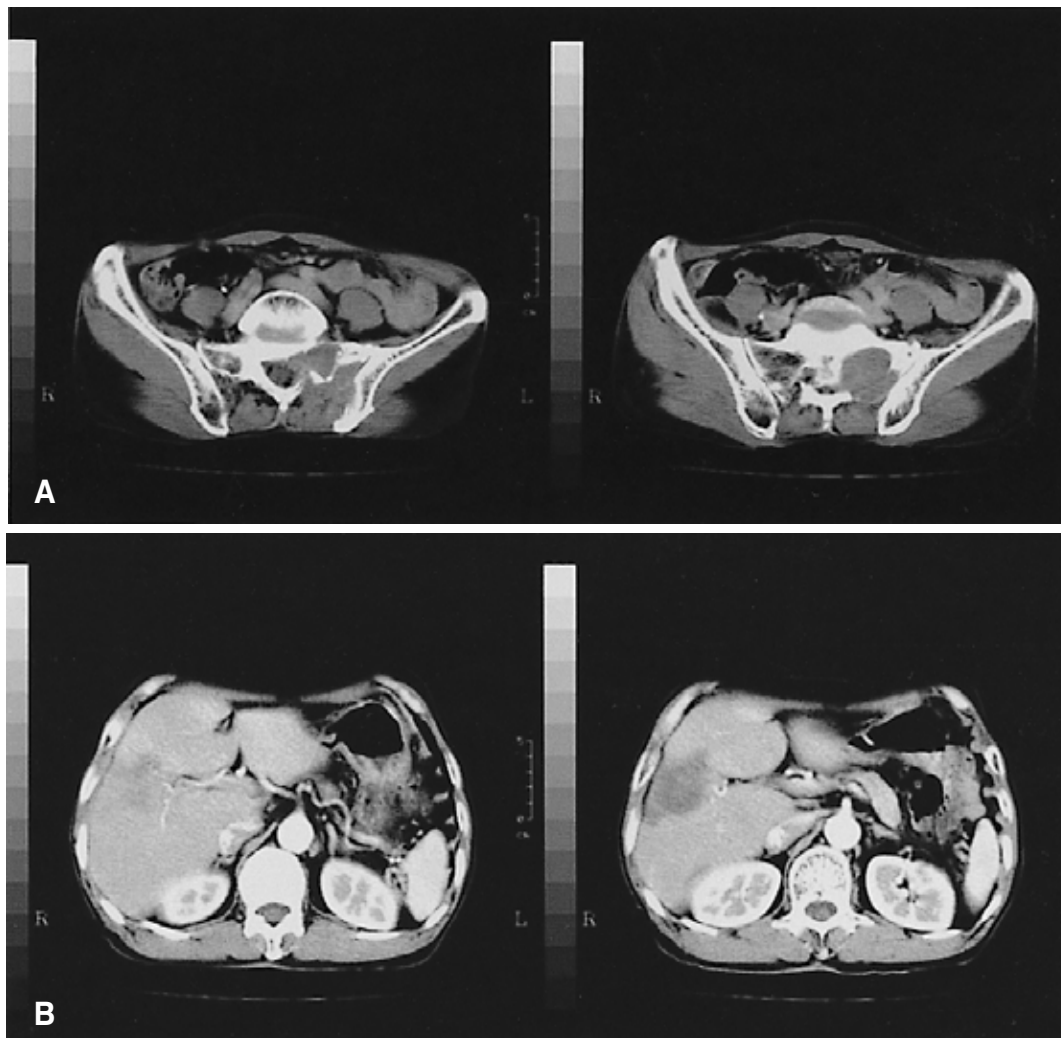


Figure 3. (A) Computed tomography showing a metastatic mass invading the left sacrum. (B) Computed tomography showing decreased hepatic mass compared to initial scan.

follow-up period (Figure 2). Fourteen months later (October 2003), he complained of pain in his left hip joint. A CT scan revealed a mass invading the left sacrum. On scanned upper abdominal imaging, however, it was noted that the primary HCC had decreased in size (about 4×3 cm) (Figure 3). His serum AFP was above 500 ng/mL. To rule out other rare conditions, we performed an incisional biopsy on the chest mass. Microscopic examination showed necrosis and eccentric nucleoli with vacuolated foamy-to-clear cytoplasm that did not stain with hematoxylin and eosin (Figure 4). These findings were consistent with clear cell carcinoma. Seventeen months later (January 2004), he felt better than before and did not complain of chest pain. It was a surprise to see upon physical examination that no palpable mass was found. A chest X-ray also showed no mass lesion. A CT scan revealed the same findings, and on the scanned upper-abdominal imaging, a

further decrease in the primary lesion (about 3×2 cm) was noted (Figure 5). His serum AFP, however, was still above 500 ng/mL. Now (June 2004), it has been about 23 months since the diagnosis. He no longer complains of discomfort and he attends the outpatient clinic regularly. On imaging study, there has been no progression in chest, liver, or sacral lesions. Additionally, his serum AFP has decreased to 8.0 ng/mL (Figure 6).

DISCUSSION

Generally, the spontaneous regression of cancer is defined by the disappearance of a malignant tumor without treatment that may cause regression. The spontaneous regression of cancer is rare, with an estimated incidence of one per 60,000–100,000 cancer patients²⁾. The spontaneous regression

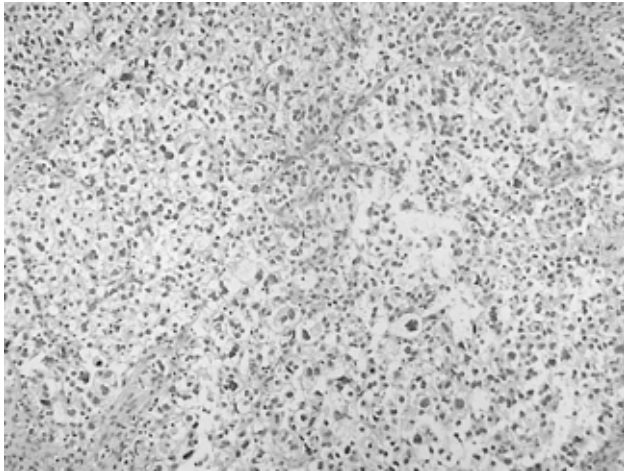


Figure 4. Microscopic findings of clear cell hepatocellular carcinoma. Biopsy specimen from left anterior chest wall revealed eccentric nucleoli with vacuolated foamy-to-clear cytoplasm that did not stain with hematoxylin and eosin ($\times 100$)

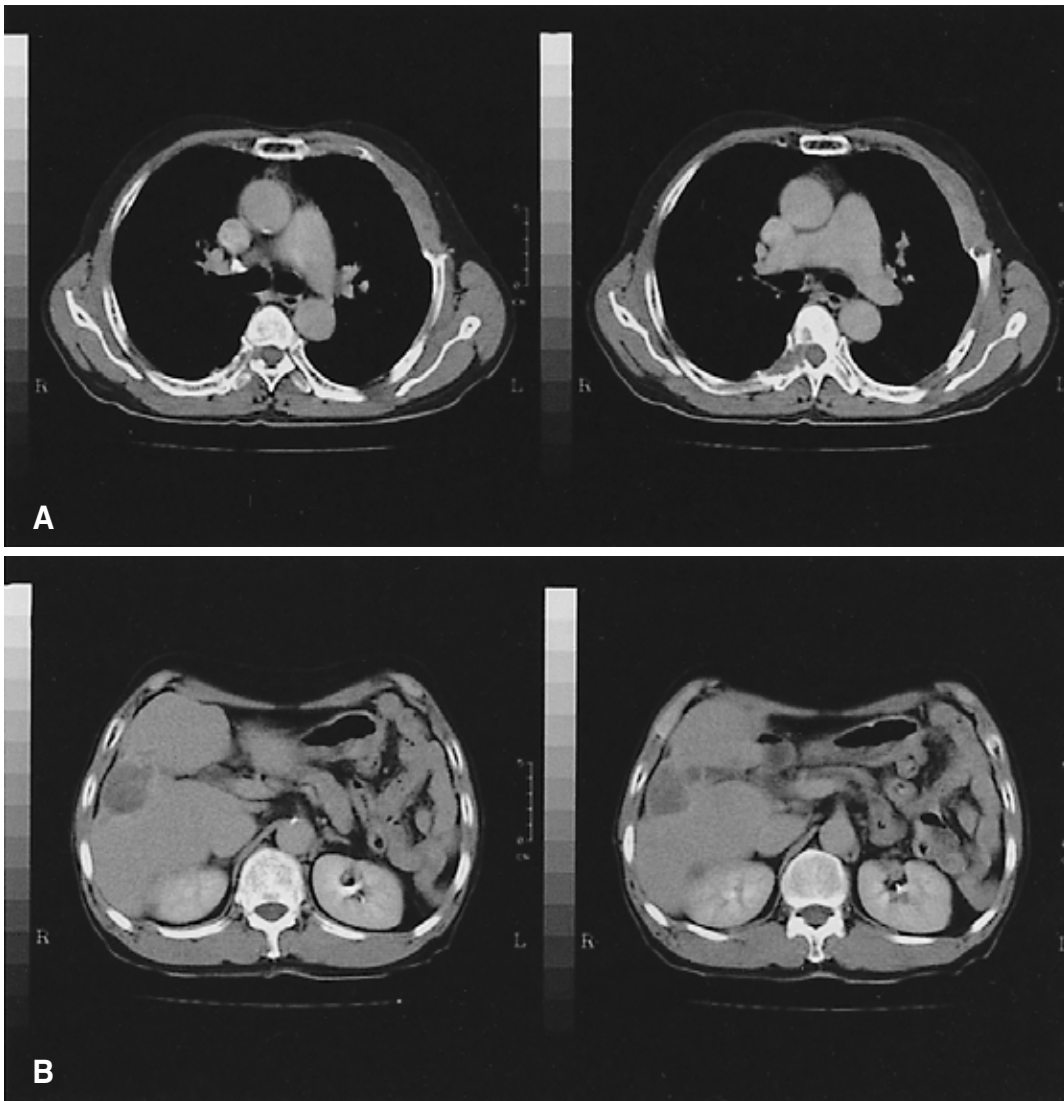


Figure 5. (A) Computed tomography showing a thickened left anterior chest wall but no mass lesion. (B) Computed tomography showing a further decreased hepatic mass lesion compared to previous images.

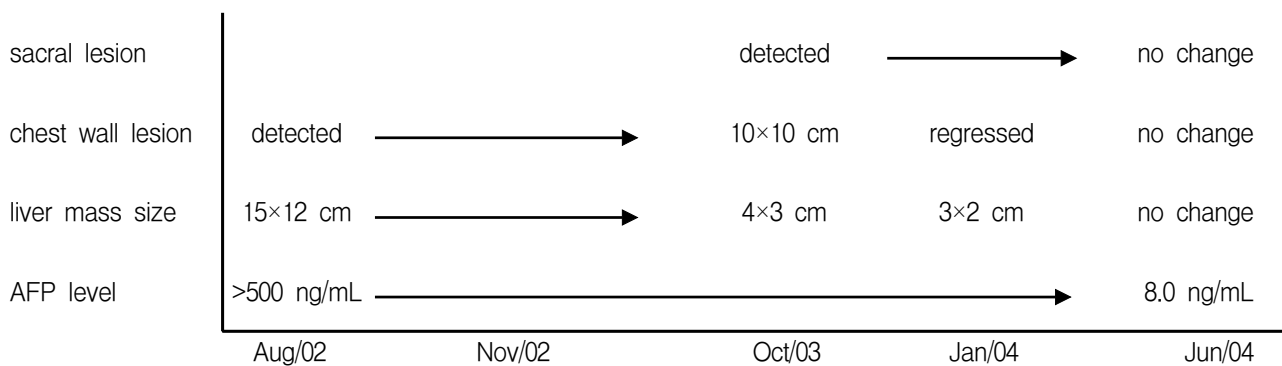


Figure 6. Schematic presentation on the course of serum AFP level, liver mass size, chest wall lesion, and sacral lesion during follow-up.

of HCC, in particular, is extremely rare. The mechanisms involved are poorly understood, but various associated conditions are proposed. Until recently the possible etiologies considered were rapid tumor growth³, massive gastrointestinal hemorrhage⁴, the use of herbal or unknown medicines⁵, abstinence from alcohol⁶, persistent fever⁷, the withdrawal of androgen⁸, surgery involving blood transfusion⁹, and spontaneous arterial thrombus¹⁰. If it were categorized by mechanisms, cessation of etiologic agents^{6, 8}, biologic blocking by infections^{7, 9}, infarction secondary to vascular insults^{3, 4, 10}, and herbal medicines⁵ would suffice. Recently, Abiru et al. reported that Interleukin 18 was elevated in HCC with spontaneous regression¹¹. They hypothesized that the spontaneous regression of HCC was associated with the cytotoxic activity of T cells and NK cells to the tumor cells. This proposed the spontaneous immune response hypothesis against tumor cell antigens. In our case, the patient stopped drinking alcohol after diagnosis (cessation of etiologic agents), but he did not take any other measures, such as herbal medicine. This is not a sufficient explanation for the regression because most cases of alcoholic HCC do not regress with only abstinence from alcohol.

To the author's knowledge, there were some reports of HCC with spontaneous regression, but the numbers of biopsy-proven cases have been rare. Clear cell hepatocellular carcinoma (CHCC) is a well-defined type of HCC in which a large number of tumor cells have clear cytoplasm that is not stained by hematoxylin and eosin stain¹². In our case, clear cell carcinoma was diagnosed by a biopsy of the chest wall mass. The origin of this mass may be in the liver, and it is supported by the existence of the huge liver mass on the CT scan and an elevated AFP serum level above 500 ng/mL¹³. In addition, there were no anatomical abnormalities with either kidney, the adrenal glands, or other intra-abdominal organs at the time of diagnosis and follow-up.

The clinical and pathological aspects of CHCC have been discussed for many years. It is generally accepted that CHCC has a favorable prognosis compared with that of conventional

non-CHCC^{14, 15}. The exact reasons and mechanisms for this better prognosis are not yet clear. Wu et al. stressed that the clear cells contained a substantial quantity of glycogens and lipids which were partially substituted for the usual cytoplasmic constituents in the ultrastructural observation¹⁴. In an attempt to explain the better outcome of clear cell HCC, an analogy was made between these tumor cells with clear cytoplasm and the clear cells which occurred in the intermediary stages of hepatocellular carcinogenesis in animals. Izumi et al. also reported that CHCC with excessive fat storage appeared to be of low-grade malignancy¹⁶. Yang et al. reported that clear cells of CHCC showed abundant storage of glycogen, variable numbers of fat vacuoles, and a marked reduction in the number and size of organelles, features suggestive of metabolic derangement¹⁷. They concluded, however, that the prognosis of CHCC was not significantly different from that of non-CHCC. The mechanism of glycogen storage and the development of fatty change in HCC are not well understood, but these may be caused by metabolic derangement or by impaired blood circulation. In fact, there have been associated case reports of hypoglycemia and hypercholesterolemia^{18, 19}. This metabolic derangement would be associated with spontaneous regression. The association of this phenomenon with the prognosis of CHCC, however, must be further validated.

Although the precise causes of the spontaneous regression of HCC remain to be further investigated, the interesting review of the case described above and additional literature suggests that intratumoral events may be involved. To date, these precise events have not been clarified. Therefore, further investigation is needed regarding the growth patterns of HCC.

REFERENCES

- 1) Okuda K, Ohtsuki T, Obata H, Tomimatsu M, Okazaki N, Hasegawa H, Nakajima Y, Ohnishi K. *Natural history of hepatocellular carcinoma and prognosis in relation to treatment: study*

- of 850 patients. *Cancer* 56:918-928, 1985
- 2) Cole WH. Efforts to explain spontaneous regression of cancer. *J Surg Oncol* 17:201-209, 1981
 - 3) Suzuki M, Okazaki N, Yoshino M, Yoshida T. Spontaneous regression of a hepatocellular carcinoma: a case report. *Hepato-gastroenterology* 36:160-163, 1989
 - 4) Tocci G, Conte A, Guarascio P, Visco G. Spontaneous remission of hepatocellular carcinoma after massive gastrointestinal haemorrhage. *BMJ* 300:641-642, 1990
 - 5) Lam KC, Ho JC, Yeung RT. Spontaneous regression of hepatocellular carcinoma: a case study. *Cancer* 50:332-336, 1982
 - 6) Gottfried EB, Steller R, Paronetto F, Lieber CS. Spontaneous regression of hepatocellular carcinoma. *Gastroenterology* 82:770-774, 1982
 - 7) Markovic S, Ferlan-Marolt V, Hlebanja Z. Spontaneous regression of hepatocellular carcinoma. *Am J Gastroenteol* 91:392-393, 1996
 - 8) McCaughan GW, Bilous MJ, Gallagher ND. Long-term survival with tumor regression in androgen-induced liver tumors. *Cancer* 56:2622-2626, 1985
 - 9) Sato Y, Fujiwara K, Nakagawa S, Kanishima S, Ohta Y, Oka Y, Hayashi S, Oka H. A case of spontaneous regression of hepatocellular carcinoma with bone metastasis. *Cancer* 56:667-671, 1985
 - 10) Imaoka S, Sasaki Y, Masutani S, Ishikawa O, Furukawa H, Kabuto T, Kameyama M, Ishiguro S, Hasegawa Y, Koyama H. Necrosis of hepatocellular carcinoma caused by spontaneously arising arterial thrombus. *Hepatogastroenterology* 41:359-362, 1994
 - 11) Abiru S, Kato Y, Hamasaki K, Nakata K, Eguchi K. Spontaneous regression of hepatocellular carcinoma associated with elevated levels of interleukin 18. *Am J Gastroenterol* 97:774-775, 2002
 - 12) Gibson JB, Sobin LH. Histologic typing of tumors of the liver, biliary tract, and pancreas. *International histologic classification of tumors. No. 20. World Health Organization, 1978*
 - 13) Bruix J, Sherman M, Llovet JM, Beaugrand M, Lencioni R, Burroughs AK, Christensen E, Pagliaro L, Colombo M, Rodes J. Clinical management of hepatocellular carcinoma: conclusions of the Barcelona-2000 EASL conference. *J Hepatol* 35:421-430, 2001
 - 14) Wu PC, Lai CL, Lam KC, Lok AS, Lim HJ. Clear cell carcinoma of liver: an ultrastructural study. *Cancer* 52:504-507, 1983
 - 15) Lai CL, Wu PC, Lam KC, Todd D. Histologic prognostic indicators in hepatocellular carcinoma. *Cancer* 44:1677-1683, 1979
 - 16) Izumi R, Shimizu K, li T, Yagi M, Matsui O, Nonomura A, Miyazaki I. Prognostic factors of hepatocellular carcinoma in patients undergoing hepatic resection. *Gastroenterology* 106:720-727, 1994
 - 17) Yang SH, Watanabe J, Nakashima O, Kojiro M. Clinicopathologic study on clear cell hepatocellular carcinoma. *Pathol Int* 46:503-509, 1996
 - 18) Sasaki K, Okuda S, Takahashi M, Sasaki M. Hepatic clear cell carcinoma associated with hypoglycemia and hypercholesterolemia. *Cancer* 47:820-822, 1981
 - 19) Ross JS, Kurian S. Clear cell hepatocellular carcinoma: sudden death from severe hypoglycemia. *Am J Gastroenterol* 80:188-194, 1985