Radiology Case Reports 15 (2020) 2059–2062

Available online at www.sciencedirect.com

ScienceDirect

journal homepage: www.elsevier.com/locate/radcr

Case Report

Brain paraneoplastic syndromes in a patient with mediastinal ganglioneuroma ☆,☆☆

Jose Migue Escudero-Fernandez, MD, Angel Sánchez-Montañez Garcia-Carpintero, MD, Ignacio Delgado-Alvarez, MD, Amparo Castellote-Alonso, MD, Elida Josefa Vázquez-Mendez, Dr*

Department of Pediatric Radiology, Hospital Universitari Vall d'Hebron, Passeig de la Vall d'Hebron 119-129 08035, Barcelona, Spain

ARTICLE INFO

Article history:
Received 29 May 2020
Revised 2 August 2020
Accepted 5 August 2020

Keywords:
Ganglioneuroma
Paraneoplastic neurologic syndrome
Opsoclonus-myoclonus-ataxia syndrome
Anti-N-Methyl-D-Aspartate Receptor encephalitis

ABSTRACT

Paraneoplastic neurologic syndromes are a rare and heterogeneous group of immune-mediated syndromes caused by underlying solid and nonsolid tumors. We present a case of 8-year-old female with long history of mild headaches and central instability who presented multiple poorly defined signal abnormalities at the subcortical white matter of both cerebral hemispheres and cerebellar atrophy on brain magnetic resonance imaging. Further studies revealed a posterior mediastinum ganglioneuroma derived from a mature ganglioneuroblastoma that was treated with surgery. Two paraneoplastic neurologic syndromes were considered: Anti-N-Methyl-D-Aspartate Receptor (NMDAR) encephalitis due to the resolution of subcortical signal abnormalities after mediastinal mass resection and opsoclonus-myoclonus-ataxia syndrome due to cerebellar atrophy. Intertnational guideline established the criteria for definite diagnosis of paraneoplastic neurologic syndromes and detection of onconeural antibodies is not mandatory for their diagnosis. Paraneoplastic neurologic syndromes may appear several years before the tumor is detected.

© 2020 The Authors. Published by Elsevier Inc. on behalf of University of Washington. This is an open access article under the CC BY-NC-ND license. (http://creativecommons.org/licenses/by-nc-nd/4.0/)

Introduction

Paraneoplastic neurologic syndromes (PNS) are a rare and heterogeneous group of immune-mediated syndromes caused by the underlying solid and nonsolid tumors. They can cause severe neurological morbidity and mortality and they may present to the neurologist several months or even years before the detection of the malignancy [1–3].

Case report

An 8-year-old female presented at the emergency department after a traumatic brain injury and long history of mild headaches and central instability.

Brain magnetic resonance imaging (MRI) showed several poorly defined signal abnormalities at the subcortical white matter of both cerebral hemispheres (Figs. 1a-c). There was

☆ Competing interest: The authors have no conflicts of interest to disclose.
☆☆ Disclosure: Written informed patient consent for publication has been obtained.

* Corresponding author.
E-mail address: jmescudero4@gmail.com (J.M. Escudero-Fernandez).

https://doi.org/10.1016/j.radcr.2020.08.010

1930-0433/© 2020 The Authors. Published by Elsevier Inc. on behalf of University of Washington. This is an open access article under the CC BY-NC-ND license. (http://creativecommons.org/licenses/by-nc-nd/4.0/)

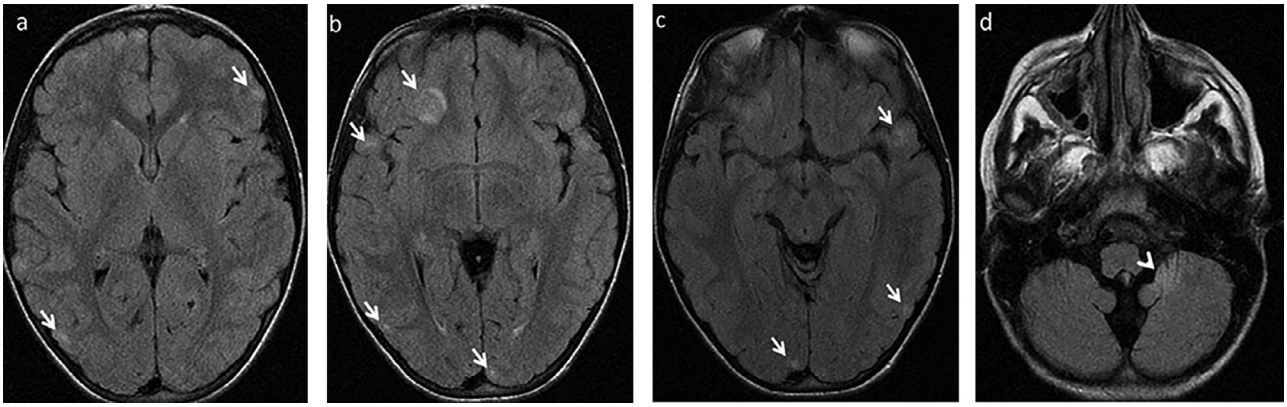

Fig. 1 – Axial FLAIR MRI images show multiple and poorly defined lesions with high signal intensity (arrows in a, b and c), specially the one at right frontobasal region. High signal intensity abnormality was also observed in left cerebellar hemisphere (arrowhead in d) Note also features of volume loss of both cerebellar hemispheres and vermis with enlargement of pontocerebellar cistern.

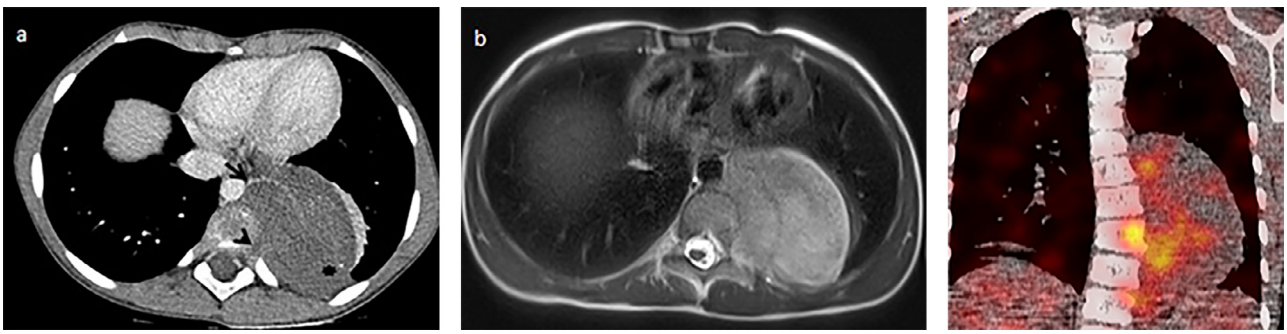

Fig. 2 – Axial nonenhanced CT (a), axial Fat-Saturation T2-WI (b) and coronal Iodine-131 metaiodobezylguanidine single photon emission computed tomography (c) show a voluminous mass at posterior mediastinum, from D6-D11. This mass partially encased descending thoracic aorta and several intercostal arteries (arrow in a) and presented a plastic growth through the T8-T9 and T9-T10 conjunction foramina (arrowhead in a). It was a heterogeneous, mainly hypodense mass with punctate calcifications (asterisk in a).

also volume loss of both cerebellar hemispheres and vermis with an asymmetric dilation of the IV ventricle, enlargement of pontocerebellar cistern and cerebellar folia. A small poorly defined signal abnormality in left cerebellar hemisphere was detected (Fig. 1d).

Small skin spots (confetti-like lesions) were also observed, so the brain lesions were initially considered cortical tubers and further studies were performed to diagnose tuberous sclerosis.

Chest CT depicted a voluminous heterogeneous mass of 56 × 64 × 86 mm, with punctate calcifications at posterior mediastinum (Fig. 2a). This mass partially encased descending thoracic aorta and several intercostal arteries and presented a plastic growth through the left T8-T9 and T9-T10 conjunction foramina. On chest MRI (Fig. 2b), this mass was iso-to-slightly hypointense on T1WI and hyperintense on T2WI, with mild low values in apparent diffusion coefficient (ADC) maps and mild heterogeneous enhancement on postcontrast T1WI sequences. There were no areas of cystic or hemorrhagic degeneration. Iodine-131 meta-iodobezylguanidine single photon emission computed tomography showed mild uptake foci inside the mass (Fig. 2c).

Urinary levels of homovanillic acid (Uri-4-OH-metoxifenilacetat) and vanillylmandelic acid (Uri-4-OH-metoximandelat) were 18 mg/g creatinine (normal value for her age group <12 mg/g creatinine) and 24 mg/g creatinine (normal value for her age group <15 mg/g creatinine), respectively.

Patient underwent surgery and microscopic examination revealed the characteristic features of ganglioneuroma derived from a mature ganglioneuroblastoma (Fig 3).

Eleven months after the resection, subcortical signal abnormalities faded out on brain MRI (Figs. 4a and b). Volume loss of cerebellar hemispheres and vermis persisted, along with mild high signal on fluid attenuated inversion recovery (FLAIR) at left cerebellar hemisphere (Fig. 4c).

Two PNS were present in this patient. The temporal relationship between the resection of the mediastinal ganglioneuroma and the disappearance of subcortical lesions on brain MRI made us considered the diagnosis of Anti-N-Methyl-D-Aspartate encephalitis, and the loss of cerebellar volume in a patient with persistent ataxia and instability of central origin was a part of opsoclonus-myoclonus-ataxia syndrome (OMAS).

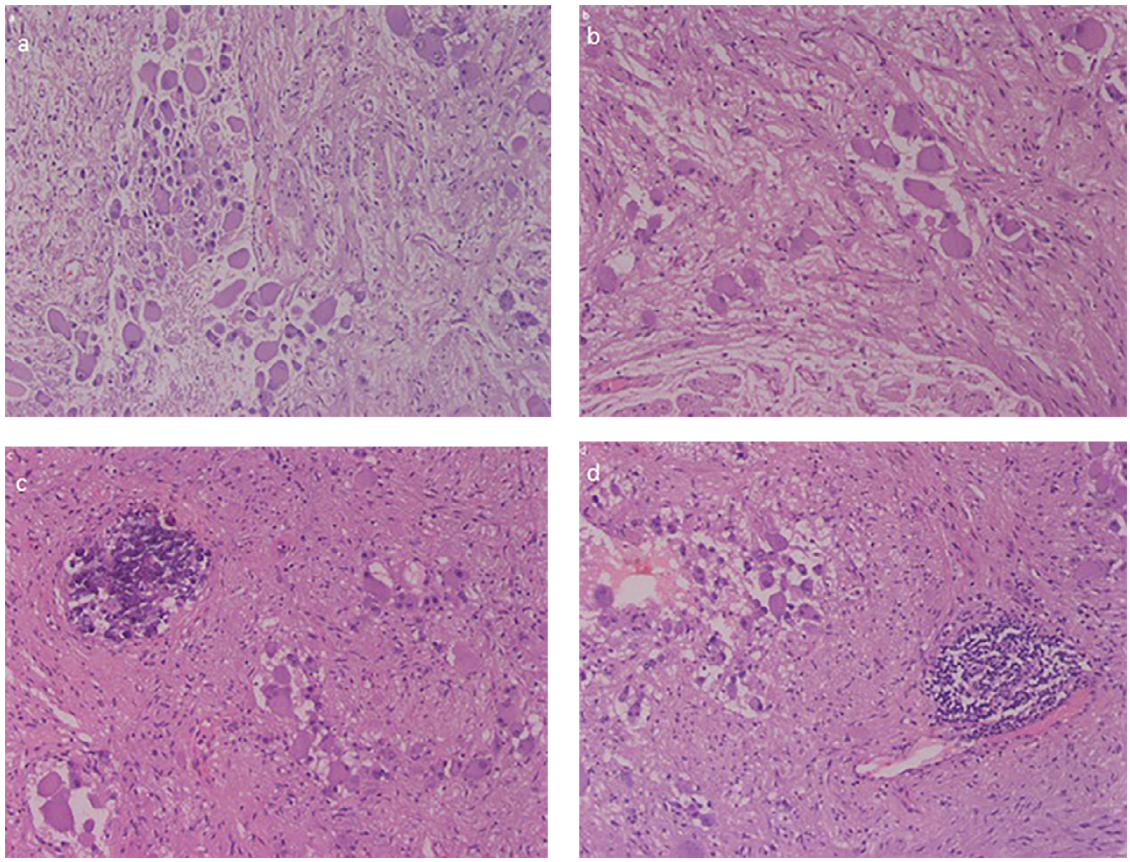

Fig. 3 – Ganglioneuroma. x10 photomicrographs, hematoxylin-eosin stain demonstrates geographic bundles of spindle cells of neural aspect (neuroblasts) in different stages of maturation (arrows in a), mature ganglion cells within a myxoid fibrovascular stroma (arrows in b). Microcalcifications (asterisk in c) and lymphoid aggregates (asterisks in d) were also found. Neuromatous cells expressed S100 protein.

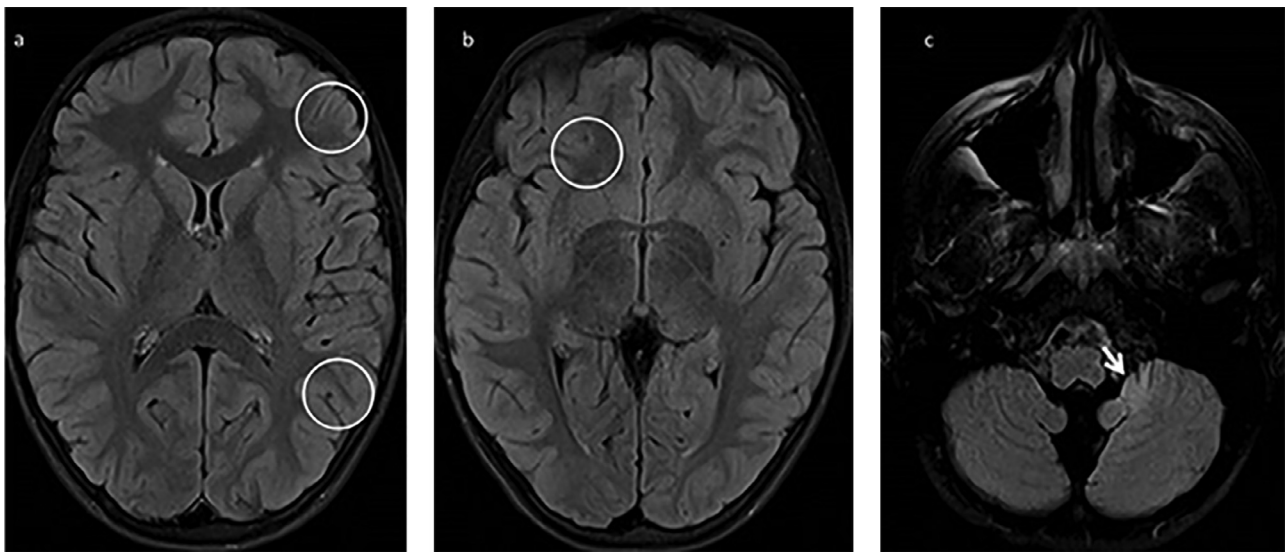

Fig. 4 – Axial FLAIR MRI images eleven months after the surgical resection demonstrates vanishing of subcortical lesions (circles in a and b). High signal abnormality and volume loss of both cerebellar hemispheres and vermis were similar to those observed in presurgical brain MRI (b)

Discussion

Ganglioneuromas represent the most common tumor arising in the posterior mediastinum in pediatric population [1] and they are composed of ganglion cells, Schwann cells without mitotic figures, and myxoid fibrovascular stroma without necrosis [1]. Ganglioneuromas may occurred de novo or arise from maturing neuroblastomas and ganglioneuroblastomas that share a common histogenic lineage [1].

Patients with ganglioneuroma usually are younger than 20 years old (median of 7 years old), with a slightly female predominance. Most patients are asymptomatic, although overproduction of catecholamines and metanephrines can cause a significant elevation in blood pressure and flushing and overproduction of vasoactive intestinal peptide can cause diarrhea [1]. Ganglioneuromas are large well-circumscribed encapsulated masses with punctate calcifications at computed tomography and slightly hyperintense on T2WI, with heterogeneous enhancement and mild restriction on diffusion sequences at MRI [1].

In our case, ganglioneuroma arise from mature ganglioneuroblastoma and showed partially encasement of descending thoracic aorta and several intercostal arteries and plastic growth through conjunction foramina. These characteristics of aggressiveness made it more likely to be associated with PNS.

PNS are rare and heterogeneous group of disorders present in patients with underlying tumors [1–3]. Onconeural antibodies against intracellular antigens are just an epiphenomenon since the real injury is secondary to cytotoxic T lymphocytes. On the contrary, in nonparaneoplastic encephalitis, antibodies against superficial antigens are directly responsible for the neurological injuries [1–3]. Sensitivity and specificity of onconeural antibodies is very low, less than 30% in some studies [2], so PNS may occur without onconeural antibodies.

In 2002, Paraneoplastic Neurological Syndrome Euronetwork elaborated a list of classical PNS that includes encephalomyelitis, limbic encephalitis, subacute cerebellar degeneration and OMAS and a list of characterized onconeural antibodies that includes anti-Hu, Yo, CV2, Ri, Ma2, and amphiphysin [4]. The criteria for definite PNS includes the presence of a classical syndrome and cancer that appears within 5 years of the diagnosis of the neurological disorder or a nonclassical syndrome that resolves or significantly improves after cancer treatment [4].

An interval shorter than 5 years between the diagnosis of PNS and detection of cancer should be considered in children due to the nature evolution of tumors most frequently involved in these patients, neuroblastoma, teratoma, and Hodgkin's lymphoma [1]. It is unlikely that cancer appears outside 3 years from the diagnosis of the neurological disorder [1].

Encephalomyelitis and limbic encephalitis are classical PNS associated with several characterized onconeural antibodies, but other nonclassical forms of encephalitis have been described in recent years. NMDAR encephalitis has been increasingly reported in children since first cases in 2007 [5,6]. NMDA-receptor antibodies have been detected in serum against NR1 and NR2 subunits located in postsynapsis dendrites. Children present neuropsychiatric abnormalities, including behavioral or personality change, sleep dysfunction, dyskinesia or dystonia, autonomic instability, and speech reduction. On MRI, there are transient signal abnormalities on FLAIR or even patchy areas of contrast-enhancement in cortical and subcortical regions, limbic areas, basal ganglia, brainstem, cerebellum, and, sometimes, white matter. Symptomatic patients are treated with corticosteroids, intravenous immunoglobulin and/or plasma exchange [5,6]. In our case, high signal abnormalities in subcortical white matter of both cerebral hemispheres resolved after resection of ganglioneuroma, so definite PNS was confirmed.

OMAS, also known as Kinsbourne syndrome, is the most common PNS in the literature [7]. Fifty percent of OMAS are associated with neuroblastoma, but they have also been described in children with ganglioneuromas and hepatoblastomas [3] and it is associated with anti-Hu and anti-Ri antibodies that damage inhibitory Purkinje cells and granular neurons in the dorsal vermis [7]. Patients may present with staggering and falling but they may develop myoclonies, drooling, and hypotonia. On MRI, signal abnormalities on vermis, flocculo-nodular lobes and dorsal midbrain, are reversible after treatment, although residual long-term neurocognitive deficits secondary to vermis atrophy and loss of axonal integrity in middle cerebellar tracts [6]. Symptoms and imaging findings in our patient met the criteria for definite PNS [3]. Subacute cerebellar degeneration was also considered in the differential diagnosis, but it usually presents as a severe cerebellar syndrome with rapid course and without cerebellar atrophy. It is also more common in lung carcinoma whereas OMAS has been widely recognized in patients with neuroblastoma.

In conclusion, PNS should be considered in the differential diagnosis of patients with neurological syndromes with or without onconeural antibodies, and they may appear several months or even years before the detection of the underlying tumor.

REFERENCES

[1] Alavi S. Paraneoplastic neurologic syndromes in children: a review article. Iran J Child Neurol 2013;7(3):6–14.
[2] Pelosof LC, Gerber DE. Paraneoplastic syndromes: an approach to diagnosis and treatment. Mayo Clin Proc 2010;85(9):838–54.
[3] Dalmau J, Lancaster E, Martinez-Hernandez E, et al. Clinical experience and laboratory investigations in patients with anti-NMDAR encephalitis. Lancet Neurol 2011;10(1):63–74.
[4] Graus F, Delattre JY, Antoine JC, et al. Recommended diagnostic criteria for paraneoplastic neurological syndromes. J Neurol Neurosurg Psychiatry 2004;75:1135–40.
[5] Florance NR, Davis RL, Lam C, et al. Anti–N-Methyl-D-Aspartate Receptor (NMDAR) encephalitis in children and adolescents. Ann Neurol 2009;66(1):11–18.
[6] Azizyan A, Albrektson JR, Maya MM, et al. Anti-NMDA encephalitis: an uncommon, autoimmune mediated form of encephalitis. J Radiol Case Rep 2014;31(8):1–6.
[7] Fancellu R, Corsini E, Bernardi G, et al. Paraneoplastic cerebellar ataxia associated with anti-Hu antibodies and benign ganglioneuroma. Funct neurol 2014;29(4):277–80.