

15–20

Heterotopic ossification in cervical disc arthroplasty: Is it clinically relevant?

Authors Giuseppe M Barbagallo, Leonardo A Corbino, Giuseppe Olindo, Vincenzo Albanese

Institution Department of Neurosurgery, Azienda Ospedaliero-Universitaria “Policlinico-Vittorio Emanuele”, Catania, Italy

Methods evaluation and class of evidence (CoE)

Methodological principle:

Study design:

Prospective cohort

Retrospective cohort

Case-control

Case series

Methods

Patients at similar point in course of treatment

Follow-up \geq 85%

Similarity of treatment protocols for patient groups

Patients followed for long enough for outcomes to occur

Control for extraneous risk factors*

Evidence class:

III

* Authors must provide a description of robust baseline characteristics, and control for those that are potential prognostic factors.

The definition of the different classes of evidence is available on page 83.

ABSTRACT

Study design: Retrospective cohort study.

Objective: To analyze the presence and clinical relevance of heterotopic ossification (HO) at 3 years mean follow-up.

Methods: Thirty patients suffering from cervical radiculopathy and/or myelopathy treated with anterior disc replacement (ADR) were studied. HO was classified using the McAfee grading system. Range of motion was measured from flexion and extension x-rays. Short-form 36 and neck disability index (NDI) assessed functional outcome.

Results: Forty-five prostheses were implanted in 30 patients with cervical radiculopathy and/or myelopathy, mean age 40.9 years. Nineteen patients received 1 level and 11 patients received multilevel disc replacement. The incidence rate of HO was 42.2% (19 levels). Segmental range of motion was $\geq 3^\circ$ in 93.8% of patients with HO. There was no significant difference in functional scores between those who did and those who did not develop HO. Males tended to develop HO more frequently than females, though this was not statistically significant. The indication for surgery (soft disc hernia or spondylosis) was not associated with the formation of HO.

Conclusions: Functional improvement is maintained despite the presence of HO following cervical disc arthroplasty. Indications for arthroplasty should not be halted by the risk of HO.

See web appendix at www.aospine.org/ebcj

No financial support has been or will be received for this study.

Notation of device status. Prodisc-C and Prestige LP cervical artificial discs: FDA approved

STUDY RATIONALE AND CONTEXT

Maintainance of motion following arthroplasty can be hindered by the development of heterotopic ossification (HO), whose causes remain uncertain [1, 2, 3–5]. Whether the formation of HO following cervical disc arthroplasty is of clinical or functional importance is also unknown. The aims of this study are to investigate the rate of HO at a longer follow-up (mean 3 years), to determine if the presence of HO negatively affects functional outcome and to identify factors that may precipitate the formation of HO following cervical disc arthroplasty.

CLINICAL QUESTIONS

1. What is the incidence of HO following cervical arthroplasty?
2. Does the development of HO negatively influence the clinical outcome in patients receiving arthroplasty?
3. Are there factors that influence the formation of HO following cervical arthroplasty?

METHODS

Study design: Retrospective cohort study.

Inclusion criteria: Patients suffering from radiculopathy, myelopathy or myeloradiculopathy secondary to soft disc hernia and/or mild degree spondylosis operated between October 2004 and December 2006.

Exclusion criteria: Patients with prior surgery at the instrumented level were excluded.

Patient population and interventions (Fig 1)

- Thirty-nine patients suffering from cervical radiculopathy and/or myelopathy treated with anterior disc replacement (ADR) were selected. Nine patients were excluded from this analysis because of insufficient outcome data at different time intervals (n=7) or were not available for follow-up (n=2).

Outcomes and analysis

- Evidence of HO using the McAfee grading system [6] (**Table 1**).
- Prostheses range of motion (ROM). ROM was calculated by using two lines parallel to the Prodisc-C keels, or to the endplates of the Prestige LP, and measuring the intervening angle in flexion and extension on lateral radiographs. Lordosis was assigned a negative value and kyphosis a positive one; the difference between the two values gave the final ROM. ROM was measured three times per level and a mean value was obtained.
- CT scan on patients with grade two or higher HO to assess localization of HO.
- Short-form 36 (SF-36) and neck disability index (NDI). A comparison of scores was made between those who developed HO and those who did not using a two-sided Student t-test.
- All images were independently reviewed by both a radiologist and a neurosurgeon not directly involved in the surgical procedures.

RESULTS

- Forty-five disc prostheses (seven Prestige-LP and 38 Prodisc-C) were implanted in 30 patients (18 males) ranging in age from 28–63 years (mean age 40.9). The underlying disease included radiculopathy (n=13), myelopathy (n=4) or myeloradiculopathy (n=13), secondary to soft-disc hernia (n=17), spondylosis (n=8) or a combination of disc hernia and spondylosis (n=5). Nineteen patients received one-level disc replacement, seven patients received two-level and four patients received three level disc replacement. The following distribution of prostheses/level was recorded: C3–4:5; C4–5:4; C5–6:23; C6–7:13 (**Table 2**).
- The incidence rate of HO using the number of prostheses as the denominator was 42.2% (19 levels in 16 patients, **Fig 6**). The risk of a patient developing HO after receiving one or more prostheses was 53.3% (16/30).
- Ten patients showed progressive ossification over time: in six patients *de novo* HO was demonstrated at 23–46 months (mean 33.3) postoperatively (**Figs 2, 3**).
- Among the 16 patients with HO, 15 (93.8%) demonstrated a range of motion $\geq 3^\circ$ (**Fig 4**).
- Comparison of pre- and postoperative SF-36 and NDI scores revealed functional improvement from baseline to follow-up at 3, 6, 12, 18, 24, and 36 months. There was no significant difference in functional scores between those who did and those who did not develop HO, $P > .05$ (**Fig 7**).
- Risks and relative risks by factor related to patient characteristics associated with HO formation were analyzed: males tended to develop HO more than females (twice as likely), though this did not reach statistical significance (**Table 3**).
- No patients required revision surgery for adjacent segment disease or persisting/recurrent symptoms.

Fig 1 Patient population and intervention

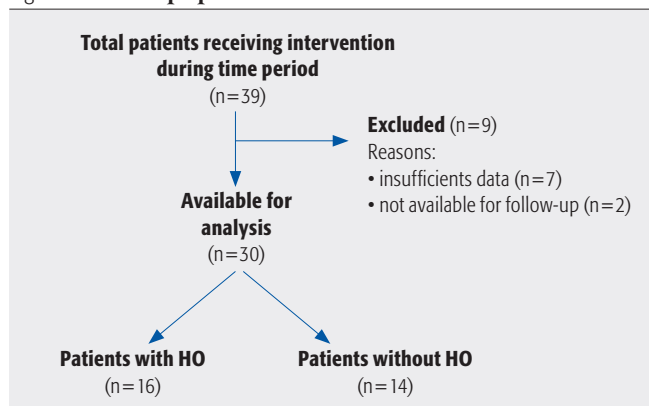


Table 1 McAfee grading of heterotopic ossification (HO)[6]

Grade 0	Absence of HO
Grade 1	Presence of HO in front of vertebral body but not in the anatomic disc space
Grade 2	Presence of HO in the disc space, possibly affecting the prosthesis's function
Grade 3	Bridging HO with prosthesis's motion still preserved
Grade 4	Complete fusion of the segment with absence of motion in flexion/extension

Table 2 Patient characteristics

Characteristic	N=30
Age, years, mean (range)	40.9 (28–63)
Male, n (%)	18 (60)
Soft disc hernia, n (%)	17 (57)
Spondylosis, n (%)	8 (27)
Soft disc hernia & spondylosis, n (%)	5 (17)
Radiculopathy, n (%)	13 (43)
Myelopathy, n (%)	4 (13)
Myeloradiculopathy, n (%)	13 (43)
No. of levels treated	45
1 level	19 (patients)
2 levels	7 (patients)
3 levels	4 (patients)
Levels implanted	
C3–4	5
C4–5	4
C5–6	23
C6–7	13

Table 3 The risk (%) and unadjusted relative risk (RR) of HO by patient characteristics

	n/N (%)	RR	95% CI	P-value
Sex				
Female	4/12 (33.3)	1.0		
Male	12/18 (66.7)	2.0	0.8, 4.7	.13
Indication				
Soft disc hernia	8/17 (47.1)	1.0		
Spondylosis	4/8 (50.0)	1.1	0.4, 2.5	1.0
Soft disc hernia & spondylosis	3/5 (60.0)	1.3	0.5, 3.1	1.0
Neurological involvement				
Myelopathy	2/4 (50.0)	1.0		
Radiculopathy	7/13 (53.8)	1.1	0.4, 3.2	1.0
Myeloradiculopathy	7/13 (53.8)	1.1	0.4, 3.2	1.0

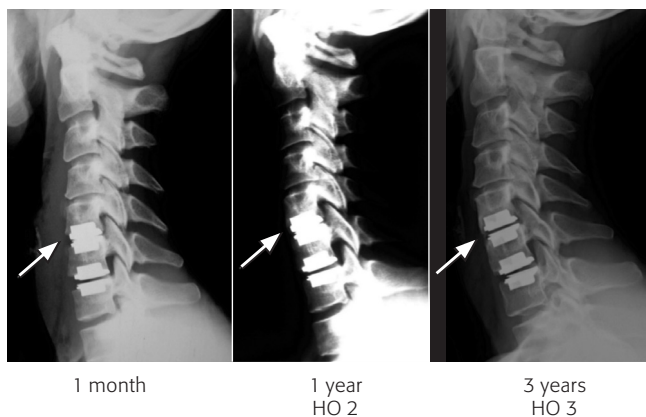
DISCUSSION

- Our rate of grade two and three HO (42.2%) is consistent with that previously reported [7]. It is higher than in other series [8, 9] but lower than Sola's et al [10].
- HO is prevalent on the anterolateral surface of vertebral bodies (**Fig 5**).
- HO does not influence the clinical and functional outcome.
- Strengths: This study reports 3 years mean follow-up data, to date the longest available. For all included patients complete follow-up data are available. Furthermore, we have shown that a delayed progression, or *de novo* onset, of HO is possible.
- Limitations: This study was not conducted prospectively and is based on a relatively small albeit consecutive sample size. Lack of potential prognostic factors available for analysis and a 77% follow-up rate are further limitations.
- A longer follow-up is necessary to assess whether arthroplasty can reach the goal of maintaining motion and if development of high-grade HO at the target level infers an increased risk of adjacent segment degeneration.

CONCLUSIONS

- Clinical and functional improvement following cervical disc arthroplasty is maintained despite the presence of HO.
- The indication for surgery (soft-disc herniation or "hard-disc" spondylosis) is not associated with the formation of HO.

Fig 2 Double-level arthroplasty with Prodisc-C at C5–6 and C6–7. Absence of HO at 1 month after surgery (left), presence of grade two HO 1 year postoperatively (middle) and of grade three HO (right) 3 years postoperatively, respectively.



- Indications for arthroplasty are not affected by the risk of HO.
- Preventative measures such as prophylactic non-steroidal medications, local application of bone wax or intentional early range of motion measures were not routinely utilized in our study. While these are interesting factors, actual prospective studies will be needed to compare their effect. Our experiences may serve as a valuable baseline comparison.

Fig 3 Double-level arthroplasty with Prodisc-C at C5–6 and C6–7. Note the progression of HO at the C4–5 disc space at 1 month (left), 12 (middle) and 48 (right) months, respectively, postoperatively (arrow).

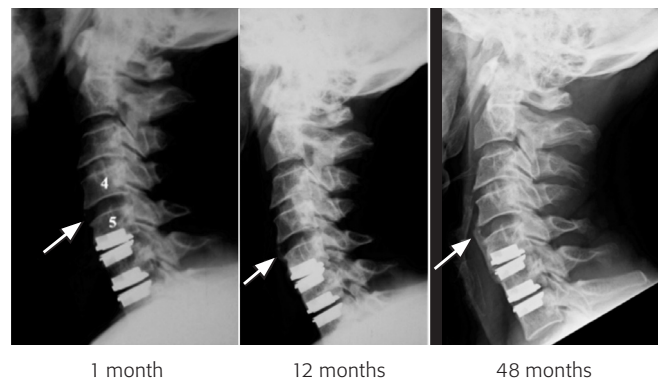


Fig 4 Flexion and extension x-rays (same patient as in Fig 3) showing mobile disc prostheses at 48-months follow-up despite the presence of heterotopic ossification.

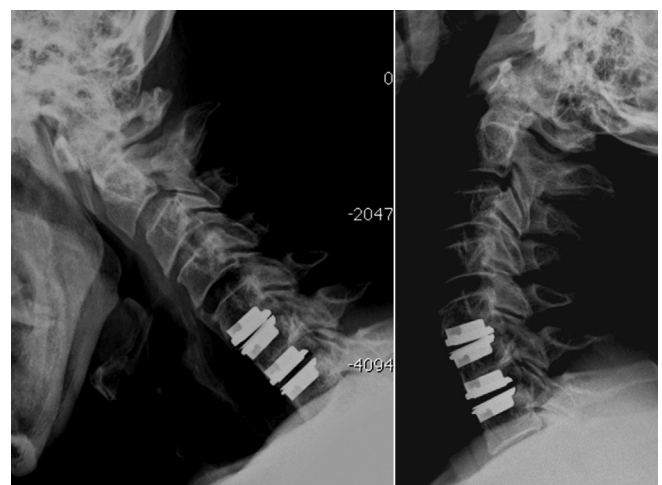

Fig 5a–b Same case as in Fig 4. Axial CT scan showing the presence of laterally sited HO (arrows) at C4–5 level (a) and at C6–7 level (b)

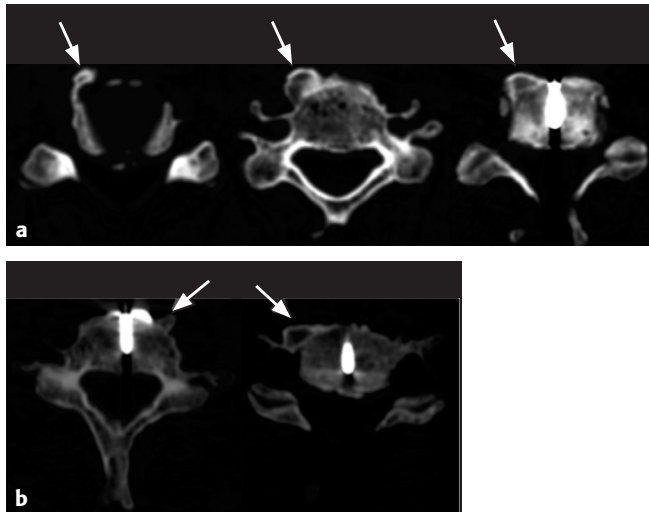


Fig 6 Number of ossified levels and stratification for McAfee ossification grades (HO: heterotopic ossification)

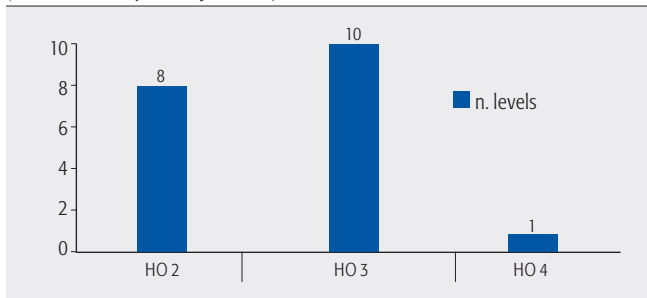
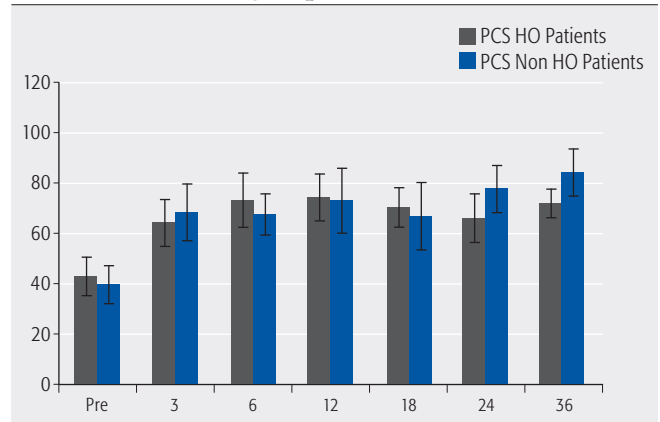
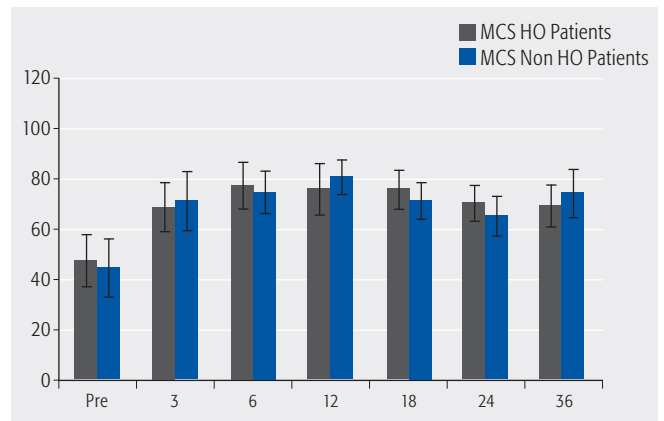


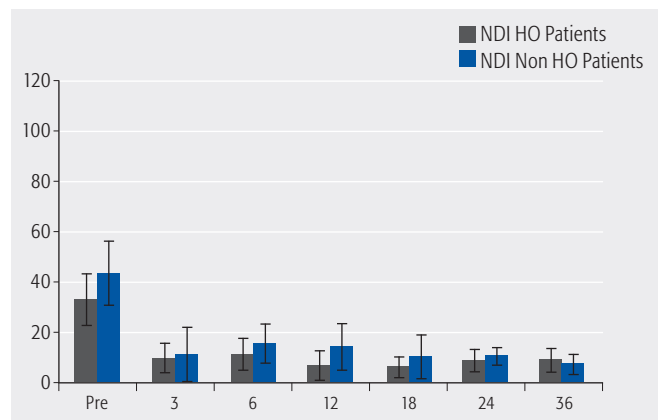
Fig 7 Differences of pre- and postoperative functional outcome in the two groups



SF-36 Physical component mean score (PCS)



SF-36 Mental component mean score (MCS)



Neck disability index (NDI) mean scores

REFERENCES

1. **Bartels RHMA, Donk R** (2005) Fusion around cervical disc prosthesis: case report. *Neurosurgery*; 57:194.
2. **Heller JG, Tortolani PJ, Park AE, et al** (2003) Computed Tomography (CT) scan assessment of paravertebral bone after total cervical disc replacement: prevalence, temporal relationships, and the effects of NSAIDs. *Proc Cervical Spine Res Soc*. Read at the Annual Meeting of the Cervical Spine Research Society, European Section, Jun 19-20; Barcelona, Spain
3. **Parkinson J, Sekhon LHS** (2005) Cervical arthroplasty complicated by delayed spontaneous fusion. *J Neurosurg Spine*; 2:377–380.
4. **Pickett GE, Sekhon LHS, Sears WR, et al** (2006) Complications with cervical arthroplasty. *J Neurosurg Spine*; 4:98–105.
5. **Pimenta L, McAfee PC, Cappuccino A** (2004) Clinical experience with the new artificial cervical PCM (Cervitech) disc. *Spine J*; 4(suppl 6):315–321.
6. **McAfee PC, Cunningham BW, Devine J, et al** (2003) Classification of heterotopic ossification (HO) in artificial disk replacement. *J Spinal Disord Tech*; 16:384–389.
7. **Mehren C, Suchomel P, Grochulla F, et al** (2006) Heterotopic ossification in total cervical artificial disc replacement. *Spine*; 31:2802–2806.
8. **Heidecke V, Burkert W, Brucke M, et al** (2008) Intervertebral disc replacement for cervical degenerative disease—clinical results and functional outcome at two years in patients implanted with the Bryan cervical disc prosthesis. *Acta Neurochir*; 150:453–459.
9. **Leung C, Casey ATH, Goffin J, et al** (2005) Clinical significance of heterotopic ossification in cervical disc replacement: a prospective multi center clinical trial. *Neurosurgery*; 57:759–763.
10. **Sola S, Hebecker R, Knoop M, et al** (2005) Bryan cervical disc prosthesis—three years follow-up. *Eur Spine J*; 14 (suppl 1):38.

EDITORIAL STAFF PERSPECTIVES

This is a CoE III prognostic study.

Disc replacement offers a new interventional option and long-term data on the potential complications to artificial disc replacement compared with fusion are very much needed. This prospective study's contribution to the literature regarding heterotopic ossification (HO) following cervical ar-

throplasty is appreciated. As the authors note, the causes of HO in disc arthroplasty remain unclear and are probably multifactorial.

HO frequency: *The authors report a HO rate of 42% following artificial disc replacement in 32 patients, a higher overall rate than is reported in most other studies. HO rates in the May 2008 EBSS Special Edition on cervical arthroplasty were summarized as follows: There were no HO cases reported in two RCTs, with follow-up of 24 months in one study and other being a preliminary report with most patients having only 12-months follow-up. HO was, however, common in two case series with one reporting an overall 18% rate or 7% cases when restricted to grades III or IV. The other series of patients with 1, 2, or 3 level disease reported that 8% of segments had grade I, 39% of segments had grade II, 10% had HO leading to restricted movement and 9% experienced spontaneous fusion.*

There are several factors which may partially explain discrepancies in HO rates across studies, aside from differences in length of follow-up. It is possible that increased attention to radiographic detail may go hand in hand with increased reporting. Grading the severity of HO is not an exact science. There is some subjectivity which may translate into difficulty in distinguishing between adjacent grades (eg, between grades 2 and 3) and overlap in classification. The grading of HO has so far not been subjected to inter- and intra-observer reliability evaluation and is not known to correlate with any health-related quality of life (HrQoL) outcomes measures.

Study specifications and protocols: *Use of structured measures and protocols in a prospective study, which are consistently applied to all patients, is important to decrease study bias. While the authors suggest that structured protocols were used, no details were provided. Reporting detail about protocols assists in determining the extent to which various factors may or may not have influenced the results. For studies of HO, important protocol details should include whether or not bone waxing was done at the osteotomy site as well as specifics for radiographic measurements and use of antiinflammatory medications. Description of post-operative rehabilitation is also important. It is unclear whether early initiation of range of motion creates an inflammatory response which contributes to HO formation or if it facilitates functional outcome.*

Strengths: *The use of validated outcomes measures (NDI and SF-36) is commendable as is the authors' acknowledgment of small sample size and a relatively low follow-up rate (77%) as study limitations.*