

# The Efficacy of Preoperative Endoscopic Retrograde Cholangiopancreatography in the Detection and Clearance of Choledocholithiasis

Edward W. Taylor, MD, Ujwala Rajgopal, MD, Jaco Festekjian, MD

## ABSTRACT

**Background and Objectives:** Endoscopic retrograde cholangiopancreatography has been reported to have a high success rate in the detection and treatment of choledocholithiasis. Although there is growing enthusiasm for laparoscopic common bile duct clearance, many patients who present with gallbladder disease and suspected choledocholithiasis have endoscopic retrograde cholangiopancreatography performed with choledocholithiasis cleared if detected. These patients are then referred for laparoscopic cholecystectomy. The purpose of this study is to determine the efficacy of preoperative endoscopic retrograde cholangiopancreatography in the diagnosis and clearance of bile duct stones at our institution.

**Methods:** A retrospective review was performed of all patients at this institution who underwent preoperative endoscopic retrograde cholangiopancreatography for suspected choledocholithiasis followed by laparoscopic cholecystectomy from January 1997 through July 1998.

**Results:** Common bile duct stones were detected endoscopically in 12 of 17 (71%) patients. We found serum bilirubin level to be the best predictor of choledocholithiasis. In 12 of 12 procedures, the endoscopist performed an endoscopic sphincterotomy with stone extraction and reported a fully cleared common bile duct. Intraoperative cholangiogram performed during subsequent cholecystectomy revealed choledocholithiasis in 4 of these 12 patients. Laparoscopic techniques successfully cleared the choledocholithiasis in 3 of these patients with open techniques necessary in the fourth.

**Conclusions:** Our data suggests that even after presumed successful endoscopic clearance of the bile duct stones, many patients (33% in our series) still have choledocholithiasis present at the time of cholecystectomy.

We recommend intraoperative cholangiography at the time of cholecystectomy even after presumed successful endoscopic retrograde cholangiopancreatography with further intervention, preferably laparoscopic, to clear the choledocholithiasis as deemed necessary.

**Key Words:** Choledocholithiasis, Preoperative endoscopic retrograde cholangiopancreatography, Laparoscopic common bile duct clearance.

## INTRODUCTION

Although laparoscopic cholecystectomy (LC) has become the standard for gallbladder removal, there is still debate as to the most effective and efficient method of clearing choledocholithiasis. One frequent clinical scenario in which the clinician must decide the most appropriate treatment methodology is the patient with preoperatively suspected choledocholithiasis. Options include open common bile duct (CBD) exploration, laparoscopic CBD clearance with postoperative endoscopic retrograde cholangiopancreatography (ERCP) or open CBD exploration reserved for laparoscopic failures. Another approach is preoperative ERCP followed by LC. Because of the higher morbidity associated with open cholecystectomy compared to LC, open CBD exploration as a first-line therapy for patients with suspected choledocholithiasis has fallen out of favor. As surgeons have improved their laparoscopic skills and laparoscopic technology continues to advance, there has been a steady increase in the number of series promoting laparoscopic CBD techniques as the initial procedure of choice in patients suspected of having CBD stones.<sup>1-9</sup> In this treatment plan, if laparoscopic techniques fail, the surgeon must either convert to open CBD exploration with increased morbidity or rely on postoperative ERCP. Many centers do not have the laparoscopic technology or expertise to reliably clear CBD stones. In other centers, timely postoperative ERCP is difficult to obtain from a logistical standpoint. Thus, many institutions still rely on preoperative ERCP in cases of suspected CBD stones.<sup>10,11</sup>

Department of Surgery, Kern Medical Center, Bakersfield, California, USA (all authors).

Address reprint request to: Edward W. Taylor, MD, FACS, Department of Surgery, Kern Medical Center, 1830 Flower Street, Bakersfield, CA 93305, USA. Telephone: (661) 326-2275, Fax: (661) 326-2282.

© 2000 by JLSLS, *Journal of the Society of Laparoendoscopic Surgeons*. Published by the Society of Laparoendoscopic Surgeons, Inc.

Advocates of preoperative ERCP are many.<sup>12-22</sup> However, a liberal use of preoperative ERCP based on risk factors for choledocholithiasis can result in a high number of nontherapeutic ERCPs (25-76%).<sup>11-13,18,21-27</sup> Well established risk factors for CBD stones include age, cholangitis, jaundice, elevated liver function tests (LFTs), gallstone pancreatitis, a prior history of CBD stones, and ultrasonography (US) findings of choledocholithiasis or a dilated CBD.<sup>28,29</sup> Recently, much effort has been expended to better define the clinical risk factors that most accurately predict CBD stones in order to avoid unnecessary ERCPs.<sup>13,30-34</sup> The results have not been consistent. Some have found US findings necessary to develop a good predictive model,<sup>11,35,36</sup> while others have found US findings to be an unreliable predictor of CBD stones.<sup>37</sup> Several series conclude that only a combination of elevated LFTs and US findings will most accurately predict CBD stones.<sup>13,28,32</sup>

In our institution, we do not have postoperative ERCP readily available, and we are still in the process of developing our laparoscopic CBD expertise. Thus, patients whom we feel are at high risk for CBD stones are subjected to preoperative ERCP with endoscopic sphincterotomy and stone extraction, as indicated, followed by LC. In this series, we analyze the accuracy of our clinical risk factors in predicting CBD stones, the success of preoperative ERCP at clearing the CBD, and, if CBD stones were left behind after ERCP (detected on intraoperative cholangiography), whether we were able to clear them laparoscopically.

## MATERIALS AND METHODS

The medical records of all patients at Kern Medical Center with gallbladder disease who had preoperative ERCP for suspected choledocholithiasis from January 1997 through July 1998 were reviewed. Each patient's age, sex, clinical presentation including laboratory values and US findings were recorded. The specific findings that led the physician to suspect choledocholithiasis and prompted preoperative ERCP were noted. The ERCP procedure details, findings and conclusions were examined, as were the intraoperative finding and procedure details. We recorded whether CBD stones were found during ERCP and, if present, how these stones were cleared. We also noted whether the endoscopist felt CBD stone clearance was complete or not. Any complication related to ERCP was noted. All patients had LC performed within 24 hours of ERCP. Intraoperative cholangiogram findings were analyzed as to the presence of CBD stones and, if present, whether they were cleared successfully. The intraoperative techniques to clear the CBD were noted.

## RESULTS

Seventeen patients had preoperative ERCP for suspected choledocholithiasis, followed by LC over the 19-month period reviewed. The mean age of patients with confirmed CBD stones was 33 years (range 15-58) and 38 years (range 22-54) in patients with no CBD stones found on ERCP. Four of the 17 patients were males. All

**Table 1.**  
Risk factors in patients with no CBD stone found on ERCP.

PATIENT	SB ≠	AP ≠	GSP	CBD STONE US	CBD DILATED ON US
1*	Yes	Yes	Yes		
2†		Yes	Yes		
3†			Yes	Yes	Yes
4†		Yes	Yes		
5†					Yes

\*Patient admitted to General Surgery.

†Patient admitted to Internal Medicine.

SB=serum bilirubin; AP=alkaline phosphatase; GSP=gallstone pancreatitis; US=ultrasound; CBD=common bile duct.

**Table 2.**  
Risk factors in patients with CBD stone found on ERCP.

PATIENT	SB ≠	AP ≠	GSP	CBD STONE US	CBD DILATED ON US
1*	Yes	Yes			Yes
2*	Yes	Yes	Yes	Yes	Yes
3*	Yes	Yes			
4*	Yes	Yes			
5*	Yes	Yes	Yes		
6*	Yes	Yes			
7*	Yes	Yes	Yes		Yes
8*	Yes	Yes			Yes
9*	Yes	Yes			
10*	Yes	Yes			Yes
11*	Yes			Yes	Yes
12*	Yes	Yes			Yes

\*Patient admitted to General Surgery.

SB=serum bilirubin; AP=alkaline phosphatase; GSP=gallstone pancreatitis; US=ultrasound; CBD=common bile duct.

patients were admitted to the hospital for acute biliary symptoms. Clinical presentations included 7 patients with biliary pancreatitis, 2 with cholangitis, and 8 with symptomatic cholelithiasis plus suspected biliary obstruction. Gallstones were visualized on US in 15 of 17 patients. The endoscopist was able to successfully cannulate the papillae and complete the ERCP in all 17 patients. There were no complications or deaths related to the endoscopic procedure in this series.

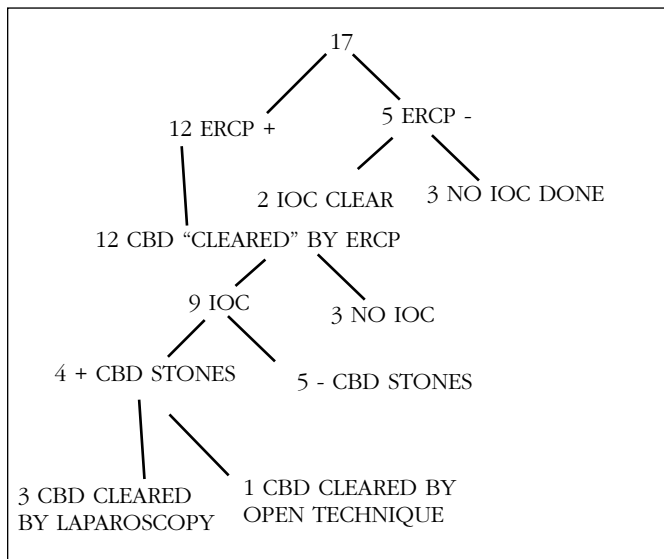
Reasons for suspected choledocholithiasis that led to pre-operative ERCP included gallstone pancreatitis in 7, elevated serum bilirubin level (>1.7 mg/dl) in 13, elevated alkaline phosphatase level (>107 U/L) in 14, US finding of choledocholithiasis in 3 and dilated CBD in 10 (>7 mm). Sixteen of 17 patients had more than one of the above risk factors for choledocholithiasis present at admission (**Tables 1 and 2**).

No CBD stones were found on ERCP in 5 of 17 patients (29%). Of these 5 patients, the intraoperative cholangiogram confirmed no choledocholithiasis in 2, while cholangiogram was not performed in the other 3 (**Figure 1**). The risk factors for choledocholithiasis, which were present as well as those not present in the patients who did not have CBD stones found on ERCP, are presented in **Table 1**.

Common bile duct stones were detected on ERCP in 12 of 17 patients (71%). The risk factors for choledocholithiasis, noted in these 12 patients, are presented in **Table 2**. In all 12 patients, sphincterotomy with stone extraction was performed and, in each case, the endoscopist reported a fully cleared CBD. Intraoperative cholangiogram was performed during subsequent LC in 9 of the 12 patients who had stones found and reportedly cleared by ERCP. Choledocholithiasis was still present in 4 of these 9 patients (**Figure 1**). Laparoscopic techniques (all transcystic) successfully cleared the CBD in 3 patients. The fourth patient required open CBD exploration for successful clearance.

## DISCUSSION

Before the introduction of LC, the use of ERCP in patients with gallbladder disease was reserved for patients with severe biliary pancreatitis, acute suppurative cholangitis, poor operative candidates with suspected CBD stones or for postoperative retained stones. Open CBD exploration added little to open cholecystectomy alone in terms of morbidity or mortality. However, open CBD exploration compared to LC substantially lengthens morbidity, hospital stay, and return to work time. This has resulted in much interest in methods to clear the CBD by



**Figure 1.** Patients with suspected choledocholithiasis who underwent ERCP prior to laparoscopic cholecystectomy. CBD=common bile duct; IOC=intraoperative cholangiogram.

less invasive means. The major options when CBD stones are suspected include preoperative ERCP, laparoscopic CBD clearance techniques, or postoperative ERCP if laparoscopic methods fail or are not available. The optimal approach to patients with suspected CBD stones is uncertain and depends upon local expertise in laparoscopy, availability of equipment, as well as the availability and expertise in ERCP.

In 1993, the NIH Consensus statement recommended preoperative ERCP or transhepatic cholangiography for all patients with clinical suspicion for CBD stones. This led to a high number of therapeutic and nontherapeutic ERCP's.<sup>38</sup> Several centers report ERCP to have a high diagnostic success rate (76-97%)<sup>12,19,39-41</sup> and an inability to cannulate rate of just 5%.<sup>24,39</sup> In our series, endoscopists had a cannulation rate of 100%. Major centers report impressive ductal clearance rates of more than 90%.<sup>11,12,26,42-44</sup> However, Poole and Cuschieri pointed out that data collected from major centers probably underestimates the actual endoscopic stone extraction failure rate and that, in European trials, the preoperative ERCP ductal clearance failure rate is approximately 20%.<sup>10,45</sup> Koo reported a small series in which endoscopists supposedly cleared the CBD of stones, yet 43% were found to have residual stones on intraoperative

cholangiography.<sup>30</sup> In our series, of the 12 patients whom the endoscopist reported to have endoscopically cleared the CBD stones, 4 (33%) were subsequently found to have choledocholithiasis on intraoperative cholangiography. We suspect that the stones undetected during ERCP were present in the intrahepatic ducts and thus difficult to visualize. Subsequently, these stones migrated into the CBD and were successfully detected during intraoperative cholangiography.

In an institution such as our own, in which ERCP is performed prior to LC in patients with suspected CBD stones, the critical element in avoiding unnecessary ERCP and its inherent risk and cost is the effectiveness of CBD stone prediction. Complications of ERCP occur approximately 10% of the time, with a mortality rate of 1-3%.<sup>46-48</sup> The most common of the complications, post-ERCP pancreatitis, occurs from 1-5.5% of the time, with 10% of those who develop the complication requiring surgical intervention.<sup>46,49</sup> In our series, we were fortunate to have no complications related to ERCP and no mortality.

The incidence of CBD stones in unselected patients undergoing elective LC has been quoted as 5-20%.<sup>27,30,50-55</sup> However, in patients thought to be at low risk for CBD stones, the rate of choledocholithiasis found on routine intraoperative cholangiogram is reported to be 1.7%.<sup>26</sup> To better define the most accurate clinical risk factors for choledocholithiasis and thereby avoid subjecting patients to unnecessary preoperative ERCP, several models have been developed. Barkin found that a combination of risk factors including age, elevated bilirubin, and US findings of a dilated duct and a CBD stone produced a 94% specificity of CBD stone presence.<sup>32</sup> He also found that if all four risk factors were absent, then the chance of a CBD stone being present was only 8%.<sup>32</sup> His model is clinically limited because most patients do not have all four risk factors either present or absent. Robertson's model using age, jaundice, albumin, and US findings produced a 75% specificity and 89% sensitivity for CBD stones.<sup>13</sup> Trondsen developed a model using age and a combination of several LFTs to accurately predict CBD stones with a 3.7% false positive rate and a 1.8% false negative rate.<sup>33</sup> Robertson and Lacaine both concluded that of all the LFTs, alkaline phosphatase was the most important in predicting CBD stones, but Robertson emphasized that a single elevated LFT was not a good predictor.<sup>13,31</sup> Saltztein found that the only combination of risk factors that accurately predicted CBD stones was a combination of elevated bilirubin and ele-

vated alkaline phosphatase.<sup>34</sup> In our series, we found a normal serum bilirubin to be the best predictor of the absence of CBD stones with a false negative rate of 0/4 (0%). Of the 4 patients who had a normal bilirubin but other risk factors present, none were found to have CBD stones (**Table 1**). An elevated bilirubin level in our series was the best predictor of the presence of CBD stones. A total of 13 patients had an elevated bilirubin and, of those, 12 of 13 (92%) had CBD stones found (a false positive rate of 8%). In this series, LFTs other than bilirubin did not accurately predict CBD stones, nor did age. Three patients had a normal alkaline phosphatase and, of those, one had a CBD stone (a false negative rate of 33%). Fourteen patients had an elevated alkaline phosphatase, but only 11 had CBD stones (a false positive rate of 21%). In our series, biliary dilatation found on US had a 22% false positive rate (2/9), while a normal-sized ductal system did not accurately predict the absence of CBD stones (false negative rate of 63%). Interestingly, each of the three patients who had false positive US findings also had a normal bilirubin, further supporting the negative predictive value of a normal bilirubin.

Many authors have demonstrated the overall low incidence of CBD stones found in gallstone pancreatitis patients, especially if one delays ERCP or intraoperative cholangiography for more than 48 hours from the time of presentation or until the pancreatitis has resolved.<sup>12,56-59</sup> Others have concluded that preoperative ERCP in patients with biliary pancreatitis is only warranted for persistent elevation of LFTs or in patients with severe pancreatitis who do not quickly improve.<sup>60</sup> Our findings support these observations. In our 7 biliary pancreatitis patients, only 3 (43%) had CBD stones detected and, of those, all 3 had an elevated serum bilirubin level, further supporting the predictive value of bilirubin in our institution. In total, of the 17 patients subjected to preoperative ERCP, 12 were confirmed to have choledocholithiasis (71%). Of note, at our institution, the Department of Surgery typically obtains preoperative ERCP based on a persistently elevated bilirubin level. Of the 5 patients who were found to have no CBD stones (received unnecessary preoperative ERCP), 4 were admitted to the Internal Medicine service. They each had a normal serum bilirubin, but preoperative ERCP was ordered based on the presence of other risk factors. Had these patients been on the Surgery service, they most likely would not have had preoperative ERCP because they had a normal serum bilirubin.

We, like others, have found laparoscopic CBD clearance an effective alternative to open CBD exploration.<sup>1,2,8</sup> Advances in technology, as well as advanced laparoscopic skills, have made possible transcystic and, more recently, supraduodenal choledochotomy with CBD clearance.<sup>3,4,9</sup> As the success rate of laparoscopic CBD clearance has improved to more than 80%, many surgeons bypass the preoperative ERCP in patients with suspected CBD stones and, if found on intraoperative cholangiography, CBD stones are cleared laparoscopically.<sup>2,5-8</sup> Erickson, using decision tree analysis and existing data in the literature, determined that the best management scheme in terms of cost and morbidity in patients with predicted CBD stones was laparoscopic CBD clearance with postoperative ERCP reserved for laparoscopic failures. If the ability of the institution to accurately predict CBD stones was high, preoperative ERCP followed by laparoscopic CBD exploration for ERCP failures was an equally effective strategy. Finally, he found that if postoperative ERCP was not readily available, then preoperative ERCP followed by LC was the preferred approach.<sup>61</sup>

Others, like us, reserve laparoscopic CBD techniques for unexpected choledocholithiasis found intra-operatively and to ERCP failures.<sup>10,62</sup> In our series, we found residual choledocholithiasis in 4 patients. These CBD stones were successfully cleared with transcystic laparoscopic techniques in 3 of 4 (75%) patients. Other treatment options for residual CBD stones post ERCP include expectant therapy, repeat postoperative ERCP, or open CBD clearance. Factors which support spontaneous postoperative passage of CBD stones include a single small stone, no significant distal CBD stricture, duodenal filling during cholangiogram, the serum bilirubin not rising since the ERCP and the gastroenterologist feeling an adequate sphincterotomy has been performed. Studies have shown that a stone greater than 1 cm or multiple stones are significantly more difficult to clear with ERCP and sphincterotomy, so we would not rely on repeat postoperative ERCP for stone clearance nor would we necessarily expect these to pass spontaneously.<sup>63-64</sup> Therefore, if we detect a residual stone greater than 1 cm or multiple stones during intraoperative cholangiography, we are inclined to convert to open CBD exploration if laparoscopic CBD techniques have failed.

## **CONCLUSIONS**

In patients with a high suspicion for choledocholithiasis,

preoperative ERCP followed by LC is an effective strategy. Unnecessary ERCP can be avoided if strict clinical criteria to reliably predict CBD stones is established and followed (serum bilirubin in our institution). Although ERCP cannulation rate and the detection rate of choledocholithiasis is high, residual stones are not uncommon even after presumed successful ERCP. These stones can be detected with intraoperative cholangiography and, if found, can be treated effectively with laparoscopic techniques if the surgeon feels the stones will not pass spontaneously.

### References:

1. Hunter JG. Laparoscopic transcystic common bile duct exploration. *Am J Surg.* 1992;163:53-56.
2. Phillips EH, Carroll BJ, Pearlstein AR, et al. Laparoscopic choledochoscopy and extraction of common bile duct stones. *World J Surg.* 1993;17:22-28.
3. Smith PC, Soper NJ, Clayman RV. Laparoscopic cholecystectomy and choledochoscopy for treatment of cholelithiasis and choledocholithiasis. *Surgery.* 1992;111:230-233.
4. Ferzli GS, Massaad A, Kiel T, Worth MH Jr. The utilization of laparoscopic common bile duct exploration in the treatment of choledocholithiasis. *Surg Endosc.* 1994;8:296-298.
5. Hunter J, Soper NJ. Laparoscopic management of bile duct stones. *Surg Clin North Am.* 1992;75:1077-1080.
6. Carroll BJ, Phillips EH, Chandra M, Fallas M. Laparoscopic transcystic duct balloon dilatation of the sphincter of Oddi. *Surg Endosc.* 1993;7:514-517.
7. Phillips EH, Rosenthal RJ, Carroll BJ, Fallas MJ. Laparoscopic transcystic duct common bile duct exploration. *Surg Endosc.* 1994;8:1389-1394.
8. Petelin J. Laparoscopic approach to common duct pathology. *Am J Surg.* 1993;165:487-491.
9. Phillips EH, Carroll BJ. New techniques for the treatment of common bile duct calculi encountered during laparoscopic cholecystectomy. *Probl Gen Surg.* 1991;8:387-394.
10. Poole G, Waldron B, Shimi SM, Cuschieri A. Laparoscopic common bile duct exploration after failed endoscopic stone extraction. *Endosc.* 1997;29:609-613.
11. Francesi D, Brandt C, Margolin D, et al. Management of common bile duct stones in patients undergoing laparoscopic cholecystectomy. *Amer Surg.* 1993;59:525-532.
12. Miller RE, Kimmelstiel FM, Winkler WP. Management of common bile duct stones in the era of laparoscopic cholecystectomy. *Am J Surg.* 1995;169:273-275.
13. Robertson GS, Jagger C, Johnson PR, et al. Selection criteria for pre-operative endoscopic retrograde cholangiopancreatography in the laparoscopic era. *Arch Surg.* 1996;131:89-94.
14. Boulay J, Schellenberg R, Brady PG. Role of ERCP and therapeutic biliary endoscopy in association with laparoscopic cholecystectomy. *Am J Gastroenterol.* 1992;87:837-842.
15. Graham SM, Flowers JL, Scott TR, et al. Laparoscopic cholecystectomy and common bile duct stones: the utility of planned perioperative endoscopic retrograde cholangiography and sphincterotomy: experience with 63 patients. *Ann Surg.* 1993;218:61-67.
16. Hawasli A, Lloyd L, Pozios V, Veneri R. The role of endoscopic retrograde cholangiopancreatogram in laparoscopic cholecystectomy. *Am Surg.* 1993;59:285-289.
17. Mo LR, Yau MP, Hwang MH, et al. The role of ERCP and therapeutic biliary endoscopy in laparoscopic cholecystectomy. *J Laparoendosc Surg.* 1993;3:19-22.
18. Vitale GC, Larson GM, Wieman TJ, Cheadle WG, Miller FB. The use of ERCP in the management of common bile duct stones in patients undergoing laparoscopic cholecystectomy. *Surg Endosc.* 1993;7:9-11.
19. Voyles CR, Sanders DL, Hogan R. Common bile duct evaluation in the era of laparoscopic cholecystectomy. *Ann Surg.* 1994;219:744-752.
20. Leitman IM, Fisher ML, McKinney MJ, et al. The evaluation and management of known or suspected stones of the common bile duct in the era of minimal access surgery. *Surg Gynecol Obstet.* 1993;176:527-533.
21. Clair DC, Carr-Locke DL, Becker JM, Brooks DC. Routine cholangiography is not warranted during laparoscopic cholecystectomy. *Arch Surg.* 1993;128:551-555.
22. Korman J, Cosgrove J, Furman M, et al. The role of endoscopic retrograde cholangiopancreatography and cholangiography in the laparoscopic era. *Ann Surg.* 1996;223:212-216.
23. Berci G. Preoperative ERCP and intraoperative cholangiography in the age of laparoscopic cholecystectomy. *Surg Endosc.* 1993;7:2.
24. Cotton PB. Endoscopic retrograde cholangiopancreatography and laparoscopic cholecystectomy. *Am J Surg.* 1993;165:474-478.
25. Neuhaus H, Feussner H, Ungeheuer A, et al. Prospective evaluation of the use of endoscopic retrograde cholangiography prior to laparoscopic cholecystectomy. *Endosc.* 1992;24:746-749.
26. Fiore NF, Ledniczy G, Wiebke EA, et al. An analysis of

- perioperative cholangiography in one thousand laparoscopic cholecystectomies. *Surgery*. 1997;122:817-823.
27. Cotton PB, Baillie H, Pappas TN, Meyers WS. Laparoscopic cholecystectomy and the biliary endoscopist. *Gastrointest Endosc*. 1991;37:94-97.
28. Reis R, Deutsch AA, Nudelman I, Kott I. Statistical value of various clinical parameters in predicting the presence of choledochal stones. *Surg Gynecol Obstet*. 1984;159:273-276.
29. Hauer-Jensen M, Karesen R, Nygaard K, et al. Predictive ability of choledocholithiasis indicators: a prospective evaluation. *Ann Surg*. 1985;202:64-68.
30. Koo KP, Traverso LW. Do preoperative indicators predict the presence of common bile duct stones during laparoscopic cholecystectomy? *Am J of Surg*. 1996;171:495-499.
31. Lacaine F, Corlette MB, Bismuth H. Preoperative evaluation of the risk of common bile duct stones. *Arch Surg*. 1980;115:1114-1116.
32. Barkin AN, Barkun JS, Fried GM, et al. Useful predictors of bile duct stones in patients undergoing laparoscopic cholecystectomy. *Ann Surg*. 1994;220:32-39.
33. Trondsen E, Edwin B, Reiertsen O, et al. Selection criteria for endoscopic retrograde cholangiopancreatography in patients with gallstone disease. *World J Surg*. 1995;19:852-857.
34. Saltztein EC, Peacock JB, Thomas MD. Preoperative bilirubin, alkaline phosphatase and amylase levels as predictors of common duct stones. *Surg Gynecol Obstet*. 1982;154:381-384.
35. Taylor TV, Torrance B, Rimmer S, et al. Operative cholangiography: is there a statistical alternative? *Am J Surg*. 1983;145:640-643.
36. Taylor TV, Armstrong CP, Rimmer S, et al. Prediction of choledocholithiasis using a pocket microcomputer. *Br J Surg*. 1988;75:138-140.
37. Wilson TG, Hall JC, Watts J McK. Is operative cholangiography always necessary? *Br J Surg*. 1986;73:637-640.
38. National Institutes of Health consensus development conference statement on gallstone and laparoscopic cholecystectomy. *Am J Surg*. 1993;165:290-296.
39. Perissat J, Huibregtse K, Keane FBV, et al. Management of bile duct stones in the era of laparoscopic cholecystectomy. *Br J Surg*. 1994;81:799-781.
40. Baird DR, Wilson JP, Mason EM, et al. An early review of 800 laparoscopic cholecystectomies at a university-affiliated community teaching hospital. *Am Surg*. 1992;58:206-210.
41. Flowers JL, Zucker KA, Graham SM, et al. Laparoscopic cholangiography: results and indications. *Ann Surg*. 1992;214:209-216.
42. Cotton PB. Endoscopic management of bile duct stones (apples and oranges). *Gut*. 1984;25:587-597.
43. Sivak MV. Endoscopic management of bile duct stones. *Am J Surg*. 1989;158:228-240.
44. Vaira D, Ainley C, Williams S, et al. Endoscopic sphincterotomy in 1000 consecutive patients. *Lancet*. 1989;ii:431-433.
45. Cuschieri A, Croce E, Faggioni A, et al. EAES ductal stone study: preliminary findings of a multicentre prospective randomised trial comparing two-stage versus single-stage management. *Surg Endosc*. 1996;10:1130-1135.
46. Freeman ML, Nelson DB, Sherman S, et al. Complications of endoscopic biliary sphincterotomy. *N Engl J of Med*. 1996;335:909-918.
47. Leese T, Neoptolemos JP, Carr-Locke DL. Successes, failures, early complications, and their management following endoscopic sphincterotomy: results in 394 consecutive patients from a single centre. *Br J Surg*. 1985;72:215-219.
48. Cotton PB, Lehman G, Vennes JA, et al. Endoscopic sphincterotomy complications and their management: an attempt at consensus. *Gastrointest Endosc*. 1991;37:383-393.
49. Sherman S, Lehman G. ERCP and endoscopic sphincterotomy induced pancreatitis. *Pancreas*. 1991;6:350-367.
50. Traverso LW, Kozarek RA, Ball TJ, et al. Endoscopic retrograde cholangiography after laparoscopic cholecystectomy. *Am J Surg*. 1993;165:581-586.
51. Sackier JM, Berci G, Phillips E, et al. Role of cholangiography in laparoscopic cholecystectomy. *Arch Surg*. 1991;126:1021-1026.
52. Hermann RE. The spectrum of biliary stone disease. *Am J Surg*. 1989;158:171-173.
53. Hauer-Jensen M, Karesen R, Nygaard K, et al. Consequences of routine perioperative cholangiography during cholecystectomy for gallstone disease: a prospective randomized study. *World J Surg*. 1986;10:996-1002.
54. Meyers WC, Branum GD, Farouk M, et al. A prospective analysis of 1518 laparoscopic cholecystectomies. *N Engl J Med*. 1991;324:1073-1078.
55. Larson GM, Vitale GC, Casey J, et al. Multipractice analysis of laparoscopic cholecystectomy in 1983 patients. *Am J Surg*. 1992;163:221-226.
56. Arrequi ME, Davis CJ, Arkush AM, Nogan RF. Laparoscopic cholecystectomy combined with endoscopic sphincterotomy and stone extraction or laparoscopic choledochoscopy and electrohydraulic lithotripsy for management of cholelithiasis and choledocholithiasis. *Surg Endosc*. 1992;6:10-15.
57. Pace BW, Cosgrove J, Breuer B, Margolis IB. Intraoperative cholangiography revisited. *Arch Surg*. 1992;127:448-450.

58. Hauer-Jensen M, Karesen R, Nygaard K, Solheim K, Amli EJB, Rosseland AR. Prospective randomized study of routine intraoperative cholangiography during open cholecystectomy: long-term follow-up and multivariate analysis of predictors of choledocholithiasis. *Surgery*. 1993;113:318-323.
59. Kurzweil SM, Shapiro MJ, Andrus CH, et al. Hyperbilirubinemia without common bile duct abnormalities and hyperamylasemia without pancreatitis in patients with gallbladder disease. *Arch Surg*. 1994;129:829-833.
60. Carr-Locke DL, Neoptoleomas NJ, London IA, et al. A randomized controlled trial of ERCP and endoscopic sphincterotomy in acute gallstone associated pancreatitis. *Gastroenterology*. 1988;94:A59.
61. Erickson RA, Carlson B. The role of endoscopic retrograde cholangiopancreatography in patients with laparoscopic cholecystectomies. *Gastroenterology*. 1995;109:252-263.
62. Fanning NF, Horgan PG, Keane FB. Evolving management of common bile duct stones in the laparoscopic era. *J R Coll Surg Edinb*. 1997;42:389-394.
63. Persson B. Relation of size and number of common duct calculi to success of sphincterotomy and stone extraction. *Gastrointest Radiol*. 1991;16(3):212-214.
64. Hammarstrom LE, Stridbeck H, Ihse I. Endoscopic sphincterotomy for bile duct calculi-factors influencing the success rate. *Hepatogastroenterology*. 1996;43(7):127-133.

---

Acknowledgments: The authors would like to thank Christine Rothermel, MS, Pat Harvey, and Diane Duclos for their assistance in manuscript preparation.

Presented at the American College of Surgeons, Southern California Chapter Meeting, Santa Barbara, California, January 22, 1999.