

Prone position plexopathy: an avoidable complication of prone positioning for COVID-19 pneumonitis?

Josh King-Robson ¹, Eleanor Bates,² Elisaveta Sokolov ³,
Robert D M Hadden ¹

¹Neurology Department, King's College Hospital, London, UK

²Critical Care Department, King's College Hospital, London, UK

³Department of Clinical Neurophysiology, National Hospital for Neurology and Neurosurgery, London, UK

Correspondence to
Dr Josh King-Robson;
j.king-robson@nhs.net

Accepted 2 November 2021

SUMMARY

Prone positioning is a mainstay of management for those presenting to the intensive care unit with moderate-to-severe acute respiratory distress syndrome due to COVID-19. While this is a necessary and life-saving intervention in selected patients, careful positioning and meticulous care are required to prevent compression and traction of the brachial plexus, and resultant brachial plexopathy. We describe two patients who developed a brachial plexus injury while undergoing prone positioning for management of COVID-19 pneumonitis. Both patients were diabetic and underwent prolonged periods in the prone position during which the plexopathy affected arm was abducted for 19 and 55 hours, respectively. We discuss strategies to reduce the risk of this rare but potentially disabling complication of prone positioning.

BACKGROUND

Prone positioning improves oxygenation and increases survival in severe acute respiratory distress syndrome (ARDS) and has become a mainstay of management for those presenting to the intensive care unit (ICU) with refractory hypoxaemia due to COVID-19.^{1–4} The life-saving benefits of prone positioning in these patients clearly outweigh the accompanying risks, including pressure sores, tracheal tube obstruction, and brachial plexus injury; however, it remains important to consider measures which can mitigate these potentially disabling complications.⁵

Brachial plexus injury is a recognised complication of prone positioning.^{6,7} The long course of the brachial plexus, its firm fixation to the prevertebral and axillary fascia and its close association with the clavicle, first rib and humerus, underlie its vulnerability.⁷ Compression and traction during prone positioning results in periaxonal oedema, ischaemia of the vasa nervorum, demyelination, and in severe cases, axonal degeneration.⁸ While short-lived and mild insults result in a reversible conduction block (neuropraxia), recovery from more severe injury can be limited and results in significant functional disability.^{9–11}

Prone positioning during anaesthesia for surgical procedures utilises various different operating tables and positioning techniques, intended to reduce tension on nerve roots or reduce intra-abdominal pressure.¹² By contrast, in those with ARDS on the ICU, positioning options are limited, while evidence suggesting that patients should be

kept in the prone position for at least 16 hours to obtain a survival benefit necessitates long periods in the prone position.^{2,5}

Current Intensive Care Society (UK) guidelines propose the use of the 'swimmer's position', in which one arm is abducted (to no more than 90°) with the elbow flexed such that the hand is placed next to the head.¹³ Although not obvious from the name, the head should face the abducted arm and the other arm is placed at the patient's side.¹³ This position is intended to minimise traction and compression of the brachial plexus, which is worse if the head faces away, or if the shoulder is abducted >90° (figure 1). The head and arm positions should be alternated every 2–4 hours, reducing the duration of any nerve insult that may occur, and patients should be tilted 30° head-up. However, during the COVID-19 pandemic the frequency of alternation, which requires an airway-trained doctor to be present, was necessarily reduced, as

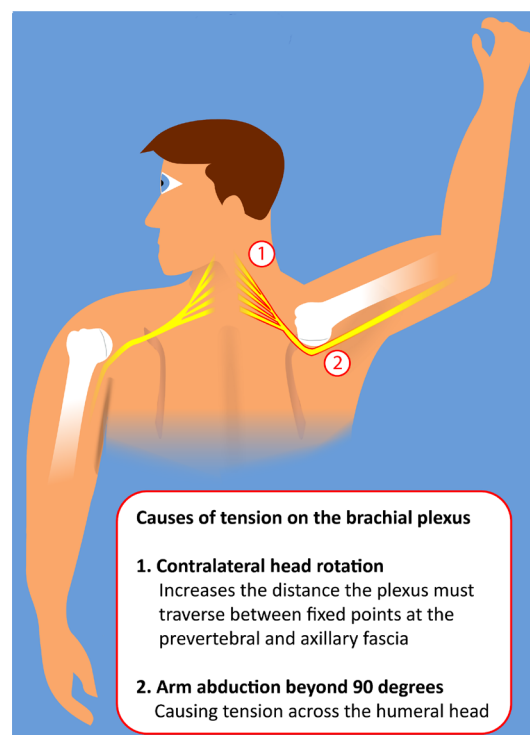
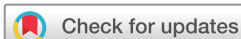

Figure 1 Traction on the brachial plexus. Traction is placed on the brachial plexus by abducting the arm, particularly beyond 90°, where it results in tension across the humeral head. This is further exacerbated by turning the head away from the abducted arm. Figure drawn by Josh King-Robson.



© BMJ Publishing Group Limited 2022. No commercial re-use. See rights and permissions. Published by BMJ.

To cite: King-Robson J, Bates E, Sokolov E, et al. *BMJ Case Rep* 2022;**15**:e243798. doi:10.1136/bcr-2021-243798

Table 1 Characteristics, clinical presentation, prone positioning details and outcome

		Patient 1	Patient 2
Patient characteristics	Age (years)	55	58
	Sex	M	M
	Ethnicity	Caribbean	Asian British
	BMI (kg/m ²)	22	29
	Diabetes?	T1DM, (HBA1C 11.8%)	T2DM, (HBA1C 6.0%)
	Days on ICU	15	32
	Hours in prone position (total)	22	101
Abduction of affected arm (hours)	Total	19	55
	Maximum continuous	10	11
	Mean continuous	9.5	6.86
Abduction of unaffected arm (hours)	Total	3	46
	Maximum continuous	3	10
	Mean continuous	3	5.75
Clinical features	Clinical presentation	Complete flaccid paralysis of all muscles in left upper limb. Absent reflexes. Severe sensory loss distal to shoulder.	Left wrist drop, bilateral intrinsic hand weakness.
	EMG	Severe acute denervation in left upper limb (first dorsal interosseous, extensor digitorum communis, extensor indicis, brachioradialis, triceps, biceps and deltoid) but normal EMG in pectoralis major and supra/infraspinatus. Sensory action potentials absent in left upper limb (median, ulnar, radial and medial antebrachial cutaneous) and left median and ulnar motor potentials small.	Severe acute denervation in left triceps, extensor digitorum and pronator quadratus. Mild EMG abnormalities in many other muscles suggesting critical illness neuromyopathy. Sensory potential absent from left (normal on the right) radial. Sensory and motor potentials absent from the median and ulnar nerves bilaterally.
	MRI c-spine and brachial plexus	Normal	Not done
Outcome (6 months)	MMN-RODS	32	15
	mRS	2	3

BMI, body mass index; EMG, electromyogram; ICU, intensive care unit; MMN RODS, Multifocal Motor Neuropathy Rasch-built Overall Disability Scale (initially developed for use in multifocal motor neuropathy, we use this due to its ability to assess functional limitation in asymmetric upper limb weakness; 50 is normal while 0 means inability to perform any of 25 common activities); mRS, Modified Rankin Scale.

high numbers of patients placed significant pressure on ICU staffing.^{7 14}

It has been proposed that factors including hypovolaemia, hypothermia and diabetes can contribute the development of brachial plexus neuropathy.^{7 15 16} COVID-19 has also been proposed to have numerous neurological sequelae, however, given the ubiquity of COVID-19 infection at the time of writing, care must be taken when attributing causality to neurological presentations.^{17–19}

We describe two cases of brachial plexopathy occurring in patients following prone positioning due to COVID-19 pneumonia and discuss measures that may prevent this complication

of prone positioning. Both patients consented to inclusion in this manuscript.

CASE PRESENTATION

Patient characteristics, prone position details and clinical and neurophysiological results are summarised in [table 1](#). Both patients were male, diabetic and from a black or ethnic minority background. Both developed an acute kidney injury requiring dialysis during their ICU stay, and neither had subclavian venous catheter insertion or any other procedure near the brachial plexus. Neither patient was treated with steroids as the efficacy of dexamethasone in COVID-19 had not been proven at the time of their admission.

Patient 1 presented with a painless flaccid complete paralysis of the entire left upper limb on waking from sedation, developing wasting over left deltoid, biceps, triceps and infraspinatus. Neurophysiological assessment was consistent with an extensive left brachial plexus injury, with electromyography (EMG) demonstrating severe acute denervation of all muscles innervated by all cords of the plexus below the level of the pectoral nerve. His ICU stay had included one single 22-hour period in the prone position, during which the left (affected) arm was abducted for nine continuous hours, before switching sides for 3 hours, and a subsequent further 10 hours of continuous left arm abduction, totalling 19 hours ([figure 2](#)). On presentation with COVID-19 he had very poorly controlled diabetes (HBA1C 11.8%) and was in severe diabetic ketoacidosis (pH 6.8). His period in the prone position coincided with supramaximal

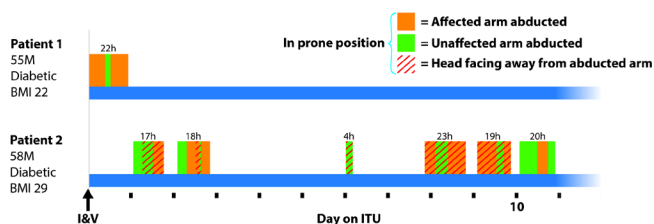


Figure 2 Analysis of prone positioning. Patient 1 spent 22 hours and patient 2 101 hours in the prone position, including extended periods with the plexopathy-affected arm continuously abducted. Patient 2 was often positioned with the head facing away from the abducted arm. Time is indicated, in hours (h), for each period in prone position. BMI, body mass index; I&V, intubated and ventilated; ITU, intensive therapy unit. Figure drawn by Josh King-Robson.

norepinephrine requirements (2.667 mcg/kg/hour) and marked hypoxaemia (pO₂ 5.2kPa). He subsequently spent 15 days intubated and ventilated and the left upper limb weakness was discovered after extubation. An MRI scan of the cervical spine and brachial plexus was normal. After 6 months there was partial improvement in proximal power but still no functional use of the left hand.

Patient 2, on waking from sedation presented with a left wrist drop. There was markedly asymmetric weakness especially of left wrist extension, and some bilateral weakness of the intrinsic hand muscles. EMG demonstrated severe focal abnormalities of the left radial nerve, but also changes suggesting critical illness neuromyopathy. His ICU stay had included 101 hours in the prone position across six separate sessions, during which the plexopathy-affected left arm was abducted for a total of 55 hours. Periods of continuous abduction of the left arm varied from 4 to 11 hours (mean 6.8 hours). His head often faced away from the abducted arm (figure 2). This patient had markedly raised levels of interleukin-6 (25.2 ng/L) and interleukin-8 (55.6 ng/L). This patient spent a total of 58 days intubated and ventilated. MRI brain imaging while on the ICU revealed a 1.3 cm T2 hyperintense lesion within the left corona radiata. This lesion demonstrated pronounced high signal on diffusion-weighted imaging with mildly reduced apparent diffusion coefficient values and involution on repeat imaging 1 month later, consistent with an inflammatory lesion with gliosis, although we cannot exclude an ischaemic aetiology. After 6 months there was partial improvement in left hand weakness but still no functional use of the left hand and persisting sensory loss.

OUTCOME AND FOLLOW-UP

Both patients had significant residual disability at 6 months, as evidenced by their Modified Rankin Scale score (table 1). The more severe plexus injury was experienced by the patient who spent a shorter overall time in the prone position, and it is clear that even short prone surgical procedures can result in brachial plexus injury.²⁰ The extremely high norepinephrine requirements and severe hypoxia of this patient may have exacerbated any ischaemic insult to the plexus.

DISCUSSION

We describe two patients who developed a brachial plexus injury following prone positioning during treatment for COVID-19 pneumonitis. In addition to necessarily prolonged periods of prone positioning, the profound hypoxia which necessitated this positioning and the metabolic consequences of diabetes would likely have conferred increased risk of nerve injury. Assuming these factors are already optimally treated, improved patient positioning is one method that we can implement to mitigate the risk of prone plexus injury in future.

Both of our patients had prolonged periods of prone positioning, with the affected arm abducted for significantly longer than the recommended 2 to 4 hours. In our second patient, the head often faced away from the abducted arm, placing the brachial plexus under increased tension.

One of these patients also developed a cerebral inflammatory lesion during his ICU stay²¹; while this left-sided lesion would not explain the left upper limb weakness, it raises the possibility that a COVID-19-related inflammatory aetiology may have played a role in his nerve injury. There are reports of mononeuritis multiplex and brachial neuritis (neuralgic amyotrophy) in patients following COVID-19 infection,²² and our patients' deficits may have a purely inflammatory cause, however we feel a

largely mechanical cause is more likely because of the prolonged prone positioning, lack of pain, and in patient 1, the anatomical distribution of severe motor and sensory deficit affecting only a single limb.^{17 19 23 24}

The weaknesses of our report include its retrospective nature and the slightly limited neurological assessment and follow-up due to staffing pressures during the pandemic.

The trials of prone positioning that demonstrated its efficacy in ARDS did not report plexopathy as a complication.^{1 2} This may be because the positioning guidance, strictly followed during these trials, was less rigorously followed during the COVID-19 pandemic as large numbers of unwell patients placed a significant burden on ICU staffing and resources. It may also be that the microvascular and inflammatory sequelae of systemic COVID-19 infection contributed to the positioning-related ischaemic insult in our patients; indeed, a number of cases of plexus injury in COVID-19 have been reported, highlighting that this is not an uncommon problem in this patient population, including in some patients who have not undergone prone positioning.^{20 22 24 25}

The 'swimmer's position' is widely advocated in guidelines, however, there is little evidence for its safety, and no controlled trials comparing different positions, while most of the pre-pandemic experience of prone positioning was derived from anaesthesia for comparatively short periods of time. Some anaesthetists have advocated avoidance of arm abduction during prone positioning, advising instead to keep both arms adducted at the patient's sides to reduce risk to the brachial plexus.²⁶ Given that the 'swimmer's position' appears liable to malpositioning, we wonder if not just the name but also the position might be abandoned, in favour of the adducted approach. Nevertheless, current guidelines provide a pragmatic approach to reduce risk. As large numbers of patients continue to be placed in the prone position due to COVID-19 infection, we emphasise the importance of meticulous patient positioning and adherence to Intensive Care Society (UK) prone positioning guidelines.¹³

Learning points

- ▶ Brachial plexus injury is a disabling complication of prone positioning for COVID-19 pneumonitis.
- ▶ Meticulous patient positioning according to Intensive Care Society (UK) prone positioning guidelines is important to reduce the risk of prone position plexopathy.
- ▶ Care must be taken to ensure that patients in the prone position are turned regularly, alternating the head and arm positions at least every 2–4 hours, to reduce the risk to the brachial plexus.

Acknowledgements We would like to thank Dr James Burge for his helpful advice and expertise in discussion of these cases.

Contributors JK-R helped in drafting and revision of the manuscript, and creation of figures. EB performed revision of the manuscript. ES helped in neurophysiological assessment and revision of the manuscript. RDMH was involved in conception of project, interpretation of results and revision of the manuscript.

Funding The authors have not declared a specific grant for this research from any funding agency in the public, commercial or not-for-profit sectors.

Competing interests None declared.

Patient consent for publication Consent obtained directly from patient(s).

Provenance and peer review Not commissioned; externally peer reviewed.

Case reports provide a valuable learning resource for the scientific community and can indicate areas of interest for future research. They should not be used in isolation to guide treatment choices or public health policy.

ORCID iDs

Josh King-Robson <http://orcid.org/0000-0002-3662-9404>

Elisaveta Sokolov <http://orcid.org/0000-0002-1509-9416>

Robert D M Hadden <http://orcid.org/0000-0002-9702-0256>

REFERENCES

- Gattinoni L, Tognoni G, Pesenti A, *et al.* Effect of prone positioning on the survival of patients with acute respiratory failure. *N Engl J Med* 2001;345:568–73.
- Guérin C, Reignier J, Richard J-C, *et al.* Prone positioning in severe acute respiratory distress syndrome. *N Engl J Med Overseas Ed* 2013;368:2159–68.
- Yang X, Yu Y, Xu J, *et al.* Clinical course and outcomes of critically ill patients with SARS-CoV-2 pneumonia in Wuhan, China: a single-centered, retrospective, observational study. *Lancet Respir Med* 2020;8:475–81.
- Alhazzani W, Møller MH, Arabi YM, *et al.* Surviving sepsis campaign: guidelines on the management of critically ill adults with coronavirus disease 2019 (COVID-19). *Intensive Care Med* 2020;46:854–87.
- Bloomfield R, Noble DW, Sudlow A. Prone position for acute respiratory failure in adults. *Cochrane Database Syst Rev* 2015;11:Cd008095.
- Simpson AI, Vaghela KR, Brown H, *et al.* Reducing the risk and impact of brachial plexus injury sustained from prone Positioning-A clinical commentary. *J Intensive Care Med* 2020;35:1576–82.
- Uribe JS, Kolla J, Omar H, *et al.* Brachial plexus injury following spinal surgery. *J Neurosurg Spine* 2010;13:552–8.
- Sawyer RJ, Richmond MN, Hickey JD, *et al.* Peripheral nerve injuries associated with anaesthesia. *Anaesthesia* 2000;55:980–91.
- Nitz AJ, Matulionis DH. Ultrastructural changes in rat peripheral nerve following pneumatic tourniquet compression. *J Neurosurg* 1982;57:660–6.
- Wall EJ, Massie JB, Kwan MK, *et al.* Experimental stretch neuropathy. changes in nerve conduction under tension. *J Bone Joint Surg Br* 1992;74-B:126–9.
- Kwan MK, Wall EJ, Massie J, *et al.* Strain, stress and stretch of peripheral nerve. rabbit experiments in vitro and in vivo. *Acta Orthop Scand* 1992;63:267–72.
- Edgcombe H, Carter K, Yarrow S. Anaesthesia in the prone position. *Br J Anaesth* 2008;100:165–83.
- Bamford P *et al.* *Guidance for: prone positioning in adult critical care. The intensive care Society and faculty of intensive care medicine*, 2019.
- DePasse JM, Palumbo MA, Haque M, *et al.* Complications associated with prone positioning in elective spinal surgery. *World J Orthop* 2015;6:351–9.
- Jones HD. Ulnar nerve damage following general anaesthetic. *Anaesthesia* 1967;22:471–5.
- Afifi AK, Kimura J, Bell WE. Hypothermia-Induced reversible polyneuropathy: electrophysiologic evidence of axonopathy. *Pediatr Neurol* 1988;4:49–53.
- Ellul MA, Benjamin L, Singh B, *et al.* Neurological associations of COVID-19. *Lancet Neurol* 2020;19:767–83.
- Fifi JT, Mocco J. COVID-19 related stroke in young individuals. *Lancet Neurol* 2020;19:713–5.
- Keddie S *et al.* Epidemiological and cohort study finds no association between COVID-19 and Guillain-Barré syndrome. *Brain* 2020.
- Goettler CE, Pryor JP, Reilly PM. Brachial plexopathy after prone positioning. *Crit Care* 2002;6:540–2.
- El Beltagi AH, Vattoth S, Abdelhady M, *et al.* Spectrum of neuroimaging findings in COVID-19. *Br J Radiol* 2021;94:20200812.
- Needham E, Newcombe V, Michell A, *et al.* Mononeuritis multiplex: an unexpectedly frequent feature of severe COVID-19. *J Neurol* 2021;268:2685–9.
- Siepmann T, Kitzler HH, Lueck C, *et al.* Neuralgic amyotrophy following infection with SARS-CoV-2. *Muscle Nerve* 2020;62:E68–70.
- Mitry MA, Collins LK, Kazam JJ, *et al.* Parsonage-turner syndrome associated with SARS-CoV2 (COVID-19) infection. *Clin Imaging* 2021;72:8–10.
- Malik GR, Wolfe AR, Soriano R, *et al.* Injury-prone: peripheral nerve injuries associated with prone positioning for COVID-19-related acute respiratory distress syndrome. *Br J Anaesth* 2020;125:e478–80.
- Winfrey CJ, Kline DG. Intraoperative positioning nerve injuries. *Surg Neurol* 2005;63:5–18.

Copyright 2021 BMJ Publishing Group. All rights reserved. For permission to reuse any of this content visit <https://www.bmj.com/company/products-services/rights-and-licensing/permissions/>
BMJ Case Report Fellows may re-use this article for personal use and teaching without any further permission.

Become a Fellow of BMJ Case Reports today and you can:

- ▶ Submit as many cases as you like
- ▶ Enjoy fast sympathetic peer review and rapid publication of accepted articles
- ▶ Access all the published articles
- ▶ Re-use any of the published material for personal use and teaching without further permission

Customer Service

If you have any further queries about your subscription, please contact our customer services team on +44 (0) 207111 1105 or via email at support@bmj.com.

Visit casereports.bmj.com for more articles like this and to become a Fellow