

# Stevens-Johnson syndrome in a pregnant woman who received the influenza vaccine



Brandon J. Calley, BS, Jamal Saleh, MD, Kara Young, MD, and Karolyn A. Wanat, MD  
*Milwaukee, Wisconsin*

**Key words:** influenza vaccine; pregnancy; Stevens-Johnson syndrome; woman.

## INTRODUCTION

Stevens-Johnson syndrome (SJS) is a life-threatening, severe cutaneous adverse reaction characterized by epidermal necrosis and systemic symptoms. There are several well-documented etiologies of SJS in the literature, including medications, viruses, and idiopathic causes. Although medications are the most common culprits of SJS, vaccines have rarely been implicated in eliciting SJS. Herein, we describe a unique presentation of SJS in a 34-year-old pregnant woman after receiving an influenza vaccine.

## CASE REPORT

A 34-year-old woman who was 29 weeks pregnant was admitted to the hospital for medical management of preeclampsia. Prior to admission, her medications included labetalol 200 mg twice daily for 22 days, ferrous sulfate 325 mg twice daily, prenatal multivitamins with folic acid once daily, and hydroxyprogesterone 250 mg/mL once daily by intramuscular injection. On day 1 of her hospital stay, she received intravenous magnesium for 24 hours, and labetalol was increased to 400 mg twice daily. She also received 2 doses of betamethasone on days 1 and 2 of admission. On day 14 of her hospital stay, she received a preservative-free quadrivalent influenza vaccine (Sanofi). She had no prior history of influenza vaccination. On day 17 of her hospital stay, she developed a sore throat and lesions on her face and chest. These symptoms worsened over the next 24 hours. Subsequent testing for influenza, streptococcus, mononucleosis, herpes simplex virus, and mycoplasma was negative. Dermatology was consulted for diagnostic clarification. On examination, a dusky bulla was observed at the administration site of the influenza vaccine (Fig 1). Additionally, she had

### Abbreviation used:

SJS: Stevens-Johnson syndrome

confluent oral-labial erosions (Fig 2), vulvar erosions, erythematous and dusky atypical macular target lesions on her palms (Fig 3), and evolving dusky pink-red macules with subsequent erosions on her trunk. Two 4-mm punch biopsy specimens were collected for routine histopathology, and 1 perilesional punch biopsy specimen was collected for direct immunofluorescence.

Histopathology demonstrated pauci-inflammatory interface dermatitis and full-thickness epidermal necrosis (Fig 4). No viral cytopathic changes were noted. Direct immunofluorescence findings were nonspecific. Given the temporal relationship between the administration of the influenza vaccine, observation of the large lesion at the vaccine site, involvement of 2 mucosal sites, full-thickness epidermal necrosis on histopathology, and systemic symptoms, a diagnosis of SJS secondary to influenza vaccination was favored. However, as a precautionary measure, labetalol was switched to nifedipine 30 mg on day 22 after collaborating with obstetricians and maternal-fetal medicine physicians. In addition to supportive measures, the patient was started on intravenous methylprednisolone, hydrocortisone suppositories, clobetasol ointment, triamcinolone ointment, and betamethasone dipropionate ointment. Given the continued evolution of the oral erosions after 3 days of prednisone, etanercept 50 mg was administered subcutaneously. One day after the administration of etanercept, her cutaneous erosions improved, and her oral erosions began to re-epithelialize. Because of the persistent

From the Froedtert Hospital and the Medical College of Wisconsin, Milwaukee.

Funding sources: None.

IRB approval status: Not applicable.

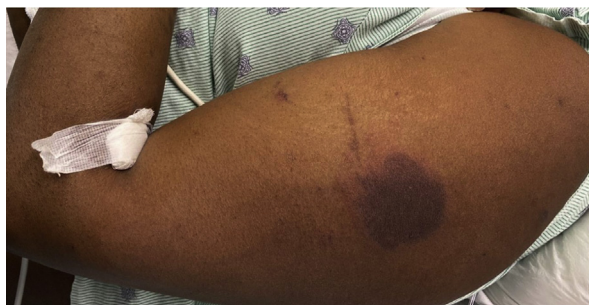Correspondence to: Karolyn A. Wanat, MD, Medical College of Wisconsin, 8701 W. Watertown Plank Road, Milwaukee, WI 53226. E-mail: [kwanat@mcw.edu](mailto:kwanat@mcw.edu).

JAAD Case Reports 2022;23:35-7.

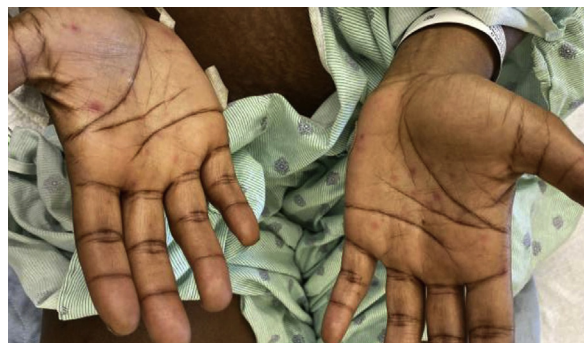2352-5126

© 2022 by the American Academy of Dermatology, Inc. Published by Elsevier, Inc. This is an open access article under the CC BY-NC-ND license (<http://creativecommons.org/licenses/by-nc-nd/4.0/>).

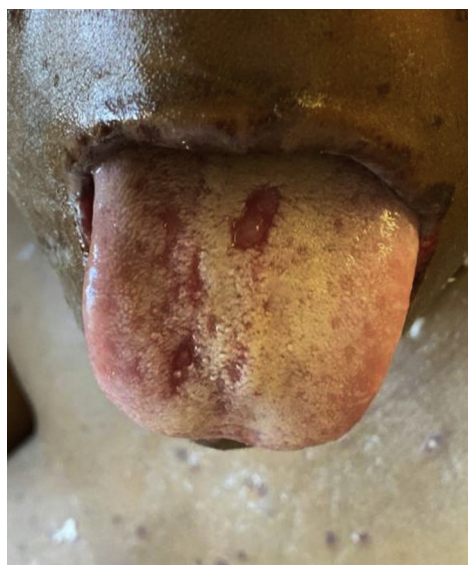<https://doi.org/10.1016/j.jidcr.2022.02.002>



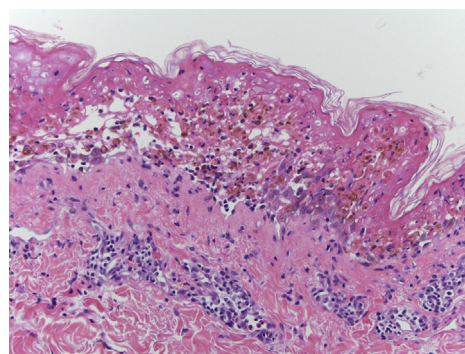
**Fig 1.** A dusky bulla was seen at the site of influenza vaccine administration, favoring the influenza vaccine as the culprit of Stevens-Johnson syndrome.



**Fig 3.** The patient developed erythematous papular erosions on the palmar surfaces of both her hands.



**Fig 2.** Oral mucosal erosions developed, which favored a Stevens-Johnson syndrome diagnosis.



**Fig 4.** Hematoxylin and Eosin staining shows prominent epidermal disruption with full-thickness epidermal necrosis. There was an inflammatory infiltrate of lymphocytes in the dermis, with interface change and scattered eosinophils. There was involvement of follicular epithelium and sebaceous glands.

headache caused by preeclampsia, cesarean section was completed at 31 weeks, without complications. She was discharged on day 26 of hospitalization. At the 1-week outpatient dermatology follow-up, her mucosal and cutaneous erosions were healed with residual postinflammatory hyperpigmentation.

## DISCUSSION

Vaccines, particularly the preservative-free influenza vaccine, have rarely been implicated in SJS.<sup>1</sup> Specifically, influenza vaccine has been reported twice as the immediately preceding cause of SJS; one of which was in a 24-year-old female and the other in an 82-year-old male in 2020.<sup>1</sup> In our patient, the presence of the large dusky bulla at the site of injection favored the influenza vaccine as the most likely culprit for development of SJS. The increased labetalol dosage was also considered as a possible etiology; however, this

seems less likely given the time between medication administration and the localized presentation of epidermal plaques. Erythema multiforme major was considered but deemed less likely because of the involvement of 2 mucosal sites, negative herpes simplex virus and mycoplasma pneumoniae cultures, an absence of classic three-zone targetoid lesions, and the extensive epidermal necrosis on histopathology.<sup>2</sup> Although acute syndrome of apoptotic pain-epidermolysis secondary to systemic lupus erythematosus can present with symptoms similar to those of SJS, the fulminant presentation without previous or current symptoms of systemic lupus erythematosus coupled with normal complement levels and inflammatory markers and prompt resolution makes this diagnosis less likely.

The hypothesized pathophysiology of SJS involves cytotoxic T cell killing of keratinocytes.<sup>3</sup> Vaccines induce proliferation of various cytokines (interleukin 1, interleukin 6, and tumor necrosis factor  $\alpha$ ) to mount an immune response against the

antigens within vaccines. These cytokine responses function to activate cytotoxic T cells. Individuals with a predisposition for SJS may mount abnormally high cytokine responses to a vaccine or may have heightened sensitivity to a normal cytokine response.<sup>3</sup>

Furthermore, this case highlights the challenges of managing SJS in pregnant women. Because reversing the effects of the vaccine was not possible, therapeutic considerations had to account for both the patient's pregnancy and her preeclampsia. Therapeutic decisions were made collaboratively with obstetricians and maternal-fetal medicine physicians. Specifically, cyclosporine was excluded from consideration because of its potential to aggravate the preeclampsia. Additionally, although intravenous immune globulin is considered safe to use in pregnancy, the excess volume load would likely have exacerbated the patient's blood pressure and worsened her pregnancy outcomes. Although oral steroids have been implicated in small-for-gestational age and low-birthweight neonates, the benefits of slowing the progression of a potentially life-threatening dermatosis outweighed the risks of short-term use. However, as the patient's condition worsened, etanercept was administered, and this provided substantial improvement. Etanercept, which is a pregnancy category B drug, has been an emerging treatment in the therapeutic armamentarium of SJS.<sup>4</sup> Although no randomized controlled trials exist for its use during pregnancy, it has a short half-life, and studies demonstrate that there is low transplacental transfer of etanercept in the third trimester<sup>5</sup>; however, there are no published data regarding its use for the treatment of SJS in pregnant patients.<sup>6</sup>

This case highlights several significant considerations for dermatologists. First, it highlighted the importance of clinicopathologic correlation in determining the best diagnosis for a patient. In this particular case, a thorough medication and vaccine history and nuances in the physical examination helped confirm the diagnosis. Further, multidisciplinary management with other medical specialists can help improve care for patients with SJS who have significant comorbidities or are pregnant. Lastly, given that the therapeutic modalities used to treat SJS are broad, tailoring treatment based on patient status and medical conditions is paramount.

#### Conflicts of interest

None disclosed.

#### REFERENCES

1. Tong J, Chan J. Stevens-Johnson syndrome due to influenza vaccination. *Cureus*. 2020;12(7):e9405.
2. Schwartz RA, McDonough PH, Lee BW. Toxic epidermal necrolysis: part II. Prognosis, sequelae, diagnosis, differential diagnosis, prevention, and treatment. *J Am Acad Dermatol*. 2013;69(2):187.e1-187.e16.
3. Ball R, Ball LK, Wise RP, Braun MM, Beeler JA, Salive ME, the VAERS Working Group. Stevens-Johnson syndrome and toxic epidermal necrolysis after vaccination: reports to the vaccine adverse event reporting system. *Pediatr Infect Dis J*. 2001;20(2):219-223.
4. Wang CW, Yang LY, Chen CB, et al. Randomized, controlled trial of TNF- $\alpha$  antagonist in CTL-mediated severe cutaneous adverse reactions. *J Clin Invest*. 2018;128(3):985-996.
5. Förger F. Treatment with biologics during pregnancy in patients with rheumatic diseases. *Reumatologia*. 2017;55(2):57-58.
6. Sharma AN, Hedayati B, Mesinkovska NA, Worswick S. Stevens-Johnson syndrome and toxic epidermal necrolysis in pregnant patients: a systematic review. *Int J Womens Dermatol*. 2020;6(4):239-247.