

Foreign body removed using curette and retrieval net after tracheostomy

Sir,

A 74-year-old man was transported by emergency services due to head and neck trauma. He had obvious facial soft-tissue injuries, and teeth were broken. Because the patient had oral bleeding, we intubated the patient for airway management with a tracheal tube. The patient was diagnosed with a right Le Fort type II fracture, a left Le Fort type III fracture, and a cervical vertebral fracture at C2 and subarachnoid hemorrhage and was admitted to our hospital. The patient was fixed with a neck collar and ventilated. Two days after admission, chest computed tomography revealed a calcified foreign body with a short diameter of 8.0 mm in the right lower lobe bronchus with distal lung consolidation [Figure 1a-c]. The patient had no fever and no respiratory failure. Bronchoscopy through a tracheal tube showed that a broken tooth was present at the entrance to the right lower bronchus [Figure 2a]. However, the size of the object was too large to remove through the tracheal tube. Because the patient needed ventilator management for the treatment of facial fractures, a tracheostomy was scheduled. After the tracheostomy under general anesthesia, it was decided to remove the broken tooth with a flexible bronchoscope (OLYMPUS BF-260, Olympus, Tokyo, Japan). A tracheostomy tube was inserted, and bronchoscopy was performed through the tube. The forceps, a wire basket and a Fogarty balloon catheter could not remove. The tooth was scraped out

with a curette [Figure 2b], and it was removed using a retrieval net (OLYMPUS 00711191) [Figure 2c]. There was no granulation or bleeding at the right lower bronchus after removal of the broken tooth [Figure 2d].

There are various risk factors for foreign body aspiration. If a long period from aspiration passes, granulation tissue forms easily. Furthermore, because the lining mucosa may be traumatized, or airway obstruction, atelectasis, bronchiectasis, obstructive pneumonia, or lung abscess may occur, it is important to diagnose foreign body aspiration quickly and remove the object immediately.^[1] In the present case, it took 7 days to remove the airway foreign body, and there was no granulation. For the treatment of airway foreign bodies, removal with a flexible bronchoscope is the first choice. A curette, forceps, wire basket, a Fogarty balloon catheter, and a retrieval net are frequently used to remove such objects. In this case, the tooth could not be removed with grasping forceps, a wire basket, and a Fogarty balloon catheter. A curette was used to scrape out the tooth, and it could be removed with a retrieval net. A retrieval net is used for large objects

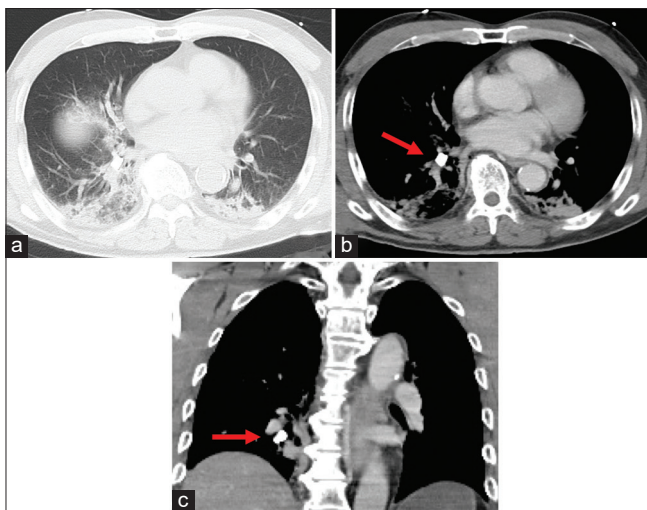


Figure 1: (a) Lung consolidation in bilateral lower lobes. (b and c) A calcified foreign body in the right lower bronchus (red arrow)

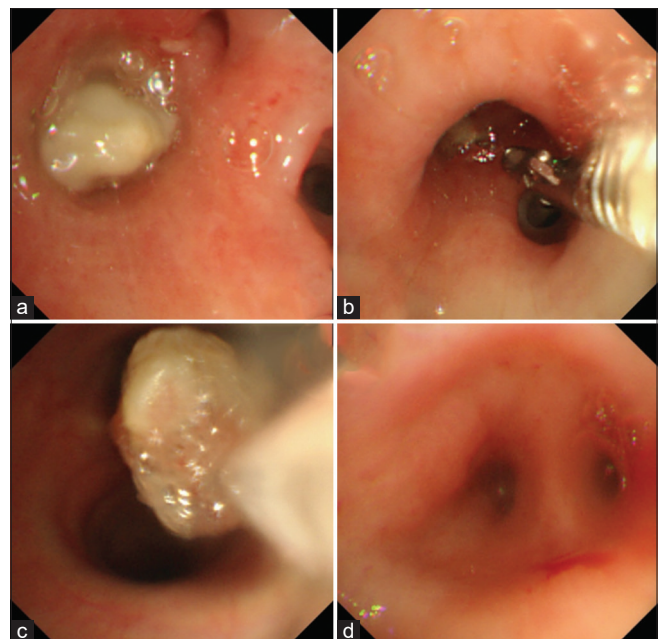


Figure 2: (a) A broken tooth with the broken surface facing up in the entrance to the right lower bronchus. (b) Dislodging the tooth with a curette. (c) Removal with a retrieval net. (d) After removal, there is no granulation or bleeding

and those that are difficult to trap with a wire basket, and a curette is used to assist them.^[2,3] In some cases, a foreign body is too large to remove through a tracheal tube.^[4] Kim *et al.* reported a method of removing an object after tracheostomy.^[5] However, in the present case, general anesthesia was necessary to perform a tracheostomy safely, because the patient had difficulty with neck extension. Furthermore, it was necessary to remove the foreign body after tracheostomy, because the object was too large to pass through the tracheal tube. Because of the above reasons, it was decided to remove it using a flexible bronchoscope under general anesthesia. Although there are not many patients with airway foreign bodies, it is important to consider an excision method and the timing based on each patient's clinical condition. To the best of our knowledge, there have been few reports of removal of an aspirated broken tooth using a curette and a retrieval net after tracheostomy in a patient with tracheal intubation after trauma. One can assume that the present case is extremely rare, but an airway foreign body should not be overlooked, because it requires appropriate treatment.

CONCLUSION

A case in which a broken tooth was aspirated after head and neck trauma, and it was removed using a flexible bronchoscope after tracheostomy was presented. In trauma patients, we should consider the possibility of the presence of airway foreign bodies. Although a flexible bronchoscope is useful for removing objects in the lower bronchus, it is important to select an appropriate removal method and timing according to the type and size of the foreign body and the general condition of the patient.

Financial support and sponsorship

Nil.

Conflicts of interest

There are no conflicts of interest.

**Kazuaki Nishiki, Yoko Ishige, Yasutaka Kawasaki,
Shiro Mizuno**

Department of Respiratory Medicine, Kanazawa Medical University, Daigaku, Uchinada-Machi, Kahoku-Gun, Ishikawa, Japan.

E-mail: kazuaki@kanazawa-med.ac.jp

Submitted: 10-Dec-2020 Accepted: 04-Jan-2021

Published: 02-Mar-2021

REFERENCES

1. Dong YC, Zhou GW, Bai C, Huang HD, Sun QY, Huang Y, *et al.* Removal of tracheobronchial foreign bodies in adults using a flexible bronchoscope: Experience with 200 cases in China. *Intern Med* 2012;51:2515-9.
2. Rafanan AL, Mehta AC. Adult airway foreign body removal. What's new? *Clin Chest Med* 2001;22:319-30.
3. Hewlett JC, Rickman OB, Lentz RJ, Prakash UB, Maldonado F. Foreign body aspiration in adult airways: Therapeutic approach. *J Thorac Dis* 2017;9:3398-409.
4. Zhang M, Zhou GJ, Zhao S, Yang JX, Lu X, Gan JX, *et al.* Delayed diagnosis of tooth aspiration in three multiple trauma patients with mechanical ventilation. *Crit Care* 2011;15:424.
5. Kim DW, Jang JY, Shim H, Jung JY, Kim EY, Nam W, *et al.* Removal of aspirated teeth in a multiple trauma patient, using fiberoptic bronchoscopy with simultaneous tracheostomy: Review of 2 cases. *Respir Care* 2014;59:e1-4.

This is an open access journal, and articles are distributed under the terms of the Creative Commons Attribution-NonCommercial-ShareAlike 4.0 License, which allows others to remix, tweak, and build upon the work non-commercially, as long as appropriate credit is given and the new creations are licensed under the identical terms.

Access this article online	
Quick Response Code: 	Website: www.lungindia.com
	DOI: 10.4103/lungindia.lungindia_957_20

How to cite this article: Nishiki K, Ishige Y, Kawasaki Y, Mizuno S. Foreign body removed using curette and retrieval net after tracheostomy. *Lung India* 2021;38:199-200.

© 2021 Indian Chest Society | Published by Wolters Kluwer - Medknow