

Addison's Disease Caused by Tuberculosis with Atypical Hyperpigmentation and Active Pulmonary Tuberculosis

Hiroki Namikawa¹, Yasuhiko Takemoto¹, Shigeto Kainuma¹, Sakurako Umeda¹, Ayako Makuuchi¹, Kazuo Fukumoto¹, Masanori Kobayashi¹, Shigeki Kinuhata¹, Yoshihiro Isaka², Hiromitsu Toyoda¹, Noriko Kamata¹, Yoshihiro Tochino¹, Yoshikazu Hiura², Mina Morimura¹ and Taichi Shuto¹

Abstract

We herein report a case of Addison's disease caused by tuberculosis characterized by atypical hyperpigmentation, noted as exacerbation of the pigmentation of freckles and the occurrence of new freckles, that was diagnosed in the presence of active pulmonary tuberculosis. The clinical condition of the patient was markedly ameliorated by the administration of hydrocortisone and anti-tuberculosis agents. When exacerbation of the pigmentation of the freckles and/or the occurrence of new freckles are noted, Addison's disease should be considered as part of the differential diagnosis. In addition, the presence of active tuberculosis needs to be assumed whenever we treat patients with Addison's disease caused by tuberculosis, despite its rarity.

Key words: Addison's disease, adrenal insufficiency, pulmonary tuberculosis, active tuberculosis, hyperpigmentation, freckles

(Intern Med 56: 1843-1847, 2017)

(DOI: 10.2169/internalmedicine.56.7976)

Introduction

Addison's disease is a rare endocrinal disorder that was first described by Thomas Addison in 1855 (1). The two most common causes of Addison's disease are autoimmune adrenalitis and tuberculosis (2). As a result of the recent substantial reduction in the incidence of tuberculosis, the number of cases of Addison's disease caused by tuberculosis has also significantly decreased (3).

Generalized cutaneous hyperpigmentation is a characteristic physical finding of Addison's disease (4). Although generalized hyperpigmentation is observed on sun-exposed skin and over pressure areas, such as the elbows and knees, in most cases (5), the darkening of freckles and/or the emergence of new freckles are rarely seen. In addition, tuberculosis is inactive in the majority of patients with Addison's disease.

We herein report a rare case involving a 48-year-old man

with Addison's disease caused by tuberculosis, presenting with atypical hyperpigmentation and active pulmonary tuberculosis.

Case Report

A 48-year-old man was referred to our hospital for general malaise and anorexia. His symptoms had appeared approximately four months prior to referral. He showed freckles on his face and trunk that had been darkening every day, the occurrence of new freckles, and weight loss of 14 kg. The patient had no particular remarkable medical history or known allergies. He was not taking any medications, did not smoke or drink alcohol, and did not use any illicit drugs. His father had diabetes mellitus, and his mother had gastric cancer.

On a physical examination, the patient's weight was 56 kg, and his height was 180 cm. His blood pressure was 84/56 mmHg; pulse, 98 beats per minute; body temperature,

¹Department of Medical Education and General Practice, Osaka City University, Graduate School of Medicine, Japan and ²Department of Diabetes, Osaka City Juso Hospital, Japan

Received for publication July 12, 2016; Accepted for publication January 16, 2017

Correspondence to Dr. Yasuhiko Takemoto, yatakemoto@med.osaka-cu.ac.jp

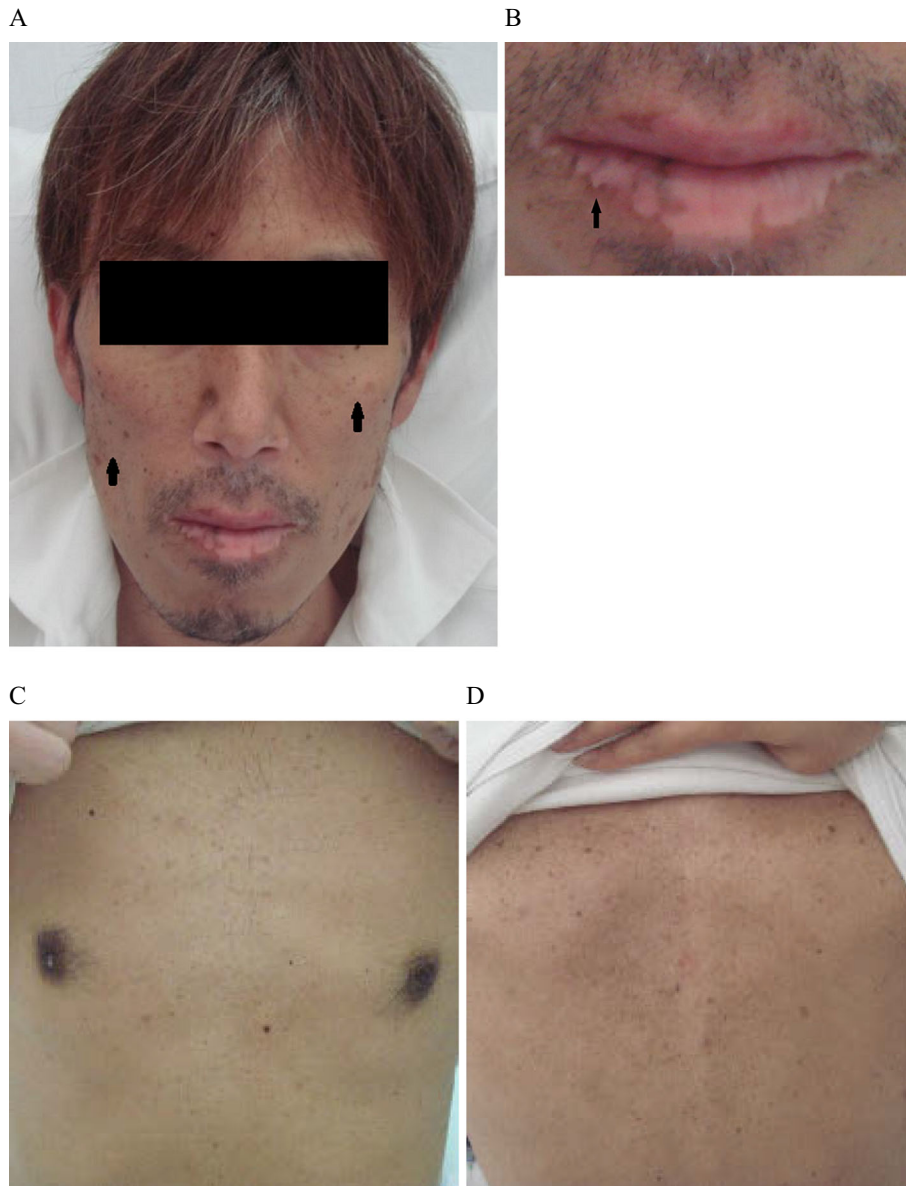


Figure 1. The skin examination findings on admission. (A, B, C, D) Brown hyperpigmentation on the face (black arrows), lips (black arrow), and trunk.

36.4°C; respiratory rate, 16 breaths per minute; and oxygen saturation level, 99% while breathing ambient air. A skin examination revealed brown freckles mainly on his face, lip, and trunk (Fig. 1). On the neck, back of the hands, elbows, and knees, the hyperpigmentation was unremarkable. His physical examination findings were otherwise normal.

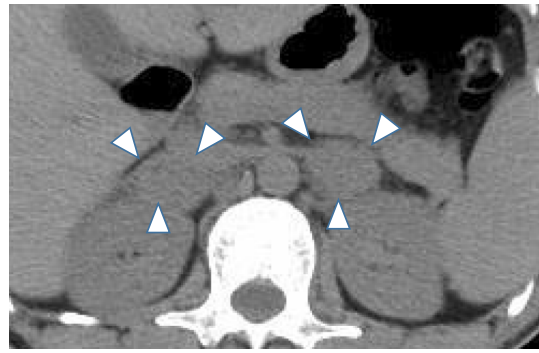
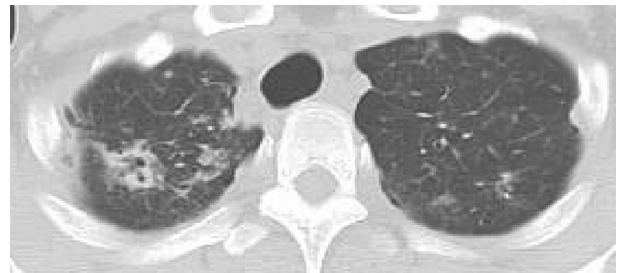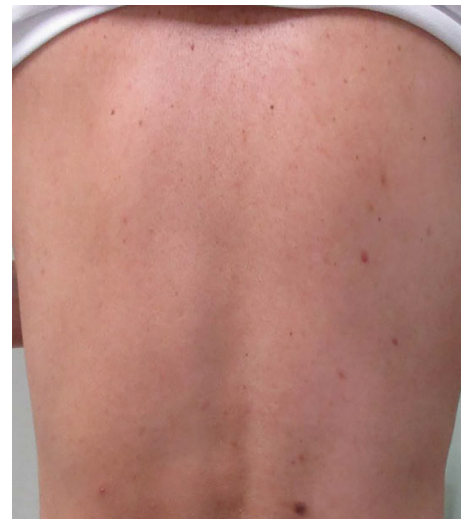Laboratory data showed a white blood cell count of 8,200/ μ L, hemoglobin level of 14 g/dL, platelet count of 289,000/ μ L, C-reactive protein level of 2.35 mg/dL, albumin level of 3.7 g/dL, creatinine level of 0.79 mg/dL, sodium level of 121 mEq/L, potassium level of 4.9 mEq/L, fasting blood glucose level of 89 mg/dL, free thyroxine level of 1.47 ng/dL, thyroid stimulating hormone level of 2.4 μ IU/mL, cortisol level of 1.0 μ g/mL (normal range, 4.0-19.3 μ g/mL), and adrenocorticotropic hormone (ACTH) level of 1,140 pg/mL (normal range, 7.2-63.3 pg/mL). Other test results are shown in Table.

Adrenal insufficiency was suspected on the basis of these clinical findings and laboratory data, and abdominal ultrasonography and non-contrast computed tomography (CT) were immediately performed to examine the patient's adrenal glands; these showed enlargement of the bilateral adrenal glands (Fig. 2). Chest radiography and non-contrast chest CT revealed multiple nodular shadows with cavitation in the fields of both lungs (Fig. 3). Addison's disease caused by tuberculosis and active pulmonary tuberculosis were suspected, and the patient was admitted to a quarantine room on the same day he visited our hospital.

Intravenous saline and oral hydrocortisone (20 mg/day) were administered to treat the hyponatremia and adrenal insufficiency, resulting in the marked amelioration of his symptoms, such as general malaise and anorexia, and hyponatremia. Although the first and second sputum smears yielded negative results, a third sputum smear was positive

Table. Laboratory Data on Admission.

Variable	Value on admission
White blood cell count (/ μ L)	8,200
Differential count (%)	
Neutrophils	53
Lymphocytes	28
Monocytes	10
Eosinophils	5
Basophils	4
Hemoglobin (g/dL)	14.0
Hematocrit (%)	40.2
Platelet count (/ μ L)	289,000
C-reactive protein (mg/dL)	2.35
Total protein (g/dL)	6.8
Albumin (g/dL)	3.7
Blood urea nitrogen (mg/dL)	25
Creatinine (mg/dL)	0.79
Sodium (mEq/L)	121
Potassium (mEq/L)	4.9
Chloride (mEq/L)	92
Calcium (mg/dL)	9.5
Total bilirubin (mg/dL)	0.6
Direct bilirubin (mg/dL)	0.3
Aspartate aminotransferase (U/L)	38
Alanine aminotransferase (U/L)	38
Alkaline phosphatase (U/L)	370
Lactate dehydrogenase (U/L)	153
Fasting blood glucose (mg/dL)	89
Free thyroxine (ng/dL)	1.47
Thyroid-stimulating hormone (μ IU/mL)	2.4
Cortisol (μ g/mL)	1.0
Adrenocorticotrophic hormone (pg/mL)	1,140

**Figure 2. Non-contrast abdominal computed tomography image. Enlargement of the bilateral adrenal glands without calcification was noted (white arrowheads).****Figure 3. Non-contrast chest computed tomography image. Numerous centrilobular nodules with at least one small cavity were observed in both apical lung fields.****Figure 4. The skin examination findings after the treatment.**

for *Mycobacterium*. Furthermore, a polymerase chain reaction (PCR) analysis of the third sputum sample showed *Mycobacterium tuberculosis* complex. In addition, a PCR analysis of his gastric juice also demonstrated *Mycobacterium tuberculosis* complex. The patient was therefore ultimately diagnosed with Addison's disease caused by tuberculosis and active pulmonary tuberculosis.

He was transferred to a tuberculosis hospital with a specialized quarantine ward and room for tuberculosis treatment, and a combination of four drugs (isoniazid, rifampicin, pyrazinamide, and ethambutol) was administered in addition to hydrocortisone. After the treatment, his hyperpigmentation was markedly ameliorated (Fig. 4), and he was discharged after one month of hospitalization. The patient has demonstrated no exacerbation of the hyperpigmentation or recurrence of Addison's disease caused by tuberculosis and/or active pulmonary tuberculosis since he was discharged. One year after treatment initiation, his laboratory data showed the following: sodium level, 140 mEq/L; potassium level, 5.0 mEq/L; chloride level, 102 mEq/L; and ACTH level, 454.6 pg/mL. Further, non-contrast abdominal CT revealed that the transverse diameter of the right adrenal gland had decreased from 34 mm to 29 mm, while that of

the left adrenal gland had decreased from 27 mm to 22 mm.

Discussion

Addison's disease is a rare disease that affects 1 in 100,000 people (5). Although autoimmune diseases account for 70-90% of the underlying conditions of Addison's disease, tuberculosis constitutes only 7-20% of cases (6), and the incidence of Addison's disease has been decreasing along with the decline of tuberculosis cases. The interval be-

tween tuberculosis and the onset of Addison's disease averages 32 ± 15 years, and Addison's disease is usually evoked very indolently by tuberculosis (3). Therefore, most cases of tuberculosis are inactive when Addison's disease develops. Considering these data, the present case (Addison's disease caused by tuberculosis with active tuberculosis) is relatively rare. Furthermore, a previous report found that none of the 94 Addison's disease patients without a clinical history of tuberculosis had active tuberculosis (7). Therefore, to our knowledge, our patient represents the first case of Addison's disease with active tuberculosis and no clinical history of tuberculosis. Although the presence of active tuberculosis is rare in terms of the statistics for Addison's disease caused by tuberculosis, it needs to be considered whenever we treat patients with Addison's disease caused by tuberculosis.

In addition to the common clinical features of Addison's disease, such as chronic malaise, fatigue, weakness, anorexia, and weight loss (8), another characteristic physical finding is hyperpigmentation. Hyperpigmentation is related to ACTH melanogenesis (9), with typical hyperpigmentation being generalized, homogeneous, brown, and conspicuously observed in areas exposed to the sun, such as the face, neck, and back of the hands, or areas exposed to chronic pressure or friction such as the elbows and knees. The present patient demonstrated freckles on his face and trunk that had darkened, and new freckles had appeared. Although the patient did not show hyperpigmentation at the predilection sites in Addison's disease and was hence considered atypical, his hyperpigmentation disappeared with the alleviation of adrenal insufficiency and was thus nonetheless considered related to his Addison's disease. To our knowledge, this patient represents the first case characterized by such an unconventional pattern of hyperpigmentation, indicating that Addison's disease needs to be considered when darkening of freckles and/or the emergence of new freckles are noticed.

Thorn et al. reported eosinophilia to be a marker of adrenal insufficiency (10). In addition, Hills et al. suggested that eosinophilia associated with Addison's disease was probably due to the low levels of circulating steroids (11). However, a previous study reported the eosinophil count to be greater than $500/\text{mm}^3$ in less than 20% of patients with adrenal insufficiency (12). Eosinophilia was not noted in the present case either; thus, eosinophilia will not necessarily be observed in all patients with Addison's disease. Further investigations are necessary to determine the differences between Addison patients with and without eosinophilia.

The serum cortisol concentration, serum ACTH concentration, and rapid ACTH stimulation test are important for the diagnosis of adrenal insufficiency. The present patient demonstrated a significant decrease in the cortisol level and an increase in the ACTH level, meeting the diagnostic criteria for Addison's disease without the rapid ACTH stimulation test. Severe adrenal cortical insufficiency is characterized by vomiting, a fever, disturbance of consciousness, and shock and can be life-threatening if immediate steroid replacement therapy is not performed. In the present case, the patient

complained of general malaise with low blood pressure and marked weight loss and was considered to have severe adrenal cortical insufficiency. Therefore, we prioritized steroid replacement therapy to restore the adrenal function, despite the exacerbation of pulmonary tuberculosis.

Rifampicin is reported to shorten the half-life of steroids and impair the therapeutic response to steroid treatment (13). However, we avoided reducing the rifampicin dosage or discontinuing rifampicin during the treatment of active pulmonary tuberculosis. We also avoided increasing the dose of the steroid medication, considering the progression of active pulmonary tuberculosis and the stable condition of the patient, who had no symptoms suggestive of progressive adrenal insufficiency and showed amelioration of his hyperpigmentation. These findings prompted us to maintain the dosage of rifampicin and steroids, which admittedly might have contributed to the slow response of the ACTH level to the steroid therapy.

In conclusion, we herein reported a case of Addison's disease caused by tuberculosis, accompanied by atypical hyperpigmentation and active pulmonary tuberculosis. To our knowledge, this is the first report of a patient with Addison's disease with presently active tuberculosis and no clinical history of tuberculosis who demonstrated exacerbation of the pigmentation of freckles and the occurrence of new freckles along with the deterioration of Addison's disease. When progressive darkening of freckles and/or the emergence of freckles are noticed, Addison's disease should be considered as part of the differential diagnosis. In addition, the presence of active tuberculosis needs to be considered whenever we treat patients with Addison's disease caused by tuberculosis, despite its rarity.

The authors state that they have no Conflict of Interest (COI).

References

1. Hiatt JR, Hiatt N. The conquest of Addison's disease. *Am J Surg* **174**: 280-283, 1997.
2. Choudhary S, Alam A, Dewan V, et al. An unusual presentation of Addison's disease - a case report. *Clin Pediatr Endocrinol* **20**: 57-60, 2011.
3. Nomura K, Demura H, Saruta T. Addison's disease in Japan: characteristics and changes revealed in a nationwide survey. *Intern Med* **33**: 602-606, 1994.
4. Barnett AH, Espiner EA, Donald RA. Patients presenting with Addison's disease need not be pigmented. *Postgrad Med J* **58**: 690, 1982.
5. Sarkar SB, Sarkar S, Ghosh S, et al. Addison's disease. *Contemp Clin Dent* **3**: 484-486, 2012.
6. Nagler M, Müller B, Briner V, et al. Severe hyperkalemia and bilateral adrenal metastasis. *J Oncol* **2009**: 831979, 2009.
7. Sanford JP, Favour CB. The interrelationships between Addison's disease and active tuberculosis: a review of 125 cases of Addison's disease. *Ann Intern Med* **45**: 56-72, 1956.
8. Burke CW. Adrenocortical insufficiency. *Clin Endocrinol Metab* **14**: 947, 1985.
9. Lanza A, Heulfe I, Perillo L, et al. Oral manifestation as a sign of Addison's disease: a brief reappraisal. *Open Dermatol J* **3**: 3-6,

- 2009.
10. Thorn GW, Forsham PH, Prunty FTG, et al. A test for adrenal cortical insufficiency; the response to pituitary adrenocorticotrophic hormone. *J Am Med Assoc* **137**: 1005-1009, 1948.
11. Hills AG, Forsham PH, Finch CA. Changes in circulating leukocytes induced by the administration of pituitary adrenocorticotrophic hormone in man. *Blood* **3**: 755-768, 1948.
12. Spry C. Eosinophilia in Addison's disease. *Yale J Biol Med* **49**: 411-413, 1976.
13. Park BK, Breckenridge AM. Clinical implications of enzyme induction and enzyme inhibition. *Clin Pharmacokinet* **6**: 1-24, 1981.

The Internal Medicine is an Open Access article distributed under the Creative Commons Attribution-NonCommercial-NoDerivatives 4.0 International License. To view the details of this license, please visit (<https://creativecommons.org/licenses/by-nc-nd/4.0/>).

© 2017 The Japanese Society of Internal Medicine
<http://www.naika.or.jp/imonline/index.html>