

Unusual mechanism of complete atrioventricular block following atrial flutter ablation



Frederic Georger, MD,^{*} Luc De Roy, MD,[†] Camelia Sorea,^{*} Jean-Paul Albenque, MD,[‡] Serge Boveda, MD,[‡] Bernard Belhassen, MD[§]

From the ^{*}Centre Hospitalier de Beziers, Beziers, France, [†]Cardiology Arrhythmology, Université Catholique de Louvain, Centre Hospitalier Universitaire de Mont-Godinne, Yvoir, Belgium, [‡]Clinique Pasteur, Département de Rythmologie, Toulouse, France, and [§]Tel Aviv Sourasky Medical Center, Tel Aviv, Israel.

Introduction

Catheter ablation of the cavotricuspid isthmus (CTI) using radiofrequency energy is currently the first line therapy for symptomatic right atrial flutter (AFL).¹ CTI ablation is associated with a 92%–97% success rate and a very low complication rate (<1%) including atrioventricular block (AVB) (0.4%).² We report an unusual case of complete AVB occurring after AFL interruption by ablation.

Case report

A 74-year-old man with a history of hypertension and no obvious heart disease was referred for electrophysiological evaluation of recurrent syncope. The syncope occurred 1 month after another hospitalization that was due to transient ischemic attack. During the prior hospitalization, the electrocardiogram (ECG) showed sinus rhythm with a normal PR interval (0.18 second), a complete right bundle branch block, and a normal QRS axis. A typical AFL occurred later and was converted to sinus rhythm with treatment with oral amiodarone, which was replaced afterward by slow-release flecainide (200 mg/d). While undergoing treatment with the latter medication, the patient experienced 2 syncopal episodes, which prompted the present hospitalization. An electrophysiological study for assessing atrioventricular (AV) conduction and CTI ablation was performed.

During the study, the patient exhibited multiple bouts of atrial fibrillation at ventricular rates of about 65 beats per minute. Intravenous flecainide (1 mg/kg, 10 mg/min) was

given to control this arrhythmia. Sustained typical counter-clockwise AFL at a cycle length of 254 milliseconds then developed and was associated with a 2:1 AV response (heart rate 118 beats per minute). The AFL terminated during radiofrequency energy delivery in the CTI at the 6-o'clock position of the tricuspid annulus, which was defined in a 45° left anterior fluoroscopic view. As AFL stopped, a 15-second asystole due to complete AVB occurred after a short sinus pause: this situation required a brief external cardiac massage before ventricular pacing could be available (Figure 1).

Immediately after AV conduction resumed, the PR interval was similar to that of baseline. A complete bidirectional CTI block was achieved after additional radiofrequency energy applications. At this step, His bundle activity recording was available and showed a normal HV value (50 milliseconds) with normal intra-Hisian conduction. Coronary sinus pacing at a cycle length of 600 milliseconds was associated with a 1:1 AV relationship. However, at a paced cycle length of 500 milliseconds, a 2:1 infranodal block developed. As pacing was discontinued, after a short sinus pause, a complete infranodal block occurred (Figure 2). Normal AV conduction resumed after a single ventricular paced beat (not shown).

A single atrial extrastimulation (A1-A2 = 400 milliseconds) during atrial pacing (cycle length 600 milliseconds with a 1:1 AV relationship) was blocked below the His deflection. This event was followed by a short sinus pause and complete infranodal AVB (Figure 3). Stable AV conduction resumed after a spontaneous ventricular beat having a left bundle branch block pattern and brief ventricular pacing.

The patient received a dual-chamber pacemaker and did not experience further syncopal episodes.

Discussion

Several possible mechanisms have been suggested to explain the occurrence of complete AVB during CTI ablation: (1) increased vagal tone owing to pain or stimulation of epicardial vagal fibers or ganglia that are dense in the

KEYWORDS Atrial flutter; Atrioventricular block; Cavotricuspid isthmus; Pause-dependent atrioventricular block; Radiofrequency ablation; Tachycardia-dependent atrioventricular block

ABBREVIATIONS AFL = atrial flutter; AV = atrioventricular; AVB = atrioventricular block; CTI = cavotricuspid isthmus; ECG = electrocardiogram (Heart Rhythm Case Reports 2015;1:369–372)

The corresponding author declares no conflict of interest related to the manuscript. **Address reprint requests and correspondence:** Dr Frederic Georger, Centre Hospitalier de Beziers, Service de Cardiologie, 2 rue Valentin Haüy, 34500 Beziers, France. E-mail address: frederic.georger@ch-beziers.fr.

KEY TEACHING POINTS

- Rapid atrioventricular conduction during supraventricular tachycardia may mask a severe underlying atrioventricular conduction disorder. Facing the difficulties encountered in assessing a diagnosis of paroxysmal atrioventricular block (AVB) in clinical practice, we should be aware of this phenomenon, particularly in the presence of syncope and right bundle branch block.
- The combination of syncope, paroxysmal supraventricular tachycardia, and bundle branch block should encourage physicians to consider conducting an electrophysiological study with a detailed analysis of the nodo-Hisian conduction during various atrial and ventricular pacing protocols and drug challenge. Study results may help to unmask a diseased His-Purkinje system. An improper diagnosis attributing to the sole tachycardia a bad tolerance, which would lead to an inadequate therapeutic strategy, could therefore be avoided.
- Several mechanisms can lead to AVB in the setting of ablation, including mechanical or heating injury of the conduction system or ischemic or neurally mediated AVB. A pause-dependent AVB may also be involved and can usually be well recognized by adequate electrophysiological testing with pacing maneuvers.
- The coexistence of tachycardia- and pause-dependent AVB is not incidental and has been observed in various clinical settings and experiments.
- Concomitance between AVB and sinus rhythm acceleration at the time of tachycardia or atrial-pacing termination rules out a vagal mechanism.

isthmus area³; (2) direct injury to the AV node³; (3) acute right coronary artery occlusion⁴; (4) catheter trauma to the infranodal conduction system in patients with preexisting left bundle branch block^{5,6}. To the best of our knowledge, this report is the first to show a case of unexpected complete AVB occurring concomitantly with the termination of AFL during CTI ablation. Our observation of a pause-dependent (previously named phase 4) AVB following isthmus-flutter interruption by ablation discloses an unrecognized mechanism of AVB in this setting.⁶ We were able to reliably reproduce the same phenomenon by pacing maneuvers, and we were able to clearly document the infranodal location of the conduction disturbance.

We speculate that the zone of block is the distal part of the His bundle or the left bundle branch, considering the preexisting right bundle branch block that showed on the basal ECG and the normal His potential and HV value during flecainide infusion.

We demonstrated that initiation of this pause-dependent AVB could be triggered by various pacing maneuvers that allowed the occurrence of sinus pauses. In addition, a tachycardia-dependent (previously named phase 3) AVB was also present, as suggested by the occurrence of rate-dependent block during incremental atrial pacing (from 100 beats per minute to 120 beats per minute).

More than 4 decades ago, Rosenbaum et al⁷ gathered 18 clinical cases of AVB displaying a biphasic time course of refractoriness. During diastole, these cases demonstrated a progressive recovery followed by a gradual loss of excitability, which the investigators called the “bellows-like effect.” Jalife et al⁹ provided experimental arguments, recently emphasized by El-Sherif et al,¹⁰ that questioned the previously established concepts of phase 3 and phase 4 blocks. It is largely accepted that the tachycardia-dependent block—for example, in our case at 500 milliseconds in atrial pacing—is caused by an abnormal prolongation of the refractory period in the diseased His-Purkinje system. However, there is more debate around the pause-dependent block and the role of a spontaneous but abnormally depressed diastolic depolarization current in the diseased automatic cells. Nevertheless, many arguments^{7,9,10} do support the involvement of time-dependent decreased kinetics of a fast depolarizing sodium current in the diseased His-Purkinje system to explain these propagation and excitability abnormalities, independently of a lower take-off potential level. This phenomenon also may explain the crucial absence of an escape rhythm in this rare but certainly underestimated clinical condition.^{8,11} Considering the present clinical history and the electrophysiological properties of flecainide, the flecainide treatment probably helped unmask this conduction disorder through its specific action on sodium channels.

The antegrade conduction was reliably restored by either paced or mechanical or spontaneous ventricular activity. This finding is concordant with the commonly postulated mechanism of block suppression by retrograde activation of the diseased tract with resetting of the diastolic membrane potential.¹²

Conclusion

A rapid 2:1 atrioventricular conduction during AFL may paradoxically mask a severe underlying Purkinje disease. To the best of our knowledge, this case report offers the first description of a concurrent tachycardia and pause-dependent paroxysmal AVB discovered during an isthmus-flutter ablation.

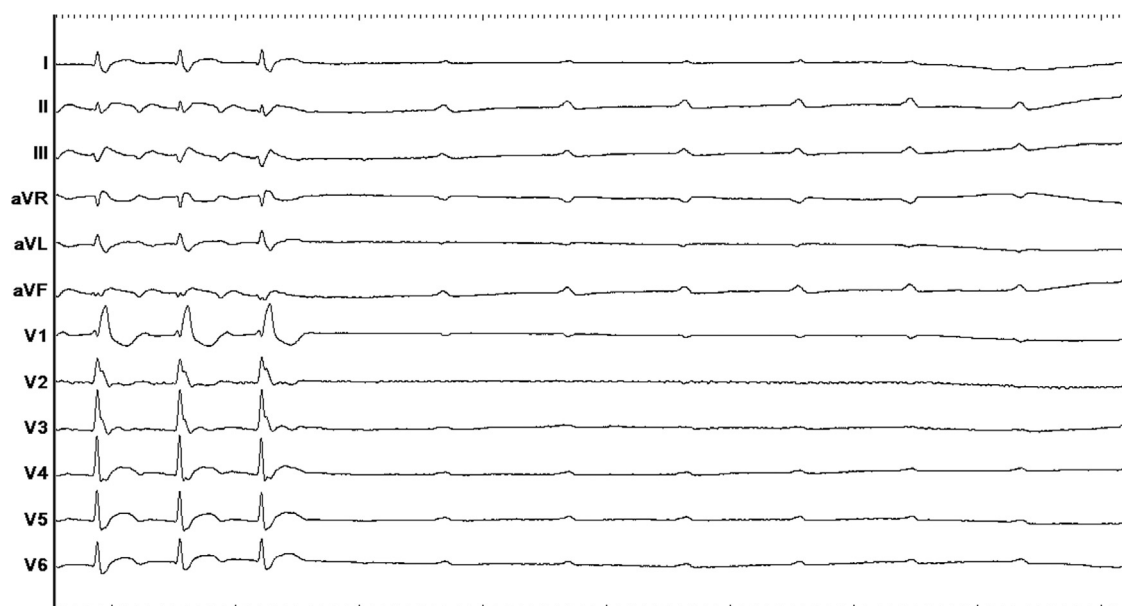


Figure 1 The left part of the electrocardiogram tracing shows typical flutter waves in leads II, III, and aVF conducted in a 2:1 fashion to the ventricles. After interruption of the flutter, a complete atrioventricular block occurs. Following a short pause, the acceleration of sinus rhythm rules out a potential vagal mechanism.

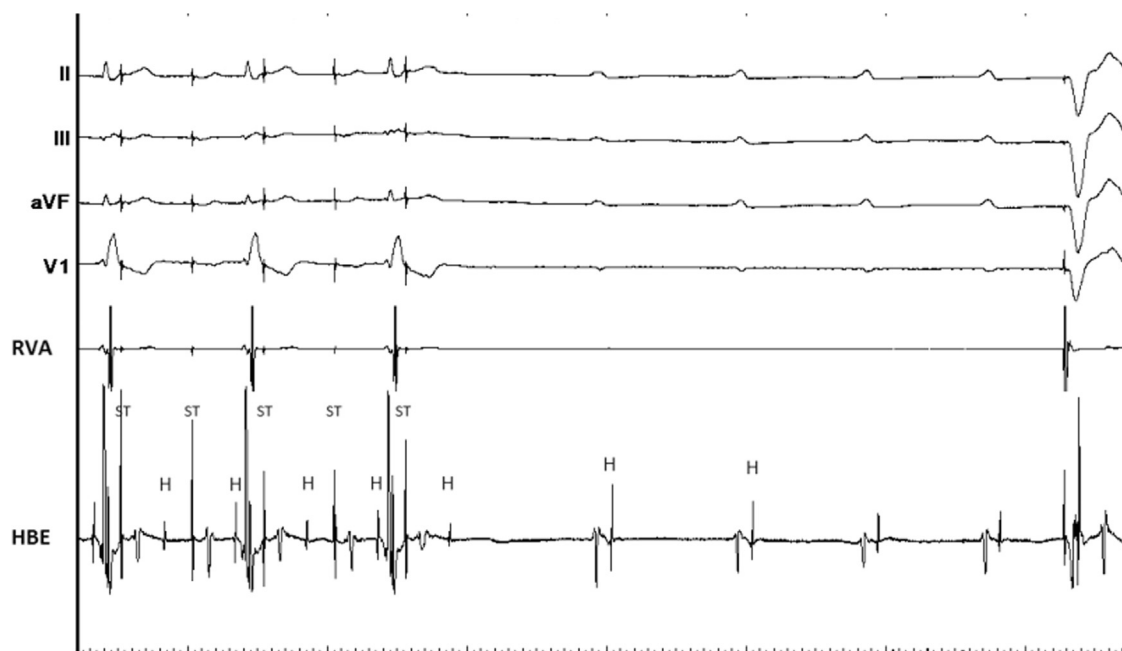


Figure 2 The top electrocardiogram tracings represent ECG, RVA represents a bipolar recording from the right ventricle and HBE recording from another bipolar catheter located close to the His bundle. Coronary sinus pacing at 500 milliseconds was conducted to the ventricles with a 2:1 infranodal block. After the pacing was stopped, we observed a complete infranodal atrioventricular block up to ventricular pacing.

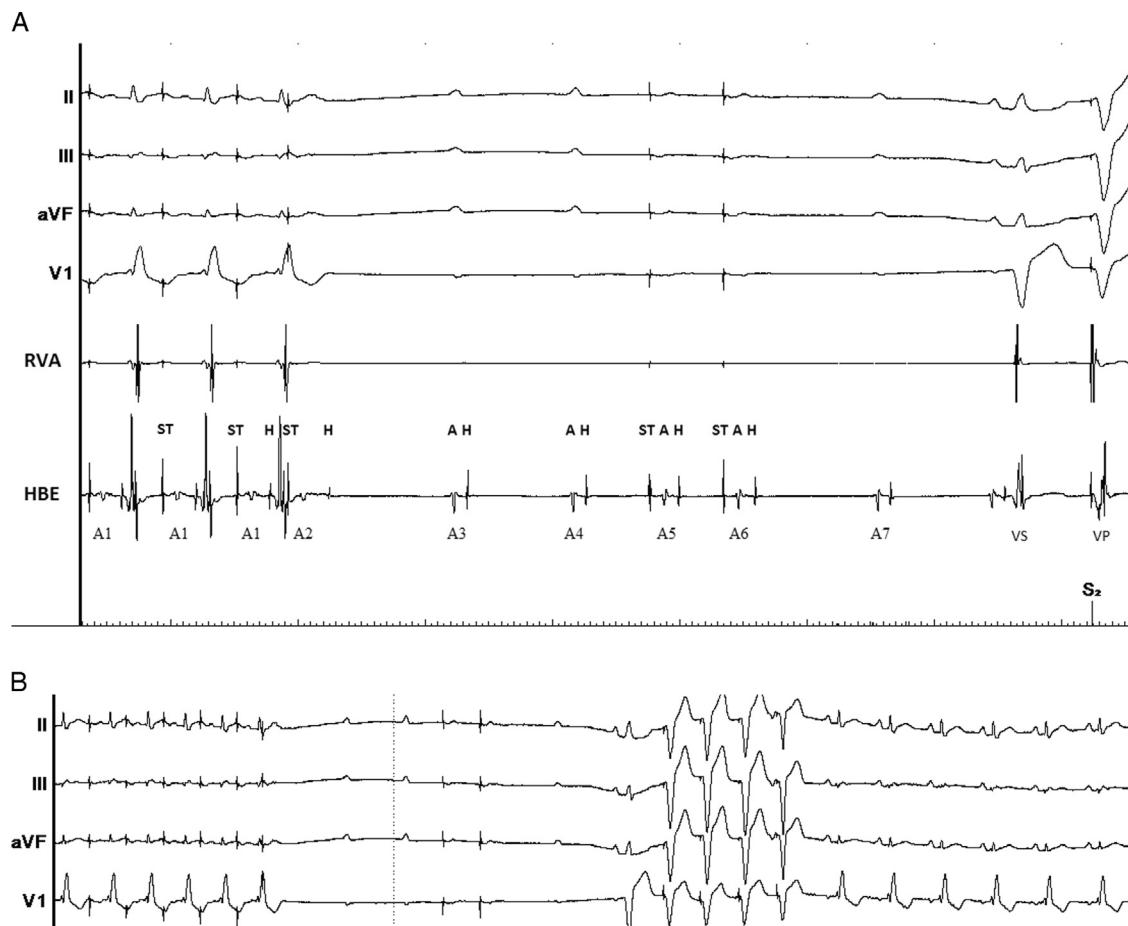


Figure 3 A: The left part of the tracing shows atrial pacing at 600 milliseconds (A1-A1) followed by a 400-millisecond coupled extra stimulus (A2) that blocks after a His deflection. Two sinus beats (A3, A4) that occurred after a short pause as well as 2 atrial-paced extra beats were then blocked in the same fashion (cycle length: 600 milliseconds) (A5, A6). Finally, ventricular conduction was restored after a spontaneous ventricular activity (VS) with a left bundle branch block pattern [probably an escape beat (slightly prolonged HV) originating in or near the right bundle branch] followed by paced ventricular complexes (VP). B: The same strip at a lower speed showing the whole sequence (continued tracing) with restoration of normal AV conduction. Other abbreviations as in Figure 2.

References

1. Blomström-Lundqvist C, Scheinman MM, Aliot EM, et al. ACC/AHA/ESC guidelines for the management of patients with supra ventricular arrhythmias. *Circulation* 2003;108:1871–1909.
2. Spector P, Reynolds MR, Calkins H, Sondhi M, Xu Y, Martin A, Williams CJ, Sledge I. Meta-analysis of ablation of atrial flutter and supraventricular tachycardia. *Am J Cardiol* 2009;104:671–677.
3. Posa E, Skanes AC, Gula LJ, Klein GJ, Yee R, Krahn AD. Unexpected AV block during cavotricuspid isthmus ablation. *Pacing Clin Electrophysiol* 2005;28:980–981.
4. Brembilla-Perrot B, Lemderski Filali M, Beurrier D, Groben L, Cedano J, Abdelaal A, Louis P, Claudon O, De La Chaise AT, Ethévenot G. Complete atrioventricular block during ablation of atrial flutter. *Pacing Clin Electrophysiol* 2010;33:516–519.
5. Stein PD, Mahur VS, Herman MV, Levine HD. Complete heart block induced during cardiac catheterization of patients with pre-existent bundle-branch block. The hazard of bilateral bundle-branch block. *Circulation* 1966;34:783–791.
6. Belhassen B, Glick A, Rosso R, Michowitz Y, Viskin S. Atrioventricular block during radiofrequency catheter ablation of atrial flutter: incidence, mechanism, and clinical implications. *Europace* 2011;13:1009–1014.
7. Rosenbaum MB, Elizari MV, Levi RJ, Nau GJ. Paroxysmal atrioventricular block related to hypopolarization and spontaneous diastolic depolarization. *Chest* 1973;63:678–688.
8. Jalife J, Antzelevitch C, Lamanna V, Moe GK. Rate-dependent changes in excitability of depressed cardiac Purkinje fibers as a mechanism of intermittent bundle branch block. *Circulation* 1983;67:912–922.
9. El-Sherif N, Jalife J. Paroxysmal atrioventricular block: are phase 3 and phase 4 block mechanism or misnomers? *Heart Rhythm* 2009;6:1514–1521.
10. Lee S, Wellens HJJ, Josephson ME. Paroxysmal atrioventricular block. *Heart Rhythm* 2009;6:1229–1234.
11. Brignole M, Menozzi C, Moya A, Garcia-Civera R, Mont L, Alvarez M, Errazquin F, Beiras J, Bottoni N, Donato P. International Study on Syncope of Uncertain Etiology (ISSUE). Mechanism of syncope in patients with bundle branch block and negative electrophysiological test. *Circulation* 2002;104:2045–2050.
12. Rosenbaum MB, Elizari MV, Lazzari JO, Halpern MS, Nau GJ, Levi RJ. The mechanism of intermittent bundle branch block. Relationship to prolonged recovery, hypopolarization and spontaneous diastolic depolarization. *Chest* 1973; 63:666–677.