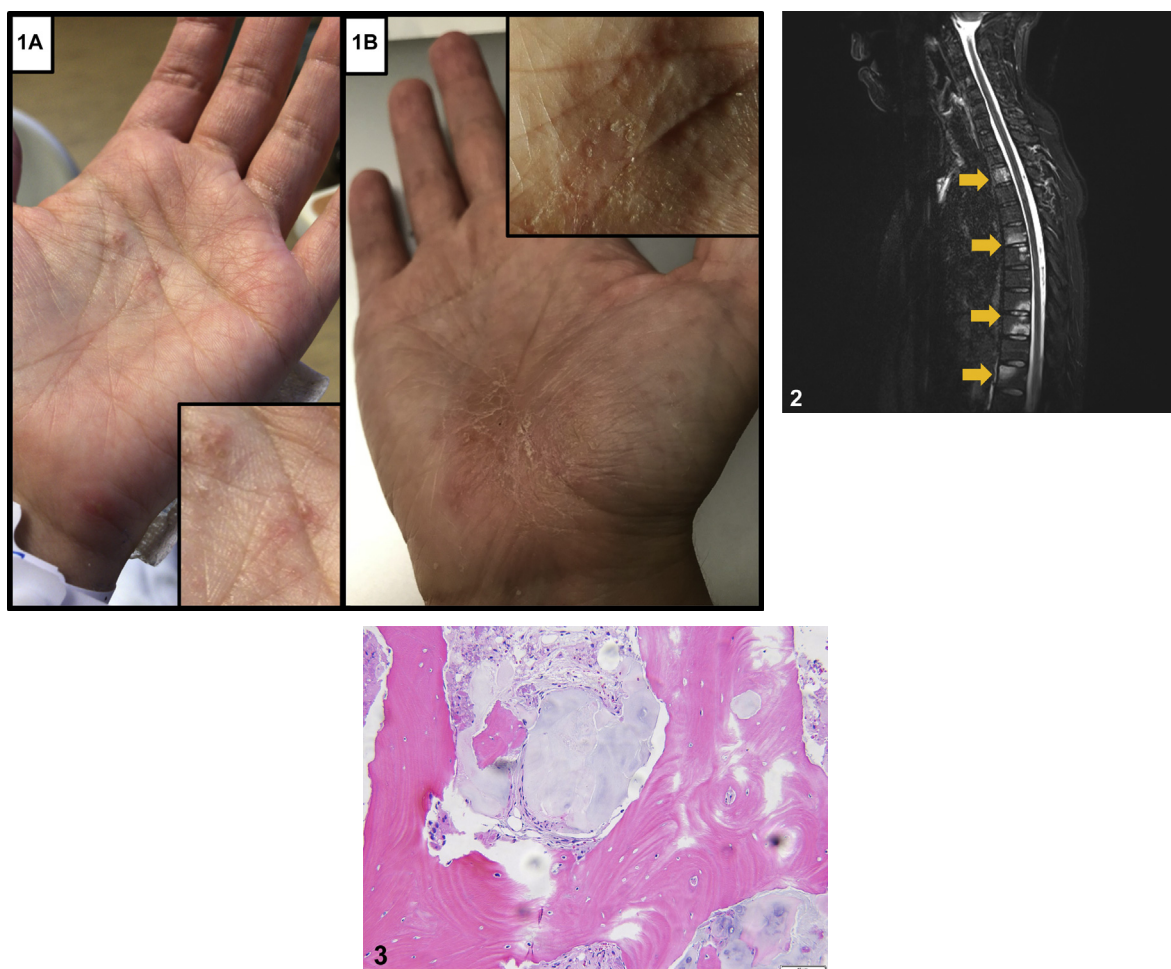


Pustular palm eruption with axial skeleton involvement



Sino Mehrmal, BSN,^a Kory P. Schrom, MD,^b Harib H. Ezaldeen, MD,^b Robert Rothbaum, MD,^b and Gregory R. Delost, DO^b
Glendale, Arizona and Cleveland, Ohio

Key words: chronic recurrent multifocal osteomyelitis; SAPHO syndrome.



From Midwestern University, Arizona College of Osteopathic Medicine^a and the Department of Dermatology, University Hospitals Cleveland Medical Center.^b

Funding sources: None.

Conflicts of interest: None disclosed.

Correspondence to: Gregory R. Delost, DO, Department of Dermatology, UH Cleveland Medical Center, 11100 Euclid Avenue, Lakeside 3500, Cleveland, OH 44106. E-mail: Gregory.Delost@UHhospitals.org; gregorydelost@gmail.com.

JAAD Case Reports 2019;5:609-11.
2352-5126

© 2019 by the American Academy of Dermatology, Inc. Published by Elsevier, Inc. This is an open access article under the CC BY-NC-ND license (<http://creativecommons.org/licenses/by-nc-nd/4.0/>).

<https://doi.org/10.1016/j.jdc.2019.05.014>

CLINICAL VIGNETTE

A 38-year-old woman with a history of severe acne vulgaris treated remotely with isotretinoin presented with acute pain of the neck and lower back and associated radicular symptoms. Physical examination found tenderness over the sternoclavicular joints bilaterally along with occasional scattered pustules on the left palm (Fig 1, A) and nontender grouped, deep-seated vesicles with crust on the right palm (Fig 1, B). Magnetic resonance imaging of the spine found multiple foci of abnormal bone marrow signaling in multiple vertebral levels and the left iliac bone (Fig 2). Core biopsy of the left iliac bone found normal bone negative for cytokeratin AE1/AE3, and cytology was negative for malignant cells (Fig 3).

Question 1: What is the most likely diagnosis?

- A. Infectious osteomyelitis
- B. SAPHO syndrome
- C. Osteosarcoma
- D. Chronic recurrent multifocal osteomyelitis (CRMO)
- E. Rheumatoid arthritis (RA)

Answers:

A. Infectious osteomyelitis — Incorrect. Infectious osteomyelitis is generally focal, and the bone biopsy would show infectious microorganisms.

B. SAPHO syndrome — Correct. SAPHO (synovitis, acne, pustulosis, hyperostosis, and osteitis) syndrome is a rare disorder characterized by cutaneous and osteoarticular manifestations that include acne, palmoplantar pustulosis, psoriasis, arthralgia, chest pain, and enthesitis.¹ Laboratory evaluation is nonspecific, and magnetic resonance imaging is the modality of choice for evaluating osteoarticular manifestations. Bone biopsies are performed to rule out malignancy and infection and primarily exhibit a sterile neutrophilic inflammatory infiltrate early in the disease; late-stage findings include enlarged sclerotic trabeculae with increased osteocytes and marrow fibrosis.¹ Dermatologists may be the first to evaluate SAPHO syndrome, and quick recognition is critical to prevent disability.

C. Osteosarcoma — Incorrect. Imaging of osteosarcoma typically finds a tumor in the metaphysis of long bones in a sunburst pattern and with elevation of the periosteum (Codman triangle) in contrast to the vertebral column lesions seen in our patient.

D. CRMO — Incorrect. CRMO presents with the cutaneous and osteoarticular manifestations of SAPHO but is more likely to present in the pediatric population and primarily affects the appendicular skeleton.² In contrast, SAPHO primarily affects the axial skeleton in adults and is likely its own distinct clinical entity.

E. RA — Incorrect. Our patient lacked the classical findings of RA which include symmetrical stiffness, nodules, and erosions that most commonly affect the hands with sparing of the distal interphalangeal joint.

Question 2: What part of the skeletal system is most commonly affected by this disease?

- A. Vertebral column
- B. Sternoclavicular region
- C. Carpometacarpal joints
- D. Iliac crest
- E. Mandible

Answers:

A. Vertebral column — Incorrect. The spine is affected in approximately 33% of patients with SAPHO syndrome.¹

B. Sternoclavicular region — Correct. The anterior chest wall is affected in 63% to 73% of patients with SAPHO syndrome. In early disease, radiography is often normal. Early lesions, when present, are osteolytic and may be accompanied by endosteal or periosteal reaction. As the disease progresses, the lesions become sclerotic. The pathognomonic bull's head sign can be seen with whole-body scintigraphy and refers to increased radiotracer uptake in the sternoclavicular joints and sternum—the manubrium represents the skull of the bull, and the sternoclavicular joints are the horns.¹ Unlike plain radiography, whole-body scintigraphy and whole-body magnetic resonance imaging may identify subclinical disease, although magnetic resonance imaging is preferred because it has similar sensitivity without the radiation exposure.¹ A bone biopsy is also necessary to rule out malignancy and osteomyelitis.¹

C. Carpometacarpal joints — Incorrect. Peripheral arthritis is present in 33% of patients with SAPHO syndrome.¹

D. Iliac crest — Incorrect. Sacroiliitis is present in 27% to 40% of patients with SAPHO syndrome.¹

E. Mandible — Incorrect. The mandible is affected in approximately 10% of patients with SAPHO syndrome.¹

Question 3: Which of the following is the most appropriate first-line treatment for this disease?

A. Methotrexate

B. Azathioprine

C. Ibuprofen

D. Infliximab

E. Clindamycin

Answers:

A. Methotrexate — Incorrect. The immunosuppressant effects of methotrexate are primarily driven by adenosine accumulation and inhibition of immune cell function. It is often used as a steroid-sparing agent in refractory SAPHO.

B. Azathioprine — Incorrect. Azathioprine causes immunosuppression by inhibiting de novo purine synthesis and is also often used as a steroid-sparing agent for cases refractory to Nonsteroidal anti-inflammatory drugs.

C. Ibuprofen — Correct. SAPHO syndrome treatment is mostly supportive. Nonsteroidal anti-inflammatory drugs like ibuprofen are used for pain and isotretinoin for acne treatment. Isotretinoin may cause a dose- and duration-dependent hyperostosis similar to that seen in SAPHO syndrome called retinoid hyperostosis (RH).³ RH is most commonly asymptomatic and seen after long-duration therapy. RH is unlikely in our patient given her short duration of isotretinoin therapy

(≤6 months) and the long delay from retinoid exposure to symptom onset.³

D. Infliximab — Incorrect. Tumor necrosis factor (TNF)- α inhibitors (eg, infliximab) are not considered first-line treatments but have been used in refractory SAPHO given high levels of TNF- α found in bone specimens and the involvement of TNF- α in neutrophilic dermatoses—like palmar pustulosis.⁴ A 7-day course of prednisone and the TNF- α inhibitor, etanercept, resolved many of our patient's skin and musculoskeletal complaints.

E. Clindamycin — Incorrect. Clindamycin is a first-line antibiotic for treating acne vulgaris. *Propionibacterium acnes* has been isolated from 67% of skin and bone biopsies in patients with SAPHO syndrome, and although remission has been seen with oral antimicrobial treatment of *P acnes*, disease activity returned to baseline levels within 3 months after the discontinuation of therapy.⁵

Abbreviations used:

CRMO: chronic recurrent multifocal osteomyelitis

RA: rheumatoid arthritis

RH: retinoid hyperostosis

TNF: tumor necrosis factor

REFERENCES

1. Nguyen MT, Borchers A, Selmi C, Naguwa SM, Cheema G, Gershwin ME. The SAPHO syndrome. *Semin Arthritis Rheum.* 2012;42(3):254-265.
2. Rohekar G, Inman RD. Conundrums in nosology: synovitis, acne, pustulosis, hyperostosis, and osteitis syndrome and spondylarthritis. *Arthritis Rheum.* 2006;55(4):665-669.
3. DiGiovanna JJ. Isotretinoin effects on bone. *J Am Acad Dermatol.* 2001;45(5):S176-S182.
4. Firinu D, Garcia-Larsen V, Manconi PE, Del Giacco SR. SAPHO syndrome: current developments and approaches to clinical treatment. *Curr Rheumatol Rep.* 2016;18(6):1-9.
5. Assmann G, Kueck O, Kirchhoff T, et al. Efficacy of antibiotic therapy for SAPHO syndrome is lost after its discontinuation: an interventional study. *Arthritis Res Ther.* 2009;11(5):R140.