

# Secondary Signet-ring cell adenocarcinoma of urinary bladder from a gastric primary

Pramod K. Sharma, Mukesh K. Vijay, Ranjit K. Das, Uttara Chatterjee<sup>1</sup>

Departments of Urology, and <sup>1</sup>Pathology, Institute of Post Graduate Medical Education and Research and SSKM Hospital, Kolkata, India

## Abstract

Primary bladder tumor is a frequent urological malignancy, whereas the incidence of secondary bladder tumor from a distant organ is quite rare. Secondary bladder neoplasms represent 1% of all malignant bladder tumors, of which distant metastases from stomach account for about 4% of cases. We present the case of a 30-year-old male who underwent partial gastrectomy for Signet-ring cell carcinoma of the stomach and presented 2 years later with hematuria. On computerized tomography scan, a bladder tumor was found which was resected cystoscopically. The histopathological examination revealed secondary Signet-ring cell adenocarcinoma of the urinary bladder.

**Key Words:** Secondaries urinary bladder, Signet-ring cell adenocarcinoma, stomach carcinoma

## Address for correspondence:

Dr. Pramod Kumar Sharma, Room No. 508, Junior Doctors Hostel, IPGME and R and SSKM Hospital, 242, AIC Bose Road, Kolkata, India.

E-mail: [surgpeekay@gmail.com](mailto:surgpeekay@gmail.com)

Received: 17.06.2010, Accepted: 01.10.2010

## INTRODUCTION

Primary bladder tumor is a frequent urological malignancy, whereas the incidence of secondary bladder tumor from a distant organ is quite rare. Bladder tumors evolve as transitional cell carcinomas in 95% of cases, whereas primary adenocarcinomas and squamous cell carcinoma account for less than 5% of all bladder cancers. Secondary bladder neoplasms represent 1% of all malignant bladder tumors, of which distant metastases from stomach account for about 4%. Signet-ring cell cancer is a rare type of bladder malignancy, accounting for approximately 0.24% of all urinary bladder malignancies.

## CASE REPORT

The patient, RG, a 30-year-old male, was diagnosed as having

carcinoma stomach by endoscopic biopsy from a prepyloric ulcer. Computerized tomography (CT) scan of the patient was suggestive of a growth in the pylorus of the stomach without any evidence of metastasis or ascites. He underwent radical D<sub>2</sub> partial gastrectomy with gastrojejunostomy, followed by six cycles of chemotherapy with Docetaxel and Oxaloplatin. The histopathological examination of the resected specimen was suggestive of a Signet-ring cell variant of poorly differentiated mucoid adenocarcinoma.

The patient progressed well after chemotherapy but presented 2 years later with complaints of weight loss and hematuria which was painless and intermittent. The ultrasonogram of the abdomen showed a localized thickening in the antero-superior wall of the urinary bladder. CT scan was suggestive of a neoplasm in the dome and adjacent left lateral wall of the urinary bladder. The gastrojejunal (GJ) anastomosis appeared to be normal. The tumour marker CA-72.4 levels were found to be elevated (32.61 U/ml; Ref. range 5.60–8.20 U/ml).

On cystoscopy, multiple grape-like lesions were found on the dome and left lateral wall of the urinary bladder [Figure 1]. The growth was resected transurethrally and on histopathological examination was found to be a poorly differentiated mucin

## Access this article online

### Quick Response Code:



### Website:

[www.urologyannals.com](http://www.urologyannals.com)

### DOI:

10.4103/0974-7796.82177

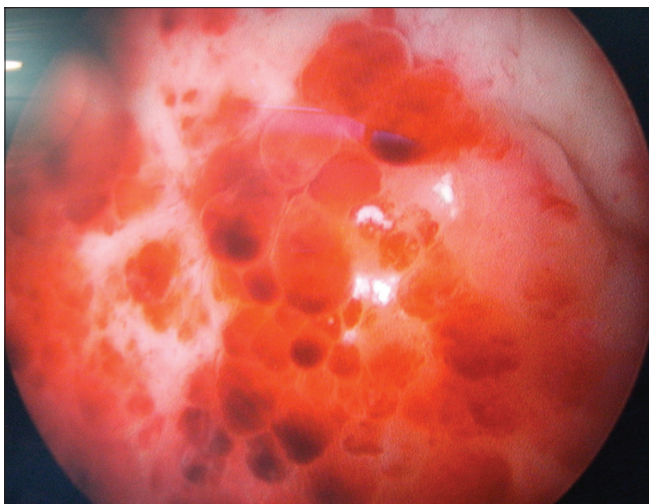
secreting adenocarcinoma of Signet-ring cell type present in lamina propria [Figure 2]. The tissue from the base of the tumor was free from the lesion.

The patient was given six cycles of chemotherapy with Oxaloplatin, Epirubicin and Capecitabine, in consultation with the medical oncologists of our institution. Following the completion of chemotherapy, the patient has been progressing well with no evidence of recurrence on cystoscopy till date (5 months following completion of chemotherapy).

## DISCUSSION

Metastatic neoplasms in the urinary bladder are unusual, accounting for 1% of all bladder neoplasms. The mechanism of metastasis to the urinary bladder includes direct extension of primary focus, implant of exfoliated cells from ureter and renal pelvis and lymphatic, hematogenous or peritoneal dissemination from distant focus. In case of bladder involvement by direct extension, the most common primary sites are colon, prostate, rectum and cervix. However, in case of metastasis from a distant organ, stomach ranks third as the most common location of primary tumor after melanoma and breast.<sup>[1]</sup> In our case, as the base of the tumor was free from the lesion, the mode of spread was most probably hematogenous, and not by direct extension, which in itself is a rare occurrence.

The metastatic bladder cancer can be classified into two types both radiologically and macroscopically: protuberant and diffuse type. Most of the cases are protuberant, as in our case, in which gross hematuria is generally observed, greatly facilitating diagnosis. In contrast, the diffuse type is rare. These cases are characterized by irritable bladder symptoms without gross hematuria and present diagnostic difficulties.<sup>[2]</sup>



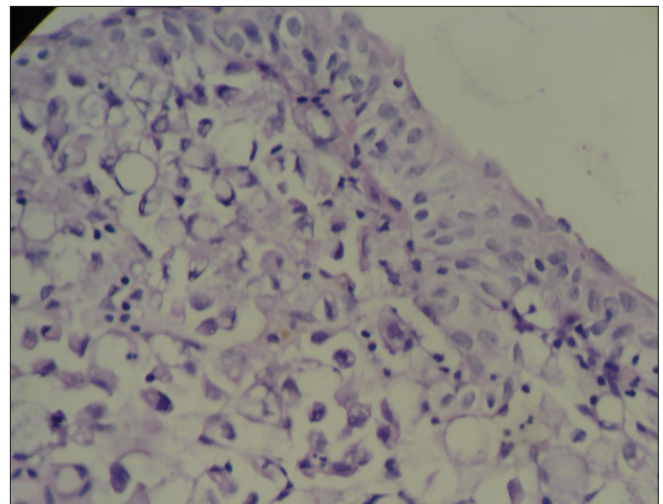
**Figure 1:** Cystoscopic appearance showing multiple grape-like lesions in the wall of urinary bladder

The relative infrequency of primary adenocarcinoma of the bladder causes the dilemma whether the bladder adenocarcinoma represents a primary or a secondary process. The presence of polypoid formation, Brun's nests or glandular or mucous metaplasia within the adjacent mucosa suggests a primary origin as also the presence of foci of other epithelial tumor cells such as squamous or transitional cells.<sup>[3]</sup>

Metastatic gastric cancers to the bladder behave differently in males and females. In females, bladder tumors are rarely found in the absence of Kruckenberg's tumor (ovarian secondaries from GI tumors). Therefore, the ovaries were hypothesized to direct metastasis from the stomach and other gastrointestinal organs to the urinary bladder.<sup>[3]</sup>

The Signet-ring variant of adenocarcinoma is a very rare entity, and when diagnosed in the bladder, it is most likely a primary. However, a metastatic spread from a GI primary should also be considered and an appropriate work-up to locate these primaries should be done as the treatment of the primary type differs from that of the metastatic type.<sup>[4]</sup> The treatment of primary Signet-ring cell adenocarcinoma is primarily surgical while that of the metastatic type is with chemotherapy. A very few cases of metastatic Signet-ring adenocarcinoma of the urinary bladder have been reported in the literature, mostly from Japan.

Management of secondaries in urinary bladder from a gastric primary is mainly with chemotherapy. Though there are no standard chemotherapeutic regimens for metastatic gastric carcinoma, best survival results are achieved with a three-drug regimen containing 5-fluorouracil (5-FU), an Anthracyclin and platinum compound like Cisplatin.<sup>[5]</sup> In our case, we used



**Figure 2:** Histopathology of the bladder lesion showing multiple Signet-ring cells in the lamina propria with overlying transitional cell epithelium. The stain used is Hematoxylin and Eosin stain and it is a high power(400x) view

platinum compound, Oxaloplatin; Epirubicin, an anthracyclin; and Capecitabin, a pro-drug of 5-FU. Other agents which may be tried include Irinotecan, Methotrexate, etc.

## CONCLUSION

Signet-ring cell type of adenocarcinoma is a rare type of urinary bladder tumor, majority of which is primary in origin, with metastatic tumors being a rarity. However, it is essential to differentiate between primary and metastatic Signet-ring cell adenocarcinomas as the treatment strategies for both are different with surgery being the first-line treatment modality for primary tumors, while the treatment of secondary Signet-ring cell adenocarcinoma is mainly by chemotherapy. So, all the cases of Signet-ring cell type of adenocarcinoma should be worked-up to search for a possible gastro-intestinal primary and a gastroscopy and possibly colonoscopy should be included in the work-up of all cases of Signet-ring cell adenocarcinoma of urinary bladder. Looking for such a primary, despite its rarity, may have significant clinical and prognostic implications, and

should therefore be considered.

## REFERENCES

1. Farhat MH, Mounneh G, Jalloul R, El Hout Y. Secondary adenocarcinoma of the urinary bladder from a primary gastric cancer. *J Med Liban* 2007;55:162-4.
2. Ota T, Shinohara M, Kinoshita K, Sakoma T, Kitamura M, Maeda Y. Two cases of metastatic bladder cancers showing diffuse thickening of the bladder wall. *Jpn J Clin Oncol* 1999;29:314-6.
3. Mostofi FK, Thompson RV, Dean AL. Mucous adenocarcinoma of the urinary bladder. *Cancer* 1955;8:741-58.
4. Saba NF, Hoening DM, Cohen SI. Metastatic Signet-ring cell adenocarcinoma to the urinary bladder. *Acta Oncol* 1997;36:219-20.
5. Wagner AD, Grothe W, Haerting J, Kleber G, Grothey A, Fleig WE. Chemotherapy in advanced gastric cancer: A systematic review and meta-analysis based on aggregate data. *J Clin Oncol* 2006;24:2903-9.

**How to cite this article:** Sharma PK, Vijay MK, Das RK, Chatterjee U. Secondary signet-ring cell adenocarcinoma of urinary bladder from a gastric primary. *Urol Ann* 2011;3:97-9.

**Source of Support:** Nil, **Conflict of Interest:** None.

## Staying in touch with the journal

### 1) Table of Contents (TOC) email alert

Receive an email alert containing the TOC when a new complete issue of the journal is made available online. To register for TOC alerts go to [www.urologyannals.com/signup.asp](http://www.urologyannals.com/signup.asp).

### 2) RSS feeds

Really Simple Syndication (RSS) helps you to get alerts on new publication right on your desktop without going to the journal's website. You need a software (e.g. RSSReader, Feed Demon, FeedReader, My Yahoo!, NewsGator and NewzCrawler) to get advantage of this tool. RSS feeds can also be read through FireFox or Microsoft Outlook 2007. Once any of these small (and mostly free) software is installed, add [www.urologyannals.com/rssfeed.asp](http://www.urologyannals.com/rssfeed.asp) as one of the feeds.